

## Management of Critical Lower Limb Ischemia through Transpedal Approach

HANY A. MOHAMED, M.Sc.; AHMED A. SHAKER, M.Sc. and AMR ABD EL-RAHIM, M.D.

The Department of General Surgery, Faculty of Medicine, Cairo University

### Abstract

*Introduction:* Until recently, the inability to cross tibial lesions in an antegrade fashion was accepted as a failure of interventional therapy and an indication for an open surgical approach.

In 1990, Iyer and colleagues described the use of a retrograde pedal/tibial approach to handle cases in which the conventional way of crossing the tibial lesion had failed.

*Aim of the Work:* To assess transpedal approach in vessel recanalization on failure of re-entry to distal true lumen during antegrade approach or in presence of limited patent distal artery.

*Patients and Methods:* The study was performed on 14 limbs in 14 patients with critical lower limb ischemia for whom percutaneous transluminal angioplasty was failed via antegrade approach.

*Results:* By using transpedal approach, clinical success rate after the procedure which was detected by immediate regaining of the pulse or clinical improvement was 13 cases from 14 cases (92.85%).

*Conclusion:* Transpedal approach is an ideal line of intervention in failure of re-entry of subintimal angioplasty or limited patent distal part of arterial tree.

**Key Words:** Transpedal – Retrograde – Lower limb – Ischemia.

### Introduction

**PERIPHERAL** Arterial Disease (PAD) is one of the manifestations of systemic atherosclerosis. The prevalence of PAD increases with the age of the population, [1].

It is important to remember the major and high significant association between coronary artery disease and cerebrovascular disease in these patients, because it represents the major cause of morbidity and mortality in the PAD population, [2].

Critical limb ischemia (CLI) is usually caused by multilevel atherosclerotic disease, typically in patients with a history of cigarette smoking, diabetes mellitus, or both. The risk of limb loss varies from 10% to 40% over the first year, with fewer than 50% of patients alive at 5 years. These patients die of cardio vascular disease, and therefore, evaluation must consider the systemic nature of the problem, [3].

PAD is mostly silent in its early stages but may manifest as intermittent claudication when the luminal obstruction is more than 50% with progression of disease, the symptoms typically intensify to rest pain with the potential for frank tissue loss, [4].

The application of percutaneous endovascular therapy for arterial occlusive disease of the lower extremities continues to increase. The long-term results of endovascular therapy are expected to improve with advancements in the technology supporting these interventions. Overall, the initial technical success rate for open surgical procedures and percutaneous endovascular therapy are somewhat similar; however, surgery frequently provides greater long-term patency. On the other hand, Percutaneous Transluminal Angioplasty (PTA) procedures are often associated with lower morbidity and mortality. Moreover, late failure of endovascular therapies can usually be treated successfully with percutaneous techniques, [5].

Although the usual treatment strategy for tibial lesions requires antegrade femoral artery approach, in 10-20% of the patients this approach does not allow the crossing of the lesion itself. So retrograde approach is used [6].

Early in the experience, access into the pedal vessels was obtained via a cut down and was

accomplished later on using direct percutaneous arterial puncture [7].

### Patients and Methods

This study included 14 patients presented to the Vascular Department in Kasr Al-Aini Hospital and New Kasr Al-Aini Teaching Hospital with critical lower limb ischemia having femoropopliteal and or infrapopliteal occlusive diseases for whom percutaneous transluminal angioplasty with or without stenting was done, between May 2011 and December 2013.

The procedure, possible complications, benefits, risks and other alternative interventions were all explained to the patients and an informed consent was obtained.

#### Methodology:

Clinical assessment through history taking and clinical examination was done for all patients including age, gender and major risk factors for atherosclerosis including; Diabetes mellitus, smoking, hypertension and dyslipidemia.

Pre-procedural investigations was done in the form of routine laboratory tests: Complete blood picture, kidney and liver function tests, coagulation profile, blood glucose level and lipid profile in addition to Duplex scanning and CT Angiography.

#### Selection criteria for this study:

##### Inclusion criteria:

In incapacitating claudication, critical limb ischemia (ischemic rest pain, minor tissue loss,

nonhealing ulcer or focal gangrene and major tissue loss) and patients with flush superficial femoral artery occlusion or total occlusion of femoral artery or popliteal artery or proximal tibial vessels in which subintimal angioplasty was performed but there is failure of re-entry or when there is a limited segment of patent distal target artery available for re-entry.

##### Exclusion criteria:

Patients with stenosis of femoral artery or popliteal artery or proximal tibial vessels in which intraluminal angioplasty is suspected, patients with flush super facial femoral artery occlusion or total occlusion of femoral artery or popliteal artery or proximal tibial vessels in which subintimal angioplasty was performed with re-entry and proximal aorto-iliac disease or known intolerance to study medications or contrast agents.

##### Technique of transpedal approach:

The retrograde access technique comprises two steps. The first step requires gaining percutaneous access into the pedal vessel. The second step involves crossing the occlusion in a retrograde fashion.

##### Access into the pedal vessel:

Patients should be prepared in a way to allow the usual access through either a retrograde or antegrade femoral approach; additionally, the foot should be prepared for the pedal access patients should be sedated in order to minimize foot movement, especially if the road mapping technique is used for access. Fig. (1).

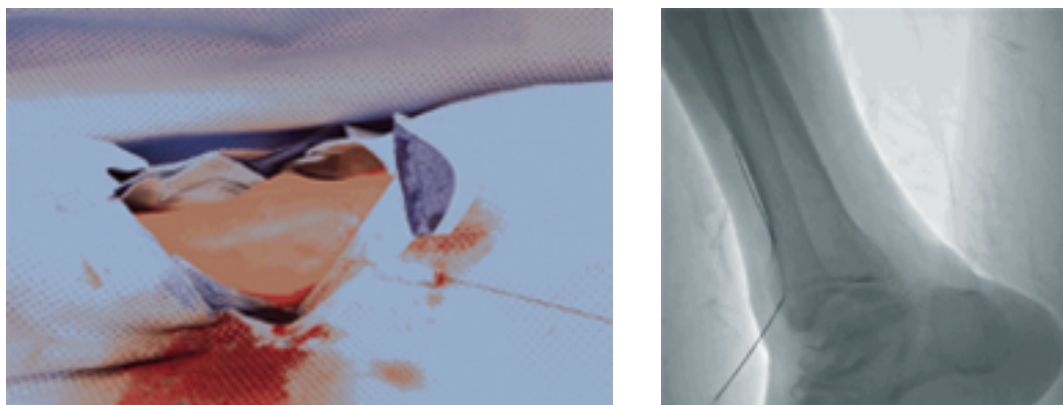


Fig. (1): Retrograde transpedal access.

All tibial vessels, including the anterior tibial, posterior tibial, and peroneal arteries, can be accessed in retrograde fashion. The access can be obtained using either standard surgical cut down on the vessel, but this carries the risk of creating asurgical wound

in the distal part of an ischemic limb especially in failure of retrograde approach-or percutaneously directly in heavily calcified vessels basedon fluoroscopic guidance alone, or by road mapping aided by ante grade angiography or duplex guided.

After accessing the artery (as evidenced by back bleeding), the micropuncture access wire (0.018 in) is passed through the needle into the vessel under fluoroscopic guidance. The needle is removed, and a micropuncture 4-Fr sheath is passed over the wire, securing access then the patient is fully heparinized (70-100 unit/kg/h).

#### *Crossing the occlusion:*

The use of the 0.014-inch wire has been disappointing as this platform does not usually have enough body to support the retrograde crossing of the tibial occlusion. So the 0.035-inch Terumo Glidewire R. (Terumo Medical, Somerset, New Jersey) is used supported by 4F guiding catheter.

Once the occlusion is crossed, the wire needs to be snared from the common femoral artery access better accomplished as distally as possible, just above the crossed occluded segment. This technique avoids the possibility of the tibial retrograde wire inadvertently finding its way into the subintimal plane above the occlusion in the popliteal or the superficial femoral artery.

Occasionally, the retrograde wire enters a subintimal plane that is different from that of the wire from the common femoral access; this will prevent successful snaring of the retrograde wire from above. In these situations, double balloon inflation just above the proximal end of the occlusion where both distal ends of the balloons are essentially touching each other to disrupt the septum separating the two subintimal spaces to create a single lumen where snaring of the retrograde wire is possible.

Once wire access across the occlusion is established, intervention is performed in the standard fashion, usually by balloon angioplasty and stenting. The retrograde introducer sheath is then withdrawn and hemostasis is secured through digital compression for 5 to 10 minutes.

#### *Procedural outcome:*

The procedure is considered to be successful depending on the following:

Clinical success i.e. regain of pulse, revascularization warmth and disappearance of rest pain. Angiographic success defined as less than 30% residual stenosis measured at the narrowest point of vascular lumen.

#### *Procedural complications:*

Complications were divided into major complications, minor complications and death. Major

complications that need for emergency surgery due to major bleeding or acute thrombotic occlusion. Minor complications included small hematoma, treated dissection, or peripheral emboli.

#### *Post-procedural management:*

The arterial sheaths were routinely removed 4-6 hours after the procedure guided by PTT and mobilization was delayed for 12-24 hours. Digital compression was held proximal to the skin puncture site for 15-20 minutes. Most patients were discharged on the second day following the procedure after receiving instructions on risk factors control and treatment including Acetyl salicylate 150mg/day for life, Clopidogrel 75mg/day for at least 3 months and Atrovastatin according to the presence or absence of dyslipidemia.

## **Results**

This study included 10 males (71.4%) and 4 females (28.6%) with ratio 2.5:1 and the patient's age varied between 40 and 85 years with a mean of 62.5, 12 patients (85.7%) were diabetics, 12 patients (85.7%) were dyslipidemic, 10 patients (71.4%) were smokers, 2 patients (14.3%) were hypertensive.

#### *Clinical presentation:*

4 patients presented by rest pain (28.5%) Rutherford 4, 2 patients presented by non healing ulcer (14.2%) Rutherford 5 and 8 patients presented by gangrene (57.3%) Rutherford 5, 6.

#### *Procedural data:*

##### *1- Access site:*

Through anterior tibial artery in 10 limbs (71.4%), and through dorsalis pedis artery in 4 limbs (28.6) (Figs. 2,3).

Surgical cutdown of the pedal artery was done in 2 cases. Fig. (4).

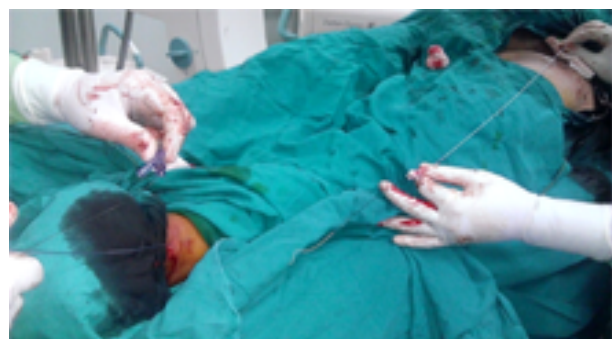

Fig. (2): Transpedal approach through anterior tibial artery.

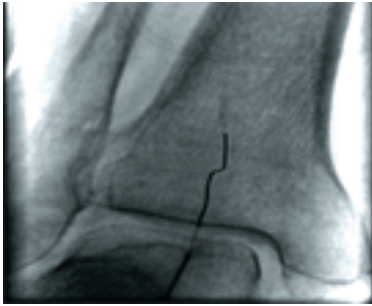

Fig. (3): Transpedal access using 0.0035 inch wire.

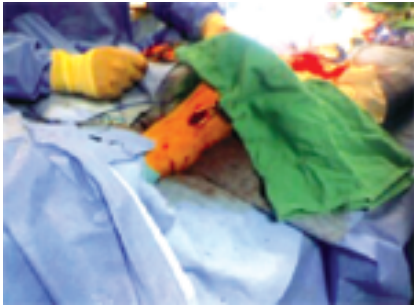

Fig. (4): Transpedal access through surgical cut down.

## 2- Snaring:

Snaring was used in 4 cases Figs. (5,6).

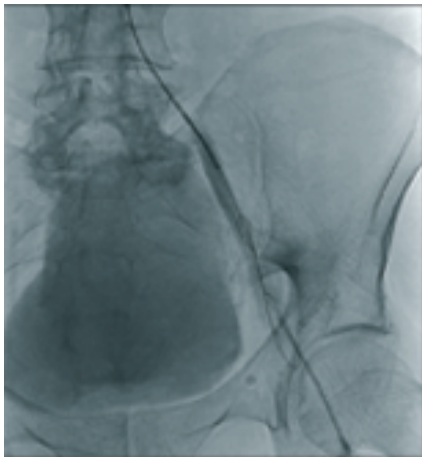

Fig. (5): Snaring of retrograde wire from contralateral retrograde access.

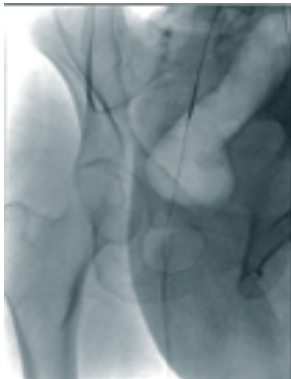

Fig. (6): Snaring of retrograde wire from contralateral retrograde access using 0.035 inch wire.

## 3- Balloon angioplasty:

Balloon angioplasty was done in all cases (14 limbs). The balloon diameters ranged between 3 and 6mm and balloon lengths ranged between 40mm and 100mm. Inflation pressure ranged between 8 and 12 ATM. Inflation time ranged between 15 and 45 seconds. Figs. (7,8).

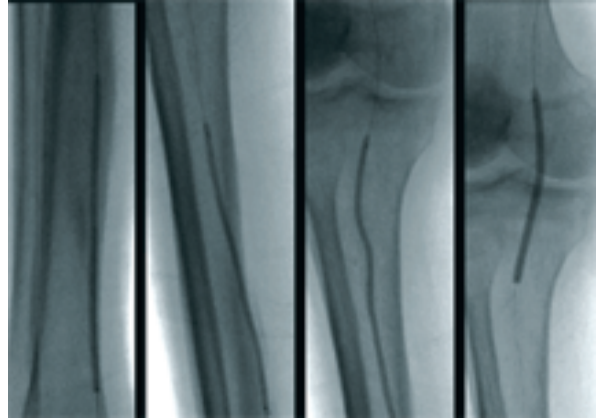


Fig. (7): Balloon dilatation of the popliteal and infrapopliteal lesions.

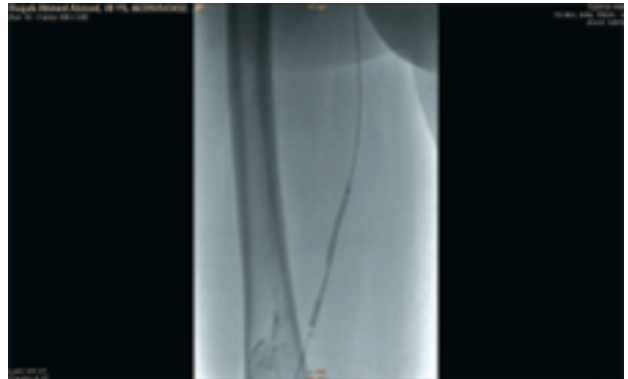

Fig. (8): Balloon dilatation of SFA lesion.

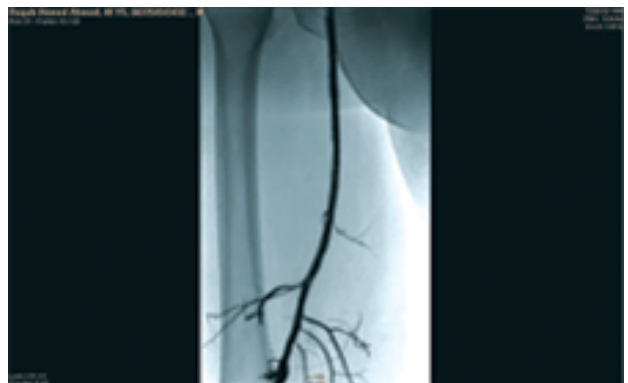


Fig. (9): After PTA of SFA lesion.

## 4- Stent deployment:

Stenting was carried out in 4 limbs (self expandable stents for residual stenosis more than 30% or recoil). All stents diameter was 6mm and the lengths were (60mm in 2 cases, 80mm in 1 case and 120mm in 1 case, Fig. (10)).




Fig. (10): Stent deployment in distal SFA lesion.

#### 5- Procedural complications:

1 case developed limited haematoma (7.2%) and 1 case developed infection (7.2%) at the site of arterial cut down resolved by conservative measures. There were no major complications, there was no any mortality.

#### Clinical outcome:

In this study, by using transpedal approach, clinical and angiographic success rate after the procedure was 13 cases from 14 cases (92.8%), Fig. (9). One case converted to open surgery due to heavy calcification of the vessels with difficult crossing the lesions.

### Discussion

Transpedal access is a relatively recent innovation in vascular interventions. It is important for the treatment of patients with critical limb ischemia with femoropopliteal or tibial occlusive disease when the regular antegrade approach for crossing the occlusion is not possible. In these cases, the transpedal retrograde approach is a very successful technique for crossing the occlusion, and it has a very low rate of occlusion at the access point of the pedal/tibial vessels [6].

In study done by Noory et al., 2009, 56 patients (43 men and 13 females, mean age 68 range 43-87) with stable chronic peripheral artery disease (Rutherford category 2 to 5) were treated with antegrade subintimal angioplasty that could not be completed owing to re-entry failure then retrograde access using transpedal access was used for completing the procedure.

In study done by Tay in 2012, 24 patients with critical limb ischemia underwent endovascular intervention. The median patient age was 72 years. The majority (70.8%) were male. 75% were in Rutherford category 6, 20.8% in category 5 and 4.2% in category 4 after antegrade access failure, retrograde transpedal access was used for recanalization [8].

This study included 10 males (71.4%) and 4 females (28.6%) with ratio 2.5:1 and the patient's age varied between 40 and 85 years with a mean of 62.5, 12 patients (85.7%) were diabetics, 12 patients (85.7%) were dyslipidemic, 10 patients (71.4%) were smokers and 2 patients (14.3%) were hypertensive, 4 patients presented by rest pain (28.5%) Rutherford 4, 2 patients presented by non healing ulcer (14.2%) Rutherford 5 and 8 patients presented by gangrene (57.3%) Rutherford 5, 6.

In study done by Botti et al., in 2013, a series of six cases in which the retrograde pedal approach was attempted for critical limb ischemia with ulceration and failed antegrade recanalization of at least one tibial vessel runoff to the foot. Access was obtained through posterior tibial artery in four patients and through the dorsalis pedis artery in two patients.

All patients showed complete healing using the technique. With no major complications [9].

As regard to study done by Roger et al., in 2011, 13 cases with failed conventional antegrade recanalization of the tibial vessels were included, indication for intervention was gangrene in ten cases and severe claudication in three cases. Eleven cases were accessed through the posterior tibial artery and two cases through the dorsalis pedis artery. In 11 cases, the technique was successful in recanalizing the accessed tibial vessels with restoration of inline flow. The two failed cases showed no deterioration in the condition of the limb, and there were no access-site complications in any [6].

Montero et al., in 2008, reported using the Transpedal approach in 51 cases. The indication for intervention was failed antegrade recanalization of at least one tibial vessel; 44 patients had successful recanalization of the anterior tibial artery and 7 patients through posterior tibial artery. There was a single instance of dorsalis pedis artery occlusion at the access site after a failed attempt to recanalize the anterior tibial artery [10].

In the present study, we used transpedal access in 14 cases, through anterior tibial artery in 10 limbs (71.4%), and through dorsalis pedis artery in 4 limbs (28.6%), with technical success rate (92.8%).

A study done by Botti et al., in 2013, showed that 8 cases were successfully recanalized by using transpedal approach with no major complications [8].

As regard to study done by Roger et al., in 2011, which presented a series of 13 cases with critical limb ischemia treated by transpedal approach, there were no access-site complications [6].

In this study, 1 case developed haematoma (7.2%) and 1 case developed infection (7.2%) at the site of arterial cutdown resolved by conservative management. And antibiotic which were completely resolved after one week of hospital stay. There was no major complications.

#### Conclusion and Recommendations:

- Transpedal approach is an ideal line of intervention in failure of re-entry of subintimal angioplasty or limited patent distal part of arterial tree.

#### References

- 1- NORGREN L., HIATT W.R., DORMANDY J.A., et al.: Inter-Society Consensus for the Management of Peripheral Arterial Disease (TASC II). Eur. J. Vasc. Endovasc. Surg., 33-5, 2007.
- 2- CRIQUI M.H., LANGER R.D., FRONEK A., FEIGELSON H.S., KLAUBER M.R., McCANN T.J. and BROWNER D.: Mortality over a period of 10 years in patients with peripheral arterial disease. N. Engl. J. Med., 326: 381-6, 1992.
- 3- BELLER G.A., BONOW R.O. and FUSTER V.: ACC revised recommendations for training in adult cardiovascular medicine: Core Cardiology Training II (COCATS 2) (revision of the 1995 COCATS training statement). J. Am. Coll. Cardiol., 39: 1242-6, 2002.
- 4- De VRIES J.P., VAN DEN HEUVEL D.A., VOS J.A., VAN DEN BERG J.C. and MOLL F.I.: Freedom from secondary interventions to treat stenotic disease after percutaneous transluminal angioplasty of infrarenal aorta: Long-term results. J. Vasc. Surg., 39: 427-31, 2004.
- 5- JORDAN W.D. and TAYLOR S.M.: SFA stenosis treated with cryoplasty. Endovascular. Today, 1: 31-3, 2004.
- 6- ROGERS R.K., DATTOLO P.B., GARCIA J.A., TSAI T. and CASSERLY I.P.: Retrograde approach to recanalization of complex tibial disease. Catheter. Cardiovasc. Interv., 77 (6): 915-25, 2011.
- 7- WALKER C.: Durability of PTAs using pedal artery approaches. 37<sup>th</sup> Annual VEITH Symposium; November 18<sup>th</sup>, New York City, 43, 2010.
- 8- NOORY B., HARTHUN N.L., BIONDI-ZOCCHI G.G., CAGE D., LEUNG D.A., ANGLE J.F., et al.: Subintimal arterial flossing with antegraderetrograde intervention (SAFARI) for subintimal recanalization to treat chronic critical limb ischemia in infrainguinal vessels. J. Vasc. Interv. Radiol., 16 (1): 37-44, 2009.
- 9- BOTTI S.S., LEWIN R.F., DORROS G. and ZAITOUN R.: Percutaneous retrograde tibial access in limb salvage. Cathet. Cardiovasc. Diagn., 4: 251-3, 2013.
- 10- MONTERO-BAKER M., SCHMIDT A., BRAUNLICH S., ULRICH M., THIEME M., BIAMINO G., et al.: Retrograde approach for complex popliteal and tibio-peroneal occlusions. J. Endovasc. Ther., 5: 594-604, 2008.

## الملخص العربي

القصور المزمن للشرايين الطرفية أحد أهم أعراض تصلب الشرايين والتي تظهر مع تقدم السن هناك إتصال وثيق الصلة بين هذا القصور المزمن الشرايين الطرفية وقصور الشرايين التاجية والتي تؤدي بنسبة كبيرة إلى الوفاة.

خلال الفترة الأخيرة هناك تقدم ملحوظ في إستخدام التوسيع البالوني وتركيب الدعامات للشرايين الطرفية والذي بدوره أدى إلى التحول من العلاج الجراحي التقليدي لقصور الشرايين الطرفية إلى إستخدام العلاج بالتوسيع البالوني وبالدعامات وهذا العلاج أكثر أماناً وأقل خطورة على المرضى من العلاج التقليدي.

العلاج بالتوسيع البالوني وبالدعامات يمتاز عن العلاج الجراحي في عدة مميزات أهمها أنه يتم تحت المخدر الموضعي لذا قد يستخدم في المرضى ذوي الصحة العامة الضعيفة والذين لا يقدر على تحمل المخدر الكلي أو النصفى والمريض قد يغادر المستشفى في نفس يوم القسطرة ويعود إلى ممارسة حياته الطبيعية بعد يوم أو يومين من العلاج وفي حالة فشل القسطرة للمرة الأولى قد يتم إعادة المحاولة مرة أخرى وينجح.

كل هذه المميزات أدت إلى الاتجاه ناحية القسطرة عن اللجوء إلى العلاج الجراحي التقليدي.

أن إستخدام تقنية القسطرة التداخلية التقدمية الرجعية تحت بطانة الوعاء الشرياني للقصور الحرج للطرف السفلى قد أضافت وسيلة جديدة وحديثة في علاج تصلب الشرايين الطرفية وقد أثبتت هذه التقنية نسبة نجاح كبيرة جداً مما يستوجب ضرورة إستخدامها.