

Control of Experimental Colisepticaemia in Broiler Chickens Using Sarafloxacin

*Wafaa A. Abd El-Ghany and K. Madian

Faculty Veterinary Medicine, Cairo University, Cairo, Egypt

Wafaa.ghany@yahoo.com

Abstract: This work was conducted to detect the effect of using sarafloxacin (5 mg/kg body weight) in the drinking water of broiler chickens to control experimental colisepticaemia in broiler chickens. One hundred and seventy, day old broiler chicks were used in the study. Twenty chicks at the day of arrival were sacrificed and cultured to ensure absence of *E. coli* infection. One hundred and fifty chicks were divided into three equal groups, each consists of 50 birds. Group (1) was challenged with *E. coli* and not treated with sarafloxacin (control positive), group (2) was challenged with *E. coli* and treated with sarafloxacin, while group (3) was neither challenged with *E. coli* nor sarafloxacin treated (blank control). Challenge was done intramuscularly (I/M) at 2 weeks of age in groups (1 and 2) as each bird received 0.5 ml of the nutrient broth culture containing 10^8 colony forming unit (CFU) *E. coli* O78 / ml. One appearance of signs, sarafloxacin was added to the drinking water for 3 successive days. All the birds were kept under complete observation for 6 weeks for estimating the bird's performance (body weight and feed conversion rate) and recording signs, mortalities, gross lesions, re-isolation of the organism and microscopical examination of the organs. The obtained results indicated significant ($P<0.05$) improvement in chickens performance in chickens challenged with *E. coli* and treated with sarafloxacin than those challenged and not treated. On the other hand, significant ($P<0.05$) decrease in morbidity and mortality rates, gross organs lesion score and re-isolation of *E. coli* O78 from the internal organs of chickens treated with sarafloxacin when compared with *E. coli* challenged non treated birds. Also, improvement of the microscopical lesion scores was also detected in sarafloxacin treated group. It could be concluded from the above results that sarafloxacin used in a dose of 5 mg/kg body weight in the drinking water for 3 consecutive days is very effective in controlling of colisepticaemia in broiler chickens.

[Wafaa A. Abd El-Ghany and K. Madian, Control of Experimental Colisepticaemia in Broiler Chickens Using Sarafloxacin. Life Science Journal. 2011;8(3):318-328] (ISSN:1097-8135). <http://www.lifesciencesite.com>.

Keywords: Sarafloxacin, *E. coli*, Chickens, Treatment

1. Introduction

Escherichia coli (*E. coli*) is a normal inhabitant chicken's microflora. Some avian *E. coli* serotypes are pathogenic and induce significant economic problems in broiler chickens (Goodwin *et al.*, 1993, Yogaratnam, 1995, Jakob *et al.*, 1998, Dho-Moulin and Fairbrother, 1999 and Russell, 2003). Serogroups O78, O2 and O8 are common serotypes usually associated with colisepticaemia in poultry (Wray and Carroll, 1993). Colisepticaemia is the primary cause of death associated with an early respiratory disease complex (RDC) characterized by depression, respiratory distress and increased mortality in broiler chickens (Tablante *et al.*, 1999 and Barnes *et al.*, 2008). Typical lesions among birds with field and experimentally induced colisepticemia are airsacculitis, pericarditis and perihepatitis (Wray *et al.*, 1996). The response of coliform infections to various medications is erratic and often difficult to evaluate. Significant increase in appearance of drug resistant strains of *E. coli* isolated from poultry has complicated the problem (Scioli *et al.*, 1983, Alimehr *et al.*, 1999 and Geornaras *et al.*, 2001). Laboratory tests to determine the sensitivity of *E. coli* to the various drugs are useful to select the most beneficial drugs (Vandemaele *et al.*, 2002).

Fluoroquinolones are broad spectrum antimicrobial agents that are effective in the treatment of wide range of infections (Medders *et al.*, 1998). Norfloxacin, enrofloxacin, ciprofloxacin, pefloxacin and sarafloxacin are examples of synthetic antimicrobials belonging to fluoroquinolone class of compounds (Hooper, 1998). The efficacies of different members of fluoroquinolone group against *E. coli* infections when the medication was administered in drinking water have been reported in several avian species (Bauditz, 1987, Copeland *et al.*, 1987, Behr *et al.*, 1988, Hafez *et al.*, 1990, Ter Hune *et al.*, 1991, Kempf *et al.*, 1995, Glisson, 1996, Gautrais and Copeland, 1997, Sumano *et al.*, 1998, Glisson *et al.*, 2004, Marien *et al.*, 2007, Da Costa *et al.*, 2009 and Garmyn *et al.*, 2009).

Sarafloxacin is a fluoroquinolone antibacterial drug which was approved in 1996 in United States for veterinary use to control morbidity and mortality associated with avian colibacillosis infections (Jones and Erwin, 1998 and Medders *et al.*, 1998). Like other fluoroquinolones, it acts by inhibiting the structure and function of DNA gyrase, a bacterial topoisomerase II which is an essential enzyme for DNA replication and transcription (Wolfson and Hooper, 1985 and Martinez *et al.*,

2006). The chemical structure of sarafloxacin hydrochloride is 6-Fluoro-1-(4-fluorophenyl)-4-oxo-7-piperazin-1-ylquinoline-3-carboxylic acid hydrochloride. *In vitro* activities of sarafloxacin against avian *E. coli* and other infections were studied previously (Soussy *et al.*, 1987, Jones and Erwin, 1998, Medders *et al.*, 1998, Wang *et al.*, 2001 and Smith *et al.*, 2007) and the drug proved its efficacy in comparison with other fluoroquinolones. Sarafloxacin had been proposed successfully for the use in the drinking water of chickens to treat bacterial infections caused by *E. coli* (McCabe *et al.*, 1993, Charleston *et al.*, 1998, Medders *et al.*, 1998, Hofacre *et al.*, 2000 and Chansiripornchai and Sasipreeyajan, 2002), *Salmonella spp* (Jiang *et al.*, 2000 and Roy *et al.*, 2002) and *Campylobacter jejuni* (McDermott *et al.*, 2002) and to prevent spiking mortality in turkeys (Vukina *et al.*, 1998).

The pharmacokinetics of sarafloxacin in broiler chickens following single-dose applications was determined (Ding *et al.*, 2000, 2001) and the results indicated that sarafloxacin was rapidly absorbed, extensively distributed, and quickly eliminated in broilers. Moreover, a dosage of 10 mg/kg administered orally every 8 hours in broilers could maintain effective plasma concentrations with bacteria infections. Also, Zhang *et al.* (2011) measured the inhibitory effects of sarafloxacin in comparison with enrofloxacin and marbofloxacin on the enzyme activity, protein levels and mRNA expression of liver cytochrome P450 (CYP) 1A and 3A in broilers and the results revealed that sarafloxacin didn't inhibit CYP in chick liver raising the possibility of drugs interaction when using those compounds.

Sarafloxacin tissue residues in different tissues and eggs of birds were comprehensively examined by Maxwell *et al.* (1999), Chu *et al.* (2000), Posyniak *et al.* (2001), Barrón *et al.* (2002), Schneider and Donoghue (2002), Christodoulou *et al.* (2007), Durden and MacPherson (2007), Herranz *et al.* (2007), Zhao *et al.* (2007), Guo *et al.* (2009), Lin (2009), Rodríguez Cáceres *et al.* (2009), Zhao *et al.* (2009), Anadón *et al.* (2010), Cho *et al.* (2010), Pena *et al.* (2010) and Rodríguez Cáceres *et al.* (2010) and all of them proved that sarafloxacin has very low tissue and egg residual effect indicating its safety which will directly reflect on the health hazard of human.

So, the objective of this study was to evaluate the efficacy of using sarafloxacin in the drinking water of broiler chickens for the treatment of experimental *E. coli* infection.

2. Material and Methods

Experimental birds:

One hundred and seventy, day old Hubbard broiler chicks of mixed sex were taken from a commercial hatchery. The birds were kept in separately thoroughly cleaned and disinfected houses and provided with feed and water ad libitum during the course of the experiment. All the birds received vaccination against Newcastle disease (ND) using Hitchner B1 and La Sota vaccines and against infectious bursal disease (IBD) using D78 vaccine at 6, 20 and 14 days of age; respectively through eye-drop instillation method. Also avian Influenza (H5N2) vaccine was given to the birds at 7 days old via intramuscular route. At day old, twenty random birds were collected and the internal organs (yolk sac, liver and heart) were cultured to certain absence of *E. coli* infection in experimental chicks.

The challenge inoculum:

The strain of *E. coli* that used for experimental challenge of the birds was serotype O78 and it was obtained kindly from Microbiology Department, Faculty of Veterinary Medicine, Cairo University. That serotype was isolated from a farm with an outbreak of avian colisepticaemia. The challenge inoculum was prepared according to the method of Quinn *et al.* (1994). At 2 weeks old, each chicken in the infected groups was intramuscularly (I/M) inoculated with 0.5 ml of the nutrient broth culture containing 10^8 colony forming unit (CFU) *E. coli*/ ml (Fernandez *et al.*, 2002).

Sarafloxacin treatment:

Sarafloxacin hydrochloride (white to light yellow crystalline powder) was obtained from Vetchem Biochemistry Science (batch number, 91296-87-6). Sarafloxacin was dissolved in the drinking water to prepare sarafloxacin 10% solution (according company's recommendation) at the dose level of 5 mg/kg live body weight for 3 days. Prior treatment, the daily water consumption of birds was monitored for 24 hours. The daily drug dose was administered continuously (continuous dosing regimen) during 24 hours period in an amount of water that was consumed in the same period. Identical dosing regimen was repeated during two subsequent days for a total of 3 consecutive days. Daily fresh drug solution was mixed with drinking water and replaced at the same time each day. Just before treatment, all birds in the treated groups were weighed to calculate the required daily amount of sarafloxacin (5 mg/kg body weight).

In vitro antimicrobials sensitivity test:

To measure the sensitivity of the used *E. coli* strain to sarafloxacin, the antibiotic sensitivity test was done using disc diffusion method (Prasad *et al.*,

1997). Other fluoroquinolones like enrofloxacin, norfloxacin, ciprofloxacin and pefloxacin discs (Oxoid, UK) were used to compare their zones of inhibition with sarafloxacin. The diameters of inhibition zones were interoperated by referring to the table which represents the National Committee for Clinical Laboratory Standards (NCCLS sub-Committee's recommendation, 2001).

Experimental design:

One hundred and seventy, day old Hubbard broiler chicks of mixed sex were randomly divided into three equal groups, each consists of 50 birds. Twenty chicks at the day of arrival were sacrificed and the yolk sac, liver and heart were cultured to ensure absence of *E. coli* infection in them. Group (1) was *E. coli* challenged and not treated with sarafloxacin (control positive), group (2) was *E. coli* challenged and treated with sarafloxacin, while group (3) was neither *E. coli* challenged nor sarafloxacin treated (blank control). At 2 weeks old, each bird in the infected groups (1 and 2) were intramuscular (I/M) inoculated in the thigh muscles with 0.5 ml of the nutrient broth culture containing 10^8 colony forming unit (CFU) *E. coli* O78 / ml. Sarafloxacin treatment in the drinking water began 3 days after experimental infection (onset of signs appearance) and continued for 3 consecutive days in the treated groups (1 and 2). All the birds were kept under complete observation for 6 weeks (experimental period).

Drug evaluation parameters:

1- Performance:

Along the whole period of the experiment (6 weeks), randomly selected birds in each group were weighed each week. Also the feed consumption of each group was determined to calculate the feed conversion rate and consequently the European Production Efficiency Factor (EPEF) (Sainsbury, 1984).

2- Clinical signs and mortalities:

Four weeks after experimental infection, all the birds in the infected and treated groups were monitored daily for clinical signs and deaths of *E. coli* infection. Dead birds were subjected to post-mortem examination.

3- Post-mortem lesions:

Sacrificed chickens as well as dead birds at the 1st, 2nd, 3rd and 4th week post challenge were subjected to post-mortem examination to determine the lesion score. Serous membranes (air-sacs, pericardium and perihepatic capsule) were examined for lesions and the lesion score were scaled from 0 to

3 as the following criteria; 0= no lesions, 1= mild, 2= moderate and 3= severe (Nakamura *et al.*, 1985, 1992 and Fernandez *et al.*, 2002). The severity index of the lesions was calculated as Nakamura *et al.* (1990).

Lesions of colisepticemia were scored as follows; For air sacs, 0 indicated no lesions, 1 indicated cloudiness of air sacs, 2 indicated that air sac membranes were thickened, 3 indicated "meaty" appearance of membranes, with large accumulations of a cheesy exudate confined to one air sac, and 4 was the same as a score of 3 but with lesions in two or more air sacs. For the pericardial lesions, 0 indicated no visible lesions, 1 indicated excessive clear or cloudy fluid in the pericardium, and 2 indicated extensive fibrination in the pericardial cavity. For perihepatic lesions, 0 indicated no visible lesions, 1 indicated definite fibrination on the surface of the liver, and 2 indicated extensive fibrination, adhesions, liver swelling and necrosis.

Birds with severe lesions were characterized as having an air sac lesion score of 4 and pericarditis and perihepatitis scores of either 1 or 2.

4- Re-isolation of the challenge organism:

Swabs from the trachea, heart, liver and air-sacs were collected from sacrificed chickens at the 7, 14, 21 and 28 days following the beginning of the treatment regimens. The swabs were streaked onto MacConkey agar and then incubated at 37°C for 24 hours. Grown colonies were further identified biochemically and serologically according to Cruickshank *et al.* (1975).

5- Histopathological examination:

Specimens from the liver, heart and lungs of birds in each group at the end of the study were collected, fixed in 10% formal saline for 24 hours, washed in tap water then serial dilutions of alcohol (methyl, ethyl and absolute ethyl) were used for dehydration. Specimens were cleared in xylene and embedded in paraffin at 56 degree in hot air oven for 24 hours. Paraffin bees wax tissue blocks were prepared for sectioning at 4 microns by slide microtome. The obtained tissue sections were collected on glass slides, deparaffinized and stained by hematoxylin and eosin stains (Bancroft *et al.*, 1996) for histopathological examination through the electric light microscope.

Statistical analysis:

The data were analyzed using ANOVA test and the Least Significant Differences (LSD) test was also detected between different treatments groups as Snedecor and Corchran (1980).

3. Results and Discussion

Infection of broiler chickens with *E. coli* usually happens at 2-8 week old with colisepticaemia and high mortalities (Leitnes and Heller, 1992). Infection with *E. coli* could be controlled using antimicrobials but gens present on the bacterial plasmids usually encode resistance to these antibiotics. Also, these plasmids transfer from one bacterial population to another rendering drug resistance (Chansiripornchai *et al.*, 1995 and Chansiripornchai and Sasipreeyajan, 2002). Recently introducing third generations of fluoroquinolones (sarafloxacin) can overcome the problem of drug fastness.

Avian pathogenic *E. coli* is frequently found to be resistant to commonly used antibacterial agents such as ampicillin, amoxicillin, tetracyclines, sulphonamides + trimethoprim and flumequine. Also, resistance to enrofloxacin is commonly encountered (Vandemaele *et al.*, 2002).

The results of *in-vitro* antibiotic sensitivity test showed that the used *E. coli* challenge strain (O78) was sensitive to sarafloxacin than the other antibiotics discs (enrofloxacin, norfloxacin, ciprofloxacin and pefloxacin). Our result coincide with these recorded by Jones and Erwin (1998) who found that sarafloxacin was very active and comparable to ciprofloxacin and enrofloxacin for inhibiting 823 strains from a wide variety of *E. coli* species. The *in vitro* studies to determine the rates of mutation of avian isolates of *E. coli* following nalidixic acid, sarafloxacin, or enrofloxacin pressure was done by Medders *et al.* (1998) and detected that lower rate of mutation was seen after sarafloxacin pressure. Moreover, Smith *et al.* (2007) demonstrated high sensitivity of *E. coli* broiler chickens strain to sarafloxacin when compared with enrofloxacin, sulfonamides and oxytetracycline.

Data present in Table (1) represents the performance parameters (Average body weight, cumulative feed conversion and European Production Efficiency Factor) that were measured along the 6 weeks course of the experiment. The performance parameters were the best and were significantly ($P<0.05$) higher in birds that were non challenged or treated than those in challenged - non treated or challenged - treated groups. Sarafloxacin treated chickens showed higher significant ($P<0.05$) parameters than challenged - non treated group. Parallel results to this study was obtained by McCabe *et al.* (1993), Joong Kim (1995), Chansiripornchai and Sasipreeyajan (2002) and Zhenling *et al.* (2002) who detected significant increase in the average daily gain and feed conversion ratio with reduction in mortalities of broilers treated with sarafloxacin than those not received treatment after infection with *E. coli*

serogroup O78. The improvement of the performance of the medicated group may be indirectly related to the bactericidal effect sarafloxacin on *E. coli* and accordingly the enhancement in the bird's health conditions.

Non *E. coli* challenged and non sarafloxacin treated (blank control) group showed no signs. While *E. coli* challenged chickens revealed signs of depression, off food, difficult breathing a day after *E. coli* challenge and these signs were estimated as an incidence of 30-70%. Twenty four hours after treatment with sarafloxacin in the drinking water, the clinical signs were declined and showed continuous reduction at the next two days of treatment (treatment course). No clinical signs were observed 5 days after treatment with sarafloxacin. However, survived chickens in the challenged non treated group estimated incidence of signs between 25-45% a week post-challenge.

The results of mortality rate, post mortem lesions and the mean of macroscopic lesion score are tabulated in Table (2). Blank control (non challenged or treated) chickens showed no mortalities along the course of experiment. In *E. coli* challenged groups, mortalities started at the 3rd day post-challenge then gradually reduced by sarafloxacin treatment and completely disappear at the 7th day of treatment. Challenged birds with *E. coli* showed cumulative mortality rate of (38%) which were significantly ($P<0.05$) higher than birds in sarafloxacin treated group (10%). Sekizaki *et al.* (1989) and Frenandez *et al.* (2002) found that *E. coli* serotype (O78) is highly pathogenic for chickens and can induce mortalities within short time. The finding of this work is in agreement with these reported by McCabe *et al.* (1993) and Joong Kim (1995) on sarafloxacin treatment of *E. coli* infected chickens. Also, our results are constant with this published by Chansiripornchai and Sasipreeyajan (2002) who reported that sarafloxacin treatment of broiler chickens could significantly ($P<0.05$) reduced mortalities from 75% in *E. coli* infected birds to 27% in infected medicated ones.

Infected groups with *E. coli* (O78) showed lesions at the 3rd day post challenge including septicaemia and serous to fibrinous air-sacculitis, pericarditis and perihepatitis either in dead or sacrificed birds. Administration of sarafloxacin significantly ($P<0.05$) reduced the macroscopic lesion score in the medicated birds than non medicated infected ones. The mean macroscopic gross lesion score in different organs of *E. coli* infected birds were varied from 2-4, however, it was not exceed 1 in sarafloxacin treated chickens. The lesions were completely absent a week after sarafloxacin medication. No lesions were observed in non infected

and non treated group. The necropsy findings of this experiment are supported by these reported by Sasipreeyajan and Pakpinyo (1992) and Gross (1999) who observed lesions of fibrinopurulent air-sacculitis, pericarditis and perihepatitis after systemic inoculation of *E. coli* serogroup (O78) in chickens. Prabhavathi *et al.* (1986) gave sarafloxacin at 4 times the minimum inhibitory concentration to the mice and found that the highest efficacy against *E. coli* (99.9%) occur within 2 hours after giving the drug. In addition, similar lesions score in serous membranes of broiler chickens were observed by Chansiripornchai and Sasipreeyajan (2002) after infection with *E. coli* and medication with sarafloxacin.

Table (3) reveals the percentages of the re-isolation rate of *E. coli* (O78) from the trachea, heart, liver and air-sacs in different groups. No re-isolation of the organism was detected in non infected non medicated group. The re-isolation rate was significantly ($P < 0.05$) higher in *E. coli* infected group than sarafloxacin treated one. The organism couldn't be re-isolated after seven days of the treatment beginning. In the study of Chansiripornchai and Sasipreeyajan (2002), *E. coli* was re-isolated only from the liver in the rate of 60% in the infected birds while it was 14% (significantly $P < 0.05$ lower) in birds treated with sarafloxacin in the drinking water.

Regarding the results of performance, morbidities, mortalities, organs lesion scores and re-isolation of the organism that are used as criteria for evaluation of *E. coli* infection in birds in this work, Piercy and West (1976), Nakamura *et al.* (1992), Mognet *et al.* (1997) and Glisson *et al.* (2004) observed nearly similar results. On the other hand, Charleston *et al.* (1998) made a comparison of the efficacies of three fluoroquinolone antimicrobial agents, given as continuous or pulsed-water medication, against *E. coli* model of colisepticaemia in chickens and found that enrofloxacin was more efficacious than either danofloxacin or sarafloxacin for the treatment of colisepticemia in chickens by medication in drinking water. Similarly, danofloxacin appeared to be more effective than sarafloxacin in treating colisepticemia.

Unfortunately, the literatures concerning using of sarafloxacin to treated *E. coli* or other infections in poultry are scarcely, but all published data (McCabe *et al.*, 1993, Charleston *et al.*, 1998, Medders *et al.*, 1998, Hofacre *et al.*, 2000, Jiang *et al.*, 2000, Chansiripornchai and Sasipreeyajan, 2002 and Roy *et al.*, 2002) agreed that sarafloxacin is effective in reducing signs, mortalities, lesions and the organism shedding as well as improving the performance.

Improving the health status of the birds caused by sarafloxacin treatment may be related to several

aspects such its bactericidal broad spectrum effect as a result of inhibiting the structure and function of DNA gyrase, a bacterial topoisomerase II which is an essential enzyme for DNA replication and transcription (Martinez *et al.*, 2006), good result of sarafloxacin antibiogram *in vitro* (Wang *et al.*, 2001 and Smith *et al.*, 2007) and sarafloxacin rapid absorption, extensive distribution, quick elimination and effective maintenance of plasma concentrations with bacterial infections (Ding *et al.*, 2001).

The histopathological alterations in the liver, heart and lungs in non *E. coli* infected, infected as well as sarafloxacin treated groups are seen in Table (4) and Figures (1-9). Non infected or treated group showed no histopathological alterations with normal histological structure of the central veins, sinusoids and surrounding hepatocytes of the liver (Figure 1), there were no microscopical alterations in the lungs lobules (Figure 2) and also no changes were recorded in the pericardium and myocardium (Figure 3). Nevertheless, *E. coli* infected bird's revealed severe microscopic lesions as there were congestion and dilatation in the portal veins and sinusoids associated with inflammatory cells infiltration in the portal area as well as focal aggregation in circumscribed manner in the hepatic parenchyma (Figure 4), the lining epithelial cells of the lungs bronchiols showed hyperplastic activation with polyps formation while the underlying lamina propria had focal circumscribed round aggregation of lymphoid cells with oedema and congested blood capillaries (Figure 5), fibrinonecrotic reaction with inflammatory cells infiltration, oedema and dilated blood capillaries were also detected in the pericardium while the myocardium showed leucocytes inflammatory cells infiltration (Figure 6). Sarafloxacin treatment alleviated the severity of lesions where the liver showed dilatation in the portal vein and sinusoids associated with few inflammatory cells infiltration in the portal area (Figure 7), congestion in the blood vessels and capillaries of the lungs lobules was detected (Figure 8) as well as oedema in the myocardium with congestion in the blood vessels were detected (Figure 9).

These observations were similar to those detected by Nakamura *et al.* (1985, 1992), Kutkat *et al.* (2002) and Sahar and El-shazly (2002) who observed that (O78) serotype of *E. coli* induced perihepatitis, vascular degeneration of the hepatocytes as well as mononuclear leucocytes inflammatory cells infiltration and dilatation of the portal veins. Also, they found severe pericarditis and myocardial heterophilic cells infiltration.

From the above mentioned results in this study, it could be concluded that sarafloxacin (3rd generation of fluoroquinolones) when used in a dose of

5 mg/kg body weight in the drinking water for 3 consecutive days is very effective in controlling of colisepticaemia in broiler chickens.

Table (1): The average body weight, cumulative feed conversion and EPEF in sarafloxacin treated and *E. coli* challenged and non challenged groups of broiler chickens

Group	Average body weight/gm						CFC	EPEF
	Age/week							
	Before <i>E. coli</i> challenge			After <i>E. coli</i> challenge				
	1	2	3	4	5	6		
Challenged-not treated	120.21±5.44 ^a	290.30±8.76 ^a	478.20±22.1 ^b	705.41±24.84 ^b	810.30±35.72 ^b	1456.12±13.15 ^b	2.40	145.22
Challenged-treated	125.29±2.99 ^a	300.51±8.31 ^a	610.30±10.12 ^c	804.66±25.20 ^c	1256.30±60.31 ^c	1741.21±21.56 ^c	1.89	198.41
Not challenged-not treated	129.40±2.00 ^a	315.90±8.78 ^a	623.4±15.61 ^a	810.70±22.9 ^a	1297.19±55.70 ^a	1808.15±31.50 ^a	1.78	203.09
LSD	18.65	30.10	28.29	70.51	121.92	132.65		

CFC= Cumulative feed conversion EPEF= European Production Efficiency Factor.

The higher the value, the better the performance LSD= Least significant difference as determined by Fisher's protected LSD procedures.

Means within the column with no superscripts are significantly different (P<0.05).

Table (2): The mortality rate and the mean gross lesion score in sarafloxacin treated and *E. coli* challenged and non challenged groups of broiler chickens

Groups	Examined birds		Cumulative mortality rate	Mean gross lesion score		
	Sacrificed	Dead		Pericarditis	perihepatitis	Airsacculitis
Challenged-not treated	10	19	19/50 (38%)	2.42±0.21 ^a	2.33±0.19 ^a	2.67±0.15 ^a
Challenged-treated	10	5	5/50 (10%)	0.18±0.32 ^c	0.16±0.54 ^c	0.20±0.11 ^c
Not challenged-not treated	10	0	0/50 (0.0%)	0	0	0
L.S.D				1.51	1.43	1.17

Values within a column represent means ± SEM.

L.S.D: least significant difference.

Values in a column not sharing a common letter are significantly (P<0.05) different.

Table (3): Re-isolation rate of *E. coli* (O78) in sarafloxacin treated and *E. coli* challenged and non challenged groups of broiler chickens

Groups	Examined birds	Re-isolation rate of <i>E. coli</i> (O78) from different organs			
		Trachea	Heart	Liver	Air-sacs
Challenged-not treated	10	5/10 (50%) ^b	7/10 (70%) ^b	6/10 (60%) ^b	8/10(80%) ^b
Challenged-treated	10	1/10 (10%) ^a	0/10 (0%) ^a	2/10 (20%) ^a	1/10 (10%) ^a
Not challenged-not treated	10	0/10 (0.00%) ^a	0/10 (0.00%) ^a	0/10 (0.00%) ^a	0/10(0.00%) ^a

Values in a column not sharing a common letter are significantly (P<0.05) different.

Table (4): The severity of reactions in different tissues according to histopathological alterations in sarafloxacin treated and *E. coli* challenged and non challenged groups of broiler chickens

Organ	Lesion	Groups		
		Challenged-not treated	Challenged-treated	Not challenged-not treated
Liver	Congestion of portal veins and sinusoids	+++	++	—
	Inflammatory cells infiltration in portal area	++	+	—
	Focal circumscribed inflammatory cells aggregation in parynchyma	+++	—	—
Lungs	Hyperplasia with polyps in the lining epithelium	++	—	—
	Peribronchiolar focal leucocytic inflammatory cells aggregation	+++	—	—
	Oedema in the peribronchiolar tissues	++	—	—
	Congestion and dilation of peribronchiolar blood capillaries	++	—	—
Heart	Fibrino necrotic reaction with oedema and inflammatory cells in the pericardium	++++	—	—
	Inflammatory cells infiltration in the myocordium	++++	—	—
	Dilated and congested blood vessels in myocardium	++	+	—
	Oedema in myocardium	++	+	—

++++= Very severe +++= Severe ++= Moderate += Mild = Nil

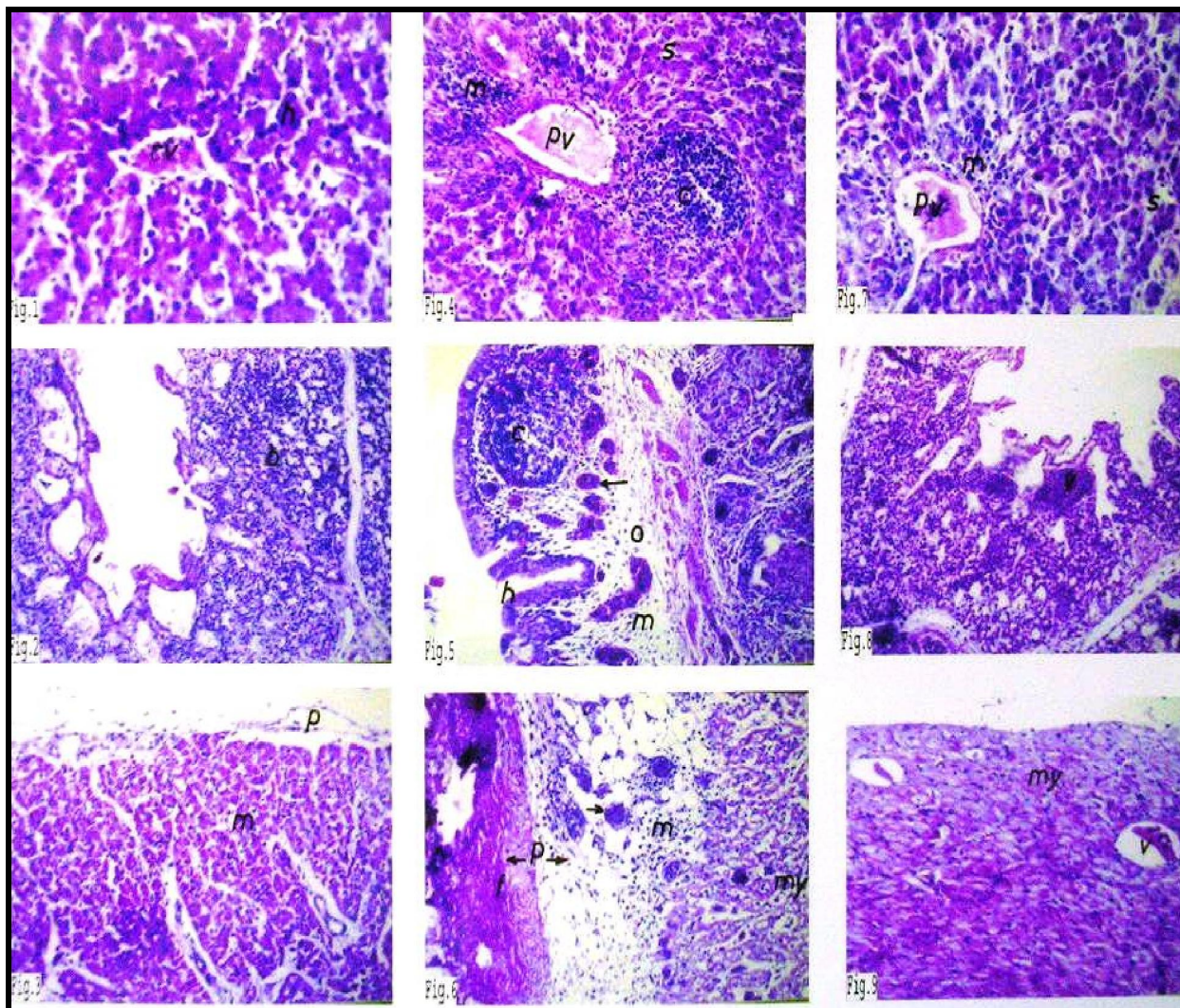


Fig. (1). The liver of non *E. coli* infected or treated group showing normal histological structure of the hepatic cells (h), central veins (cv) and sinusoids (s). H & E (X 80).

Fig. (2). The lungs of non *E. coli* infected or treated group showing normal histological structure of the lobules (b). H & E (X 40).

Fig. (3). The heart of non *E. coli* infected or treated group showing normal histological structure of the pericardium (p) and myocardium (m). H & E (X 64).

Fig. (4). The liver of *E. coli* infected group showing congestion and dilatation of portal vein (pv) and sinusoids (s) with inflammatory cells infiltration in the portal area (m) and focal aggregation in circumscribed manner of hepatic parenchyma (c). H & E (X 64).

Fig. (5). The lungs of *E. coli* infected group showing hyperplasia with polyps formation in the bronchiolar lining epithelium (h) with peribronchiolar focal leucocytic inflammatory cells aggregation (c), oedema (o) and dilated capillaries (arrow). H & E (X 40).

Fig. (6). The heart of *E. coli* infected group showing fibrinonecrotic reaction (f) with oedema (o), inflammatory cells infiltration (m) and dilated blood capillaries (m) in the pericardium (p) as well as inflammatory cells infiltration in myocardium (my). H & E (X 64).

Fig. (7). The liver of sarafloxacin treated and *E. coli* infected group showing dilated portal veins (pv) and sinusoids (s) with few inflammatory cells infiltration (m) in portal area. H & E (X 80).

Fig. (8). The lungs of sarafloxacin treated and *E. coli* infected group showing congestion of the blood vessels of the lobules (v). H & E (X 40).

Fig. (9). The heart of sarafloxacin treated and *E. coli* infected group showing myocardial oedema (my) with dilatation and congestion in blood vessels (v). H & E (X 64).

Corresponding author

Wafaa A. Abd El-Ghany
Faculty Veterinary Medicine, Cairo University,
Cairo, Egypt
[*Wafaa.ghany@yahoo.com](mailto:Wafaa.ghany@yahoo.com)

References

- Alimehr, M., G. Sadeghi-Hashjin, S. A. Poorbakhsh and K. Nofoofi, (1999): Isolation, identification and *in vitro* susceptibility of avian *Escherichia coli* to selected fluoroquinolones. *Ach Razi Ins.*, 50: 77-82.
- Anadón, A., F. H. Suárez, M. A. Martínez, V. Castellano, M. Martínez, I. Ares, E. Ramos, F. Gamboa and M. R. Martínez-Larrañaga, (2010): Plasma disposition and tissue depletion of difloxacin and its metabolite sarafloxacin in the food producing animals, chickens for fattening. *Food Chem Toxicol.*, Nov. 23.
- Bancroft, J. D., A. Stevens and D. R. Turner, (1996): Theory and practice of histopathological techniques. 4th Ed., Churchill Livingstone, New York.
- Barnes, H. J., K. N. Lisa and J. P. Vaillancourt, (2008): Colibacillosis. Pages 691–737 in *Diseases of Poultry*. 12th ed. Y. M. Saif, H. J. Barnes, A. M. Fadly, J. R. Glisson, L. R. McDougald, L. K. Nolan, and D. E. Swayne, ed. Iowa State University Press, Ames.
- Barrón, D., E. Jiménez-Lozano, S. Bailac and J. Barbosa, (2002): Determination of difloxacin and sarafloxacin in chicken muscle using solid-phase extraction and capillary electrophoresis. *J Chromatogr B Analyt Technol Biomed Life Sci.*, 767 (2): 313-319.
- Bauditz, R. (1987): Results of clinical studies with Baytril in poultry. *Vet Med. Rev.*, 2: 130-136.
- Behr, K. P., M. Friederichs, K. H. Hinz, H. Lüders and O. Siegmann, (1988): Klinische Erfahrungen mit dem Chemotherapeutikum Enrofloxacin in Hühner- und Putenherden. *Tierärztl. Umschau*, 43: 507-515.
- Chansiripornchai, N. and J. Sasipreeyajan, (2002): Efficacy of sarafloxacin in broilers after experimental infection with *Escherichia coli*. *Vet Res Commun.*, 26: 255-262.
- Chansiripornchai, N., J. Sasipreeyajan and S. Pakpinyo, (1995): The *in vitro* antimicrobial sensitivity testing of *Escherichia coli* isolated from commercially reared chickens. *Thia J Vet Med.*, 25: 275-283.
- Charleston, B., J. J. Gate, I. A. Aitken, B. Stephan and R. Froyman, (1998): Comparison of the efficacies of three fluoroquinolone antimicrobial agents, given as continuous or pulsed-water medication, against *Escherichia coli* infection in chickens. *Antimicrob Agents Chemother.*, 42 (1): 83-87.
- Cho, H. J., H. Yi, S. M. Cho, D. G. Lee, K. Cho, A. M. Abd el-Aty, J. H. Shim, S. H. Lee, J. Y. Jeong and H. C. Shin, (2010): Single-step extraction followed by LC for determination of (fluoro) quinolone drug residues in muscle, eggs, and milk. *J Sep Sci.*, 33 (8):1034-1043.
- Christodoulou, E. A., V. F. Samanidou and I. N. Papadoyannis, (2007): Validation of an HPLC-UV method according to the European Union Decision 2002/657/EC for the simultaneous determination of 10 quinolones in chicken muscle and egg yolk. *J Chromatogr B Analyt Technol Biomed Life Sci.*, 859 (2): 246-255.
- Chu, P. S., D. J. Donoghue and B. Shaikh, (2000): Determination of total 14C residues of sarafloxacin in eggs of laying hens. *J Agric Food Chem.*, 48 (12): 6409-6411.
- Copeland, D. D., R. H. Schulz and J. N. Davidson, (1987): The efficacy and optimum dosage of Bay Vp 2674 for the control of *E. coli* infections in chicken. *Poult Sci.*, 66 (Suppl. 1): 85.
- Cruickshank, R., J. P. Duguid, B. P. Marmion and R. H. A. Swain, (1975): *Med. Microbiology Vol. II* 12th edn.
- Da Costa, P. M., A. Belo, J. Goncalves and F. Bernardo, (2009): Field trial evaluating changes in prevalence and patterns of antimicrobial resistance among *Escherichia coli* and *Enterococcus spp.* isolated from growing broilers medicated with enrofloxacin, apramycin and amoxicillin. *Vet Microbiol.*, 139: (3-4): 284-292.
- Dho-Moulin, M. and J. M. Fairbrother, (1999): Avian pathogenic *Escherichia coli* (APEC). *Vet Res.*, 30: 299-316.
- Ding, H. Z., Q. H. Fing, Z. L. Zeng and Z. L. Chen, (2000): Pharmacokinetic studies of sarafloxacin in chickens. *Chinese J Vet Sci.*, 20 (5): 493-496.
- Ding, H. Z., Z. L. Zeng, K. F. Fung, Z. L. Chen and G. L. Qiao, (2001): Pharmacokinetics of sarafloxacin in pigs and broilers following intravenous, intramuscular, and oral single-dose applications. *J Vet Pharmacol Ther.*, 24: 303-308.
- Durden, D. A. and T. MacPherson, (2007): Quantitation and validation of fluoroquinolones in eggs using liquid chromatography/tandem mass spectrometry. *J AOAC Int.*, 90 (2): 613-625.
- Fernandez, A., C. Lara, A. Loste and M. C. Marca, (2002): Efficacy of calcium fosfomycin for the treatment of experimental infection of broiler chickens with *Escherichia coli* O78:K80. *Vet Res Commun.*, 26: 427-436.

- Garmyn, A., A. Martel, R. Froyman, H. Nauwynck, L. Duchateau, F. Haesebrouck and F. Basmans, (2009): Effect of multiple- and single-day enrofloxacin medications against dual experimental infection with avian pneumovirus and *Escherichia coli* in turkeys. *Poult Sci.*, 88 (10): 2093-3000.
- Gautrais, B. and D. Copeland, (1997): Use of enrofloxacin in turkeys; a worldwide experience. Page 79 in Proc. 46th West Poult Dis Conf., Sacramento, CA.
- Geornaras, I., J. W. Hastings and A. Holy, (2001): Genotypic analysis of *Escherichia coli* strains from poultry carcasses and their susceptibilities to antimicrobial agents. *Appl Environ Microbiol.*, 67 (4): 1940-1944.
- Glisson, J. R. (1996): The efficacy of enrofloxacin (Baytril) for the treatment of colibacillosis in chickens and turkeys and fowl cholera in turkeys, p. 22. In Proceedings of the 45th Western Poultry Disease Conference.
- Glisson, J. R., C. L. Hofacre and G. F. Mathis, (2004): Comparative efficacy of enrofloxacin, oxytetracycline, and sulfadimethoxine for the control of morbidity and mortality caused by *Escherichia coli* in broiler chickens. *Avian Dis.*, 48: 658-662.
- Goodwin, M. A., J. Brown and L. M. Rowland, (1993): Disease prevention and control in broilers, p. 140-175. In M. Pattison (ed.), *The health of poultry*. Longman Scientific and Technical, Harlow, United Kingdom.
- Gross, W. B. (1999): Colibacillosis: In Calnek, B.W., C.W. Beard, W.M. Rie, and S.H. Yoder, Jr. (ed), *Diseases of Poultry*, 9th edn, (Iowa State University Press, Ames, IA), 138-144.
- Guo, W., Y. Liu and N. Liu, (2009): Simultaneous analysis of 7 fluoroquinolone residues in chicken muscle by ultra performance liquid chromatography-electrospray ionization tandem mass spectrometry. *Se Pu.*, 27 (4): 406-411.
- Hafez, H. M., J. Emele and H. Woernle, (1990): Turkey rhinotracheitis (TRT). Serological flock profiles and economic parameters and treatment trials using enrofloxacin (Baytril). *Tierärztl. Umschau*, 45:111-114.
- Herranz, S., M. C. Moreno-Bondi and M. D. Marazuela, (2007): Development of a new sample pretreatment procedure based on pressurized liquid extraction for the determination of fluoroquinolone residues in table eggs. *J Chromatogr A.*, 1140 (1-2): 63-70.
- Hofacre, C. L., A. R. de Cotret, J. J. Maurer, A. Garrity and S. G. Thayer, (2000): Presence of fluoroquinolone-resistant coliforms in poultry litter. *Avian Dis.*, 44 (4): 963-967.
- Hooper, D. C. (1998): Clinical applications of quinolones. *Biochem Biophys Acta.*, 1400: 45-61.
- Jakob, H. P., R. Morgenstern, P. Albicker and R. K. Hoop, (1998): Reasons for condemnation of slaughtered broilers from two large Swiss producers. *Schweiz Arch Tierheilkd.*, 140: 60-64.
- Jiang, Z. Q., L. Y. Fang, W. Zong, Y. P. Wang and X. Ye, (2000): Studies on acute toxicity and efficacy of sarafloxacin against experimental salmonellosis in chicks. *Acta Agri Zhejiangensis*, 12 (1): 38-41.
- Jones, R. N. and M. E. Erwin, (1998): *In vitro* susceptibility testing and quality control parameters for sarafloxacin (A-56620): a fluoroquinolone used for treatment and control of colibacillosis in poultry. *Quality Control Study Group. Diagn Microbiol Infect Dis.*, 32 (1): 55-64.
- Joong Kim, S. (1995): Efficacy of floxacillin for the control of poultry bacterial diseases. *Samji Vet.*, 10: 2-23.
- Kempf, I., F. Gesbert, M. Guittet, R. Froyman, J. Delaporte and G. Bennejean, (1995): Dose titration study of enrofloxacin (Baytril) against respiratory colibacillosis in Muscovy ducks. *Avian Dis.*, 39:480-488.
- Kutkat, M. A., S. Nagwa and A. Ebtehal, (2002): Effect of *Lactobacillus acidophilus* on controlling of *Clostridium perfringens* and *E. coli* infections in native breed chickens. *J Egypt Vet Med Associ.*, 62 (6): 89-101.
- Leitnes, G. and E. D. Heller, (1992): Colonization of *Escherichia coli* in young turkeys and chickens. *Avian Dis.*, 36: 211-220.
- Lin, B. (2009): Multi-residue determination of 11 quinolones in chicken muscle by high performance liquid chromatography with fluorescence detection. *Se Pu.*, 27 (2): 206-210.
- Marien, M., A. Decostere, L. Duchateau, K. Chiers, R. Froyman and H. Nauwynck, (2007): Efficacy of enrofloxacin, florfenicol and amoxicillin against *Ornithobacterium rhinotracheale* and *Escherichia coli* O2:K1 dual infection in turkeys following APV priming. *Vet Microbiol.*, 121: 94-104.
- Martinez, M., P. McDermott and R. Walker, (2006): Pharmacology of the fluoroquinolones: A perspective for the use in domestic animals. *Vet J.*, 172: 10-28.
- Maxwell, R. J., E. Cohen and D. J. Donoghue, (1999): Determination of sarafloxacin residues in fortified and incurred eggs using on-line microdialysis and HPLC/programmable fluorescence detection. *J Agric Food Chem.*, 47 (4): 1563-1570.

- McCabe, M. W., R. H. Rippel and R. E. Miller., (1993): Efficacy of sarafloxacin for the control of mortality associated with *E. coli* infections in broiler chickens and turkeys, p. 75. In Proceedings of the 42nd Western Poultry Disease Conference (Sacramento, California).
- McDermott, P. F., S. M. Bodeis, L. L. English, D. G. White, R. D. Walker, S. Zhao, S. Simjee and D. D. Wagner, (2002): Ciprofloxacin resistance in *Campylobacter jejuni* evolves rapidly in chickens treated with fluoroquinolones. *J Infect Dis.*, 185 (6): 837-40.
- Medders, W. M., R. E. Wooley, P. S. Gibbs, E. B. Shotts and J. Brown, (1998): Mutation rate of avian intestinal coliform bacteria when pressured with fluoroquinolones. *Avian Dis.*, 42: 146-53.
- Mognet, L., P. Bezille, J. Guyonnet and H. Karembe, (1997): comparaison de la flumequine à l'amoxicilline dans deux modes d'administration par voie orale, en traitement de la colibacillose du poulet: approche pharmacodynamique et clinique. *Revue Medicine Veterinaire*, 148: 793-804.
- Nakamura, K., N. Youasa, H. Abe and M. Narita, (1990): Effect of infectious bursal disease virus on infections produced by *Escherichia coli* of high and low virulence in chickens. *Avian Pathol.*, 19: 713-712.
- Nakamura, K., K. A. Cook, A. Frazier and M. Narita, (1992): *Escherichiacoli* multiplication and lesions in the respiratory tract of chickens inoculated with infectious bronchitis virus and / or *E. coli*. *Avian Pathol.*, 36: 881-890.
- Nakamura, K., M. Maeda, Y. Imada, T. Imada and K. Sato, (1985): Pathology of spontaneous colibacillosis in broiler flock. *Vet Pathol.*, 22: 592-597.
- National Committee for Clinical Laboratory Standards, (2001): Performance Standards for antimicrobial susceptibility testing- Eleventh information. Supplement M100-S11. NCCLS Villanova, PA, USA.
- Pena, A., L. J. Silva, A. Pereira, L. Meisel and C. M. Lino, (2010): Determination of fluoroquinolone residues in poultry muscle in Portugal. *Anal Bioanal Chem.*, 397 (6): 2615-2621.
- Piercy, D. W. T. and B. West, (1976): Experimental *Escherichia coli* infection in broiler chickens: course of the disease induced by inoculation via the air-sac route. *J Comp Pathol.*, 86: 203-210.
- Posyniak, A., J. Zmudzki and S. Semeniuk, (2001): Effects of the matrix and sample preparation on the determination of fluoroquinolone residues in animal tissues. *J Chromatogr A.*, 914 (1-2): 89-94.
- Prabhavathi, B. F., T. W. Danial, R. B. Robert, P. J. Kenneth, R. R. Nancy and S. Nathon, (1986): *In vitro* evaluation of A-56619 (Difloxacin) and A-4552: new aryl fluoroquinolones. *J Antimicrob Agent Chemotherap.*, 29: 70-77.
- Prasad, V., K. Krishnamurlthy and T. V. Janardhana Rao, (1997): *In vitro* antibiogram studies of *Escherichia coli* in chickens. *Indian Vet J.*, 74: 616-617.
- Quinn, P. J., M. E. Carte, B. Markeryo and G. R. Carter, (1994): *Clinical Vet Microbiol.* Year book-wolf publishing- Europe Limited.
- Rodríguez Cáceres, M. I., A. Guiberteau Cabanillas, D. Bohoyo Gil and M. A. Martínez Cañas, (2009): Quantification of danofloxacin and difloxacin in chicken tissues in the presence of sarafloxacin as interference. *J Agric Food Chem.*, 57 (17): 7627-7633.
- Rodríguez Cáceres, M. I., A. Guiberteau Cabanillas, T. Galeano Díaz and M. A. Martínez Cañas, (2010): Simultaneous determination of quinolones for veterinary use by high-performance liquid chromatography with electrochemical detection. *J Chromatogr B Analyt Technol Biomed Life Sci.*, 878 (3-4): 398-402.
- Roy, P., A. S. Dhillon, L. H. Lauerman, D. M. Schaberg, D. Bandli and S. Johnson, (2002): Results of Salmonella isolation from poultry products, poultry, poultry environment, and other characteristics. *Avian Dis.*, 46 (1): 17-24.
- Russell, S. M. (2003): The effect of airsacculitis on bird weights, uniformity, fecal contamination, processing errors, and populations of *Campylobacter* spp. and *Escherichia coli*. *Poult Sci.*, 82: 1326-1331.
- Sahar, A. and M. El-shazly, (2002): Effect of probiotic and prebiotic combination (Biomin IMBO and Biomin C-EX) on *E. coli* infection in broiler chickens. *J Egypt Vet Med Associ.*, 62 (6): 113-119.
- Sainsbury, D. (1984): Systems of management. Ch.9 P.102. In *Poultry Health and Management*. 2nd Ed. By Sainsbury. Granada Publishing LTD. 8 Grafton Street, London W1X3 LA.
- Sasipreeyajan, J. and S. Pakpinyo, (1992): The result of using enrofloxacin in broiler. *Thai J Vet Med.*, 22: 95-104.
- Schneider M. J. and D. J. Donoghue, (2002): Multiresidue analysis of fluoroquinolone antibiotics in chicken tissue using liquid chromatography-fluorescence-multiple mass spectrometry. *J Chromatogr B Analyt Technol Biomed Life Sci.*, 780 (1): 83-92.
- Scioli, C., S. Esposito, G. Anazilotti, A. Parone and C. Pennucci, (1983): Transferable drug resistance in *Escherichia coli* isolated from antibiotic fed chickens. *Poult Sci.*, 382-384.
- Sekizaki, T.; L. Nonomura and Y. Imada, (1989): Loss of virulence associated with plasmid curing

- of chickens pathogenic *Escherichia coli*. J Japanese Vet Sci., 51: 659-661.
- Smith, J. L., D. J. Drum, Y. Dai, J. M. Kim, S. Sanchez, J. J. Maurer, C. L. Hofacre and M. D. Lee, (2007): Impact of antimicrobial usage on antimicrobial resistance in commensal *Escherichia coli* strains colonizing broiler chickens. Appl Environ Microbiol., 73 (5): 1404-1414.
- Snedecor, G. W. and W. G. Cochran, (1980): Statistical Methods. 7th Ed., (Iowa State College Press, Ames, IA), 39-63.
- Soussy, C. J., L. Deforges, J. Le Van Thoi and J. Duval, (1987): *In vitro* antibacterial activity of 2 new quinolones: A 56619 (difloxacin) and A 56620. Comparison with pefloxacin, ofloxacin and ciprofloxacin. Pathol Biol., 35: 759-67.
- Sumano, L. H., C. L. Ocampo, G. W. Brumbaugh and R. E. Lizarrage, (1998): Effectiveness of two fluoroquinolones for the treatment of chronic respiratory disease outbreak in broilers. Br Poult Sci., 39 (1): 42-46.
- Tablante, N. L., P. Y. Brunet, E. M. Odor, M. Salem, J. M. Harter-Dennis and W. D. Hueston, (1999): Risk factors associated with early respiratory disease complex in broiler chickens. Avian Dis., 43 (3): 424-428.
- Ter Hune, T. N., P. W. Wages, W. S. Swafford and S. T. Tolling, (1991): Clinical evaluation of efficacy of danofloxacin treatment of *E. coli* airsacculitis, p. 270. In Proceedings of the 40th Western Poultry Disease Conference.
- Vandemaële, F., M. Vereecken, J. Derijcke and B. M. Goddeeris, (2002): Incidence and antibiotic resistance of pathogenic *Escherichia coli* among poultry in Belgium. Vet Rec., 151: 355-356.
- Vukina, T., H. J. Barnes, and M. N. Solakoglu, (1998): Intervention decision model to prevent spiking mortality of turkeys. Poult Sci., 77 (7): 950-955.
- Wang, C., M. Ewing and S. Y. Aarabi, (2001): *In vitro* susceptibility of avian mycoplasmas to enrofloxacin, sarafloxacin, tylosin, and oxytetracycline. Avian Dis., 45: 456-460.
- Wolfson, J. S. and D. C. Hooper, (1985): The fluoroquinolones: structures, mechanisms of action and resistance, and spectra of activity *in vitro*. Antimicrob Agents Chemother., 28: 581-586.
- Wray, C. M. and P. J. Carroll, (1993): *Escherichia coli* isolated from farm animals in England and Wales between 1986 and 1991. Vet Rec., 133.
- Wray, C., R. H. Davies and J. D. Corkish, (1996): Enterobacteriaceae, p. 9-43. In F. T. W. Jordan, and M. Pattison (ed.), Poultry diseases. W. B. Saunders, London, United Kingdom.
- Yogarathnam, V. (1995): Analysis of the causes of high rates of carcass rejection at a poultry processing plant. Vet Rec., 137: 215-217.
- Zhang, L. L., J. R. Zhang, K. Guo, H. Ji, Y. Zhang and S. X. Jiang, (2011): Effects of fluoroquinolones on CYP4501A and 3A in male broilers. Res Vet Sci., 90 (1): 99-105.
- Zhao, S., H. Jiang, X. Li, T. Mi, C. Li and J. Shen, (2007): Simultaneous determination of trace levels of 10 quinolones in swine, chicken, and shrimp muscle tissues using HPLC with programmable fluorescence detection. J Agric Food Chem., 55 (10): 3829-3834.
- Zhao, S., X. Li, Y. Ra, C. Li, H. Jiang, J. Li, Z. Qu, S. Zhang, F. He, Y. Wan, C. Feng, Z. Zheng and J. Shen, (2009): Developing and optimizing an immunoaffinity cleanup technique for determination of quinolones from chicken muscle. J Agri Food Chem., 57 (2): 365-371.
- Zhenling, Z., S. Yongxue, F. BingHu, C. Zhangliu, Z. Zi and B. Fang, (2002): Therapeutic efficacy of sarafloxacin against mixed infection of *Mycoplasma gallisepticum* and *Escherichia coli* in chickens. Chinese J Vet Med., 28: 17-19.