

A review of avian mycobacteriosis: An emerging bacterial disease of public health concern

Wafaa A. Abd El-Ghany 

Department of Poultry Diseases, Faculty of Veterinary Medicine, Cairo University, Giza, 12211, Egypt.

Corresponding author: Wafaa A. Abd El-Ghany, e-mail: wafaa.soliman@cu.edu.eg

Received: 04-04-2022, **Accepted:** 29-08-2022, **Published online:** 22-10-2022

doi: www.doi.org/10.14202/IJOH.2022.70-75 **How to cite this article:** Abd El-Ghany WA (2022) A review of avian mycobacteriosis: An emerging bacterial disease of public health concern, *Int. J. One Health*, 8(2): 70-75.

Abstract

Avian mycobacteriosis is a chronic debilitating disease of birds which poses a public health threat. In avian species, the disease is primarily caused by *Mycobacterium avium* subspecies *avium*. Nearly all bird species are susceptible to this infection, with older birds being more susceptible than younger ones. Ingestion of feed and water contaminated by the excreta of infected or chronic carrier birds is the main route of *Mycobacterium* infection and transmission; however, the respiratory route is also possible. Migratory wild or free-living birds play an important role in mycobacteriosis transmission, and affected birds show severe depletion, emaciation, anemia, diarrhea, and respiratory manifestations. The appearance of characteristic tuberculous nodules in the digestive system, especially in the intestine, liver, and spleen, is pathognomonic. Confirmation of *Mycobacterium* infection can be achieved through isolation on specifically selected media, direct smear for detection of characteristic acid-fast bacilli, and detection of the bacterium using molecular diagnostic methods. Serological and allergic tests can also be applied. Different species of *Mycobacterium*, especially *M. avium*, have public health significance and can be transmitted from birds to humans. Such zoonosis is especially dangerous in human immunocompromised patients. Authorities and governments have implemented strict and comprehensive eradication programs for avian mycobacteriosis. These biosecurity measures, including surveillance monitoring programs and antimicrobial susceptibility testing, are essential for the prevention and treatment of *Mycobacterium* infection in poultry production systems. This review was designed to focus on avian mycobacteriosis in birds and humans.

Keywords: birds, human, mycobacteria, zoonosis.

Introduction

Mycobacteriosis is a contagious chronic debilitating zoonotic disease of animals, birds, and immunocompromised humans [1]. Avian mycobacteriosis affects domestic, psittacine, captive exotic, and wild birds [2]. The disease is associated with serious economic losses, including increased condemnation rates during processing, decreased egg production, lower body weights, sudden deaths associated with high mortality rates, and losses of valuable endangered bird species [3]. The causative agents of infection belong to the genus *Mycobacterium* [4]. Members of *Mycobacterium avium* species contain four subspecies that are termed as the *M. avium* complex. This complex includes *M. avium* subsp. *avium*, *M. avium* subsp. *hominissuis* (serotypes 4–6, 8–11, and 21), *M. avium* subsp. *paratuberculosis*, and *M. avium* subsp. *silvaticum* [5]. All members of the *M. avium* complex, as well as *Mycobacterium genavense*, and *Mycobacterium intracellulare* (serotypes 7, 12–20, and 22–28) can infect an extensive range of mammals and exotic species.

Mycobacteriosis is a disease of great public health significance worldwide. Approximately 8.6 million cases of mycobacteriosis were recorded by the WHO in 2012 [6]. Most of the recorded cases were in Asia (58%) and Africa (27%). All members of *M. avium* complex and *M. genavense* are capable of inducing infection in humans, which is refractory to treatment, especially in immunocompromised individuals [5].

Accordingly, this review focuses on the bacterium causing mycobacteriosis in avian species, the susceptibility and infection, the clinical picture in birds, its zoonotic and public health importance, the diagnosis of infection, and prevention and control measures.

The Causative Agent

There are more than 35 mycobacterial species which can cause mycobacteriosis. The disease in avian species is mainly caused by *M. avium* subsp. *avium* serotypes 1, 2, and 3, and genotype *IS901* segment [7]. The most common *Mycobacterium* isolated species seen in psittacine birds are *M. avium*, *M. genavense*, and *Mycobacterium fortuitum* [8]. In addition, *Mycobacterium tuberculosis* has been reported in canaries and parrots [9], and although birds could be infected with *Mycobacterium bovis*, it would be only under experimental conditions. Ledwón *et al.* [10] found that experimental infection of budgerigars with *Mycobacterium* species induced signs in birds after 70 days of challenge with *M. bovis*, but no signs were

Copyright: Abd El-Ghany. This article is an open access article distributed under the terms of the Creative Commons Attribution 4.0 International License (<http://creativecommons.org/licenses/by/4.0/>), which permits unrestricted use, distribution, and reproduction in any medium, provided you give appropriate credit to the original author(s) and the source, provide a link to the Creative Commons license, and indicate if changes were made. The Creative Commons Public Domain Dedication waiver (<http://creativecommons.org/publicdomain/zero/1.0/>) applies to the data made available in this article, unless otherwise stated.

observed among other species. Experimental infections with *M. avium* subsp. *paratuberculosis* in poultry have been investigated with successful results [11], but there is no evidence that this bacterium is involved in the etiology of avian mycoplasmosis. The disease may also be caused by other members of *M. avium* complex, including *M. avium* subsp. *hominissuis*, *M. intracellulare*, *Mycobacterium scrofulaceum*, *M. fortuitum*, and other potentially pathogenic mycobacterial species [12].

Mycobacteria are Gram-positive, non-motile, non-sporulated, and aerobic acid-fast bacilli. The pathogen is able to resist harsh environments (low oxygen, high temperature, dryness, and low pH) and commonly used disinfectants [13]. *Mycobacteria* species can survive in soil for more than 4 years, in 3% hydrochloric acid for more than 2 h, and in 2% sodium hydroxide for more than 30 min [14]. In addition, *M. avium* has been shown to remain viable in carcasses buried 1 m deep for 27 months, and to survive in sawdust for 168 days at 20°C and 244 days at 37°C. However, the bacterium is inactivated after boiling of eggs for more than 6 min [13].

The bacterium is characterized by its intracellular opportunistic nature, which enables its strong resistance against host immune system responses, especially macrophages [15]. The presence of a thick and complex cell wall with high lipid content may be responsible for its intrinsic multidrug resistance and virulence [16].

Susceptibility and Infection

All avian species, including galliformes, columbiformes, waterfowls, psittacines, passerines, raptors, and ratites, could potentially be infected with *M. avium* under favorable conditions [12].

The incidence of mycobacteriosis in companion psittacine birds has been estimated at 0.5–14% through post-mortem examination surveys [17]. Sparrows, pheasants, partridges, and wild birds in captivity are also susceptible to this infection.

Among gallinaceous domestic poultry, *M. avium* has been detected in the droppings of chickens in Bangladesh with a prevalence rate of 3.75% [18], while in Ethiopia, the pathogen was isolated in chickens at a rate of 4.26% [3]. In addition, *M. avium* has been found in turkeys in the Czech Republic [19]. Dvorska *et al.* [20] isolated *M. avium* with a prevalence rate of 11.1% among captive waterfowl, and *M. avium* infection has also been reported in common pheasants kept in captivity [21] and in racing pigeons [22]. Infection in ratites, such as emus, with mycobacteriosis has also been documented [23]. Adult birds older than 1 year are more susceptible to mycobacteriosis than younger birds. However, cases of avian mycobacteriosis have also been reported in very young birds [24].

Infected birds and contaminated water and soil are the primary sources of mycobacteriosis, since the pathogen can survive for a long time in the

environment. It has been found that contaminated droppings contain tubercle bacilli from liver or gall bladder lesions of infected birds. The ability of the mycobacteria species to persist in the environment for several years, especially in soil and litter, facilitates the transmission of the infection [20].

Oral infection is the primary route of mycobacteria affection in birds. However, the extensive affection of the respiratory system in some cases suggests an airborne infection. Thus, ingestion of contaminated feed and water, and inhalation of contaminated droplets from infected or carrier birds are believed to be the primary routes of *M. avium* infection [25]. In addition, skin abrasions around the eyes may be considered an infection route [23]. Regarding egg-borne infection, *M. avium* has been found in eggs of naturally infected chickens, but hatched chicks have failed to develop the disease.

Recovered chronic carriers and wild birds usually serve as major reservoirs and shedders of *M. avium*, thus exposing other birds, animals, humans, and the surrounding environment to the bacterium and facilitating its spread for years [12]. Rearing birds in free-range systems and retaining breeders for several years are also possible contributors to infection spread. Moreover, maintaining older flocks or multi-aged populations without adequate cleaning and hygiene, especially in overcrowded conditions, leads to persistent mycobacterial infection and human exposure. The infection may also be transmitted via contaminated shoes and equipment, as well as through cannibalism.

Clinical Picture in Birds

The clinical signs of avian mycobacteriosis in poultry can be non-specific or pathognomonic [26]. The disease is usually chronic, persistent, and wasting. These may be prolonged for several weeks or months before death. Mycobacterial infection in birds is mostly enteric and differs from respiratory forms which are commonly described among mammals. Therefore, the disease first involves the gastrointestinal tract and liver, with a subsequent spread to other organs [13]. Mycobacteriosis shows three periods of infection: a latent period, a lesion development period, and a cachexia period [26]. The latent period during the first 7 days of infection shows no lesions, but hypersensitivity reaction tests reveal positive results. The lesion development period occurs from day 8 to 17 post-infection, in which the bacilli multiply in lymphoid tissues, the thymus glands show atrophy, small tubercles with few bacilli are developed, and serum antibody titers develop. The cachexia period lasts from day 18 until death.

Once the mycobacterial infection has been established, infected birds show depression, ruffled feathers, unthriftiness, fatigue, loss of weight, whitish mucoid diarrhea, dyspnea, swelling of the eyelids, conjunctivitis, and decreased egg production.

Advanced and progressive cases show weakness and lethargy, anemia, pale comb and wattle, maintained appetite, severe emaciation with loss of pectoral muscles, a prominent keel bone, unilateral lameness, walking with a peculiar jerky hopping gait, paralysis, ocular affections, and finally death [23]. Death may occur in a few months in some cases, while in other cases, sudden death, despite good body condition, may occur due to the rupture of the liver or the spleen with internal hemorrhaging [26].

Typical lesions of mycobacteriosis are present primarily in the gastrointestinal tracts of birds and are also found in their other organ systems [12]. The lesions vary among species and may be tuberculous or non-tuberculous. Three forms of mycobacteriosis have been described in avian species. These include classic tuberculosis in most organs, the intestinal form, and the non-tuberculous form which is almost macroscopically unrecognizable [26]. Deep intestinal ulcers filled with caseous material have also been observed. Later, ulcers appear as tumor-like nodules attached to the gut wall. Tuberculous nodules are present on the intestines, liver, and spleen, and may spread to all internal organs. The characteristic tuberculous nodules range in size from irregular pinpoint to several centimeters across, and are grayish-yellow or grayish-white in color. The spleen eventually assumes an irregular “knobby” appearance due to the presence of multiple irregular nodules. Hepatomegaly, and sometimes liver rupture, which can cause internal hemorrhaging, have been observed, and intestinal nodules can often be palpated externally. Furthermore, tuberculous lesions can extend to the joints, causing arthritis and even paralysis. Finally, pulmonary tuberculous lesions have been seen in pigeons and waterfowl [27], and are infrequently detected in the ovaries, testes, heart, skin, conjunctiva, and bone marrow [28].

Zoonosis and Public Health Significance

Avian mycobacteriosis is a potential zoonotic disease, especially among immuno-suppressed individuals who are in contact with infected birds [17]. It is classified as a List B disease of the World Organization for Animal Health (OIE) with a public health threat. The disease is considered an important veterinary and economic threat to birds. Infected, recovered carriers, and untreated birds, could all be potential reservoirs resulting in zoonosis. In addition, humans can get mycobacteriosis through the consumption of insufficiently cooked meat of infected birds [21]. Figure-1 shows the different routes of human infection with avian mycobacteriosis.

The primary mycobacterial species that infects humans is *M. tuberculosis*. Birds, especially psittacines, may acquire mycobacteriosis through contact with infected owners. In New York City and Switzerland, green-winged macaws have been observed to develop osteomyelitis, multifocal granulomatous panniculitis, and granulomatous hepatitis,

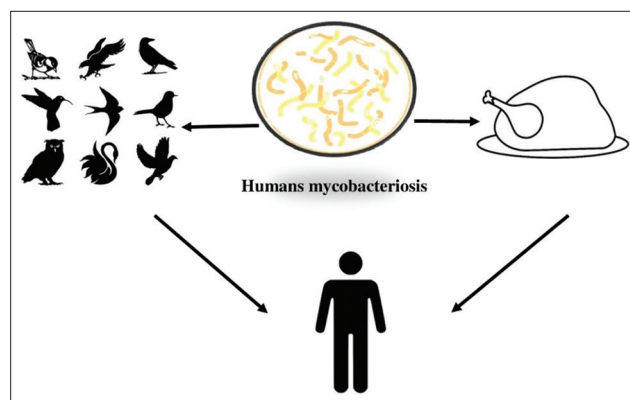


Figure-1: Different routes of human infection with avian mycobacteriosis [Source: Figure prepared by the author].

and have been confirmed as positive for *M. tuberculosis* [9]. Bird owners in both cases confirmed positive pulmonary tuberculosis. In addition, two veterinarians in Switzerland revealed positive tuberculin skin test after handling diseased birds [12]. However, *M. avium* is the second most common cause of pulmonary infection in humans, as serotype 1 has been isolated from patients with endobronchial lesions [29]. Furthermore, *M. avium* serovars 1, 4, and 8 have been isolated from patients with immune deficiency syndrome acquired immunodeficiency syndrome (AIDS), while serovars 4, 8, 9, 16, and 19 have been isolated from non-AIDS patients in the United States [30]. Mycobacteriosis caused by *M. avium* in humans is a progressive disease which is characterized by pulmonary disease, localized lymphadenitis, and a disseminated form of infection [31].

Diagnosis of Infection

Routine diagnoses and epidemiological surveys of avian mycobacteriosis are challenging to perform due to the absence of a specific clinical picture, the chronic nature of the infection, the intracellular nature of the organism, and the difficulty of utilizing inexpensive, highly sensitive diagnostic techniques [32]. Despite these challenges, diagnosis is based primarily on culture as the gold-standard technique [33], microscopic examination of acid-fast bacilli using Ziehl-Neelsen stain, and the molecular detection of genes *IS6110*, *IS901*, and *IS1245* using polymerase chain reaction (PCR) techniques as confirmatory diagnosis [34, 35]. These techniques are considered the most specific and sensitive laboratory tests for a definitive diagnosis of mycobacteriosis [4].

Mycobacterium grows on selective media such as Lowenstein–Jensen, Herrold’s, Middlebrook 7H10 and 7H11, or Coletso’s medium supplemented by 1% sodium pyruvate. Typically, smooth colonies can be produced within 2–4 weeks, but conventional biochemical tests are time-consuming and may not always distinguish between different species. Therefore, a miscellaneous group of mycobacteria is usually classified as *M. avium* complex.

The tuberculin test is a rapid field hypersensitivity-allergic test for determining the presence of mycobacteriosis in fowl [33]. The technique involves intradermal inoculation of one wattle site with 0.05–0.1 mL of a purified tuberculin protein derivative prepared from *M. avium*, while the other wattle is kept as a non-inoculated control site. The inoculated site should be observed within 24 h for a swelling reaction. However, this test is not suitable for all bird species, such as waterfowl. In addition, it may show false-negative results twice during the course of an infection, once during the early infection, and again during the late infection. These results are usually seen after the exhaustion of the bird's immune system. It is noteworthy that tuberculin testing is unreliable in some avian species.

The whole-blood stained-antigen agglutination test could be used for a rapid diagnosis of *M. avium* in all species of birds. However, the potential of false-positive reactions is a drawback. Serologic identification testing, such as hemagglutination inhibition, complement fixation, enzyme-linked immunosorbent assay (ELISA) with monoclonal antibodies, and high-performance liquid chromatography, has all been used to confirm diagnoses [33]. However, these techniques are each unique, and are species-specific and not available for all avian species. Sero-agglutination is useful in that it allows for the classification of *M. avium* complex organisms into 28 serovars [36]. Baghal *et al.* [37] considered the ELISA test as not sensitive but highly specific and used it to detect antibodies in experiments using *M. avium* serovar 2 challenged chickens which showed false-positives reactions. Serovars 1–6, 8–11, and 21 have been identified with *M. avium* subsp. *avium* and *M. avium* subsp. *hominissuis*, while serovars 7, 12–20, and 25 have been identified with *M. intracellulare*. Avian tuberculosis in birds is caused by *M. avium* subsp. *avium* serotypes 1, 2, or 3. If the isolated strain is not one of these three serotypes, further identification tests (e.g., *IS901* PCR) should be utilized.

Different species of *Mycobacterium* may be rapidly identified using nucleic acid hybridization probes. However, identification errors have been detected due to cross-reactivity [38]. Recently, molecular techniques, such as real-time PCR, have been developed to detect species belonging to the *M. avium* complex [39].

Prevention and Treatment

Complete eradication of mycobacterial infection is difficult because of the chronic carrier status and the intermittent shedding of bacteria by infected birds. According to the recommendations of OIE [33], certain procedures should be applied to obtain mycobacteriosis-free flocks. These recommendations include replacing old equipment with new equipment, removal of litter and contaminated soil, thorough cleaning and disinfection, proper fencing to prevent the unrestricted movement of birds, elimination of old

flocks, burning of infected birds, and quarantining of newly introduced birds for 60 days followed by retesting for avian tuberculin.

Mycobacteriosis is regarded as a serious problem for valuable endangered bird species, so these birds should be checked regularly. In addition, continuous surveillance programs and early diagnosis of mycobacteria should be performed in imported psittacine birds [40].

Members of the *M. avium* complex are classified in Risk Group 2 for human infection and should be handled appropriately [5]. Handling infected birds on farms, and live cultures of *M. avium* in laboratories, should be accomplished with adequate care. Infected birds should be kept away from humans, particularly the elderly and especially immunocompromised individuals [41].

Governments, especially in developing countries, should prohibit the slaughtering of birds in homes and encourage the use of authorized or licensed abattoirs [42]. In addition, attention should be given to awareness creation programs targeted at poultry producers and consumers regarding the predisposing factors of avian mycobacteriosis in both birds and humans [42].

Treatment of infected birds with mycobacteriosis is controversial and difficult due to weak responses from the host. Moreover, treatment is considered expensive and may take up to 12–18 months [43]. Difficulties associated with the treatment are related to the continuous development of resistance among the *M. avium* complex to various antimicrobials. Multidrug resistance in mycobacteria species is defined as the resistance to isoniazid and rifampicin, at a minimum [33]. This resistance may be due to some intrinsic factors, such as the complicated lipoid cell wall structure, presence of mycolic acid, development of specific antibiotic resistance genes, and gene mutations [16, 44, 45]. Some important genes present in *M. avium*, such as *rpoB*, *otrB*, *rpsL*, and *inhA* have shown mutations that encoded for multiple drug resistance. For instance, resistance to streptomycin is attributed to a mutation in the *rpsL* gene encoding a ribosomal protein (16S rRNA) [46]. In Egypt, emerging multidrug-resistant *M. avium* in both apparently healthy and diseased domestic house-reared chicken, ducks, and geese has been shown to have mutations of the *IS901*, *inhA*, *rpoB*, *rpsL*, and *otrB* genes [35]. Treatment protocols for psittacine birds are based on those used in humans [17]. At present, azithromycin is the most effective antibiotic used in the treatment of avian mycobacteriosis [47]. Recently, azithromycin combined with clofazimine showed a strong *in vitro* antibacterial activity against *M. avium* [35, 48].

There is no currently available vaccine for mycobacteriosis in birds. Vaccination of chickens with fractions of *M. avium* reduced the severity of liver lesions and decreased the number of bacilli but did not prevent the infection after homologous strain challenge [49].

However, oral vaccination of chickens with live *M. intracellulare* serovar 6 (*M. avium* serovar 6) and the combination of intramuscular vaccination with inactivated plus live *M. intracellulare* serovar 7 and serovar Darden (*M. avium* serovars 7 and 19) showed promising results [2, 34]. It is noteworthy that the human Bacille Calmette-Guérin vaccine was tested in poultry but resulted in little benefit.

Conclusion

Avian mycobacteriosis is considered a chronic and highly contagious zoonotic List B disease by the OIE. Although the disease induces chronic affection in avian species, these birds are also a potential source of infection among humans. Therefore, great attention is warranted toward this dangerous infection, both in veterinary and human medicine. More research of mycobacteriosis control methods in different avian species should be conducted, and the regular application of antibiotic sensitivity testing is necessary to detect the most effective drugs for managing the *Mycobacterium*. Finally, continuous monitoring and surveillance programs of poultry flocks are required to decrease the incidence of avian mycobacteriosis, and humans should be vigilant and careful during the handling of indicated bird species, especially psittacine species.

Authors' Contributions

WAA: Collected the literature, drafted and revised the manuscript, and approved the final manuscript.

Acknowledgments

The author is thankful to Faculty of Veterinary Medicine, Cairo University, Egypt, for providing the necessary facilities for this review. The author did not receive any funds for this study.

Competing Interests

The author declares that she has no competing interests.

Publisher's Note

Veterinary World (Publisher of International Journal of One Health) remains neutral with regard to jurisdictional claims in published institutional affiliation.

References

1. Thorel, M.F., Huchzermeyer, H. and Michel, A.L. (2001) *Mycobacterium avium* and *M. intracellulare* infection in mammals. *Rev. Sci. Tech.*, 20(1): 204–218.
2. Fulton, R.M. and Sanchez, S. (2018) Other bacterial diseases. In: Swayne, D.E., Boulianne, M., Logue, C.M., McDougald, L.R., Nair, V. and Suarez, D.L., editors. *Diseases of Poultry*. 14th ed. American Association of Avian Pathologists, Hoboken, NJ, USA. p1033–1043.
3. Kindu, A. and Getaneh, G. (2016) Prevalence of avian tuberculosis in domestic chickens in selected sites of Ethiopia. *J. Vet. Sci. Technol.*, 7(6): 377.
4. Dahlhausen, B., Tovar, D.S. and Saggese, M.D. (2012) Diagnosis of mycobacterial infections in the exotic pet patient with an emphasis on birds. *Vet. Clin. North Am. Exot. Anim. Pract.*, 15(1): 71–83.
5. World Organization for Animal Health. (2018) Manual of Diagnostic Tests and Vaccines for Terrestrial Animals. World Organization for Animal Health, Paris, France. Available from: <https://www.oie.int/standard-setting/terrestrial-manual/access-online> Retrieved on 18-07-2018.
6. World Organization for Animal Health. (2013) Global Tuberculosis Report. World Health Organization, Geneva, Switzerland.
7. Dhama, K., Mahendran, M. and Tomar, S. (2007) Avian tuberculosis: An overview. *Poult. Punch*, 24(3): 38–52.
8. Evans, E.E. (2011) Zoonotic diseases of common pet birds: Psittacine, passerine, and columbiform species. *Vet. Clin. North Am. Exot. Anim. Pract.*, 14(3): 457–476.
9. Steinmetz, H.W., Rutz, C., Hoop, R.K., Grest, P., Bley, C.R. and Hatt, J.M. (2006) Possible human avian transmission of *Mycobacterium tuberculosis* in a green-winged macaw (*Ara chloroptera*). *Avian Dis.*, 50(4): 641–645.
10. Ledwón, A., Szeleszczuk, P., Zwolska, Z., Augustynowicz-Kopeć, E., Sapieryński, R. and Kozak, M. (2008) Experimental infection of budgerigars (*Melopsittacus undulates*) with five *Mycobacterium* species. *Avian Pathol.*, 37(1): 59–64.
11. Larsen, A.B. and Moon, H.W. (1972) Experimental *Mycobacterium paratuberculosis* infection in chickens. *Am. J. Vet. Res.*, 33(6): 1231–1235.
12. Tell, L.A., Woods, L. and Cromie, R.L. (2001) Mycobacteriosis in birds. *Rev. Sci. Tech.*, 20(1): 180–203.
13. Dhama, K., Mahendran, M., Tiwari, R., Singh, S.D., Kumar, D., Singh, S. and Sawant, P.M. (2011) Tuberculosis in birds: Insights into the *Mycobacterium avium* infections. *Vet. Med. Int.*, 2011: 712369.
14. Coelho, A.C., de Lurdes Pinto, M., Matos, A., Matos, M. and dos Anjos Pires, M. (2013) *Mycobacterium avium* Complex in Domestic and Wild Animals. IntechOpen, London.
15. Rocco, J. and Irani, V. (2011) *Mycobacterium avium* and modulation of the host macrophage immune mechanisms. *Int. J. Tuberc. Lung Dis.*, 15(4): 447–452.
16. Gygli, S.M., Borrell, S., Trauner, A. and Gagneux, S. (2017) Antimicrobial resistance in *Mycobacterium tuberculosis*: Mechanistic and evolutionary perspectives. *FEMS Microbiol. Rev.*, 41(3): 354–373.
17. Lennox, A.M. (2007) Mycobacteriosis in companion psittacine birds: A review. *J. Avian Med. Surg.*, 21(3): 181–187.
18. Reza, M.R., Lijon, M.B., Khatun, M.M. and Islam, M.A. (2015) Prevalence and antibiogram profile of *Mycobacterium* spp. in poultry and its environments. *J. Adv. Vet. Anim. Res.*, 2(4): 458–463.
19. Shitaye, J., Matlova, L., Horvathova, A., Moravkova, M., Dvorska-Bartosova, L., Tremel, F., Lamka, J. and Pavlik, I. (2008) *Mycobacterium avium* subsp. *avium* distribution studied in a naturally infected hen flock and in the environment by culture, serotyping and IS901 RFLP methods. *Vet. Microbiol.*, 127(1–2): 155–164.
20. Dvorska, L., Matlova, L., Ayele, W.Y., Fischer, O.A., Amemori, T., Weston, R.T., Alvarez, J., Beran, V., Moravkova, M. and Pavlik, I. (2007) Avian tuberculosis in naturally infected captive water birds of the *Ardeidae* and *Treskiornithidae* families studied by serotyping, IS901 RFLP typing, and virulence for poultry. *Vet. Microbiol.*, 119(2–4): 366–374.
21. Moravkova, M., Lamka, J., Kriz, P. and Pavlik, I. (2011) The presence of *Mycobacterium avium* subsp. *avium* in common pheasants (*Phasianus colchicus*) living in captivity and in other birds, vertebrates, non-vertebrates and the environment. *Vet. Med. (Praha)*, 56(56): 333–343.
22. Tsiouris, V., Kiskinis, K., Mantzios, T., Dovas, C.I., Mavromati, N., Filiouis, G., Brellou, G., Vlemmas, I. and Georgopoulou, I. (2021) Avian mycobacteriosis and molecular identification of *Mycobacterium avium* subsp. *avium*

- in racing pigeons (*Columba livia domestica*) in Greece. *Animals*, 11(2): 291.
23. Pocknell, A.M., Miller, B.J., Neufeld, J.L. and Grahn, B.H. (1996) Conjunctival mycobacteriosis in two emus (*Dromaius novaehollandiae*). *Vet. Pathol.*, 33(3): 346–348.
 24. Manarolla, G., Liandris, E., Pisoni, G., Sasser, D., Grilli, G., Gallazzi, D., Sironi, G., Moroni, P., Piccinini, R. and Rampin, T. (2009) Avian mycobacteriosis in companion birds: 20-year survey. *Vet. Microbiol.*, 133(4): 323–327.
 25. Leite, C.Q.F., Souza, C.W. and Leite, S.R. (1998) Identification of mycobacteria by thin layer chromatographic analysis of mycolic acids and conventional biochemical method: Four years of experience. *Mem. Inst. Oswaldo Cruz.*, 93(6): 801–805.
 26. Bharti, A., Swamy, M., Dubey, A. and Marskole, P. (2018) Avian mycobacteriosis. *Int. J. Curr. Res.*, 10(5): 69722–69725.
 27. Marco, I., Domin, M. and Lavin, S. (2000) *Mycobacterium* infection in a captive-reared capercaillie (*Tetrao urogallus*). *Avian Dis.*, 44(1): 227–230.
 28. Huguenin, M.T.C. and Picoux, J.B. (2015) Bacterial diseases. In: Picoux, J.B., Vaillancourt, J.P., Bouzouaia, M., Shivaprasad, H.L., Venne, D., editors. *Manual of Poultry Diseases*. AFAS, Paris, France. p360–363.
 29. Slany, M., Ulmann, V. and Slana, I. (2016) Avian mycobacteriosis: Still an existing threat to humans. *Biomed. Res. Int.*, 2016: 4387461.
 30. Beamer, G.L., Flaherty, D.K., Assogba, B.D., Stromberg, P., Gonzalez-Juarrero, M., de Waal Malefyt, R., Vesosky, B. and Turner, J. (2008) Interleukin-10 promotes *Mycobacterium tuberculosis* disease progression in CBA/J mice. *J. Immunol.*, 181(8): 5545–5550.
 31. Shah, N.M., Davidson, J.A., Anderson, L.F., Lalor, M.K., Kim, J., Thomas, H.L., Lipman, M. and Abubakar, I. (2016) Pulmonary *Mycobacterium avium-intracellulare* is the main driver of the rise in non-tuberculous mycobacteria incidence in England, Wales and Northern Ireland. *BMC Infect. Dis.*, 16(1): 195.
 32. Boseret, G., Losson, B., Mainil, J.G., Thiry, E. and Saegerman, C. (2013) Zoonoses in pet birds: Review and perspectives. *Vet. Res.*, 44(1): 36.
 33. World Organization for Animal Health (2014) Avian tuberculosis. In: *Manual of Diagnostic Tests and Vaccines for Terrestrial Animals*. Chapter 2.3.6. World Health Organization, Geneva, Switzerland. p497–508.
 34. Babacan, O., Bülent, B. and Sareyyüpoğlu, B. (2020) PCR detection of *Mycobacterium genavense* DNA in fecal samples of caged birds. *Ank. Univ. Vet. Fak.*, 67(2): 201–204.
 35. Algammal, A.M., Hashem, H.R., Al-Otaibi, A.S., Afifi, K.J., El-dawody, E.M., Mahrous, E., Hetta, H.F., El-Kholy, A.W., Ramadan, H. and El-Tarabili, R.M. (2021) Emerging MDR-*Mycobacterium avium* subsp. *avium* in house-reared domestic birds as the first report in Egypt. *BMC Microbiol.*, 21(1): 237.
 36. Wolinsky, E. and Schaefer, W.B. (1973) Proposed numbering scheme for mycobacterial serotypes by agglutination. *Int. J. Syst. Bacteriol.*, 23(2): 182–183.
 37. Baghal, M.L., Mayahi, M., Mosavari, N. and Boroomand, M. (2020) Comparison of PCR and designed ELISA methods to detect avian tuberculosis in suspected pigeons. *Iran. Vet. J.*, 16(2): 29–37.
 38. Van Ingen, J., Al Hajoj, S.A.M., Boere, M., Al Rabiah, F., Enaimi, M., de Zwaan, R., Tortoli, E., Dekhuijzen, R. and van Soolingen, D. (2009) *Mycobacterium riyadhense* spp. nov.; a non-tuberculous species identified as *Mycobacterium tuberculosis* by a commercial line-probe assay. *Int. J. Syst. Evol. Microbiol.*, 59(Pt 5): 1049–1053.
 39. Keavská, M., Slana, I., Kralík, P. and Pavlík, I. (2010) Examination of *Mycobacterium avium* subsp. *avium* distribution in naturally infected hens by culture and triplex quantitative real-time PCR. *Vet. Med. (Praha)*, 55(7): 325–330.
 40. Shitaye, E.J., Grymova, V., Grym, M., Halouzka, R., Horvathova, A., Moravkova, M., Beran, V., Svobodova, J., Dvorska-Bartosova, L. and Pavlík, I. (2009) *Mycobacterium avium* subsp. *hominissuis* infection in a pet parrot. *Emerg. Infect. Dis.*, 15(4): 617–619.
 41. Une, Y. and Mori, T. (2007) Tuberculosis as a zoonosis from a veterinary perspective. *Comp. Immunol. Microbiol. Infect. Dis.*, 30(5–6): 415–425.
 42. Debelu, T., Abunna, F. and Kassa, G.M. (2021) A preliminary study on public health implications of avian tuberculosis in selected districts of the Oromia Region, Ethiopia. *Vet. Med. Int.*, 2021: 6331599.
 43. Fulton, R.M. and Thoen, C.O. (2003) Tuberculosis. In: Saif, Y.M., Barnes, H.J., Glisson, J.R., Fadly, F.M., McDougald, L.R. and Swayne, D.E., editors. *Diseases of Poultry*. Iowa State University Press, Ames, IA, USA. p836–844.
 44. Nasiri, M.J., Haeili, M., Ghazi, M., Goudarzi, H., Pormohammad, A., Fooladi, A.A.I. and Feizabadi, M.M. (2017) New insights into the intrinsic and acquired drug resistance mechanisms in mycobacteria. *Front. Microbiol.*, 8: 681.
 45. Parker, H., Lorenc, R., Castillo, J.R. and Karakousis, P.C. (2020) Mechanisms of antibiotic tolerance in *Mycobacterium avium* complex: Lessons from related mycobacteria. *Front. Microbiol.*, 11: 573983.
 46. Sanz-García, F., Anoz-Carbonell, E., Pérez-Herrán, E., Martín, C., Lucía, A., Rodrigues, L. and Anisa, J. (2019) Mycobacterial aminoglycoside acetyltransferases: A little of drug resistance, and a lot of other roles. *Front. Microbiol.*, 10: 46.
 47. Brown-Elliott, B.A., Philley, J.V., Benwill, J.L. and Wallace, R.J. (2014) Current opinions in the treatment of pulmonary nontuberculous mycobacteria in non-cystic fibrosis patients: *Mycobacterium abscessus* group, *Mycobacterium avium* complex, and *Mycobacterium kansasii*. *Curr. Treat Options Infect. Dis.*, 6(4): 392–408.
 48. Huang, C.C., Wu, M.F., Chen, H.C. and Huang, W.C. (2018) *In vitro* activity of aminoglycosides, clofazimine, d-cycloserine and dapson against 83 *Mycobacterium avium* complex clinical isolates. *J. Microbiol. Immunol. Infect.*, 51(5): 636–643.
 49. Falkingham, J.O., Gross, W.B. and Pierson, F.W. (2004) Effect of different cell fractions of *Mycobacterium avium* and vaccination regimens of *Mycobacterium avium* infection. *Scand. J. Immunol.*, 59(5): 478–484.
