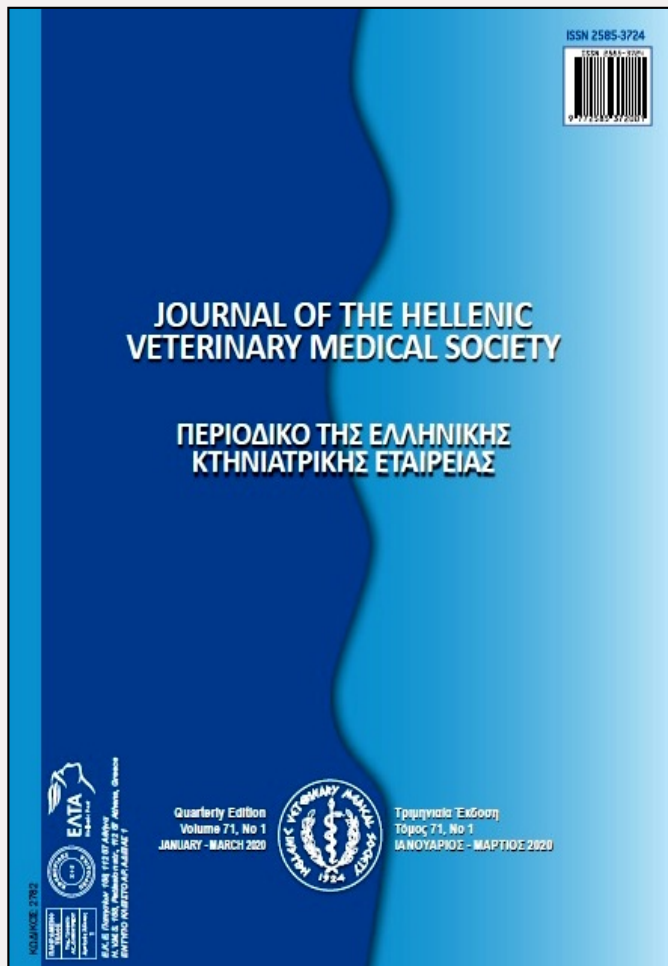

Journal of the Hellenic Veterinary Medical Society

Vol. 71, 2020



Studies on *Pseudomonas aeruginosa* Infection in Hatcheries and Chicken

ERAKY R. Bacteriology Department,
Animal Health Research
Institute (Damietta branch),
Egypt

ABD EL-GHANY W. Poultry Diseases
Department, Faculty of
Veterinary Medicine, Cairo
University, Egypt

SOLIMAN K. Pathology Department,
Animal Health Research
Institute, Dokki, Egypt

<https://doi.org/10.12681/jhvms.22937>

Copyright © 2020 R. D. ERAKY, W. A. ABD EL-GHANY, K. M. SOLIMAN



To cite this article:

ERAKY, R., ABD EL-GHANY, W., & SOLIMAN, K. (2020). Studies on *Pseudomonas aeruginosa* Infection in Hatcheries and Chicken. *Journal of the Hellenic Veterinary Medical Society*, 71(1), 1953-1962.
doi:<https://doi.org/10.12681/jhvms.22937>

Studies on *Pseudomonas aeruginosa* Infection in Hatcheries and Chicken

R. D. Eraky¹, W. A. Abd El-Ghany^{*2}, K. M. Soliman³

¹Bacteriology Department, Animal Health Research Institute (Damietta branch), Egypt

²Poultry Diseases Department, Faculty of Veterinary Medicine, Cairo University, Egypt

³Pathology Department, Animal Health Research Institute, Dokki, Egypt

ABSTRACT. The aim of this work was to spot light on the presence of *Pseudomonas aeruginosa* (*P. aeruginosa*) strains in hatcheries and dead in shell embryos. A total of 406 samples representing 200 and 206 swabs from hatcheries environment and yolk sacs of dead in shell embryos were collected from Damietta governorate, Egypt. *P. aeruginosa* was isolated and identified. Some virulent genes (*toxA*, *pslA* and *fliC*) of *P. aeruginosa* were detected using polymerase chain reaction (PCR). The antimicrobial susceptibility of *P. aeruginosa* was tested *in vitro*. Day and 11 days old broiler chicks were challenged with *P. aeruginosa* to determine the pathogenicity of the isolated strains. The results showed that *P. aeruginosa* was recovered from 16 (8%) out of 200 hatcheries and from 17 (8.25%) out of 206 chicken embryos samples. Isolated strains of *P. aeruginosa* showed presence of *toxA*, *pslA* and *fliC* virulent genes. *P. aeruginosa* strains were sensitive (100%) to ciprofloxacin, levofloxacin and gentamycin but resistant (100%) to amoxicillin/clavulanic acid, doxycycline and erythromycin. The pathogenicity test of day and 11 days old chicks revealed that *P. aeruginosa* was highly pathogenic induced mortality rates of 72 and 40%, respectively. Septicaemia of internal organs, unabsorbed yolk sacs, pneumonia, greenish exudates in the abdominal cavity, liver necrosis and enteritis were the predominant lesions. Histopathological changes supported the previous lesions. In conclusion, *P. aeruginosa* is of great importance pathogen of embryos and newly hatched chicks based on presence of virulent genes as well as *in vivo* pathogenicity study; respectively.

Keywords: Antimicrobials, Chickens, *P. aeruginosa*, Pathogenicity, PCR

Corresponding Author:
Wafaa Abd El-Ghany Abd El-Ghany, Poultry Diseases Department, Faculty of Veterinary Medicine, Cairo University, Egypt, Giza Square, 12211
E-mail address: wafaa.ghany@yahoo.com

Date of initial submission: 12-01-2019
Date of revised submission: 12-11-2019
Date of acceptance: 11-12-2019

INTRODUCTION

Pseudomonas species are ubiquitous organisms and usually present in soil, humid areas and water (Barnes, 2003). Infection of chickens especially young's with *Pseudomonas aeruginosa* (*P. aeruginosa*) induces septicaemia, mortalities, respiratory manifestations and diarrhea or localized infections in different organs (Walker et al., 2002). High rates of late embryonic deaths and loses of netwly hatched chicks were recorded after infection with *P. aeruginosa* (Fekadu, 2010). Conventional methods for isolation and identification of *P. aeruginosa* faces some difficulties in accurate detection of the bacteria due to misidentification with closely related Gram-negative bacilli (Al-Ahmadi and Roodsari, 2016). So, the use of molecular techniques as polymerase chain reaction (PCR) improves accurate and rapid identification of *P. aeruginosa* (Anuj et al., 2009). *P. aeruginosa* possess different virulent factors inducing toxicity and pathogenicity (Fadhil et al., 2016).

Presence of intrinsic and acquired antibiotic resistance mechanisms creates difficulty of *P. aeruginosa* treatment (Lister et al., 2009).

The opportunistic pathogenic nature of *P. aeruginosa*, biofilm formation, induction of chronic infections are factors responsible for high level of multiple drug resistance (Wei and Ma, 2013; Rasamiravaka et al., 2015).

Therefore, this study was designed to identify *P. aeruginosa* strains from hatcheries and dead in shell embryos, detect some virulent genes (*toxA*, *psIA* and *fliC*), test the susceptibility of the isolated strains to various antimicrobials *in vitro* and finally examine their pathogenicity in newly hatched chicks.

MATERIALS AND METHODS

Isolation and identification of *Pseudomonas* isolates

Samples were taken from 8 hatcheries in Damietta governorate, Egypt during the period from March to August, 2018. A total of 406 samples representing 200 swabs from hatcheries environment and 206 swabs from yolk sacs of late dead in shell embryos (Table 1). Samples were collected in sterile plastic containers, kept in ice box and transported as soon as possible to the laboratory. Isolation of *Pseudomonas* isolates was done according to Quinn *et al.* (2002). The samples were aerobically inoculated into nutrient broth for 24h at 37°C. A loop-full of inoculated broth were streaked onto MacConkey agar and *Pseudomonas* agar base media and incubated aerobically for 24h at 37°C. The non-lactose fermented colonies were randomly selected and sub-cultured onto nutrient agar plates to observe the pigmentation. The purified colonies were examined for their colonial morphology, pigment production and odour. Identification was carried out through Gram staining, biochemical reactions and sugar fermentation.

Serological identification of *P. aeruginosa* isolates

Serological identification was done in Animal Health Research Institute, Dokki, Egypt using antisera from Denka Seiken Co. Ltd, Tokyo, Japan. It was carried out for detection of somatic antigen "O" using *P. aeruginosa* antisera according to the method of Homma (1980). Agglutination kit contained polyvalent and monovalent antisera. Agglutination was described as positive if it caused a positive slide agglutination reaction.

Molecular detection of *P. aeruginosa* virulent genes

Presence of specific virulent genes of *P. aeruginosa* (*toxA*, *psIA* and *fliC*) was examined using PCR. DNA extraction from *P. aeruginosa* isolates was performed using the QIAamp DNA Mini kit (Qiagen, Germany, GmbH) with modifications from the manufacturer's recommendations are listed in Table (2).

Table 1: The number of the examined samples distributed in Damietta governorate, Egypt

Locality	Number of samples	
	Hatcheries	Chicken embryos
Om El-Reda	25	28
Farskour	25	29
Zarka	25	22
Kafer-Saad	50	58
Cinania	25	15
Kafer El-Batekh	50	54
Total	200	206

Table 2: Virulence target genes, oligonucleotide primers, amplicon sizes and cycling conditions for *P. aeruginosa*

Target gene	Primers sequences	Amplified segment (bp)	Primary denaturation	Amplification (35 cycles)			Final extension	Reference
				Secondary denaturation	Annealing	Extension		
toxA	GACAACG	396	94°C 5 min.	94°C 30 sec.	55°C 40 sec.	72°C 45 sec.	72°C 7 min.	Matar et al. (2002)
	CCCTCAG							
	CATCACC							
pslA	AGC	656	94°C 5 min.	94°C 30 sec.	60°C 40 sec.	72°C 45 sec.	72°C 10 min.	Ghadaksaz et al. (2015)
	CGCTGGC							
	CCATTTCG							
fliC	CTCCAGC	180	94°C 5 min.	94°C 30 sec.	56.2°C 30 sec.	72°C 30 sec.	72°C 7 min.	
	GCT							
	TCCCTAC							
	CTCAGCA							
	GCAAGC							
	TGTTGTA							
	GCCGTAG							
	CGTTTCT							
	G							
	TGAACGT							
	GGCTACC							
	AAGAACG							
	TCTGCAG							

In vitro*-antibiotic susceptibility test of *P. aeruginosa

In vitro antibiotic susceptibility test of *P. aeruginosa* strains was carried out using disc diffusion method (CLSI, 2015). Culture with 0.5 McFarland density was distributed onto the Müller-Hinton agar. The antibiotic discs were distributed on the agar surfaces and the zones of inhibition were measured after 24 hr.

Pathogenicity test of *P. aeruginosa* in chickens

The experiment was done according to the regulation of Institutional Animal Care and Use Committee (CU-IACUC), Cairo University with Code Number (CU II F 110 18). A total of 80, day-old Cobb chicks was obtained from local hatcheries and 5 birds were subjected for bacteriological examination to confirm absence of *P. aeruginosa*. Chicks were reared on thoroughly cleaned and disinfected semi closed houses and vaccinated using standard protocol for vaccination. Feed and water was given *ad libitum*. Chicks were divided into 3 equal groups, each containing 25 birds. Chicks of group (1) were challenged at day old, while chicks of group (2) were challenged at 11 days old. Chicks in group (3) were kept as blank control negative non challenged group. Each chick in groups (1) and (2) was challenged intramuscularly with 0.2 ml of 24 hr broth culture contained 10^3 viable cell of *P. aeruginosa* /ml (Joh et al., 2005), while those in

group (3) were inoculated with sterile phosphate buffer saline. The strain used in challenge is that identified herein. All chickens were kept under observation for 10 days to detect clinical signs, mortalities and post-mortem lesions. Samples were collected from dead birds for re-isolation of *P. aeruginosa*. At the end of the study, samples including; liver, spleen and heart were collected from sacrificed birds for gross lesions, re-isolation of *P. aeruginosa*.

Histopathological examination

Tissue specimens from lung, heart and liver were collected, fixed in 10% neutral buffered formaline, routinely processed by standard paraffin embedding technique, sectioned at 4 micron and finally stained with Hematoxylin and Eosin (H&E) (Bancroft and Gamble, 2002).

RESULTS

Based on cultural, morphological and biochemical characteristics of the isolates, a total of (16, 8%) and (17, 8.25%) *P. aeruginosa* isolates were recovered from 200 hatchery and 206 chicken embryos samples, respectively (Table 3).

Morphologically, *P. aeruginosa* is aerobic β haemolytic colonies on blood agar, on MacConkey agar; it has pale colonies of non-lactose fermenter. The plates

containing characteristic colonies of *P. aeruginosa* (large, irregular, translucent and produced a greenish diffusible pigment and characterized by fruity smell). Microscopically, the organism is Gram-negative short rod. Biochemically, it is positive oxidase, catalase, urea, citrate utilization and gelatin hydrolysis, negative for indole, methyl red and Voges Proskauer. It shows sugar fermentation of glucose, mannose and xylose, but not sucrose, lactose and maltose.

Serological identification of *P. aeruginosa* revealed that all of isolates were belonged to types G and M (Table 3).

Molecular detection of virulent genes of *P. aeruginosa* showed presence of *toxA* and *psIA* genes in all strains and *fliC* in almost strains (Figures 1, 2 and 3).

Strains of *P. aeruginosa* showed *in vitro* susceptibility (100%) to ciprofloxacin, levofloxacin and gentamycin and (48.48%) streptomycin but resistant (100%) to amoxycillin/clavulanic acid, doxycycline and erythromycin and (78.78%) nalidixic acid. Intermediate susceptibility was detected to chloramphenicol (75.75%) and colistin sulphate (36.36%) (Table 4).

Table 3: The incidence and the predominant serotypes of *P. aeruginosa* in Damietta governorate, Egypt

Locality	Hatcheries			Serotype	Chicken embryos			Serotype
	Number of samples	Number of positive	% positive		Number of samples	Number of positive	% positive	
Om El-Reda	25	6	24	M	28	5	17.85	G and M
Farskour	25	4	16	M	29	3	10.3	M
Zarka	25	0	0		22	0	0	
Kafer-Saad	50	3	6	M	58	5	8.6	G and M
Cinania	25	0	0		15	0	0	
Kafer El-Batekh	50	3	6	G	54	4	7.4	G
Total	200	16	8		206	17	8.25	

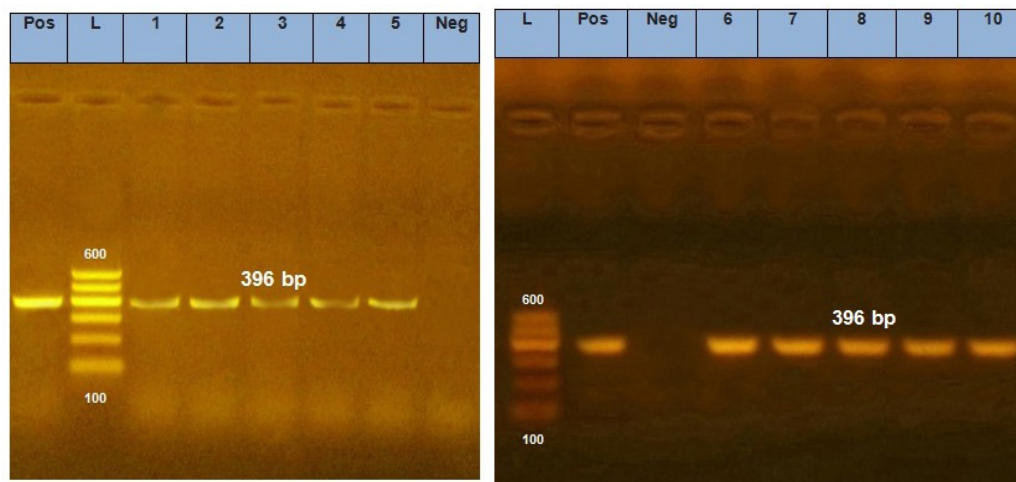


Figure 1: PCR amplification using *Pseudomonas* genus-specific primers (*toxA* gene), Pos= positive control, L= ladder, lines 1-10 = clinical isolates of *P. aeruginosa*, Neg= negative control

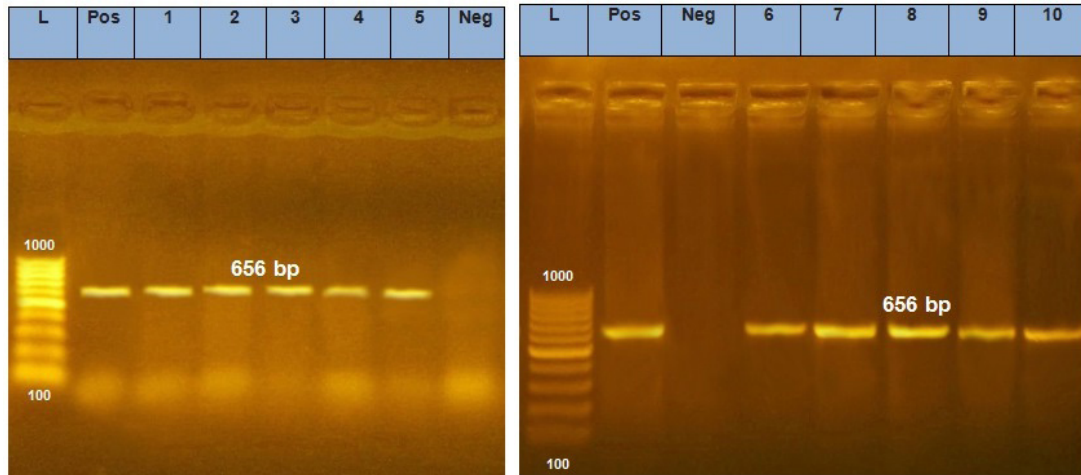


Figure 2: PCR amplification using *Pseudomonas* genus-specific primers (*psIA* gene), Pos= positive control, L= ladder, lines 1-10 = clinical isolates of *P. aeruginosa*, Neg= negative control

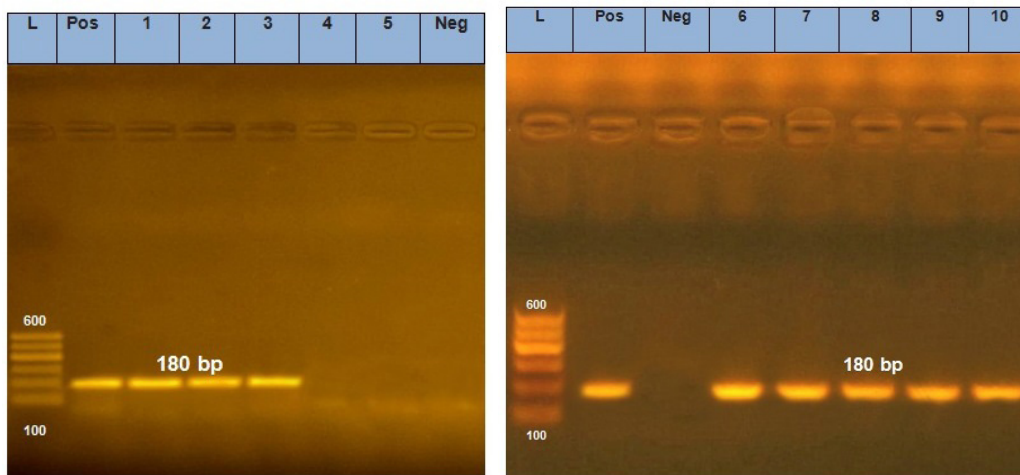


Figure 3: PCR amplification using *Pseudomonas* genus-specific primers (*filC* gene), Pos= positive control, L= ladder, lines 1-4, 6-10 = clinical isolates of *P. aeruginosa*, Neg= negative control

Table 4: Results of antibiogram test against *P. aeruginosa*

Antibiotic Disc (Code)	Disc content/ μg	Antimicrobial efficacy (%) against 33 strain of <i>P. aeruginosa</i>		
		Susceptible	Intermediate susceptibility	Resistant
Amoxicillin/Clavulanic acid (AMC)	30	0 (0%)	0 (0%)	33 (100%)
Chloramphenicol (C)	30	8 (24.2%)	25 (75.75%)	0 (0%)
Ciprofloxacin (CIP)	5	33 (100%)	0 (0%)	0 (0%)
Colistin sulphate (CT)	10	11 (33.3%)	12 (36.36%)	10 (30.3%)
Doxycycline (Do)	30	0 (0%)	0 (0%)	33 (100%)
Erythromycin (E)	15	0 (0%)	0 (0%)	33 (100%)
Gentamycin (CN)	10	33 (100%)	0 (0%)	0 (0%)
Levofloxacin (LEV)	5	33 (100%)	0 (0%)	0 (0%)
Nalidixic acid (NA)	30	0 (0%)	7 (21.2%)	26 (78.78%)
Streptomycin (S)	10	16 (48.48%)	9 (27.27%)	8 (24.2%)

Clinical signs of *P. aeruginosa* challenged chicks were depression, off food, reluctance, sleepy appearance, respiratory signs and greenish diarrhea. Mortalities began on day old *P. aeruginosa* challenged chicks 12-16 hr post challenge (PC) with mortality rate of (18/25, 72%), while appeared on 11 days old chicks 24 hr PC with mortality rate of (10/25, 40%). The post-mortem examination of the dead chick's revealed septicemia, congestion with peticheal haemorrhages on liver, spleen and lung, pericarditis, distention of gall-bladder, unabsorbed yolk sacs, greenish exudates in the abdominal cavity and enteritis. Gross lesions of sacrificed birds showed congestion of the liver, spleen and kidneys, pneumonia, liver necrosis and unabsorbed yolk sacs. *P. aeruginosa* organism was re-isolated from dead and sacrificed birds. No clinical signs or mortalities was recorded on phosphate buffer saline inoculated chicks.

The results of histopathological examination of dead and sacrificed chicks that challenged at one day old are collected in Figure (4). The lung had severe interstitial pneumonia with highly edematous thickening of alveolar wall, highly congested alveolar capillaries as well as mononuclear inflammatory cell infiltration with some heterophiles throughout the interstitial tissue (A). The bronchi and bronchioles had hyperplastic proliferation of their epithelial lining especially goblet cells were had marked hyperplastic proliferation. Mononuclear inflammatory cell infiltration with some heterophiles around bronchi and bronchioles could be detected. Sub-peluraledema could be detected. The heart had marked subepicardial edema with dilatation of sub epicardial blood vessels (B). The liver showed highly congested hepatic sinusoids with disarrangement of hepatic rosettes as well as hepatic cell degeneration and necrosis with infiltration of mononuclear inflammatory cells with some heterophils (C). Wide patches of hepatic cells coagulative necrosis could be detected with infiltration of mononuclear inflammatory cells and some heterophils (D) as well as Kupffer cell activation could be detected.

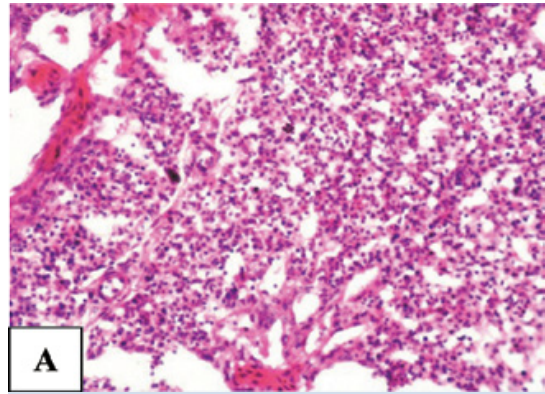


Figure 4 (A): Lung of one-day old chicks showed severe interstitial pneumonia with highly edematous thickening alveolar wall, highly congested alveolar capillaries as well as mononuclear inflammatory cell infiltration with heterophils through the interstitial tissue. (H&E X400).

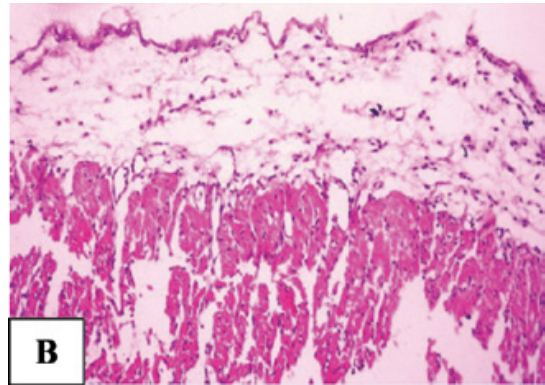


Figure 4 (B): Heart of one-day old chicks showed marked subepicardial edema with dilatation of subepicardial blood vessels. Marked edema could be detected between cardiac muscle fibers accompanied by some degenerative changes of cardiomyocytes. (H&E X400).

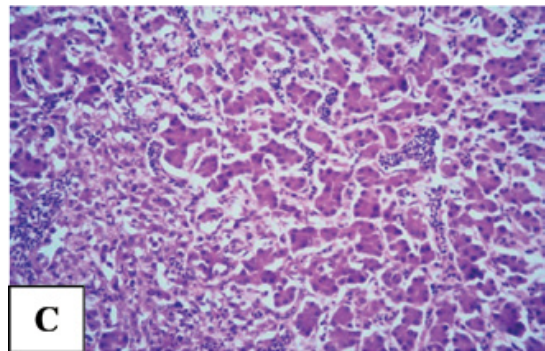


Figure 4 (C): Liver of one-day old chicks showed highly congested hepatic sinusoids with disarrangement of hepatic rosettes as well as patches of hepatic cell necrosis with infiltration of mononuclear inflammatory cells with some heterophils. Kupffer cell activation could be observed. (H&E X400).

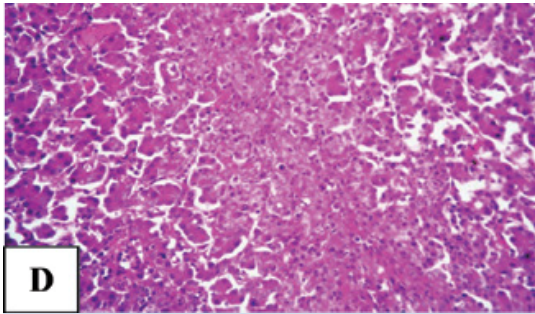


Figure 4 (D): Liver of one-day old chicks showed wide patches of hepatic cells coagulative necrosis could be detected with infiltration of mononuclear inflammatory cells and some heterophils (H&E X400).

The histopathological lesions of dead and sacrificed chicks that challenged at 11 days old are represented in Figure (5). The lungs revealed bronchopneumonia with marked hyperplastic proliferation of its epithelial lining as well as highly hyperplastic proliferated goblet cells (A). The bronchial lumen filled with exudates consisted of desquamated epithelial cells, mononuclear inflammatory cells, heterophils and red blood cells. Marked peribroncheal heterophils and mononuclear cell infiltration could be observed (A). The lung showed patches of consolidated pneumonia and the alveolar lumen was filled with fibrinopurulent exudates (B) with desquamated epithelial cells with necrosis in alveolar wall and heterophils detection in alveolar lumen. Other patches of pulmonary tissue had haemorrhagic pneumonia. Moreover, the lung had pulmonary blood vessel with large red attached thrombus consisted of fibrin, mononuclear cells and red blood cells (C). Other blood vessels had perivascular mononuclear inflammatory cell infiltration with many heterophils and myriads of bacteria. The heart had marked myocarditis, edema and some hemorrhage between cardiomyocytes (D). Zenker's necrosis of most cardiomyocytes could be detected. The wall of most interstitial blood vessels showed degenerative and necrotic changes (D). The liver had dilated hepatic sinusoids with dissociated hepatic rosettes, vacuolar degeneration of many hepatocytes, other hepatocytes had pyknotic nuclei (E). Multiple foci of degenerated and necrotic hepatocytes were seen around central veins which replaced by mononuclear inflammatory cell infiltration and heterophils (E). Kupffer cell activation could be detected. Portal area revealed proliferation of bile duct and highly dilated portal blood vessel. Mononuclear inflammatory cells and heterophils infiltration could be detected around portal area (F). Other patches of hepatic tissue

had highly dilated portal blood vessel surrounded by dissociated, degenerative, necrotic hepatocytes and marked large haemorrhagic area (G).

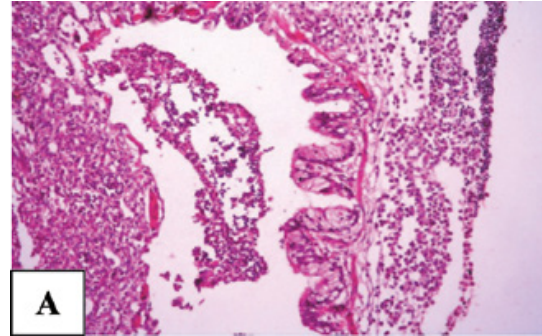


Figure 5 (A): Lung of 11-days old chicks showed bronchus with marked hyperplastic proliferation of its epithelial lining as well as highly hyperplastic proliferated goblet cells. The bronchial lumen had exudates with desquamated epithelial cells, mononuclear inflammatory cells, heterophils and red blood cells. Marked aggregation of peribroncheal heterophils and mononuclear inflammatory cell could be seen. (H&E X400).

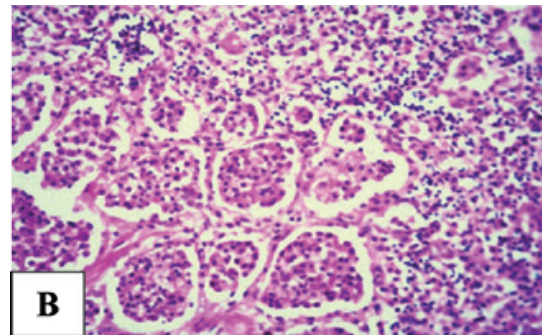


Figure 5 (B): Lung of 11-days old chicks showed patches of consolidated pneumonia, alveolar lumen filled with fibrinopurulent exudates with desquamated epithelial cells, as well as other patches of haemorrhagic pneumonia. (H&E X400).

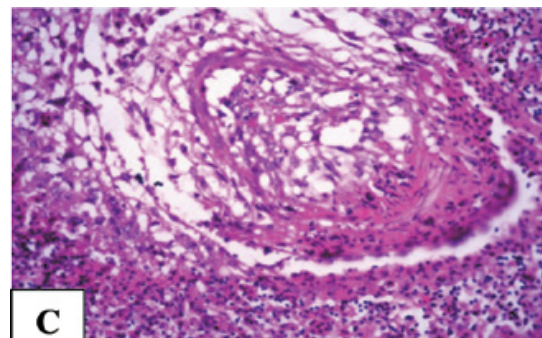


Figure 5 (C): Lung of 11-days old chicks showed pulmonary blood vessel with large red attached thrombus consisted of fibrin, mononuclear cells and red blood cells. Haemorrhagic pneumonia could be seen around thrombosed blood vessel. (H&E X400).

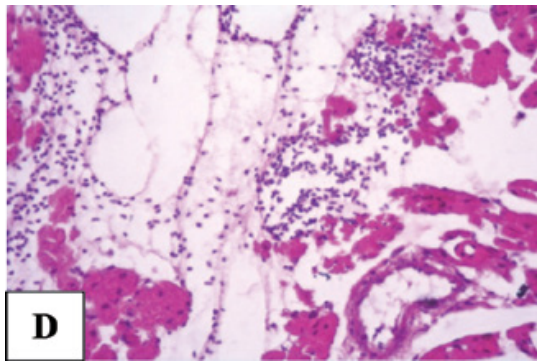


Figure 5 (D): Heart of 11-days old chicks showed marked interstitial edema and some hemorrhage between cardiac muscle fibers. Zenker's necrosis of most myocardial fibers could be seen as well as degenerative and necrotic changes through the wall of most interstitial blood vessels. (H&E X400).

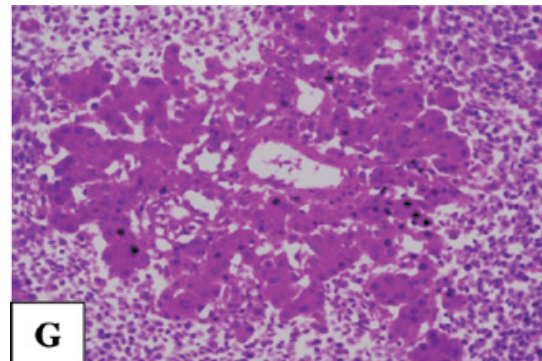


Figure 5 (G): Liver of 11-days old chicks showed highly dilated portal blood vessel, surrounded with degenerative and necrotic hepatocytes. Marked large haemorrhagic areas near necrotic hepatocytes could be seen. (H&E X400).

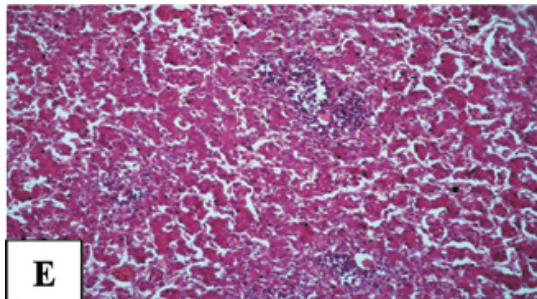


Figure 5 (E): Liver of 11-days old chicks showed dilated hepatic sinusoids with vacuolar degeneration of many hepatocytes, other hepatocytes had pyknotic nuclei. Multiple foci of degenerated and necrotic hepatocytes were seen around central veins which replaced by mononuclear inflammatory cell infiltration and heterophils. Kupffer cell activation could be seen. (H&E X400).

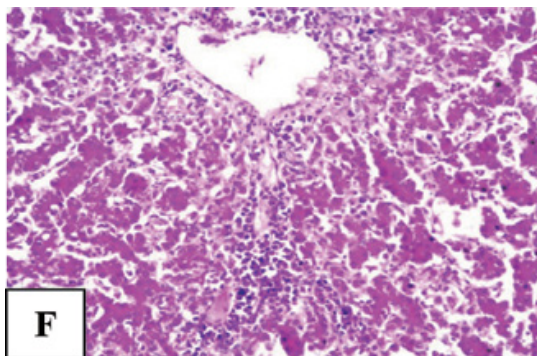


Figure 5 (F): Liver of 11-days old chicks showed portal area with hyperplastic proliferation of bile duct and highly dilated portal blood vessel. Mononuclear inflammatory cell and heterophils infiltration could be detected around portal area. Most hepatocytes had degenerative and necrotic changes. (H&E X400).

DISCUSSION

In the present investigation, the results of cultural, morphological and biochemical characteristics of *P. aeruginosa* isolates were similar to the findings of Betty et al. (2007) who isolated *P. aeruginosa* with an incidence 8% from 100 chicken suffering from respiratory symptoms. In Egypt, Farghaly et al. (2017) detected presence of *P. aeruginosa* in 42 samples after examination of 480 ones with a percentage of 8.75. Lower isolation percentages were recorded by Hayford (2017) who isolated for *P. aeruginosa* from chickens samples in rates of 1.8 and 2.6%, respectively. Elsayed et al. (2016) isolated *P. aeruginosa* with percentage 22.9% (38 /166) and a high isolation rate from yolk sac of dead-in-shell embryos 26/50 (52%) was observed.

P. aeruginosa was isolated from young chickens with high mortalities and late dead in shell embryos (Fekadu, 2010).

Satish and Priti (2015) succeed in isolation of *P. aeruginosa* from 200 samples of 4- days- old chicks in percentage of 20%; where the isolation rate from healthy birds was 12% and from diseased ones was 30%.

Serological examination of *P. aeruginosa* is very important for epidemiological studies as serotyping facilitates the detection of the prevalent serotypes and locating sources of infection (Nedeljković et al., 2015). Serological identification of the present *P. aeruginosa* isolates were G and M. El-Gohary et al. (2012) demonstrated that the predominant serotypes were A, B, D, F, H, K, L and M.

Due to difficulties and inaccuracy of phenotypic characterization of *P. aeruginosa*, PCR amplification

and sequencing for detection of species specific conserved genes (*toxA*, *psIA* and *fliC*) in the genome of *P. aeruginosa* can be utilized in its identification and classification. Molecular detection of virulent genes of *P. aeruginosa* in this work showed presence of *toxA* and *psIA* genes in all strains and *fliC* in almost strains. Potential virulence factors secreted by *P. aeruginosa* that are important in its pathogenicity include exotoxin A (*toxA*), which is the most toxic virulence factor detected in this organism (Dong et al., 2015). It inhibits protein biosynthesis, it has a necrotizing activity on tissues causing cell death and contributes to the colonization process (Michalska and Wolf, 2015). Other genes like (*psIA*) is responsible for biofilm formation (Ghadaksaz et al., 2015). Flagellar gene (*fliC*) plays important roles in tissue penetration (Ertugrul et al., 2018).

P. aeruginosa is also known to harbor antibiotic resistant plasmids, integrons and transposons and is able to transfer these genes to other species. Here, isolated strains of *P. aeruginosa* showed *in vitro* susceptibility (100%) to ciprofloxacin, levofloxacin and gentamycin and (48.48%) streptomycin but resistance (100%) to amoxicillin/clavulanic acid, doxycycline and erythromycin and (78.78%) nalidixic acid. Nearly similar finding was observed by Farghaly et al. (2017) who demonstrated that 42 *P. aeruginosa* chicken's isolates showed high sensitivity for norfloxacin, ciprofloxacin, and levofloxacin with the percentages of 80.9, 76.2 and 73.8, respectively, 76.2 % to colistin sulfate and gentamicin and 66.7 to streptomycin; however, high resistance (100%) to ampicillin, nalidixic acid and lincomycin followed by trimethoprim sulfamethoxazole with percentage 78.6. As well, Elsayed et al. (2016) recorded sensitivity of *P. aeruginosa* strains to ciprofloxacin and gentamycin.

The results of clinical signs and post-mortem lesions of the inoculated chicks were parallel to the results of Mohamed (2004) who found that subcutaneous inoculation of 3 days old chicks with *P. aeruginosa* induced mortality reached 80% with sleepy appearance, closed eyes, sitting on hocks and diarrhea while the gross lesions revealed congestion of all internal organs, petechial haemorrhages on liver and spleen, pericarditis, pneumonic lungs, swollen of kidneys with deposition of ureates in the ureters, enteritis, enlargement of the gall-bladder and unabsorbed congested yolk sacs. Satish and Priti (2015) found that *P. aeruginosa* induced 100% mortality when inoculated intramuscularly in 7 days old chicks where dead birds showed congested liver with petechial haemorrhages and distended dark gall bladder,

congested heart, lungs and kidneys, enlarged yolk sac and haemorrhagic intestines. Walker et al. (2002) and Joh et al. (2005) reported that the mortality rate was 95% in chick's inoculated *P. aeruginosa* through yolk where dead birds showed congestion and enlargement of liver, peritoneal fluid in the abdomen, epicarditis, omphalitis and some solidified yolks.

Considering the histopathological examination, severe interstitial pneumonia of one day old chicks led to increase thickening of alveolar wall and capillary membrane and decrease the number of ventilated alveoli resulting in hypoxia. Van Delden (2004) discussed that elastin protein of connective tissues and its degradation which carried out by LasB enzyme which is an important enzyme of elastolytic activity that produced by *P. aeruginosa*. That explains the destruction in alveolar wall and blood vessel wall which led to haemorrhagic pneumonia, also explains the destruction of hepatic sinusoids which led to haemorrhage (wide patches of accumulated red blood cells) in hepatic tissue. Rejmanj et al. (2007) stated that *P. aeruginosa* infection alters the permeability function of the epithelial and endothelial junction and that clarifies pulmonary blood vessels thrombosis. Most histopathological changes of lung, heart and liver were inflammatory in nature that come in agree with Timurkaan et al. (2008) who found inflammatory reaction through heart and lung especially in young birds. Ferro et al. (2004) stated that heterophils functions in 1-14 days old chickens were found inefficient compared to older birds, that inefficiency in function continued until 21 days of age and that was correlated with an increase in susceptibility to bacterial infection. Kupffer cells activation which detected in liver of all infected chicken comes in agree with Katja et al. (2015) who described that Kupffer cells are important cells for filtration of *P. aeruginosa* during systemic infection and that in corporation with heterophils which are essential for bacterial control. Most of liver diseases in chicken were associated with liver failure which was explained by Supertika et al. (2006) who found degeneration and necrosis of hepatic tissue in infected 10 days old chickens. The prominent microscopic lesions of the dead broilers with *P. aeruginosa* were multiple foci of coagulative necrosis with intra lesion bacteria and heterophilic infiltration in the liver and the serosal surface was covered with fibrino-purulent exudates, diffuse fibrinous exudates with bacterial colonization in the epicardium and decreased lymphocytes and moderately increased reticulocytes in the spleen (Joh et al., 2005).

In conclusion, *P. aeruginosa* is of great importance

pathogen as it could be isolated from both hatcheries environment and dead in shell embryos based in detection of virulent genes. *In-vitro* antibiogram is important to detect susceptibility and resistance of *P. aeruginosa* to different antimicrobials. The pathogenicity of *P. aeruginosa* in newly hatched chicks revealed that this organism is pathogenic. Farm management should take strict hygienic measures against

possible sources of infection. Further studies are in need to study the effect of this pathogen on Egyptian poultry industry.

CONFLICT OF INTEREST

The authors declare that there are no conflicts of interest.

REFERENCES

- Al-Ahmadi JG, Roodsari ZR (2016) Fast and specific detection of *Pseudomonas aeruginosa* from other Pseudomonas species by PCR. *Annals of Burns and Fire Disasters*, XXIX 4: 264-267.
- Anuj SN, Whitley DM, Kidd TJ, Bell SC (2009) Identification of *Pseudomonas aeruginosa* by a duplex real-time polymerase chain reaction assay targeting the *ecfX* and the *gyrB* genes. *Diagn Microbiol Infect Dis* 63: 127-131.
- Bancroft JD, Gamble M (2002) *Theory and practice of histological technique*. 6th Ed., Churchill, Livingstone, New York, London, San Francisco, Tokyo.
- Barnes HJ (2003) *Miscellaneous Bacterial Diseases*. In: *Diseases of Poultry*. 11th ed. Iowa State University Press, Ames, pp. 852-854.
- Clinical Laboratory and Standards Institute (CLSI) (2015) *Methods for dilution antimicrobial susceptibility tests for bacteria that grow aerobically*; approved standard - tenth edition. CLSI document M07-A10 Villanova, PA, USA: CLSI, 2015.
- Dong D, Zou D, Liu H, Yang Z, Huang S, Liu N, He X, Liu W, Huang L (2015) Rapid detection of *Pseudomonas aeruginosa* targeting the *toxA* gene in intensive care unit patients from Beijing, China. *Frontier Microbiol* 6: 1100.
- El-Gohary Amany H, El-Shehedi Mona A, Safwat E (2012) Characterization of *Pseudomonas aeruginosa* isolated from ration and its viability in the environment. 1st Conference of Animal Health Institute Association, Cairo, Egypt, December, pp. 729-737.
- Elsayed MSA, Ammar AM, Al-Shehri ZS, Abd-El Rahman H, Abd-El Rahman NA (2016) Virulence repertoire of *Pseudomonas aeruginosa* from some poultry farms with detection of resistance to various antimicrobials and plant extracts. *Cell Molc Biol* 62: 124-128.
- Ertugrul BM, Oryasin E, Lipsky BA, Willke A, Bozdogan B (2018) Virulence genes *fliC*, *toxA* and *phzS* are common among *Pseudomonas aeruginosa* isolates from diabetic foot infections. *Infect Dis* 50: 273-279.
- Fadhil L, Al-Marzoqi AH, Zahraa MA, Shalan AA (2016) Molecular and phenotypic study of virulence genes in a pathogenic strain of *Pseudomonas aeruginosa* isolated from various clinical origins by PCR: Profiles of genes and toxins. *Res J Pharmaceut Biol Chem Sci* 7: 590-598.
- Farghaly EM, Roshdy H, Bakheet AA, Abd El-Hafez SA, Badr H (2017) Advanced studies on *Pseudomonas aeruginosa* infection in chicken. *Anim Health Res J* 5: 207-217.
- Fekadu K (2010) *Pseudomonas* infection in chickens. *J Vet Med Anim Health* 2: 55-58.
- Ferro PJ, Swaggerty CL, Kaiser P, Pevzner IY, Kogut MH (2004) Heterophils isolated from chickens resistant to extra intestinal *Salmonella enteritidis* infection express higher levels of pro-inflammatory cytokine mRNA following infection than heterophils from susceptible chickens. *Epidemiol Infect* 132: 1029-1037.
- Forbes B, Sahn D, Weissfeld A (2007) *Bailey and Scott's Diagnostic Microbiology*. Elsevier, Science Publishing Company, New York, 12th edition, pp. 322-325.
- Ghadaksaz A, Fooladi AAA, Hosseini HH, Amin M (2015) The prevalence of some *Pseudomonas* virulence genes related to biofilm formation and alginate production among clinical isolates. *J App Biomed* 13: 61-68.
- Homma JY (1980) Designation of thirteen "O" group antigen of *Pseudomonas aeruginosa* attachment for the tentative proposal in 1976. *Jap Experim Med* 52: 317-321.
- Hayford O (2017) Isolation and characterisation of multi-drug resistant *Pseudomonas aeruginosa* from clinical, environmental and poultry litter sources in Ashanti region of Ghana. Mv.Sc, Thesis, Kwame Nkrumah University of Science and Technology, Kumasi- Ghana.
- Joh SJ, Kim MC, Kwon YK, Kim JH (2005) Occurrence of *Pseudomonas aeruginosa* infection in the broilers in Korea. *Korean J Vet Res* 45: 71-74.
- Katja M, Vishal K, Torben K, Namir S, Nadine H, Vikas D et al. (2015) Virus-induced type I interferon deteriorates control of systemic *Pseudomonas aeruginosa* Infection. *Cell Physiol Biochem* 36: 2379-2392.
- Lister PD, Wolter DJ, Hanson ND (2009) Antibacterial-resistant *Pseudomonas aeruginosa*: clinical impact and complex regulation of chromosomally encoded resistance mechanisms. *Clin Microbiol Rev* 22: 582-610.
- Matar GM, Ramlawi F, Hijazi N, Khneisser I, Abdelnoor AM (2002) Transcription levels of *Pseudomonas aeruginosa* exotoxin A gene and severity of symptoms in patients with otitis externa. *Curr Microbiol* 45: 350-354.
- Michalska M, Wolf P (2015) *Pseudomonas* exotoxin A: optimized by evolution for effective killing. *Frontier Microbiol* 6: 963.
- Mohamed HA (2004) Some studies on pseudomonas species in chicken embryos and broilers in Assiut governorate. *Assiut Univ Bull Environ Res* 7: 23-31.
- Nedeljković NS, Todorović B, Kocić B, Ćirić V, Milojković M, Waisi H (2015) *Pseudomonas aeruginosa* serotypes and resistance to antibiotics from wound swabs. *Vojnosanitetski Pregled*, 72: 996-1003.
- Quinn PJ, Markey BK, Carter ME, Donnelly WJC, Leonard FC (2002) *Veterinary Microbiology and Microbial Disease*. First published A Blackwell Science Company.
- Rasamiravaka T, Labtani, Q, Duez P, ElJaziri M (2015) The Formation of biofilms by *Pseudomonas aeruginosa*: A review of the natural and synthetic compounds interfering with control mechanisms. *BioMed Res Inter* 1-17.
- Rejman J, Di Gioia S, Bragonzi A, Conese M (2007) *Pseudomonas aeruginosa* infection destroys the barrier function of lung epithelium and enhances polyplex-mediated transfection. *Human Gene Therapy* 18: 642-652.
- Satish S, Priti M (2015) *Pseudomonas aeruginosa* infection in broiler chicks in Jabalpur. *Inter J Extensive Res* 6: 37-39.
- Supartika IK, Toussaint MJ, Gruys, E (2006) Avian hepatic granuloma. A review. *Vet Q* 28: 82-89.
- Timurkaan N, Yilmaz F, Kilic A, Ozbey G (2008) Pathological and microbiological investigations on lung lesions of slaughtered broilers in the slaughterhouse. *J Anim Vet Adv* 7: 1358-1363.
- Van Delden CV (2004) Virulence factors in *Pseudomonas aeruginosa*. In: *Pseudomonas: virulence and gene regulation*. Kluwer Academic/Plenum Publishers, New York, pp. 23-45.
- Walker SE, Sander JE, Cline JL, Helton JS (2002) Characterization of *Pseudomonas aeruginosa* isolates associated with mortality in broiler chicks. *Avian Dis* 46: 1045-1050.
- Wei Q, Ma LZ (2013) Biofilm matrix and its regulation in *Pseudomonas aeruginosa*. *Inter J Mol Sci* 14 : 20983-21005.