

## Percutaneous Transluminal Balloon Angioplasty: A disparaged Revascularization Tool for Limb Salvage in Patients with Total Popliteal Artery Occlusions

Mohamed El-Maaddawy, Amr Abdulbaky, Usama Lotfi  
Vascular Surgery Unit, Faculty of Medicine, Cairo University

### ABSTRACT

**Background:** Endovascular management of popliteal artery (PA) occlusive disease constitutes a territory of true challenge. PA comprises a milieu that have higher likelihood of de novo disease, challenging lesions, and amplified response to injury with overall implication on difficult recanalization, limited room for stenting and higher restenosis rate. **Aim of study:** To evaluate the outcome of percutaneous transluminal angioplasty (PTA) in recanalization of PA total occlusive lesions, its feasibility, safety, patency and complications. **Patient and Method:** Between October 2012 through December 2014, 21 patients with severe ischemia due to PA occlusive disease were included in this study. Rutherford ischemia class 4 was the main presentation in eight (38%) cases. Ischemic Heart Disease (IHD) was the main comorbidity in 20 (95%) cases. Distal reconstitution of one tibial vessel was present in 10 (47.6%) cases. Patients were followed up both clinically and by duplex ultrasound at one, six, and 12 months. **Results:** The procedure was technically successful in 19 patients who had immediate angiographic success with restoration of distal pulsations in 13 patients. Failure to cross the lesion occurred in two cases. One patient had groin hematoma that required open surgical control and repair. Primary patency rates were 72.3%, 35.3%, and 21.4%, while limb salvage rates were 85.7%, 80.9%, and 66.7% at 1, 6, and 12 months respectively. **Conclusion:** Although technically demanding, PTA can be considered as a feasible and safe option for revascularization of total occlusive lesions of the PA. The relatively mid-term low patency rates should not preclude the advantage of buying time for achieving limb salvage in poor surgical risk patients. **Keywords:** Percutaneous transluminal angioplasty, popliteal artery, total occlusion.

### INTRODUCTION

Approximately 60% to 70% of symptomatic peripheral arterial disease (PAD) is secondary to underlying femoropopliteal (FP) lesions.<sup>1</sup> PA lesions whether isolated or extending from superficial femoral artery (SFA) disease belong to a territory that is characterized by unique slow-flow and high resistance environment with resultant increased incidence of plaque accumulation and higher likelihood of long diffuse occlusions rather than mild focal stenoses.<sup>2</sup> The aforementioned criteria are claimed for the prevalence of both de novo disease and higher incidence of restenosis following interventions as well.<sup>3</sup>

Open surgical revascularization of PA occlusive disease constitutes a challenging task especially in high risk, diabetics, and/or patients who have poor autogenous conduit. However, there is a debate about PTA as a first choice in treatment of PA occlusive disease owing to the fact that PA is the

solitary inflow to the tibial vessels<sup>4,6</sup>. Moreover, the intimacy of PA to the knee joint demands accommodation during limb movement, including bending, shortening, and torsion. Thus add to the generated stresses should a stent be implanted in the PA. This belief is especially considered true for the middle segment of PA and lead to the traditional concept of the so called "non-stent zone".<sup>7-9</sup>

The aim of this retrospective study is to revise, describe and evaluate the results of PTA in PA total occlusive lesions regarding the feasibility, safety, patency and complications.

### PATIENTS AND METHODS

The study was conducted in Kasr Al-Ainy teaching hospitals during the period from October 2012 through December 2014. Twenty one patients with chronic atherosclerotic lower limb ischemia due to PA occlusive lesions were included in the study. Exclusion criteria included

patients with acute ischemia, chronic ischemia due to non-atherosclerotic causes and patients who suffer chronic kidney disease (serum creatinine level > 2 mg/dl or creatinine clearance < 30 ml/ min).

Demographic and clinical data including age, gender, and severity of ischemia whether intermittent claudication or critical limb ischemia, and the presence of any possible risk factor or comorbidities were obtained. In addition to the routine laboratory investigations, the ankle-brachial index (ABI) was measured and a color-Doppler ultrasound (USCD) was done. A pre-procedural computed tomography-angiography (CTA) to achieve complete anatomical overview of the morphology & diameter of the PA, length of the occluded segment, proximal lesions, and distal run-off in tibial arteries was also performed.

The procedure, possible complications, benefits, risks and other alternative interventions were all explained to the patients and an informed consent was obtained.

#### **Technique**

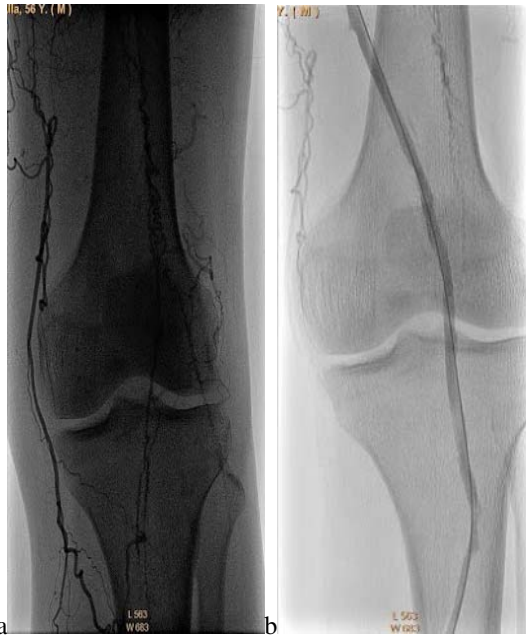A loading dose of clopidogrel 300 mg was given the night of the procedure, both groins were prepared and draped with the patient lying in supine position. Local anesthetic (Lignocaine 2%) was infiltrated at the access site. An ipsilateral common femoral artery (CFA) access in the majority of cases was established by 6-F sheath. After 5,000 IU Heparin was administered through the sheath and scout angiogram was obtained, lesions were negotiated and crossed by either 0.035" Terumo (Terumo, Inc.) or 0.018" V18 (Boston Scientific Inc.) wire. Vertebral or Bernstein catheter supported either wire during the process of lesion negotiation and crossing.

Lesion crossing was attempted either by transluminal or subintimal route. Reentry was accomplished by exploiting the angled tip of the catheter and no special reentry device was used. PTA was done by compliant balloons of a length suitable to the arterial segment being treated.

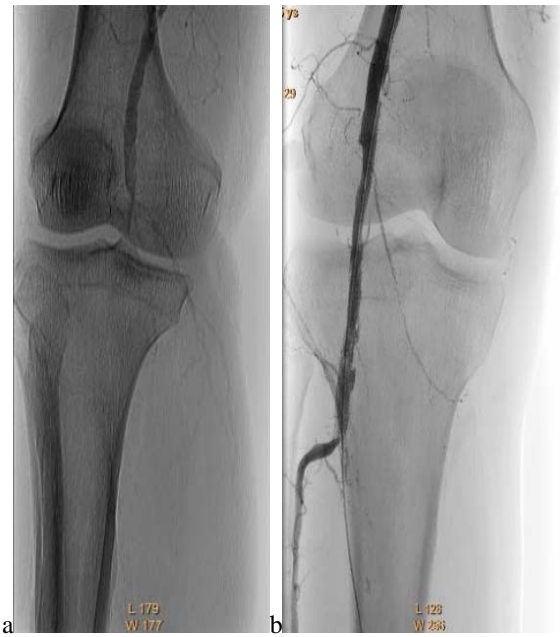We commenced the dilatation by a 3 mm diameter balloon followed by a 4 mm diameter one. A strict adherence to the nominal pressure of a given balloon was respected and balloon inflation lasted for one minute. A check angiogram was obtained following each balloon deflation. The use of a 5 mm diameter balloon was dependent on the finding of less satisfactory picture on the check angiogram.

Whenever a dissection was encountered, additional inflation of a balloon (sometimes in a diameter that is one millimeter less than the diameter of the initially used one) for 3 minutes at a pressure slightly lower than the nominal pressure. Arteriotomy was closed by manual pressure for 10 minutes. The groin was strapped in figure of eight adhesive tape for further 12 hours.

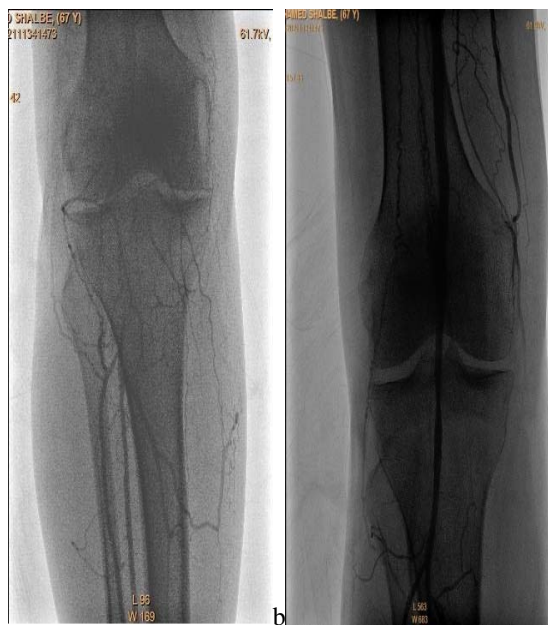Angiographic success of the procedure was considered if the distal flow was reestablished with residual stenosis less the 30%, if any, and without flow limiting dissection. Clinical success was considered by restoration of distal pulses and relief of patient symptoms. Complications were divided into major and minor. Major complications included death, need for emergency surgery, major bleeding or acute thrombotic occlusion. Minor complications included hematoma, treated dissection, dye extravasation or peripheral emboli.



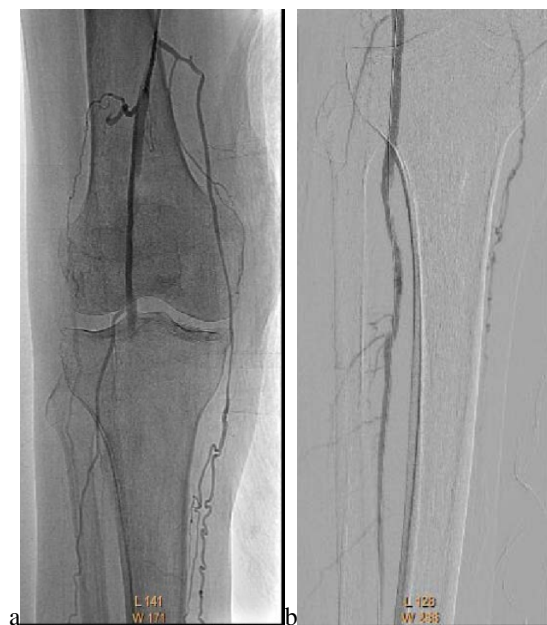**Fig. (1):** Total Occlusion of the femoropopliteal artery transition with poor runoff, A. After successful PTA, B.



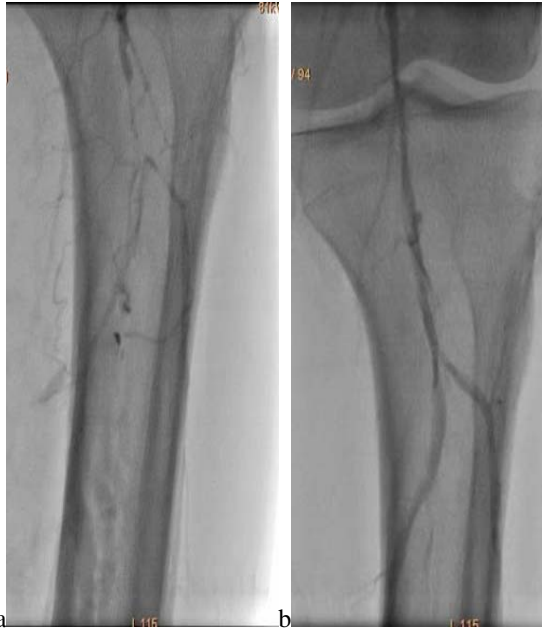**Fig. (2):** Total Occlusion of P2 segment with poor runoff, A. After successful PTA ,B.



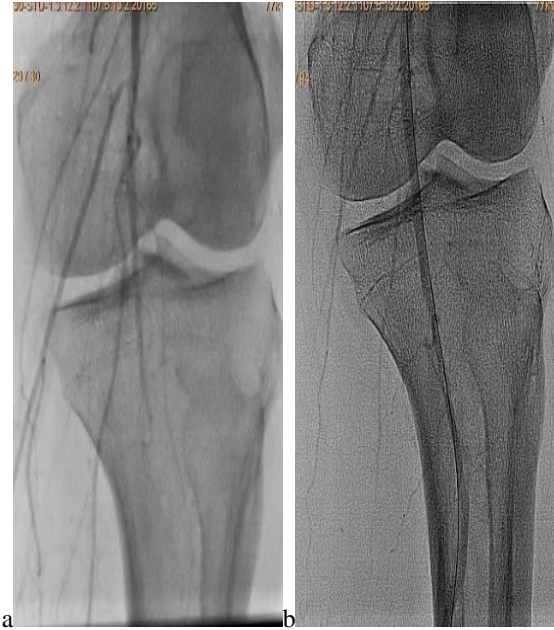
**Fig. (3):** Total Occlusion of P2 segment with runoff to ATA & peroneal artery, A. Successful PTA of the PA & the posterior tibial artery, B.



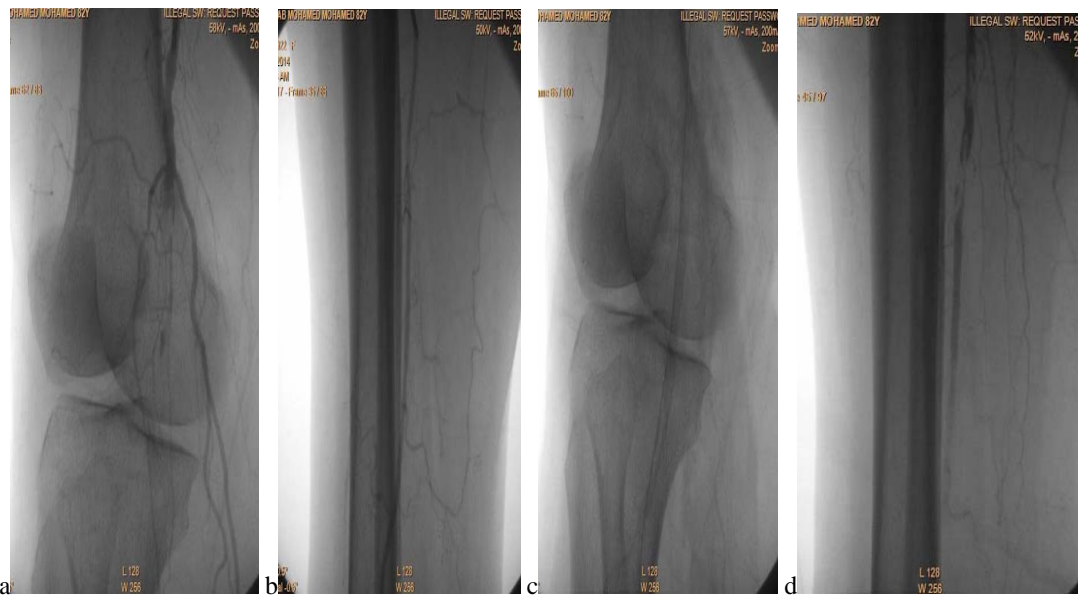**Fig. (4):** Total Occlusion of P2 segment with very poor runoff, A. Successful PTA of the PA & the peroneal artery, B



**Fig. (5):** Total Occlusion of P3 segment, A. Successful PTA with revascularization of PA to both anterior and posterior tibial arteries, B.



**Fig. (6):** Total Occlusion of P3 segment, A. Successful PTA with revascularization of PA to tibioperoneal trunk, B.



**Fig. (7):** Total Occlusion of P1 segment with poor run off, A. Successful recanalization of popliteal & posterior tibial arteries, B. PTA of PA induced dislodgement of thrombus distally. C. Dislodged embolus into posterior tibial artery, D.

Most patients were discharged on the second post-procedure day after receiving instructions on risk factors control and treatment including Aspirin 150 mg/ day and Atrovastatin for life, Clopidogrel 75 mg/ day for at least 3 months. Patients were advised for supervised walking exercise, foot care & protection and proper shoeing. Wound care, debridement and minor amputations were performed whenever indicated before hospital discharge.

Follow up was done at 1, 6, and 12 months after the procedure by clinical and duplex examination. Clinical assessment included relief of ischemic pain, quality of distal pulsations, healing of ulcer &/or amputation stump and resolution of infection.

Any additional endovascular procedures to maintain or restore patency of the vascular channel were recorded, as well as any open surgical revisions, bypasses, and major amputations performed through the follow up period.

## RESULTS

This retrospective study was carried out in Kasr Al-Ainy Teaching Hospitals and included 21 patients (13 males and 8 females) between October 2012 through December 2014. Their age range was 45-82 (mean  $61 \pm 7.9$ ) years. The commonest recorded co-morbidity was ischemic heart disease (IHD) which was found in 20 (95%) cases. Other risk factors included diabetes, hypertension and smoking in 18 (86%), 12 (57%), and 11 (52%) patients, respectively. Variable degrees of severe ischemia were the indication for intervention in all patients: Rutherford class 3 in 4, class 4 in 8, class 5 in 3 and class 6 in 6 patients.

All lesions were denovo total occlusive in nature. Patient demographics, underlying clinical features, and lesion distribution & characters are listed in Table-1.

**Table-1 Patient demographics and base line clinical features**

Patients total number	21 (100%)
Gender: Male/Female	13 (62%)/8 (38%)
Age range (years), Mean $\pm$ SD*	45-82, $61 \pm 7.9$
IHD	20 (95%)
Diabetes mellitus	18 (86%)
Hypertension	12 (57%)
Smoking	11 (52%)
Severity of ischemia	
- Rutherford class 3	4 (19%)
- Rutherford class 4	8 (38%)
- Rutherford class 5	3 (15%)
- Rutherford class 6	6 (28%)
PA segment involved :	
- P1	7
- P2	8
- P3	13
Associated lesions	
- Iliac	1
- SFA	9
- Tibioperoneal	8
Run-off vessels	
- 2-3 (good)	11
- 0-1 (Poor)	10

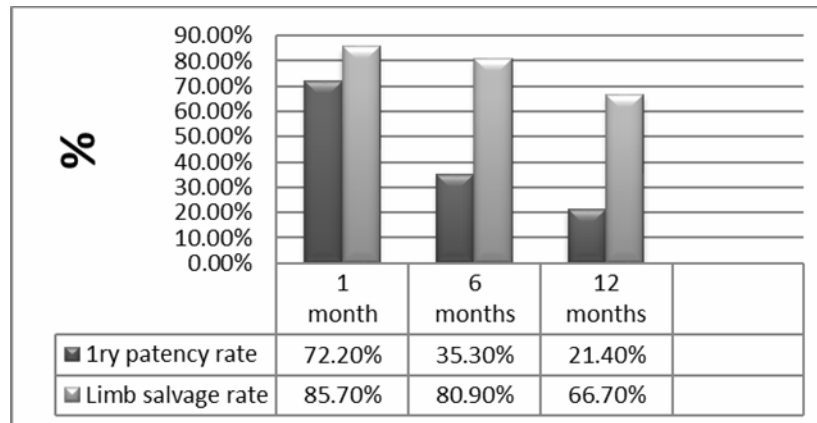
An ipsilateral CFA access was done in the majority of cases n. 16 (76.1%), while a contralateral CFA was used in the remainder to tackle associated iliac or proximal SFA lesions in 1 and 4 cases respectively. Immediate angiographic success was achieved in 19 cases with restoration of pedal pulsations in 13 cases. Figures 1-6 show recanalization of PA occlusions to at least one of the tibial vessels.

Failure to cross the lesion occurred in two cases one of them subsequently had an above knee amputation and the other one had open surgical revascularization because of distal thrombo-embolization into posterior tibial artery (Figure 7). Complications occurred in the form of groin hematoma that required open surgical evacuation and repair. However, the patient died two weeks later because of myocardial infarction. Further management in the form of minor amputation was done for five cases. Procedure details and outcome are shown in Table-2.

**Table-2: Procedure details and outcome**

Parameter	Number
Access (Puncture) site	
- Ipsilateral CFA	16
- Contralateral CFA	5
Diameters of the balloon used	
- 3mm	21
- 4mm	21
- 5mm	7
Successful recanalization	19
Pedal pulse restoration	13
Minor amputations	5
Complications	
- Groin hematoma (open repair)	1
Failure of recanalization	2
- Major amputation	1
- Femoro-distal bypass	1

After one month, the results of follow up were the same as immediate outcome after intervention. At six months follow up, one case was lost. Six cases still had their pedal pulses with primary patency rate 6/17 (35.3%). At one year follow up, a case had spreading gangrene necessitating above knee amputation and two cases were lost in follow up. The primary patency rate was 3/14 (21.4%) as three cases remained preserving their pedal pulse. However, limb salvage rate at the same follow up intervals was 85.7%, 80.9%, and 66.7% respectively. Follow up results at 1, 6 and 12 months are shown in Figure 8.

**Figure 8:** 1<sup>st</sup> patency & limb salvage rates at 1,6, and 12 months

## DISCUSSION

The number of endovascular procedures performed for the treatment of symptomatic PAD has been progressively increasing over the last two decades. Such procedures have significantly replaced conventional surgical solutions in many iliac and SFA lesions.<sup>10</sup> However, the role of PTA in revascularization of PA lesions remains controversial, as there is no consensus on the optimal form of intervention used in this arterial segment.<sup>11-13</sup>

The pattern of “long occlusive” rather than “short stenotic” lesions commonly encountered in the femoropopliteal portion, the fear of PA dissection (being the channel to tibial arteries

supplying the leg & foot), and the characteristic relation of the PA to the knee joint are all factors that traditionally thwart the temptation to endovascular intervention of the PA. These are particularly true especially if the lesion belongs to an advanced TASC grade.<sup>14</sup> However, open surgery poses higher morbidity especially in high risk patients with poor distal run off. In addition, several reports have shown that PTA rarely jeopardizes subsequent surgery and the lower patency rates following PTA in comparison to surgery are not necessarily followed by inferior limb salvage. In other words, the outcome of patients who had bypass surgery after a previous PTA did not differ from those who underwent surgery first.<sup>15</sup>

Primary patency rates at 1-year following PTA in the PA segment varies greatly from 22 to 81%. The wide diversity among the published results is due to differences in criteria used to denote success, patients' demographics and the types of lesions treated.<sup>9, 12</sup> In this study, IHD (95% of patients) could have affected rethrombosis due to low cardiac reserve while diabetes (86% of patients) could be claimed as a risk factor of disease progression.

The role of PTA in treating intermittent claudications due to PA occlusive disease is another debatable issue as some authors did not find valid consensus regarding the use of popliteal angioplasty to treat claudication,<sup>8,16</sup> while others concluded immediate improvement of symptoms after a successful angioplasty especially in short single lesions.<sup>17</sup>

To date, a wide variation in success rates has been reported for endovascular techniques on dealing with chronic total occlusion rather than stenotic lesions with the likelihood of better success rates in the latter.<sup>18,19</sup> Subintimal recanalization with distal reentry has been proposed as a solution for the inability to achieve true luminal crossing of occluded vessels, particularly in long and complex lesions with success rates ranging from 74% to 92%.<sup>20-23</sup> However, the ability to re-enter the true lumen of the target vessel remains a limitation. Uncontrolled guide wire advancement distal to the target lesion can be relatively unpredictable and reentry may occur distal to significant collaterals jeopardizing the distal perfusion. In this study, all patients had total occlusions in which 90.4% could be safely recanalized. We did not use any reentry device, only the angled tip catheter was exploited to direct the tip of the guidewire into the true lumen.

The overall success rates have shown to be superior in patients having better run off. In this context, previous reports have concluded that initially successful cases had better long term follow up patency rates in patients who had better runoff at the time of PTA than in those with poor runoff.<sup>24-26</sup> These reports conform to our results. We found that both patency and limb salvage were much better in 11 (52.3%) patients who had good distal run off at the time of revascularization.

Some reports have advocated that no significant difference could be recognized in

primary patency between patients who received balloon angioplasty alone and those treated with balloon angioplasty and stenting. Others concluded lower secondary patency in the stent group because of high risk of in-stent restenosis whenever a stent is deployed in a joint area. In other words, the majority of authors have advocated balloon angioplasty alone as a safer choice on dealing with PA lesions; others have championed either selective or primary stenting of these lesions.<sup>4,5,13</sup> We did not use stents in our study because we did not have residual stenosis more than 30% and no flow limiting dissection. Stringent reduction of trauma to the artery being treated decreased the number of potential flow limiting dissection near to nil. This was achieved through the use of undersized balloon keeping its inflation pressure at the nominal pressure value. Moreover, when a dissection was encountered prolonged balloon inflation, for three minutes, (sometimes with balloon one millimeter less than the initially used one) sufficed in all cases.

In our study, the primary patency rate after 1 year were inferior to the reported patency rates after surgical revascularization in similar patients concluded in previous reports.<sup>27-29</sup> However, the limb salvage rate was not far below corresponding rates especially when considering the high percentage of poor surgical risk patients with poor distal run off included in this study. Moreover, our results have shown high technical success rate, no major periprocedural complications, there was no need for further intervention in patients who continued their follow up.

## CONCLUSION

Although technically demanding, PTA can be considered as a feasible and safe option for revascularization of total occlusive lesions of the PA. The relatively mid-term low patency rates should not preclude the advantage of buying time for achieving limb salvage in poor surgical risk patients.

## REFERENCES

1. Morris-Stiff G, Ogunbiyi S, Rees J, Davies CJ, Hicks E, Lewis MH. Variations in the anatomical distribution of peripheral vascular disease according to gender. *Ann R Coll Surg Engl.* 2011; 93(4):306-309.



2. Zeller T. Current state of endovascular treatment of femoro-popliteal artery disease. *Vasc Med.* 2007; 12(3):223-234.
  3. Osamu Iida. Current Status and Limitations in the Treatment of Femoropopliteal In-Stent Restenosis. *VASCULAR DISEASE MANAGEMENT* 2015; 12(9):E161-E165.
  4. Dalainas I, Nano G. Balloon angioplasty or nitinol stents for peripheral-artery disease. *New Engl J Med.*2006; 355:521.
  5. Rastan A, Krankenberg H, Baumgartner I, Blessing E, Müller-Hülsbeck S, Pilger E, Scheinert D, Lammer J, Beschorner U, Noory E, Neumann FJ, Zeller T. Stent placement vs. balloon angioplasty for popliteal artery treatment: two-year results of a prospective, multicenter, randomized trial. *J Endovasc Ther.* 2015 Feb; 22(1):22-7.
  6. Taylor SM, Kalbaugh CA, Blackhurst DW, Cass AL, Trent EA, Langan EM 3rd, Youkey JR: Determinants of functional outcome after revascularization for critical limb ischemia: an analysis of 1000 consecutive vascular interventions. *J Vasc Surg* 44:747–755, 2006.
  7. Wolfle KD, Bruijnen H, Loeprecht H, Rumenapf G, Schweiger H, Grabitz K, Sandmann W, Lauterjung L, Largiader J, Erasmi H, Kasprzak PM, Raithel D, Allenberg JR, Lauber A, Berlakovich GM, Kretschmer G, Hepp W, Becker HM, Schulz A: Graft patency and clinical outcome of femorodistal arterial reconstruction in diabetic and non-diabetic patients: results of a multicentre comparative analysis. *Eur J Vasc Endovasc Surg* 25:229–234, 2003.
  8. Abdul Raouf A, Rouleau Y, Clement A, Le Roux P, Genay P and Ricco J. (2005): Endoluminal Angioplasty of the Popliteal Artery. Review of 54 Consecutive Patients. *Eur J Vasc Endovasc Surg* 30, 610–3.
  9. Karch L, Mattos M, Henretta J, McLafferty R, Ramsey D, Hodgson K. Clinical failure after percutaneous (2000): Transluminal Angioplasty Of The Superficial Femoral And Popliteal Arteries. *J Vasc Surg*; 31:880–7.
  10. Henry M, Amor M, Ethevenot G, Henry I, Amicabile C, Beron R et al. (1995): Palmaz Stent Placement In Iliac And Femoropopliteal Arteries: Primary And Secondary Patency In 312 Patients With 2–4 Year Follow-Up. *Radiology*; 197:167–74.
  11. David D. Dearing, Kaushal R. Patel, John M. Compoginis, Mary A. Kamel, Fred A. Weaver, Steven G. Katz (2009). Primary stenting of the superficial femoral and popliteal artery. *J Vasc Surg*; 50(3):542-7.
  12. Soga Y, Tomoi Y, Sato K (2013): Clinical Outcome After Endovascular Treatment For Isolated Common Femoral And Popliteal Artery Disease. *Cardiovasc Interv and Ther*; 28:250–7.
  13. Dierk Scheinert, Martin Werner, Susanne Scheinert, Anett Paetzold, Ursula Banning-Eichenseer, Michael Piorkowski, Matthias Ulrich, Yvonne Bausback, Sven Bräunlich, Andrej Schmidt. Treatment of Complex Atherosclerotic Popliteal Artery Disease With a New Self-Expanding Interwoven Nitinol Stent 12-Month Results of the Leipzig SUPERA Popliteal Artery Stent Registry. *J Am Coll Cardiol Intv.* 2013;6(1):65-71. doi:10.1016/j.jcin.2012.09.011.
  14. Tamashiro GA, Tamashiro A, Villegas MO, Dini AE, Mollón AP, Zelaya DA, Soledispa-Suarez CI, Díaz JA. Flexions of the popliteal artery: technical considerations of femoropopliteal stenting. *J Invasive Cardiol.* 2011 Oct;23(10):431-3.
  15. AK Ah Chong, CB Tan, Maket WC Wong, Florence SK Cheng. Bypass surgery or percutaneous transluminal angioplasty to treat critical lower limb ischaemia due to infrainguinal arterial occlusive disease? *Hong Kong Med J* 2009;15:249-54.
  16. Perkins J, Collin J, Creasy T, Fletcher E, Morris P (1996): Exercise Training Versus Angioplasty For Stable Claudication. Long And Medium Term Results Of A Prospective, Randomised Trial. *Eur J Vasc Endovasc Surg*;11:409–13.
  17. Whyman M, Fowkes F, Kerracher E, Gillepsie I, Housley E, Ruckley C (1996): Randomised Controlled Trial Of Percutaneous Transluminal Angioplasty For Intermittent Claudication. *Eur J Vasc Endovasc Surg*; 12:167–72.
  18. Alback A, Biancari F, Schmidt S, Mikkola P, Kantonen I, Matzke S et al. (1998): Haemodynamic Results Of Femoropopliteal Percutaneous Transluminal Angioplasty. *Eur J Vasc Endovasc Surg*; 16:7–12.
  19. Strecker E, Boos I, Go'ttmann D, Vetter S, Haase W. (2001): Popliteal Artery Stenting
-



- Using Flexible Tantalum Stents. *Cardiovasc Intervent Radiol*; 24:168–75.
20. Bolia A, Brennan J, Bell PR. Recanalisation of femoro-popliteal occlusions: improving success rate by subintimal recanalisation. *Clin Radiol*. 1989;40:325–332.
  21. Markose G, Bolia A. Subintimal angioplasty in the management of lower limb ischaemia. *J Cardiovasc Surg (Torino)*. 2006;47:399–406.
  22. Ko YG, Kim JS, Choi DH, et al. Improved technical success and midterm patency with subintimal angioplasty compared to intraluminal angioplasty in long femoropopliteal occlusions. *J Endovasc Ther*. 2007;14:374–381.
  23. Thomas Zeller, Antonio M. Kambara, Samuel M. Moreira, Eliyahu Atar, Alexander Chulsky, Yoav Turgeman, Sebastian Sixt, Gunnar Tepe, Aljoscha Rastan, and Maurice Buchbinder. Recanalization of Femoropopliteal Chronic Total Occlusions Using the ENABLER-P Balloon Catheter System. *J Endovasc Ther* 2012; 19:131–139.
  24. Johnston KW. Femoral and popliteal arteries: reanalysis of results of balloon angioplasty. *Radiology*. 1992 Jun; 183(3):767-71.
  25. Treiman S, Treiman L, Ichikawa L, Van Allan R (1995): Should Percutaneous Transluminal Angioplasty Be Recommended For Treatment Of Infrageniculate Popliteal Artery Or Tibioperoneal Trunk Stenosis? *J Vasc Surg*; 22:457-65.
  26. Vogel T, Dombrovskiy V, Carson J, Graham A (2011): In-Hospital And 30-Day Outcomes After Tibioperoneal Interventions In The US Medicare Population With Critical Limb Ischemia. *J Vasc Surg*.; 54:109–15.
  27. Joe Feinglass, William H. Pearce, Gary J. Martin, James Gibbs, Diane Cowper, Mark Sorensen, Shukri Khuri, Jennifer Daley, William G. Henderson (2001). Postoperative and amputation-free survival outcomes after femorodistal bypass grafting surgery: Findings from the Department of Veterans Affairs National Surgical Quality Improvement Program. *J Vasc Surg*.; 34 (2) : , 283-290.
  28. E Ducasse, J Chevalier, E Chevier, G Forzyc, F Speziale, E Sbarigia, P Fiorani, P Puppinc (2004). Patency and Limb Salvage after Distal Prosthetic Bypass Associated with Vein Cuff and Arteriovenous Fistula. *Eur J Vasc Endovasc Surg*; 27 (4): 417–422.
  29. Byrne J, Darling R, Chang B, Paty P, Kreienberg P, Lloyd W et al. (1999): Infrainguinal Arterial Reconstruction For Claudication: Is It Worth The Risk? An Analysis Of 409 Procedures. *J Vasc Surg*; 29:259–69.
-