

VOLUME 51

NO. 1

January-March 2016

ISSN - 1110 - 1148



# The Egyptian Orthopaedic Journal



Medknow

 Wolters Kluwer

---

**PUBLISHED BY  
THE EGYPTIAN ORTHOPAEDIC ASSOCIATION**

# Time to union and functional outcome following minimally invasive plating of extra-articular fractures of the distal tibia

Walid El-Nahal, Sherif A. Khaled, Wael Koptan, Ahmed Galal

Department of Orthopedics, Kasr Al-Ainy Hospital, Cairo University, Cairo, Egypt

Correspondence to Sherif A. Khaled, MD, 18 Omar Ibn El Khattab St, Dokki, Giza, Egypt.  
Tel: +20 3742 0049/20 2795 0027/20 2792 6690/20 2795 6339;  
e-mail: sherifakhaled@yahoo.com

Received 3 April 2016

Accepted 23 May 2016

The Egyptian Orthopaedic Journal  
2016, 51:85–89

## Background

Treatment of distal tibial fractures is often challenging and fraught with complications. Minimally invasive plating is thought to overcome complications associated with open plating and intramedullary fixation in the distal third of the tibia.

The aim of this study was to evaluate the use of minimally invasive plating in extra-articular fractures of the distal tibia regarding time to union, functional outcome, and complications.

## Patients and methods

Thirty consecutive patients with extra-articular fractures involving the distal third of the tibia were classified according to the Muller-Arbeitsgemeinschaft für Osteosynthesefragen (AO) classification and treated with minimally invasive plating using the anatomical distal plate. In nine cases, the locked anatomical distal plate was used, whereas in 21 cases the conventional nonlocked anatomical distal plate was used.

Patients were followed up at 2 and 6 weeks postoperatively and then every 6 weeks with a mean follow-up time of 30 weeks (range: 18–94 weeks), in which time to union and complications were documented. Functional outcome was assessed using the American Orthopedic Foot and Ankle Society ankle scoring system at a minimum of 12 weeks from the start of weight-bearing.

## Results

All cases showed union at a maximum of 16 weeks, except four cases: two had delayed union, one had plate failure that ended in deep infection, and there was a case of nonunion. Overall, the mean time to union was 17 weeks (range: 6–60 weeks). The American Orthopedic Foot and Ankle Society ankle scoring system scored an average of 92.4 points (range: 72–100 points).

## Conclusion

This technique minimizes the soft-tissue complications and provides a good functional outcome for patients with extra-articular distal tibial fractures within a reasonable period of time.

## Level of evidence

The present study was a level IV case series.

## Keywords:

extra-articular distal tibial fractures, minimally invasive plating, minimally invasive percutaneous plate osteosynthesis, tibial fractures

Egypt Orthop J 51:85–89

© 2016 The Egyptian Orthopaedic Journal  
1110-1148

## Introduction

Because of better understanding of the complexity of fracture healing, new techniques favoring biology over rigid fixation have been developed. The bridge plate and the limited contact-dynamic compression plate were introduced to apply the principles of biological plate fixation, taking advantage of biological support from bone and soft tissues that is still present after injury.

Furthermore, ‘minimally invasive percutaneous plate osteosynthesis’ (MIPPO) has been introduced to utilize all the recent developments in biological fixation. MIPPO involves inserting a plate in a subcutaneous extraperiosteal tunnel, bridging the

fracture site, which is then secured proximal and distal to the fracture zone.

The MIPPO techniques have been successfully performed in different fracture sites including the distal tibial region. This is because both intramedullary nailing and open plating in this region is often challenging and fraught with complications. Hence, the need for a reliable technique with better outcome [1–3].

This is an open access article distributed under the terms of the Creative Commons Attribution-NonCommercial-ShareAlike 3.0 License, which allows others to remix, tweak, and build upon the work noncommercially, as long as the author is credited and the new creations are licensed under the identical terms.

The purpose of this study was to evaluate the technique of MIPPO in the treatment of extra-articular distal tibia fractures regarding time to union, complications, and functional outcome using the American Orthopedic Foot and Ankle Society (AOFAS) ankle score [4].

### Patients and methods

This prospective study involved 30 consecutive patients – 20 men and 10 women – with extra-articular distal tibial fractures attending the Emergency Department of Cairo University Hospitals between December 2010 and March 2012. Mean patient age was 35.4 years. All patients had closed fractures. Twenty-one patients were subjected to high-energy trauma including motor vehicle accidents and road traffic accidents. Nine patients were subjected to low-energy trauma including falls to the ground and fall downstairs (Table 1). Fractures were classified according to the Orthopedic Trauma Association's classification [5] into the following: 4–3, which refers to distal tibia metaphyseal fractures (20 cases), and 4–2, which in this study refers to fractures of the distal third of the tibia (10 cases) but not extending to the metaphyseal region (Table 1). The authors operated upon all cases. Patient demographics are illustrated in Table 1.

**Table 1 Patient demographics**

Mean age	35.4
Youngest	16
Eldest	53
Male to female ratio	2:1
Male	20
Female	10
Mechanism of injury	
High-energy trauma	21 (70%)
Motor vehicle accident	19
Road traffic accident	3
Low-energy trauma	9 (30%)
Fall to the ground	8
Fall downstairs	1
Associated injuries	5 (16.7%)
Ipsilateral femur	1
Contralateral tibia	1
Humerus	1
Head injury	1
Contralateral ankle fracture	1
Fracture site	
Distal tibial metaphysis (4–3)	20 (33.3%)
Distal third of tibial shaft (4–2)	10 (66.7%)
Fracture classification	
42A2	6
42B3	2
42C3	2
43A1	14
43A2	4
43A3	2

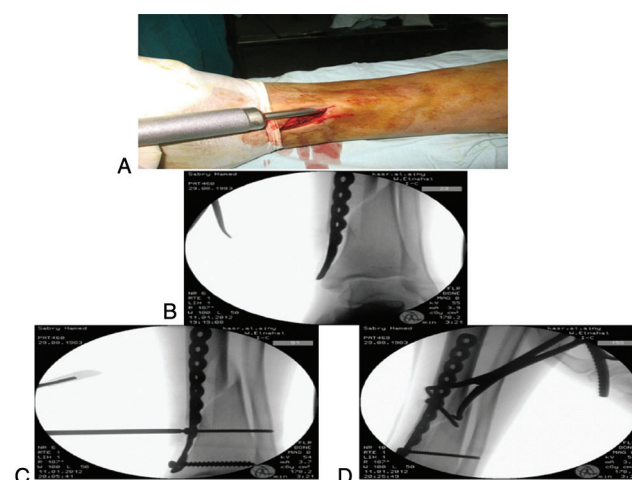
### Operative technique

Patients were operated upon under regional anesthesia on a standard radiolucent orthopedic table. One gram of third generation cephalosporin was given with induction of anesthesia. A pneumatic tourniquet was inflated on the thigh except in the case with an ipsilateral femoral fracture. Patients were positioned supine on the operative table.

A 4 cm curved anteromedial incision was centered over the medial malleolus. Afterwards, a subcutaneous extraperiosteal tunnel was created using a Cobb dissector, through which a plate was then introduced taking care not to damage the periosteum and choosing an appropriate plate size with the aid of an image intensifier (Fig. 1). Reduction was carried out utilizing the anatomical configuration of the plate; thus the plate itself acted as a reduction mold. The most distal screw was inserted first, followed by a second screw just distal to the fracture site. This screw was often longer than the desired length and could be exchanged to an appropriate size after the plate was fixed. This screw helped in fracture reduction by using the anatomical configuration of the plate. If more reduction was still needed, it was achieved percutaneously using a reduction forceps. A lag screw was inserted if the fracture configuration allowed it, which was possible in five patients.

A conventional distal tibial plate was used for 21 patients and a locked distal tibial plate was used for nine patients.

**Figure 1**



(a) A 4-cm incision and a Cobb dissector to create a subcutaneous extraperiosteal tunnel. (b) Checking plate position and size. (c) Inserting most distal screw followed by a distal screw near the fracture site. (d) Better reduction by aid of the reduction forceps and a lag screw inserted percutaneously.

### Follow-up and evaluation

Average postoperative hospital stay was 2 days. Routine postoperative antibiotic prophylaxis and deep vein thrombosis (DVT) prophylaxis were administered. Injured extremity was splinted in a below-knee back slab for 2 weeks, and then removed, after which the patients were instructed to start a range of motion exercises. Follow-up was scheduled at 2 and 6 weeks, and then every 6 weeks. Mean patient follow-up was 30 weeks (range: 18–94 weeks). Patients were assessed for wound condition, radiological healing, and range of motion on each visit. Weight-bearing was instructed after full radiological healing. Final patient assessment and evaluation using the AOFAS ankle scoring system [4] were carried out 12 weeks after commencing full weight-bearing (minimum: 18 weeks postoperative).

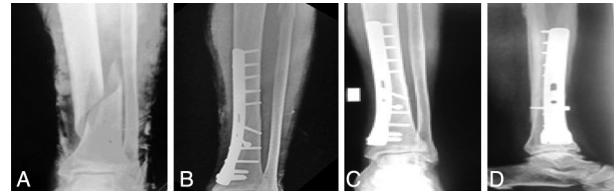
### Statistical analysis

Data were statistically described as mean and percentage when appropriate. Comparison of numerical variables between the study groups was carried out using the Mann–Whitney *U*-test for independent samples when comparing between two groups. When comparing between more than two groups, the Kruskal–Wallis test was used. Correlation was determined using the Spearman rank correlation equation. A *P*-value less than 0.05 was considered statistically significant. All statistical calculations were carried out using the computer program statistical package for the social sciences (SPSS, version 15 for Microsoft Windows; SPSS Inc., Chicago, Illinois, USA).

### Results

Union was defined as full radiological and clinical union, evident by bridging callus, absence of fracture line, and full weight-bearing (Fig. 2). All cases showed union by 16 weeks, except four cases: two had delayed union, one had plate failure that ended in deep infection, and there was a case of nonunion. Overall, the mean time to union was 17 weeks (range: 6–60 weeks). Patients subjected to high-energy trauma showed a mean of 16.1 weeks to union, whereas those subjected to low energy showed a mean of 19.3 weeks to union ( $P=0.78$ ). There was no significant difference regarding the fracture site and/or configuration to the time to union. A lag screw was inserted in five cases; the mean time to union in fractures with a lag screw was 12 weeks compared with a mean time of 18 weeks in the fractures in which we did not use a percutaneous lag screw ( $P=0.1$ ). The conventional distal tibial plate

Figure 2



Forty-five-year-old man, motor vehicle accident, 42-A1 fracture: (a) preoperative radiographs. (b) Postoperative after fixation with a conventional distal tibial plate and a percutaneous lag screw. (c, d) 10 weeks postoperative with absence of fracture line; the patient was instructed to start full weight-bearing.

showed a faster time to union (mean: 16.4 weeks) compared with locked plates (mean: 18.4 weeks) ( $P=0.5$ ; Table 2).

The AOFAS score was obtained at a minimum of 12 weeks after start of full weight-bearing. The mean score was 92.4 points (range: 72–100 points).

Complication rate was 12% (four cases). Three cases that did not show union at 16 weeks were first treated conservatively. Two of them healed at 24 weeks; the third case required bone grafting and showed full union at 60 weeks. One case suffered deep infection following revision surgery, which was done due to plate failure. This case required plate removal and application of an external fixator; his final score was 90 at 42 weeks.

### Discussion

The purpose of the MIPPO technique is to avoid endangering the rich extra-osseous blood supply in the metaphyseal region of the distal tibia, thus achieving a faster time to union and a better functional outcome compared with open plating in this region [3,6].

#### Time to union

In our study, conducted on 30 patients, all cases showed union at a mean of 17 weeks (range: 6–60 weeks). These results are similar to those obtained by Oh *et al.* [7], who, in 2003, reported a mean time to union of 15.2 weeks (range: 12–30 weeks) in 20 patients using contoured limited contact–dynamic compression plate. In addition, in 2004, Redfern *et al.* [8] reported a mean of 23 weeks (range: 18–29 weeks) to union with no complications in 20 patients with closed fractures of the distal tibia, which was compatible with our results. Collinge *et al.* [9] reported a longer mean time to union of 35 weeks (range: 12–112 weeks) in 26 patients with high-energy distal tibial metaphyseal fractures, as their series included open and closed fractures with high soft-tissue injuries, which were not included in ours.

**Table 2 Results**

Variables	Number of patients	Minimum time to union	Maximum time to union	Mean time to union	P-value	AOFAS score	P-value
Female	10	12	60	18.20	0.75	90	0.24
Male	20	6	36	16.50		93.7	
Trauma							
High-energy trauma	21	6	36	16.10	0.78	93	0.7
Low-energy trauma	9	12	60	19.33		97	
Site of fracture							
Metaphyseal 4–3	20	10	60	19.00	0.96	91.3	0.7
Distal third 4–2	10	6	36	16.10		93	
Lag screw insertion							
No	25	6	60	18.00	0.1	92.6	0.61
Yes	5	10	14	12.40		91.6	
Fracture classification							
A1	14	6	20	13.86	0.56	93.5	0.81
A2	10	10	60	21.60		89.4	
A3	2	16	28	22.00		95	
B3	2	14	16	15.00		95	
C3	2	12	16	14.00		95	
Associated injuries							
None	25	6	60	17.20	0.39	92.8	0.49
Yes	5	10	20	16.40		90.6	
Implant used							
Distal tibial plate	21	6	36	16.4	0.54	93.7	0.4
Locked distal tibial plate	9	12	60	18.4		89.5	

AOFAS, American Orthopedic Foot and Ankle Society.

On the other hand, Collinge and Protzman [10] reported a mean of 21 weeks (range: 9–60 weeks) in 38 patients with distal tibial low-energy metaphyseal fractures, which we found to be compatible with our results. Ahmad *et al.* [11] retrospectively reviewed 18 patients with distal tibial metaphyseal fractures treated with locked distal tibial plates and reported a rather lengthy average time to union of 23.1 weeks (range: 8–56 weeks), although the technique used by Ahmad *et al.* [11] appeared to be the same as ours, and yet we believe the discrepancy was due to the complexity of the fracture in their series and due to a rather smaller sample size. However, with time to union varying from one study to another, we believe MIPPO still provides a faster time to union than does open plating. In their study, Yang *et al.* [12] reported an average of 27.8 weeks (range: 18–36 week) in 14 patients with 43A distal tibial fractures managed by using the open plating technique.

#### Functional outcome

Oh *et al.* [7] used the Olerud and Molander ankle score [13] to assess the functional outcome, which for all patients ranged from 80 to 100%. Ahmad *et al.* [11] reported an average AOFAS ankle score of 88.8. Collinge *et al.* [9] reported an average AOFAS ankle score of 83 (range: 65–100) [9]. In our study, the 21 high-energy injuries united with a mean of 16.1 weeks (range: 6–36 weeks). Their AOFAS ankle score showed a mean

of 93. However, our study did not include open injuries, which was in contrast to the findings of Collinge *et al.* [9]. The difference in functional outcome and time to union demonstrates the importance of the soft tissues in the MIPPO technique.

#### Complications

One case showed nonunion at 6 months and required bone grafting, mainly because of improper reduction; a malrotation of 10° was detected in the immediate postoperative radiographs. This case was encountered at the beginning of the series during the inevitable learning curve.

Hasenboehler *et al.* [14] published a series of 32 patients with diaphyseal and distal tibial fractures treated with the MIPPO technique and reported one case of plate bending of more than 18° at 5 months postoperatively because of excessive weight-bearing, for which plate was exchanged. Mushtaq *et al.* [15] reported one patient with implant failure, which was revised and ultimately healed with good functional outcome. We had one case of implant failure; the patient came to us 3 weeks postoperatively, with a 30° bent plate due to excessive weight-bearing against instructions given to him. We had to exchange the plate. He later came with an infected wound and exposed plate; plate removal was carried out and

external fixator was applied. He eventually healed at 28 weeks, and AOFAS score at 42 weeks was recorded as 90.

Hasenboehler *et al.* [14] reported that 29 patients complained of local disturbance over the medial malleolus, which was caused by the high-plate profile. In our study, implant discomfort was not noted, which might be attributed to the use of low-profile plates.

Furthermore, this surgical procedure was performed through closed reduction, thus increasing the risk for intraoperative fluoroscopic radiation exposure. Proper means of radiation protection should be available. As the learning curve continues to rise the operative time, radiation exposure was minimized. However, an average of 60 images was taken by the image intensifier in each case.

In this study, we utilized the standard operative table, which necessitated the presence of an extra assistant to maintain reduction. We also used devices like the bone clamp to facilitate reduction. The anatomical plate itself was used as a mold. Percutaneous lag screws were applied whenever the fracture configuration allowed its insertion. This technique was described in most of the series we reviewed [7,11]. Other techniques described included the application of a temporary external fixator or a femoral distractor to maintain and aid reduction while applying the plate [16]. This technique was used by Collinge and Protzman [10] and Collinge *et al.* [9] in their respective series. Other tools have also been used, such as a tibial alignment grid to help check the alignment intraoperative and a tunnel to help create a subcutaneous extraperiosteal tunnel without injuring the periosteum [17].

## Conclusion

Out of the fractures managed by this method, most of them showed uncomplicated healing within a reasonable period of time. Functional assessment using the AOFAS scoring system showed excellent outcomes. The complication rate was considered minimal.

The MIPPO method could be used safely in the management of distal tibial fractures. The procedure, however, is technically demanding, requiring the availability of appropriate tools and surgical implants. Careful follow-up of the patients is recommended. This technique, as confirmed by our results, minimizes the complication rate, promotes

union within a reasonable period of time, and facilitates early return to normal activities for the patient.

Although the MIPPO technique is widely accepted nowadays, a larger multicenter series are still needed to confirm the superiority of the technique over other modalities.

## Financial support and sponsorship

Nil.

## Conflicts of interest

There are no conflicts of interest.

## REFERENCES

- Ruedi T, Buckley RAO. Principles of fracture management. Thieme Medical Publishers; 0002- edition (2007).
- Nikolaou VS, Efsthathopoulos N, Papakostidis C, Kanakaris NK, Kontakis G, Giannoudis PV. Minimally invasive plate osteosynthesis – an update. *Curr Orthop* 2008; 22:202–207.
- Montemurro G, Di Russo L, Vitullo A. Minimally invasive surgery for closed lower limb fractures: past and present experiences with conventional and updated devices in 90 cases. *J Bone Joint Surg Br* 2006; 88:183–1183.
- SooHoo N, Shuler M, Fleming L. Evaluation of the validity of the AOFAS clinical rating systems by correlation to the SF-36. *Foot Ankle Int* 2003; 24:50–55.
- Marsh J, Slongo TF, Agel J, Broderick JS, Creevey W, DeCoster TA, *et al.* Fracture and dislocation classification compendium – 2007: Orthopaedic Trauma Association classification, database and outcomes committee. *J Orthop Trauma* 2007; 21:S1.
- Borrelli JJr, Prickett W, Song E, Becker D, Ricci W. Extraosseous blood supply of the tibia and the effects of different plating techniques: a human cadaveric study. *J Orthop Trauma* 2002; 16:691–695.
- Oh CW, Kyung HS, Park IH, Kim PT, Ihn JC. Distal tibia metaphyseal fractures treated by percutaneous plate osteosynthesis. *Clin Orthop Relat Res* 2003; 408:286–291.
- Redfern DJ, Syed SU, Davies SJ. Fractures of the distal tibia: minimally invasive plate osteosynthesis. *Injury* 2004; 35:615–620.
- Collinge C, Kuper M, Larson K, Protzman R. Minimally invasive plating of high-energy metaphyseal distal tibia fractures. *J Orthop Trauma* 2007; 21:355–361.
- Collinge C, Protzman R. Outcomes of minimally invasive plate osteosynthesis for metaphyseal distal tibia fractures. *J Orthop Trauma* 2010; 24:24.
- Ahmad MA, Sivaraman A, Zia A, Rai A, Patel AD. Percutaneous locking plates for fractures of the distal tibia: our experience and a review of the literature. *J Trauma Acute Care Surg* 2012; 72:E81.
- Yang SW, Tzeng HM, Chou YJ, Teng HP, Liu HH, Wong CY. Treatment of distal tibial metaphyseal fractures: plating versus shortened intramedullary nailing. *Injury* 2006; 37:531–535.
- Olerud C, Molander H. A scoring scale for symptom evaluation after ankle fracture. *Arch Orthop Trauma Surg* 1984; 103:190–194.
- Hasenboehler E, Rikli D, Babst R. Locking compression plate with minimally invasive plate osteosynthesis in diaphyseal and distal tibial fracture: a retrospective study of 32 patients. *Injury* 2007; 38:365–370.
- Mushtaq A, Shahid R, Asif M, Maqsood M. Distal tibial fracture fixation with locking compression plate (LCP) using the minimally invasive percutaneous osteosynthesis (MIPO) technique. *Eur J Trauma Emerg Surg* 2009; 35:59–162.
- Ehlinger M, Adam P, Bonnomet F. Minimally invasive locking screw plate fixation of non-articular proximal and distal tibia fractures. *Orthop Traumatol Surg Res* 2010; 96:800–809.
- Apivatthakakul T, Phornphutkul C, Patumasutra S. Idea and innovation: simple minimally invasive plate osteosynthesis (MIPO) instruments. *Injury Extra* 2009; 40:39–44.