

Experimental Study on the Efficacy of Some Commonly Used Anticoccidial Drugs in Controlling of Coccidiosis with Mixed Field Isolates in Broiler Chickens

¹M.M. Amer, ¹M.H.H. Awaad, ²Nadia M.N. Abo-Elezz, ²Rabab M. El-Khateeb,
³A. Sherein-Said ⁴M.M. Ghetas and ⁴M.A. Kutkat

¹Department of Poultry Diseases, Faculty of Veterinary Medicine, Cairo University, Giza, Egypt

²Department of Parasitology and Animal Diseases,

Veterinary Research Division, National Research Centre, Giza, Egypt

³Department of Pathology, Faculty of Veterinary Medicine, Cairo University, Giza, Egypt

⁴Department of Poultry Diseases, Veterinary Research Division, National Research Centre, Giza, Egypt

Abstract: One hundred, one day- old Cobb broiler chicks were randomly divided to 5 equal (1-5) groups. First four Chickens groups 1-4 were orally infected with 5×10^5 mixed sporulated oocysts per chick at 14th day – old. Group (5) were kept as non infected control. After appearance of signs; groups 1, 2 and 3 were treated with toltrazuril, amprolium and Sulphaquinoxaline (S.Q); respectively; while group (4) was kept as nontreated control. Results revealed that, group treated with toltrazuril showed great improvement in feed intake average; weight gain and food rate conversion as well as high reduction in the number of oocysts. The results of experimentally infected chicks with mixed field Eimerial oocysts showed some sort of drug resistance to S.Q and amprolium. Our study pointed out that; toltrazuril is still more effective than S.Q or amprolium in elimination of *E. oocysts* infection in chickens. Area of drug resistance needs more investigation to explore its magnitude, mode and how to overcome.

Key words: Toltrazuril • Amprolium • Sulphaquinoxaline • Chickens

INTRODUCTION

Control of coccidiosis has relied mainly on the preventative use of anticoccidial drugs (coccidiostats), together with the induction of species-specific natural immunity in chicken flocks [1, 2]. However, this widely used approach is costly and has led to serious problems with drug resistance in *Eimeria* populations [3]. Due to these drug resistance problems, live, virulent vaccines have been utilized to protect chicken flocks against coccidiosis, particularly in intensive establishments [4] and attenuated or precocious live vaccines are now finding wide application [1, 2]. In spite of the advance in immunological, biotechnological and genetically methods, control of coccidiosis still chiefly depends upon prophylactic chemotherapy with anticoccidial drugs [5].

Some authors considered stress factors, as well as Newcastle disease vaccination and overcrowdings as factors increase the severity of coccidiosis [6] and others explained the severity of coccidiosis by the development of drug resistance [7-11].

Emergence of drug resistance in coccidiosis is a great problem with most of the anticoccidial drugs, which limit their use [12-17]. The change in sensitivity has forced the pharmaceutical industries to continuously change the formulation of drugs, which requires at least US\$ 50–100 million for the development of a new drug [18].

From the above mentioned background, the present study was planed to investigate the effect of some anticoccidial drugs on mixed infection in broiler chickens with field isolates.

MATERIALS AND METHODS

Experimental Chicks: One hundred; 1 day old Cobb broiler chicks obtained from a commercial hatchery was used in the current study.

Ration: The chicks were feed on prepared ration according to the National Research Council. Ration without feed additives was given to the chicks *ad libitum*.

Anticoccidial Drugs: The following drugs were used as recommended by the manufacturer.

- Amprolium 20% soluble powder produced by Vetwic Veterinary Division, El Nasr Pharmaceutical Chemicals Co. with batch number 3/741/09. It was given as 1g/ liter of the drinking water for 5 successive days.
- Sulphaquinoxaline (S.Q) Sodium (20%) soluble powder produced by Veterinary Division, El Nasr Pharmaceutical Chemicals co. with batch number 3/753/09. was given as 1 g/ liter of the drinking water for 5 successive days.
- Toltrazuril 2.5% (Deltazuril®) in liquid form produced by Delta Pharma Veterinary Sector, Industrial Zone B4, Batch number 71333, was given at concentration of 7 mg/kg body weight for two successive days.

Eimerial Oocysts: Sporulated oocysts were isolated from field cases and purified. Collected oocysts were sporulated and passed in susceptible chicks 3 times. Virulence of the 3rd passage sporulated oocyst was tested according to Walelzy [19] and McDougald *et al.* [20] Sporulated oocysts were kept in 2.5% potassium dichromate in screw capped bottles at 4-8°C till used for challenge test.

Oocysts Count: Sporulated oocysts was counted/ml by using Mc-Master technique after Maff [21] and Soulsby [22]. Different species of sporulated oocysts were used for experimental infection after Soulsby [22].

Experimental Infection: Each bird of infected and medicated groups was inoculated orally with 0.5 ml solution containing 5×10^5 mixed species of sporulated oocysts on the 14th day of age.

Chicken Performance: Mean body weights gain, feed intake as well as total feed intake were calculated weekly according to Sainsbury [23].

Samples for Oocysts Count: Freshly voided droppings were collected from intestinal and cecal of living; sacrificed or dead chickens and microscopically examined for oocyst count.

Histopathology: Intestinal tissues were fixed for 1-2 hour and washed several changes of 50% alcohol for 4-6 hour and stored in 70% alcohol then washed in 80%, 90%, 95% and absolute alcohol, finally the specimens were embedded in paraffin wax, sectioned and stained with H&E [24].

Lesion Score: Lesion scores were calculated according to the procedure of Johnson and Reid [24].

Experimental Design: One day-old Cobb broiler chicks were obtained from a private commercial hatchery. At the 1st day of life, the used chicks (100) were randomly divided into 5 equal groups (1-5); 20 each.

At the 14th day of life droppings were examined to be confirming it's free from oocysts of Eimeria. Chicks of group (5) were kept as negative control group while chicks of groups 1- 4 were orally inoculated with 0.5 ml containing 5×10^5 mixed sporulated oocysts/ chick.

At the 18th day of age with appearance of clinical signs chicken of Group 1, 2 and 3 were treated with Toltrazuril, Amprolium and S.Q; respectively; while birds of Group (4) were kept as infected control.

All groups were kept under daily observation for signs with collection of dropping for calculation of oocyst. At 0, 7, 14 and 24 days of age, Body weight and feed intake were recorded for calculation of feed conversion rate (FCR).

Two birds from each group were sacrificed at the 5th, 7th and 9th days post infection (dpi) and its intestines were collected for histopathological examination. The obtained results are shown in Tables 1- 4.

RESULTS

Infected birds showed general signs (ruffled feathers; off food; huddling together and loose dropping) on the 4th dpi. Results of the average total feed intake is presented in Table 1. It was found that, Toltrazuril treated group consumed higher ration (718.75 g/ bird) followed by negative control group (714.37 g/bird); S.Q treated group (697.5 g/bird); Amprolium treated group (680.9 g/bird) and finally control positive group (678.13 g/ bird). Average body weight was the best in the negative control group (619.38 g) followed by toltrazuril treated group (618.13 g); S.Q treated group (570.25 g); Amprolium treated group (557.12 g) and control infected non treated group (515.5 g) (Table 1).

Feed conversion rate was the best in control negative group (1.80) followed by toltrazuril treated group 1(1.84) and S.Q treated group 3 (1.86) while Amprolium treated group showed the lowest feed conversion (1.94) followed by that of control infected non treated (2.17) (Table 1).

Average weekly body weight gain in toltrazuril treated group 1 (Table 1) and control negative group 5 were the highest followed by S.Q treated group and Amprolium treated group while the lowest values were in non treated infected control positive group 4.

Table 1: Average body weight, feed intake, feed conversion rate and average weight gain of infected treated and control chicken groups at 1-4 week of age

Group No.	Treatment	Age / days	Average body weight /gm.	Average Feed intake /gm	Feed conversion rate (FCR)	Average weekly weight gain/gm
1	Toltrazuril	0	42.50	-	-	-
		7	99.75	82.00	1.43	57.25
		14	227.50	177.50	1.73	102.81
		24	618.13	718.75	1.84	390.62
2	Amprolium	0	43.07	-	-	-
		7	97.50	82.00	1.51	54.43
		14	206.25	147.50	1.75	84.37
		24	557.12	680.90	1.94	350.93
3	S.Q	0	41.35	-	-	-
		7	96.75	81.50	1.47	55.40
		14	195.25	129.38	1.74	74.31
		24	570.25	697.50	1.86	375.00
4	Control Positive	0	42.09	-	-	-
		7	96.25	77.50	1.43	54.16
		14	203.00	145.94	1.77	82.69
		24	515.50	678.13	2.17	312.50
5	Control Negative	0	41.43	-	-	-
		7	98.75	82.00	1.43	57.32
		14	220.00	169.81	1.76	96.56
		24	619.38	714.37	1.80	396.87

Table 2: The effect of treatment on the body weight (BW), body weight gain (BWG) and relative growth rate (RGR) in infected and treated groups

Item	Group and treatments				
	Gr (1) Toltrazuril	Gr (2) Amprolium	Gr (3) S.Q	Gr (4) Infected non treated	Gr (5) Control negative
Mean W1 (gm)	320.000	310.00	310.000	310.00	332.00
Mean W2 (gm)	618.130	557.12	570.250	515.50	619.38
W2-W1 (weight gain)	298.130	247.12	266.250	205.50	287.38
W2+W1 2	468.065	433.56	441.125	412.75	475.69
RGR	63.550	56.99	59.130	49.78	60.41

W1: Average body weight of each group at 18th day of age

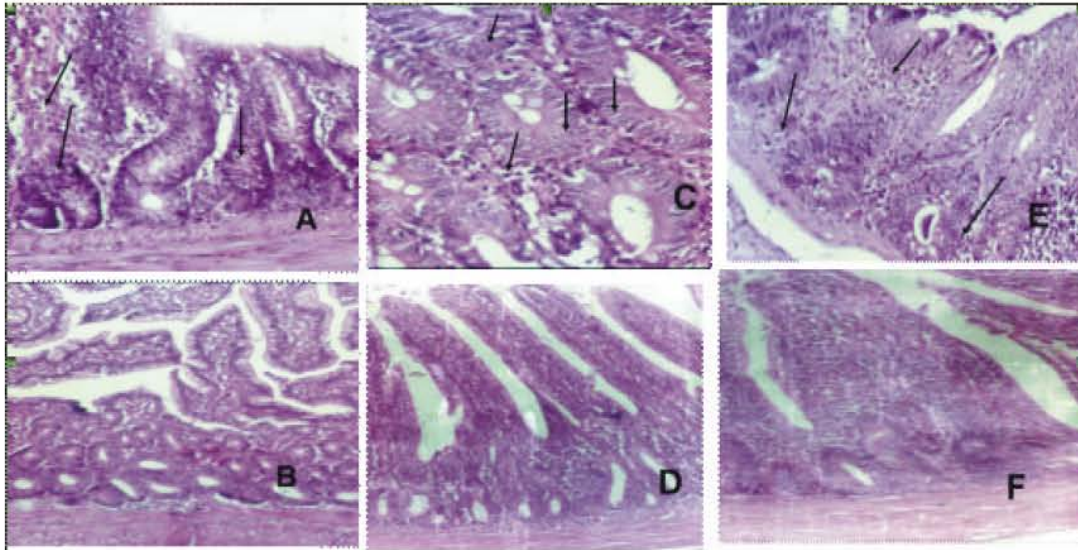
W2: Average body weight of each group at 24th day of age

Table 3: Number of Eimeria oocyst /gm of dropping of infected treated and control groups (X 10³)

Days post infection						Treatment	Infection	Group No.
10	9	8	7.0	6	5			
4	20	38	10.8	4	0	Toltrazuril	+	1
24	6	110	38.0	4	4	Amprolium	+	2
6	60	42	12.6	2	0	S.Q	+	3
30	68	160	138.0	10	4	Infected	+	4
0	0	0	0.0	0	0	Negative	-	5

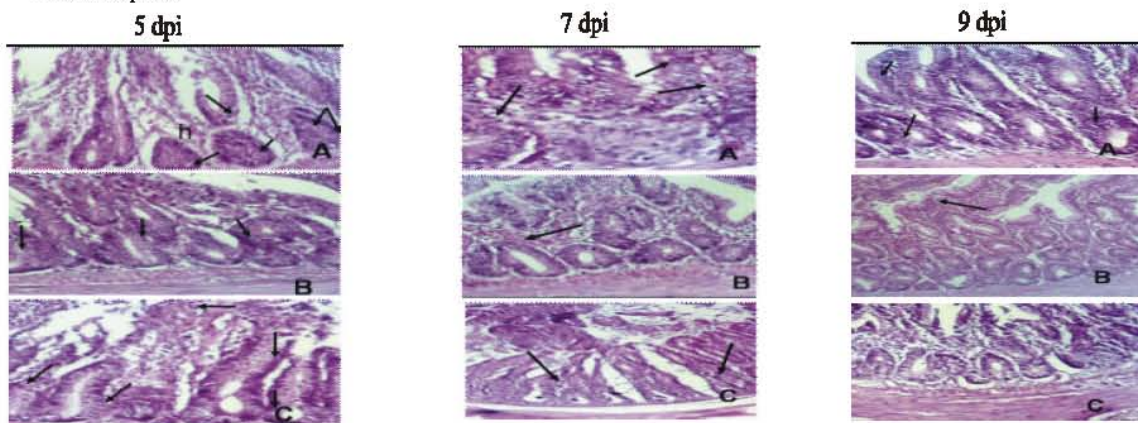
Table 4: Eimeria lesion score in intestinal parts of infected treated and control chicken

Lesion score in intestine							
Caecum	Lower	Mid	Upper	Dpi	Treatment	Gr No.	
1	1	1	1	5	Toltrazuril	1	
1	0	0	1	7			
1	0	0	0	9			
1	1	1	1	5	Amprolium	2	
1	1	1	2	7			
1	1	1	2	9			
1	1	1	1	5	S.Q.	3	
2	1	1	2	7			
2	1	1	2	9			
2	1	1	2	5	Control positive	4	
2	1	1	2	7			
2	1	1	2	9			
0	0	0	0	5-9	Control -ve	5	



A: Infected non treated duodenum: different stages in duodenal crypts an villi (arrows) [x100].
 B: Control negative duodenum: apparently normal mucosa and submucosa [x10].
 C: Infected non treated intestine: different Eimerial stages (arrows) [x200].
 D: control negative intestine: apparently healthy tissues [x100].
 E: Infected non treated caecum: different parasitic stages (arrows) [x100].
 F: Control negative caecum: normal histology of mucosa & submucosa [x100].

Plate 1: Histopathological sections stained with H&E of Eimeria infected nontreated and control negative chicken intestinal parts



A: Toltrazuril treated: Eimerial stages (arrows) and heterophilic infiltration (h) [x200].
 B: Amprolium treated: few parasitic stages (arrows) [x100].
 C: S.Q treated: parasitic stages in mucosa (arrows) [x100].
 A: Toltrazuril treated: parasitic stages (arrows) [x100].
 B: Amprolium treated: slight mucosal hemorrhage (arrow) [x100].
 C: S.Q treated: few parasitic stages (arrows) [x100].
 A: Toltrazuril treated: parasitic stages (arrows) [x100].
 B: Amprolium treated: hemorrhagic mucosa (arrow) [x200].
 C: S.Q treated showing: healthy mucosa [x200].

Plate 2: Histopathological duodenum sections stained with H&E of chicken infected with Eimeria and treated at the 5, 7 and 9th dpi

Our results revealed that good performance in toltrazuril treated and non infected groups from the 18th -24th day of age, followed by S.Q treated and amprolium treated groups, respectively; while infected non treated group showed bad performance parameters.

Toltrazuril treated group showed the highest relative growth rate (RGR) (63.55) followed by negative control (60.41), S.Q treated group (59.13) and Amprolium treated group (56.99). In the other hand RGR of treated group were higher than that of non treated infected group 4 (49.78) Table (2).

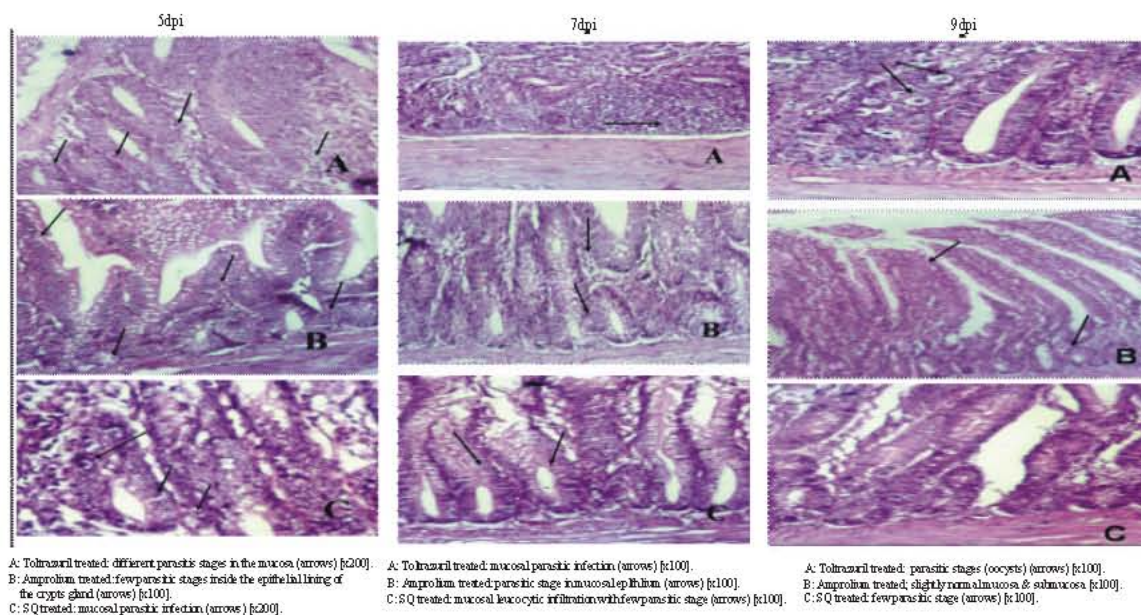


Plate 3: Histopathological sections stained with H&E of intestine of chicken infected with Eimeria and treated at 5, 7 and 9 dpi

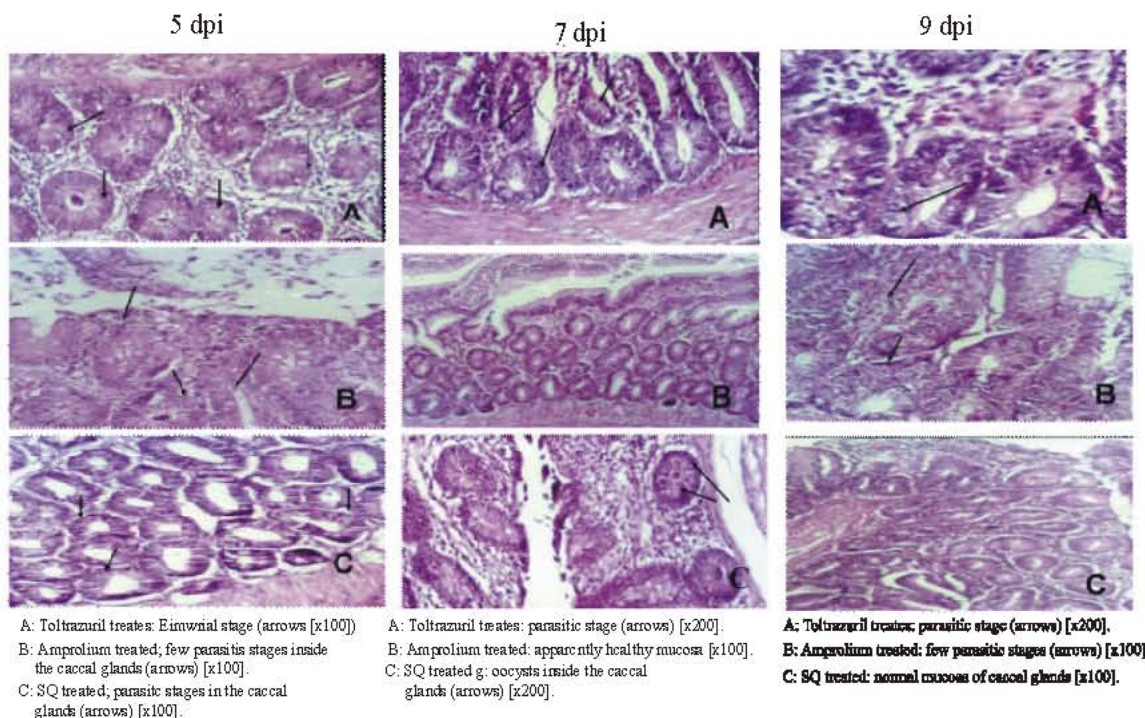


Plate 4: Histopathological sections stained with H&E of chicken caecum infected with Eimeria and treated at the 5, 7 and 9 dpi

No oocyst was detected at 1st day post treatment (dpt) with toltrazuril and S.Q, but in amprolium treated group, the shedding of oocysts was occurred similar to that of non treated control

positive group; and continued higher till 10th dpi. Toltrazuril treated group showed oocyst shedding lower than S.Q treated group from 3rd dpt (7 dpi) till 10 dpi (Table 3).

The effect of different treatments on the lesion score in infected and treated groups was seen in Table 4. No lesions were detected in non infected non treated control group. Highest score lesions were showed in infected non treated control group. Lowest lesion score were showed in Birds that treated with toltrazuril if compared with those treated with Amprolium and S.Q.

Results of histopathological examination showed different parasitic stages in duodenal crypts, villia in duodenal glands and at all intervals post infection of infected nontreated group (Plate 1- A). Also, different parasitic stages were detected in both intestinal and cecal sections (Plate 1- C and E). All examined intestinal parts of non infected control showed apparent normal histological structure. (Plate 1- B, D and F), in comparesion with Amprolium treated group sections had few parasitic stages, slight mucosal hemorrhage and hemorrhagic mucosa free of parasite at the 5th, 7th and 9th dpi; respectively. S.Q treated group showed parasitic stages in mucosal epithelium, few parasitic stages and apparent healthy mucosa at 5, 7 and 9 dpi; respectively. Toltrazuril treated group sections showed parasitic stages and heterophilic infiltration at 5 dpi and few stages at 7 and 9 dpi. (Plates 2,3 and 4). Generally, *Eimeria tenella* more lesion score and histopathological changes were detected in cecum S.Q and Amprolium treated groups.

DISCUSSION

Our field observation suggested the presence of variation in results of usage of anticoccidial drugs. This observation has been reported by many authers [26-31] Accordingly; this work was designed to evaluate the therapeutic efficacy of three commonly used anticoccidial drugs for controlling coccidial infection in Broiler chicks. Bedrnik [32] has established that a reduced efficacy of an anticoccidial always has an adverse effect on weight gain and/or on the feed conversion. These factors play a decisive part in practice, since they determine the economic success of the operation. Oocyst excretion alone is insufficient to assess the efficacy of anticoccidial drugs and indeed it is misleading [33]. Many publications have shown that oocyst production correlates poorly with weight development, with intestinal lesions and in the highly pathogenic species *E. tenella* and *E. necatrix* even with mortality [34-40] No anticoccidial can completely suppress oocyst production under practical conditions [41]. The most useful criterion for evaluating the effects of anticoccidial drugs is body weight gain particularly during the acute phase of coccidial infection

[42]. Normally the weight gain is measured from the day of inoculation till the 6th or 7th day post inoculation (dpi) or during the period of maximum growth depression (3-7 or 4-8 dpi).

Broiler chicks were inoculated at the 14th old by pathogenic field mixed isolates. Infected birds showed general signs of ruffled feathers, off food and huddling together at the 4th day post-infection with loose dropping. Results in this experiment showed that the treated group with Toltrazuril revealed great improvement in its performance parameters including feed intake, mean BW, BWG and FCR and relative growth rate with reduction in oocysts count as well as macroscopic and microscopic lesion score. Our results are in a great accordance with [43] found that toltrazuril when administered on days 18 and 19 in the drinking water at 7 mg/kg of body weight have equal to the non infected birds in performance. Toltrazuril most completely eliminated all coccidial lesions and dramatically reduced oocyst shedding. The performance data, lesion scores and oocyst counts showed that a treatment with Toltrazuril successfully controlled the coccidiosis after 2-days with no relapse of infection. Toltrazuril can thus be used for supplemental control with in-feed anticoccidials or as a primary anticoccidial with non medicated feed. Also [44] found that all Toltrazuril treatments (Days 2-3; 6-7; 10-11; 14-15 and 18-19) resulted in birds with good weights and feed conversions at all weigh periods (0, 21, 35 and 56 day old). They added that highest *E. acervulina* lesions and highest oocyst counts were recorded for Toltrazuril when given at days 2-3; 21 and 35, respectively. All other toltrazuril treatments had low numbers of oocysts and low lesion scores after Toltrazuril administration. None of the Toltrazuril treatments showed visible reoccurrence of coccidiosis. Comparing with the group treated with toltrazuril, the birds which treated with S.Q and Amprolium had lower body weight gain and relative growth rate, oocyst count and higher lesion score. Gill and Bajwa, [45] found that various species of *Eimeria* were resisted to S.Q and Amprolium treatment.

The findings of the histopathological examination in this study were confirmative and accord with the macroscopic lesion score. No microscopic lesions were seen in non infected non treated group, while the severest lesions were observed in infected non treated birds. Chickens treated with Toltrazuril showed the mildest lesions followed by those treated with S.Q. and Amprolium; respectively. Regarding to results of treatment there was some sort of drug resistance to

S.Q and amprolium which accord with the results of Waletzky *et al.* [46] Hemsley, [47]; Panda *et al.* [48] and Gill and Bagwa [45]. In conclusion: Results of this experiment showed that *Eimeria tenella* show more lesion score and histopathological changes in the cecum in group treated with both S.Q and Amprolium that indicated presence of some sort of drug resistance strains of *Eimeria*.

REFERENCES

1. Shirley, M.W., A. IvensGruber, A. Madeira, K.L. Wan and P.H. Dear, 2004. The *Eimeria* Genome Projects: a Sequence of Events. *Trends Parasitol.*, 20: 199-201.
2. Shirley, M.W., A.L. Smith and F.M. Tomley, 2005. The biology of avian *Eimeria* with an emphasis on their control by vaccination. *Adv. Parasitol.*, 60: 285-330.
3. Williams, R.B., 1998. Epidemiological aspects of the use of live anticoccidial vaccine for chickens. *Internat. J. Parasitol.*, 28(7): 1089-1098.
4. Williams, R.B., 2002. Fifty years of anticoccidial vaccines for poultry, 1952-2002. *Avian Dis.*, 46: 755-802.
5. McDougald, L.R. and W.M. Reid, 1994. Coccidiosis In: B.W. Calnek, (Ed.), *Diseases of Poultry*, 9th Edition. Affiliated East West Press Pvt. Ltd., New Delhi.
6. Awadallah, S.F., E.A. El-Shishtawy and S.Y. Mohamed, 1998. Effect of some stressors on pathogenicity of *Eimeria tenella* in broiler chickens. *J. Egyptian Society of Parasitol.*, 28: 683-690.
7. Chapman, H.D., 1986. Drug resistance in coccidia: recent research. In: L.R. McDougald, L.P. Joyner and P.L. Long, (Eds), *Research in Avian coccidiosis*, Proceed of the Georgia Coccidiosis Conference, November 18-20, 330-34. University of Georgia, Athens.
8. McDougald, L.R., G.F. Mathis and D.P. Conway, 1996. Effect of semduramicin, salinomycin and monensin on performance, shank pigmentation and coccidian lesions in broiler chickens in floor pens. *Avian Dis.*, 40(1): 69-71.
9. Yadav, A. and S.K. Gupta, 2001. Study of resistance against some ionophore in *Eimeria tenella* field isolates. *Vet. Parasitol.*, 102: 69-75.
10. Peek, H.W. and W.J.M. Tansman, 2001. Resistance to anticoccidial drugs of Dutch avian *Eimeria* spp. Field isolate originating from 1996, 1999 and 2001. *Avian Pathol.*, 32(4): 391-401.
11. Li, G.Q., S. Kann, F.Y. Xiang, S.M. Xiao, L. Zhoog, H.W. Chen and H.J. Ye, 2004. Isolation and selection of ionophore-tolerant *Eimeria* precocious lines: *E. tenella*, *E. maxima* and *E. acervulina*. *Vet. Parasitol.*, 119(4): 261-276.
12. Mathis, G.F. and L.R. McDougald, 1982. Drug responsiveness of field isolates of chicken coccidian. *Poult. Sci.*, 61: 38-45.
13. McDougald, L.R., A.L. Fuller and J. Solis, 1986. Drug sensitivity of 99 isolates of coccidia from broiler farms. *Avian Dis.*, 30: 690-694.
14. Stallbaumer, M. and K.J. Daisy, 1988. The effect of monensin, narasin, salinomycin and nicarbazin on field strain of chicken coccidian. *Avian Pathol.*, 17: 793-801.
15. Chapman, H.D. and M.W. Shirley, 1989. Sensitivity of field isolates of *Eimeria* species to monensin and lasalocid in the chicken. *Res. Vet. Sci.*, 46: 114-117.
16. Rotibi, A., L.R. McDougald and J. Solis, 1989. Response of 21 Canadian field isolates of chicken coccidian to commercial anticoccidial drugs. *Avian Dis.*, 33: 365-367.
17. Bafundo, K.W. and T.K. Jeffers, 1990. Selection for resistance to monensin, nicarbazin and monensin plus nicarbazin combinations. *Poult. Sci.*, 69: 1485-1490.
18. Williams, R.B., 1997. Williams, The mode of action of anticoccidial quinolones (6-decyloxy-4-hydroxyquinoline-3-carboxylates) in chickens. *Int. J. Parasitol.*, pp: 101-111.
19. Waletzky, E., 1970. Poultry anticoccidial agent: survey of parameters for evaluation. *Exp. Parasitol.*, 28(1): 164-168.
20. McDougald, L.R. and W.M. Reid, 1994. Prophylactic Efficacy of Diclazuril in Broilers Experimental Coccidiosis. In: B.W. Calnek, (Ed.), *Diseases of Poultry*, 9th edition.
21. Maff, A., 1977. Technical Bulletin no. 18: Manual of veterinary parasitological laboratory techniques. Ministry of Agriculture, Fisheries and Food, London, pp: 58-91.
22. Soulsby, E.J.L., 1978. *Helminthes, Arthropod and Protozoa of domestic animals*. 6th ed. Bailliere and Tindall, London.
23. Sainsbury, D.W., 1983. Poultry housing and disease. *Vet Rec.*, 10, 113(24): 565-568.
24. Urara Kawazoe Edson Luiz Bordin, Cirene Alves de Lima, Lu'cio Andre' Viana Dias 2005, 131(1-2): 5-15. Characterisation and Histopathological Observations of a Selected Brazilian Precocious Line of *Eimeria Acervulina*.

25. Johnson, J. and W.M. Reid, 1970. Anticoccidial drug: Lesion scoring techniques in battery and floor pen experiments with chickens. *Exp. Parasitol.*, 28: 30-36.
26. Barwick, M.W., G.T. Stevenson, R.V. Johnson, D.R. Casorso and T.A. Hymas, 1970. Coccidiosis: evaluation of techniques for battery testing of field collected *Eimeria* oocysts. *Exp. Parasitol.*, 28: 37-41.
27. Conway, D.P., A.D. Dayton and M.E. McKenzie, 1999. Comparative testing of anticoccidials in broiler chicken: the role of coccidial lesion scores. *Poult. Sci.* 78: 529-535.
28. Doerig, C., 2004. Protein kinases as targets for antiparasitic chemotherapy. *Biochimica et Biophysica Acta.*, 1697: 155-168.
29. Kawazoe, U., E.L. Bordin, C.A. Lima and L.A.V. Dias, 2005. Characterization and histopathological observations of a selected Brazilian precocious line of *Eimeria acervulina*. *Vet. Parasitol.*, 131: 5-14.
30. Wang, Z., J. Shen, X. Suo, S. Zaho and X. Cao, 2006. Experimentally induced monensin-resistant *Eimeria tenella* and membrane fluidity of sporozoites. *Vet. Parasitol.*, 138: 186-193.
31. Guo, F.C., X. Suo, G.Z. Zhang and J.Z. Shen, 2007. Efficacy of decoquinate against drug sensitive laboratory strain of *Eimeria tenella* and field isolates of *Eimeria* species. In broiler chickens in china. *Vet. Parasitol.*, 147: 239-245.
32. Bedrnik, P., 1983. Evaluation of sensitivity of coccidia to ionophores, *Arch. Geflugelk.*, 47: 129-133.
33. Reid, W.M., 1975. Relative value of oocyst counts in evaluating anticoccidial activity. *Avian Dis.*, 19: 802-811.
34. Engle, A.T., R.P.C.A. Humphrey and Johnson, 1967. Buquinolate, a new broad-spectrum coccidiostat. *Poult. Sci.*, 46: 810-818.
35. Norton, C.C. and L.P. Joyner, 1968: Coccidiostatic action of meticlorpindol. *Vet. Rec.*, 83: 317-323.
36. Barwick, M.W., 1973. An investigation of methods of expressing the coccidiostat intake of chickens with reference to clopidol. *Proc. 4th Eur. Poult. Conf.*, London, pp: 151-156.
37. Greuel, E., W.W. Braunius and W. Ktihhold, 1978. Zur Wirksamkeit verchiedener Coccidiostatica gegen *Eimeria* Feldisolate. *Arch. Gefliigelk.*, 42: 16-22.
38. Chapman, H.D., 1979. Studies on the sensitivity of recent field isolates of *Eimeria maxima* to monensin. *Avian Pathol.*, 8: 181-186.
39. Grant, R.J., H.F. King and G.H. Myers, 1986. The effect on broiler growth and coccidiosis parameters of feeding halofuginone and monensin continuously in the same commercial pens for two years. In: L.R.
40. Weber, G.M. and M. Frigg, 1986. Comparative efficacy of lasalocid and monensin against coccidia of two field isolates, repeatedly propagated in medicated chicks. In: L.R. McDougald, P.L. Joyner and L.P. Long, (Editors), *Research in Avian Coccidiosis*. Univ. Georgia, Atlanta, pp: 363-371.
41. Jeffers, T.K., 1978. Genetics of coccidia and the host response. In: P.L. Long, K.N. Boorman and B.M. Freeman (Editors), *Avian Coccidiosis*. Brit. Poult. Sci. Ltd, Edinburgh, pp: 50-125.
42. Chapman, H.D., 1998. Evaluation of the efficacy of anticoccidial drugs against *Eimeria* species in the fowl. *Inter. J. Parasitol.*, 28: 1141-1144.
43. Mathis, G.F., R. Froyman, T. Irion and T. Kennedy, 2003. Coccidiosis control with toltrazuril in conjunction with anticoccidial medicated or nonmedicated feed. *Avian Dis.*, 47: 463-469.
44. Mathis, G.F., R. Froyman and T. Kennedy, 2004. Coccidiosis control by administering toltrazuril in the drinking water for a 2-day period. *Vet. Parasitol.*, 121: 1-9.
45. Gill, B.S. and R.S. Bajwa, 1979. Drug resistance in field isolates of chicken from Punjab state. *Indian J. Parasitol.*, 3: 132-134.
46. Waletzky, E., R. Neal and I. Hablet, 1954. A field strain of *Eimeria tenella* resistant to sulfonamides. *J. Parasitol.*, 40: Supplement 24.
47. Hemsley, L.A., 1964. Experience of coccidiosis in young chickens fed a coccidiostat with particular reference to the incidence of coccidiosis in broiler chickens in the south of England. *Vet. Rec.*, 76: 1432-1436.
48. Panda, N.C., H.K. Pradhan, A. Mitra and S.N. Parichha, 1973. Drug resistance of coccidian exposed to a single type of coccidiostat. *Indian Vet. J.*, 50: 2.