

## Management of ear lobule keloids using 980-nm diode laser

Ahmed Nazmi Kassab · Ahmed El Kharbotly

Received: 31 December 2010 / Accepted: 9 May 2011 / Published online: 1 June 2011  
© Springer-Verlag 2011

**Abstract** The objective of the study was to evaluate the 980-nm diode laser in conjunction with corticosteroids in the treatment of ear lobule keloids. Several methods have been described for the treatment of keloid scars, but none of them have been 100% successful. Advances in laser techniques have enabled surgeons to define the most appropriate lasers for use in the treatment of different scar types. The diode laser pulses are delivered interstitially in a single repeated mode in non-overlapping sites using a bare optical fiber, followed by intralesional triamcinolone acetonide injection. The number of sessions varies between two to five for the management of more than 75% of keloid size, with a total success rate of 75% and no recurrence in the follow-up of 12 months. The technique used proved to be effective in the treatment of ear lobule keloids.

**Keywords** Ear lobule keloids · 980-nm diode laser · Triamcinolone acetonide

### Introduction

Keloids are benign dermal tumors that generally form by local fibroblast proliferation and excessive collagen production following skin trauma [1]. They are firm, rubbery lesions or shiny, fibrous nodules and can vary from pink to flesh-colored or red to dark brown in color. It is non-contagious, sometimes accompanied by severe itching, pain,

changes in texture and, in severe cases, can affect the movement of the skin [2]. Upon palpation, Keloids are firmer than hypertrophic scars. They exhibit a prolonged, proliferative phase resulting in the appearance of thick hyalinized collagen bundles similar to those produced by hypertrophic scars, but extend beyond the margins of the inciting wound and do not regress over time [2]. Although they can be seen in all skin types, keloids appear most frequently in patients with darker skin types and are related to an inherited metabolic alteration in collagen [3]. The etiology of keloids has been hypothesized by multiple different theories; nutritional, biochemical, immunological and genetic factors play a role in the formation of keloids [1]. Ear piercing is performed for both esthetic and cultural reasons. Keloid formation is a recognized complication of this procedure, although its incidence remains unknown. The size of the keloid may vary considerably. Ear lobule keloids may be unsightly and often cause significant distress to the patient [4]. A variety of treatments for keloid scarring have been described, alone or in combination, with varying degrees of success. These include surgical excision, cryotherapy, laser therapy, radiotherapy, interferon injection and corticosteroid injection [3]. The most commonly used corticosteroid in keloid treatment is the use of triamcinolone acetonide at a concentration of 10–40 mg/ml depending on the size of the keloid. Progress in laser technology and refinements in technique have made laser therapy a preferred treatment of choice for hypertrophic scars and keloids [5].

The near infrared diode laser has energy and wavelength characteristics that specifically target the soft tissues. It has an affinity for hemoglobin and melanin, which are the components that provide color or pigmentation to the tissue. Due to these characters, it is more efficient and better equipped to address soft tissue problems [6–8].

---

A. N. Kassab (✉) · A. El Kharbotly  
Otorhinolaryngology Unit, Department of Medical Laser  
Applications, National Institute of Laser Enhanced Sciences,  
Cairo University, Cairo, Egypt  
e-mail: kassabahmed28@yahoo.com

The light energy released by the diode laser transforms into heat, resulting in the vaporization of cells, a process referred to as the photothermal effect. The diode laser's optical fiber is the mechanism that delivers this energy to the tissue. The degree to which the tissue absorbs this energy depends on its affinity to the laser's wavelength, the clinician-selected energy output (which is dictated by the darkness of the tissue), the time of exposure and the characteristics of the targeted tissue [9, 10]. The absorbed energy increases the temperature of the targeted tissue, resulting immediately in a sequence of tissue reactions, which range from warming and welding to coagulation, protein denaturation, vaporization, drying, and carbonization depending on the amount of heat produced [11].

However, a variety of lasers have been used alone for the treatment of keloids, but all showed limited effectiveness [12]. Hence, in this study we attempted to evaluate the effectiveness of near IR 980-nm diode laser in combination with triamcinolone acetonide on the regression of keloids.

## Materials and methods

This study was conducted in the Otorhinolaryngology Unit, Medical Department, National Institute of Laser Enhanced Sciences, Cairo University, in the interval between November 2008 and November 2009. Patients, who presented to the Otorhinolaryngology Unit, seeking medical advice and treatment, were clinically examined to exclude hypertrophic scars, which may be confused with keloids. Exclusion criteria also included pregnancy or lactation, patients with diabetes mellitus and patients with previous recent history of treatment up to 6 months. The study included 12 patients with a total of 16 lobule keloids. In four patients, keloids presented bilaterally. Three of the patients had a previous surgical interference from 8 months to 1 year, but there was recurrence; two of them recorded that the lesion even became worse concerning itching and recurrence in the bigger sized ones. All the patients were females ranging between 15 and 45 years old, with skin phototype ranging from type 3 to type 5 according to Fitzpatrick's Skin Phototypes [13], which are the prevalent skin types among the Egyptian population. Before conducting the study, detailed information about the treatment was described to the patients, and a full written consent was taken from all the patients.

In each case, the lesion was measured by a centimeter scale (length and width ranged from 1 to 2 cm, and height ranged from 1 to 1.5 cm) to assess the degree of success after treatment.

All the patients were treated with the same modality, under the effect of local anesthesia (2% lidocaine infiltration), and the application of topical lidocaine/prilocaine

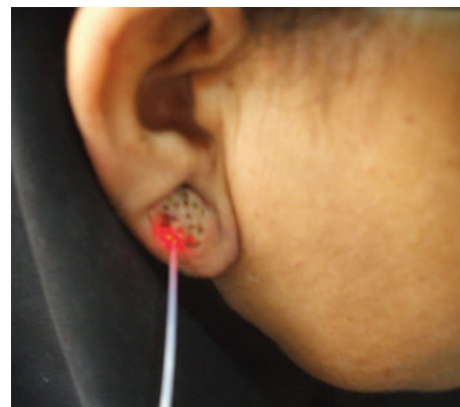
(EMLA<sup>®</sup>) cream as a local anesthetic 10 min before the session. Afterward, the keloid lesion was subjected to diode laser (Quanta, Italy) 980-nm pulses using bare optical fiber (320  $\mu\text{m}$ ). The laser pulses were delivered interstitially under aseptic conditions in adjacent, non-overlapping sites (Fig. 1). Single repeated mode of 4 s duration, at power 5 W with an energy fluence 20  $\text{J}/\text{cm}^2$  was applied. The number of pulses varied according to the size of the lesion and the degree of its darkness and it ranged from five to nine pulses. During the laser session, the patient and the medical personnel wore safety goggles of the appropriate wavelength.

Following the laser session, 1 ml of 40 mg/ml triamcinolone acetonide (kenakort) was injected intralesionally. Topical antibiotic ointments were prescribed between the sessions to be used for a period of 7–10 days following each session. Weekly follow-up was done, with 3 weeks interval between sessions.

## Results

Of 16 lesions, 11 required five sessions to achieve the best results, while in four cases, four sessions had to be performed, and in only one case two sessions were done for full improvement. An immediate erythematous skin response was observed in all 12 cases. No immediate complications such as major bleeding related to the treatment were observed. Minor complications such as infection were recorded in four lesions, and they were treated by antibiotics without any more complaints. Also, in another four lesions, minimal hyperpigmentation was recorded. All the results in this study were recorded after a 1-year follow-up.

Figure 2a, b represents two cases before the treatment. Success of the treatment was considered on the basis of lesional shrinkage to 75% or more of its original size. This



**Fig. 1** Keloid lesion subjected to diode laser. The fiber was inserted interstitially in an adjacent manner

was manifested in 12 lesions out of 16, and in these cases the lesion showed maximal reduction in size with very minimal scarring (Fig. 3A and B). Only in four cases, which were initially the biggest lesional size, there was regression to less than 50% of the original size.

## Discussion

Normally, wound healing proceeds uneventfully, but occasionally wounds heal with excessive deposition of collagen resulting in keloid formation. The current challenge of keloid treatment is the re-establishment of the proper balance between collagen synthesis and degradation throughout the phases of wound healing. In keloids, the collagen bundles are thick and are randomly oriented as swirls and whorls [14]. The ultrastructural characteristics of keloid fibroblasts and myofibroblasts were described in previous studies and all reported apoptosis of these cells [15–17]. Keloid formation is characterized by active angiogenesis, hypoxia and occlusion of some microvessels by excessive endothelial cells, which may lead to local hypoxic conditions and apoptosis [16, 18]. Accordingly, keloids can be divided into: interface and peripheral areas characterized by angiogenesis, proliferating fibroblast populations and enhanced collagen production; central areas characterized by hypoxia, apoptosis and an abundance of collagen [16, 18–20]. Several modalities of treatment have been reported, one of which is laser. It is well known that the photothermal effect of lasers produce collagen denaturation. The heat energy ruptures collagen stabilizing intermolecular and molecular cross links. In addition, the concurrent superheating of collagen fibers could also dissociate disulfide bonds with a subsequent realignment of these fibers [21–23].

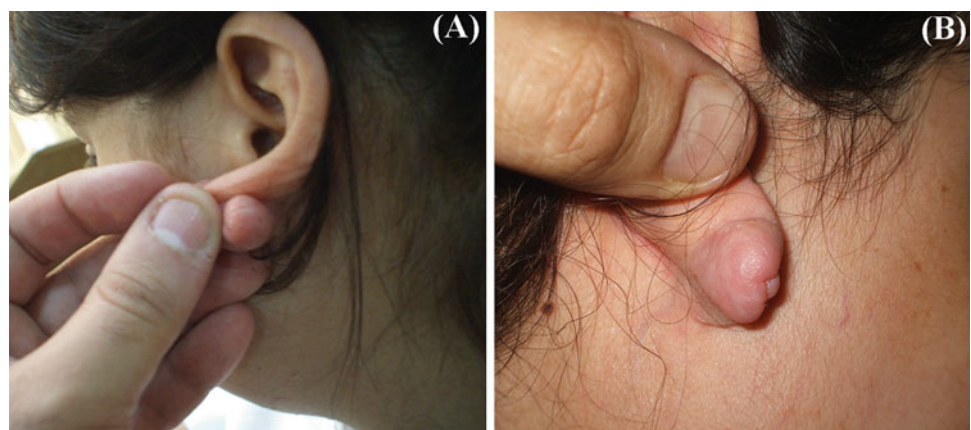
Pulsed dye laser (FPDL) has been used for the treatment of keloids with achievement of promising results [23]; however, the treatment by FPDL alone is only suitable for

smaller keloids with a limited volume. In larger keloids, a combination of excision, corticoid application and FPDL treatment showed better results. Symptom scores dropped by 50 and 70% after concomitant intralesional corticosteroid was used [24]. On the other hand, simple surgical excision alone reported a high recurrence rate [25]. For highly proliferative or fibrotic keloids, Nd:YAG-laser was utilized to reduce vascularization and tissue masses [3]; however, scar recurrences were reported [26]. Using interstitial Nd:YAG-laser vaporization effected shrinkage and flattening of the keloid, but a complete regression of the keloid size was not achieved. This modality is quite painful and requires general anesthesia [3]. In a clinical study on 17 patients, it was reported that Nd:YAG-laser effected full flattening of keloids in 60% of patients at 3 months with complete resolution of the remaining patients achieved by intralesional triamcinolone acetonide [27]. Carbon dioxide laser has been tried alone for keloid removal, by excision or ablation, but high recurrence rate was reported within 1 year of follow-up [12, 28–31]. On the other hand, other authors reported better results when using the carbon dioxide laser in combination with triamcinolone acetonide (2 ml of 40 mg/ml) [32].

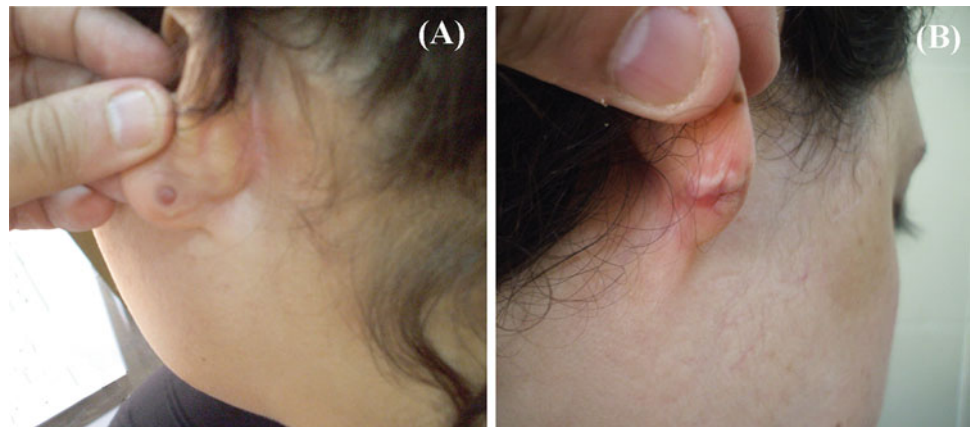
It is noticeable that much studies have been reported on the use of different types of lasers, yet the reported literature almost tells nothing about the use of the 980-nm diode laser in keloid treatment. For this reason, and also regarding its properties, we were prompted to investigate and assess the success of using diode laser in this respect. The long wavelength (980 nm, near infrared) of diode laser furnishes a short depth of penetration and high energy density making it more selective to interaction with water and hemoglobin, resulting in high tissue ablation properties with good hemostasis [33, 34].

The results of this study showed 75% success rate, which can be considered a high success rate for a type of laser that is not yet popular in the treatment of keloids. These achieved results proved that the photothermal effect

**Fig. 2** Two female patients exhibiting lobule keloid lesions before laser treatment



**Fig. 3** The same patients exhibiting regression of keloid lesion with minimal scarring after laser treatment



of the diode laser on the collagen was adequate to effect shrinkage of the collagen fibers and, consequently, contraction of the keloid [35]. The interstitial application of the laser beam delivered uniform heat energy into the dermis, while preserving to a great extent epidermal integrity. This mode of application guaranteed the effectiveness and safety of the application, as there was minimal dispersion of energy to the surrounding tissues, which could have resulted in the initiation of a new scar formation.

Most of the data evaluating intralesional steroid injections come from studies done four decades ago [36, 37] with most studies reporting about 50% recurrence rate [38]. In a recent study using 40 mg/ml intralesional injections of triamcinolone acetonide, the results showed that this treatment helped flattening and softening of keloids, but rarely resulted in complete and long-term resolution. Adverse drug reactions were also experienced by patients, such as development of telangiectasias, skin atrophy, hypo- or hyperpigmentation and irregular menstrual cycle. Therefore, it is concluded that this modality is not recommended for large or multiple keloids that require the injection of large doses of corticosteroid [39]. The use of adjuvant triamcinolone acetonide is believed to reduce excessive scarring by reducing collagen synthesis, inhibition of inflammatory cell migration and inhibition of fibroblast proliferation [40].

From the literature survey, it is evident that no single therapeutic modality has proven to be 100% efficient; therefore, in our work we decided to combine the effects of the diode laser with the corticosteroid injections hoping to achieve promising results and avoiding the well-known complications related to the use of large doses of corticosteroid. In conclusion, we can assume that the 980-nm diode laser in combination with intralesional corticosteroid injections is an effective modality in the management of ear lobule keloids that can be done under local anesthesia as an office-based procedure. However, it is quite difficult to determine the exact effectiveness of the diode laser

combined treatment with triamcinolone acetonide in comparison with other types of lasers, due to the variety of the reported application methods and different periods of follow-up. In addition, the outcomes of treatment modalities are greatly influenced by the size, type and color of the keloid, as well as environmental factors. Nevertheless, our results are better than those reported for carbon dioxide laser and are comparable to those of PDL and Nd:YAG-laser, besides the diode laser being less painful and cost saving.

**Conflict of interest** We hereby declare that we have no conflict of interest or any financial relationship with any organization that sponsored the research.

## References

- Louw L (2007) The keloid phenomenon: progress towards a solution. *Clin Anat* 20:3–14
- Alster TS, West TB (1997) Treatment of scars: a review. *Ann Plast Surg* 39:418–432
- Philipp CM, Schar Schmidt D, Berlien HP (2008) Laser treatment of scars and keloids: how we do it. *Med Laser Appl* 23:79–86
- Rusell R, Horlock N, Gault D (2001) Zimmer splintage: a simple effective treatment of keloids following ear piercing. *Brit J Plastic Surg* 54:509–510
- Alster TS, Railan D (2005) *Scar Goldman book*, chap 10
- Miyasaki MA (2004) Shedding light on the soft tissue laser. *Signature* 11(1):11–13
- Patino MG, Neiders ME, Andreana S et al (2002) Collagen as an implantable material in medicine and dentistry. *J Oral Implantol* 28(5):220–225
- Patino MG, Neiders ME, Andreana S et al (2003) Cellular inflammatory response to porcine collagen membranes. *J Periodontol Res* 38(5):458–464
- Rossmann JA, Cobb CM (1995) Lasers in periodontal therapy. *Periodontol* 2000 9:150–164
- Sarver DM (2004) Principles of cosmetic dentistry in orthodontics. Part 1. Shape and proportionality of anterior teeth. *Am J Orthod Dentofacial Orthop* 126:749–753
- Sarver DM, Yanosky M (2005) Principles of cosmetic dentistry in orthodontics. Part.3 Laser treatments for tooth eruption and soft tissue problems. *Am J Orthod Dentofacial Orthop* 127:262–264

12. Poochareon VN, Benman B (2003) New therapies for the management of keloids. *J Craniofac Surg* 14:654–657
13. Fitzpatrick TB (1975) Soleil et peau. *J Med Esthet* 2:330–34
14. Rockwell WB, Cohen IK, Ehrlich HP (1989) Keloids and hypertrophic scars: a comprehensive review. *Plast Reconstr Surg* 84:827–837
15. Matsuoka LY, Uitto J, Wortsman J, Abergel RP, Dietrich J (1988) Ultrastructural characteristics of keloid fibroblasts. *Am J Dermatopathol* 10:505–508
16. Appleton I, Brown NJ, Willoughby DA (1996) Apoptosis, necrosis, and proliferation: possible implications in the etiology of keloids. *Am J Pathol* 149:1441–1447
17. Nedelec B, Shankowsky H, Scott PG, Ghahary A, Tredget EE (2001) Myofibroblasts and apoptosis in human hypertrophic scars: the effect of interferon- $\alpha$ 2b. *Surgery* 130:798–808
18. Kischer CW (1992) The microvessels in hypertrophic scars, keloids and related lesions: a review. *J Submicrosc Cytol Pathol* 24:281–296
19. Louw L, Van Der Westhuizen JP, Duyvene de Wit L, Edwards G (1997) Keloids: peripheral and central differences in cell morphology and fatty acid compositions of lipids. *Adv Exp Med Biol* 407:515–520
20. Louw L, Keloids in rural black South Africans (2000) Part 3: A lipid model for the prevention and treatment of keloid formations. *Prostaglandins Leukot Essent Fatty Acids* 63:255–262
21. Bass LS, Moazami N, Possodio J et al (1992) Changes in type I collagen following laser welding. *Lasers Surg Med* 12:500–505
22. Schober R, Urlich F, Sander T, Durselen H, Hessel S (1986) Laser induced alteration of collagen substructure allows microsurgical tissue welding. *Science* 232:1421–1422
23. Dierickx C, Goldmann MP, Fitzpatrick RE (1995) Laser treatment of erythematous/hypertrophic and pigmented scars in 26 patients. *Plast Reconstr Surg* 95(1):84–90
24. Alster TS (2003) Laser scar revision: comparison study of 585 nm pulsed dye laser with and without intralesional corticosteroids. *Dermatol Surg* 29(1):25–29
25. Mustoe TA, Cooter RD, Gold MH (2002) International clinical recommendations on scar management. *Plast Reconstr Surg* 110:560–571
26. Nouri K, Vidulich K, Rivas MP (2006) Lasers for scars: a review. *J Cosmetic Dermatol* 5(1):14–22
27. Kumar K, Kapoor BS, Rai P (2000) In situ irradiation of keloid scars with Nd:YAG laser. *J Wound Care* 9:213–215
28. Driscoll B (2001) Treating keloids with carbon dioxide lasers. *Arch Otolaryngol Head Neck Surg* 127(9):1145
29. Stern JC, Lucente FE (1989) Carbon dioxide laser excision of ear lobule keloid. *Arch Otolaryngol Head Neck Surg* 115(9):1107–1111
30. Apfelberg DB, Maser MR, White DN, Lash H (1989) Failure of carbon dioxide laser excision of keloids. *Lasers Surg Med* 9:382–388
31. Norris JE (1991) The effect of carbon dioxide laser surgery on the recurrence of keloids. *Plast Reconstr Surg* 87:44–49
32. Verma KK, Garg T, Raj T (2002) Carbon dioxide laser for the treatment of keloids. *Indian J Dermatol* 47(2):91–93
33. Hernandez-Divers SJ (2002) Diode laser surgery: principles and application in exotic animals. *Seminars in avian and Exotic Pet Med* 11(4):208–220
34. Wendt-Nordahl G, Huckele S, Honeck P, Alken P, Knoll T, Michel MS, Hacker A (2007) 980-nm Diode Laser: a novel laser technology for vaporization of the prostate. *Europeanurology* 52:1723–1728
35. Vangness TC, Mitchell JW, Nimni M, Erlich M, Sadaat V, Schmotzer H (1997) Collagen shortening, an experimental approach with heat. *Clin Orthopaedics Related Res Number* 337:267–271
36. Ketchum LD, Robinson DW, Masters FW (1971) Follow up on treatment of hypertrophic scars and keloids with triamcinolone acetonide. *Plast Reconstr Surg* 48:256–259
37. Griffith TH, Monroe CW, McKinney PA (1970) Follow-up study on the treatment of keloids with triamcinolone acetonide. *Plast Reconstr Surg* 46:145–150
38. Berman B, Flores F (1997) Recurrence rates of excised keloids treated with triamcinolone acetonide injections or interferon  $\alpha$ -2b injections. *J Am Acad Dermatol* 37:755–757
39. Robles DT, Berg D (2007) Abnormal wound healing: keloids. *Clin Dermatol* 25:26–32
40. Shanthi M, Ernest K, Dhanraj P (2008) Comparison of intralesional verapamil with intralesional triamcinolone acetonide in the treatment of hypertrophic scars and keloids. *Indian J Dermatol Venereol Leprol.* 74:343–348