

## **Case 11546**

### **Mature benign cystic teratoma of the right adrenal gland in a 21-year-old female patient: A case report**

Sally Emad-Eldin, Youstina G. Shokry, Ahmed Zein, Sameh A. Z. Hanna  
kaser El Eini

**Section:** Uroradiology & Genital Male Imaging

**Published:** 2014, Jan. 27

**Patient:** 21 year(s), female

#### **Authors' Institution**

---

Department of Diagnostic and Intervention Radiology,  
Cairo University Hospitals,  
Kasr Al-Ainy,  
Cairo, Egypt.

#### **Clinical History**

---

A 21 years old female patient presented with abdominal pain for 6 months duration. Physical examination revealed a palpable, non tender right flank mass. All laboratory investigations were unremarkable.

#### **Imaging Findings**

---

Abdominal CT scan with IV contrast showed a large right side retroperitoneal mass lesion, measuring about 8x10x12 cm in its maximum diameters. The mass appeared heterogeneous with mixed soft tissue (arrow head) and fat content (arrow). Tiny calcific foci were also seen at the wall of the lesion. The right adrenal gland was indistinct. The mass was displacing the liver, right kidney, renal vein and IVC with no signs of infiltration.(Fig.1)

Upon surgical exploration a freely mobile, tumor originating from the right adrenal gland was

identified. The patient underwent complete surgical resection of the lesion. Grossly the lesion had well-circumscribed borders and rubbery consistency. The cut-section was soft and yellowish with areas of cystification filled with yellowish pasty material.(Fig.2)

Microscopically the cyst walls were lined with keratinized squamous epithelium, it shows lobules of mature adipocytes entangling bony trabeculae, blood vessels, mature glial tissue. No evidence of malignancy was identified.

## Discussion

---

The adrenal gland as the origin of a teratoma is extremely rare, only few cases are reported [1-4]. According to degree of maturation, teratomas are classified as mature, immature and malignant teratomas [5]. A mature teratoma is an adult-type tumor consisting of differentiated elements [6]. Most mature teratomas are cystic, and therefore called dermoid cysts [2]. They are usually benign, although they have potential for malignant transformation [3].

Retroperitoneal teratomas have bimodal peak in incidence (first 6 months of life and early adulthood) [5]. The retroperitoneum provides a large space to grow, so tumors are large at the time of presentation. They may cause abdominal or back pain, or may be asymptomatic and discovered incidentally. Cystic teratomas may rupture and cause sudden onset of abdominal pain, ascites, and peritonitis [7].

The morphologic features of mature teratoma extend from predominantly cystic to completely solid [8]. The characteristic imaging findings are a well-defined, fat-containing mass with heterogeneous density/signal, fat-fluid level or calcification[9]. Calcifications present as punctate, shard like or linear-strand high densities in mature teratomas. If the attenuation of calcification is higher than cortical bone, this sign strongly suggests teeth are contained in the lesion[9].

CT and MRI can reliably detect fat. [9] CT better distinguishes between fat and calcified masses [10]. Whereas MRI offers better soft tissue resolution, identification of benign and malignant neoplastic features, and superior tumor staging [11]. The diagnosis is often made on the basis of imaging [5]. However, a definitive diagnosis requires histopathology [12].

Differentiation of a retroperitoneal teratoma in the para-adrenal area from a true adrenal teratoma is tricky. Generally, the exact location is difficult to define [13]. In our case, because the normal adrenal gland could not be recognized, the mass was thought to be a neoplasm arising from adrenal gland. Based on its characteristic CT findings, a diagnosis of teratoma was considered.

As fat-contained mass arising from the adrenals, myelolipoma must be considered firstly in the differential diagnosis. Other tumors as angiomyolipoma, lipoma and liposarcoma are very rare[9]. Compared to them teratomas are more heterogeneous and calcification is more common[2, 14]. Complete surgical resection and close follow-up are the recommended therapy and required for definitive diagnosis [5, 15]. Prognosis is excellent after complete excision with 100% overall 5-year survival rate [16].

Primary mature cystic teratoma of the adrenal gland can present as a large retroperitoneal mass, with the characteristic imaging findings of complex mass with fat, and calcification.

## Final Diagnosis

---

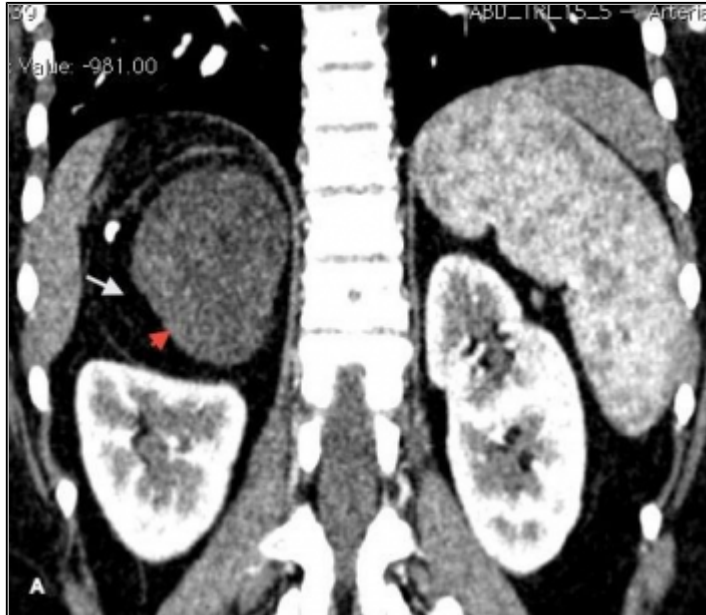Mature benign cystic teratoma of the right adrenal gland

## Differential Diagnosis List

Adrenal Myelolipoma, Retroperitoneal Lipoma, Retroperitoneal liposarcoma

## Figures

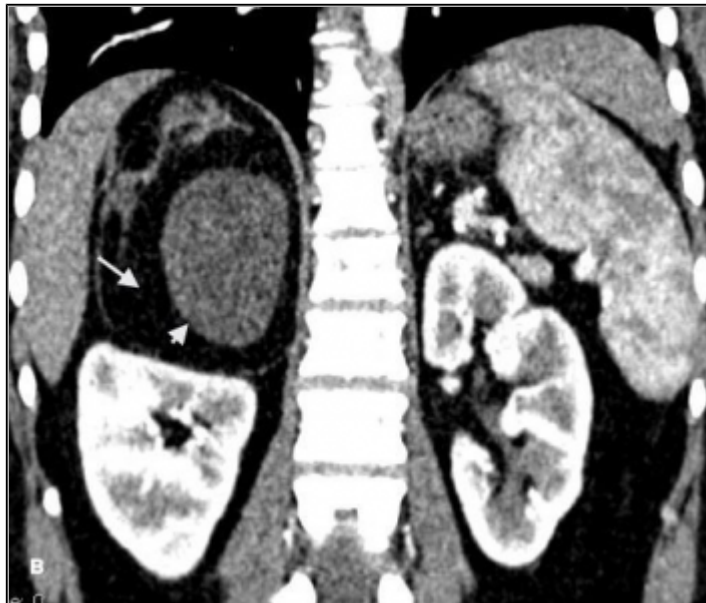Figure 1 Abdominal CT with IV contrast reconstructed in coronal & sagittal planes.



There is a large right side retroperitoneal mass. The mass appears heterogeneous with mixed soft tissue (arrow head) and fat content (arrow). Tiny calcific foci are seen at the wall of the lesion.

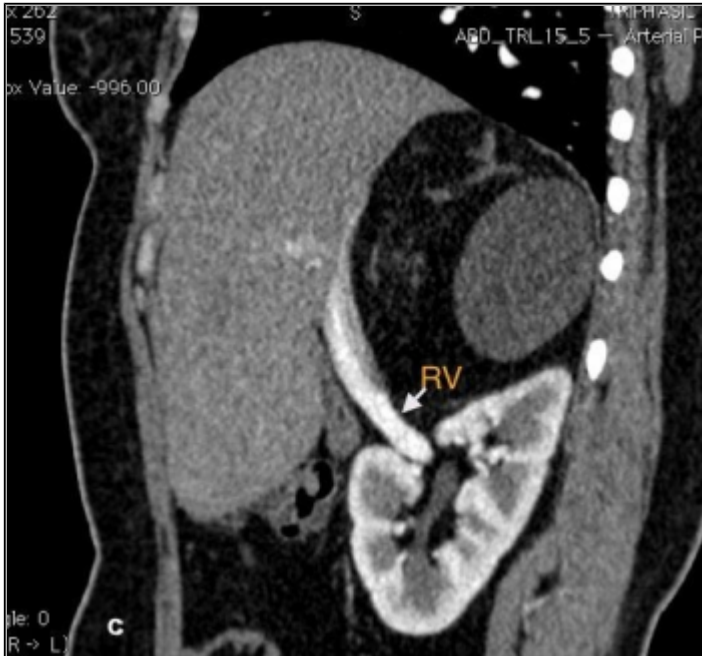© Department of Diagnostic and Interventional Radiology, Kasr Al-Ainy Hospital, Cairo University, Cairo, Egypt.

Area of Interest: Abdomen;  
Imaging Technique: CT;  
Procedure: Contrast agent-intravenous;  
Special Focus: Neoplasia;



The right adrenal gland is indistinct.


Area of Interest: Abdomen;  
Imaging Technique: CT;  
Procedure: Contrast agent-intravenous;  
Special Focus: Neoplasia;

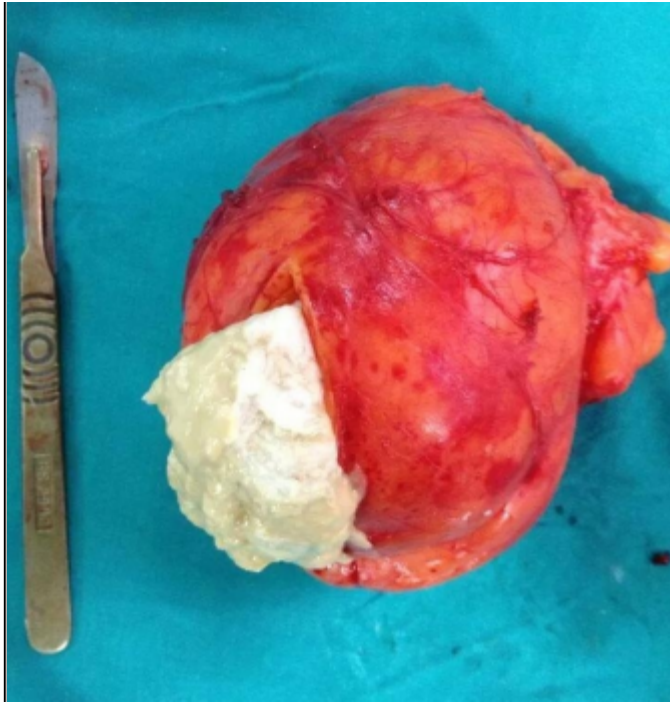


The mass is displacing the right kidney, IVC and renal vein with no signs of infiltration.

Area of Interest: Abdomen;  
Imaging Technique: CT;  
Procedure: Contrast agent-intravenous;  
Special Focus: Neoplasia;

**Figure 2 Photograph of the gross surgical specimen of the lesion**





Photograph of the gross surgical specimen of the lesion opened in the operating room and demonstrating soft and yellowish cut section of the lesion with the yellowish pasty material filled the lesion

© Department of Diagnostic and Interventional Radiology, Kasr Al-Ainy Hospital, Cairo, Egypt.

Area of Interest: Abdomen;  
Imaging Technique: CT;  
Procedure: Contrast agent-intravenous;  
Special Focus: Neoplasia;

## References

- [1] Bedri S, Erfanian K, Schwaitzberg S, and Tischler AS (2002) Mature cystic teratoma involving adrenal gland *Endocr Patho* 113(1): 59-64
- [2] Polo J L, Villarejo PJ, Molina M, Yuste P, Menendez JM, Babe J, Puente S (2004) Giant mature cystic teratoma of the adrenal region *Am J Roentgenol* 183(3):837-838
- [3] Bhatti A, Al-Hindi H, Azzam A, Amin T, Abu-Zaid A (2013) Mature (benign) cystic retroperitoneal teratoma involving the left adrenal gland in a 22-year-old male: a case report and literature review *Case Rep Oncol Med* 2013:610280. doi: 10.1155/2013/610280
- [4] Lam KY, Lo CY (1999) Teratoma in the region of adrenal gland: A unique entity masquerading as lipomatous adrenal tumor *Surgery* . 126: 90-4
- [5] Gatcombe HG, Assikis V and Kooby D (2004) Primary retroperitoneal teratomas: a review of the literature *J Surg Oncol* 86:107-113
- [6] Selimoglu E, Ozturk A, Demirci M, Erdogan F (2002) A giant teratoma of the tongue. *Int J Pediatr Otorhinolaryngol* 66:189-192

- [7] Scott AL, Abbassi-Ghadi N, Archer CM, Swamy R, Gupta S (2010) Neuroendocrine carcinoma arising within a retroperitoneal mature teratoma. *Ann R CollSurg Engl* 92:5-8.
- [8] Chen JC , Khiyami A, McHenry CR (2011) Retroperitoneal cystic teratoma masquerading as incidentally discovered adrenal mass. *Endocr Pract.* 17(5):e130-4
- [9] Guo YK, Yang ZG, Yuan Li a, Denga YP, Maa ES, Mina PQ, Zhang XC (2007) Uncommon adrenal masses: CT and MRI features with histopathologic correlation. *Eur J Radiol* 62: 359-370.
- [10] Taori K, Rathod J, Deshmukh A, Sheorain VS, Jawale R, Sanyal R, Bhagat M, and Jumle S (2006) Primary extragonadal retroperitoneal teratoma in an adult. *Br J Radiol* 79, (946): 120-122.
- [11] Bellin MF, Duron JJ, Curet P, Dion-Voirin E, and Grellet J (1991) 11. Primary retroperitoneal teratoma in the adult: correlation of MRI features with CT and pathology. *Magn Reson Imaging* 9(2): 263-266
- [12] Mathur P, Lopez-Viego MA, and Howell M (2010) Giant primary retroperitoneal teratoma in an adult: a case report. *Case Rep Med.* 2010.pii:650424. doi:10.1155/2010/650424
- [13] Castillo OA, Vitagliano G, Villeta M, Arellano L, Santis O (2006) Laparoscopic resection of adrenal teratoma. *JLS.* 10(4):522-4.
- [14] Pereira JM, Sirlin CB, Pinto PS, Casola G (2005) CT and MR imaging of extrahepatic fatty masses of the abdomen and pelvis: techniques, diagnosis, differential diagnosis, and pitfalls. *Radiographics* 25:69-85.
- [15] Sato F, Mimata H, Mori K (2010) Primary retroperitoneal mature cystic teratoma presenting as an adrenal tumor in an adult. *Int J Urol.*17(9): 817
- [16] Pinson CW, ReMine SG, Fletcher WS, and Braasch JW (1989) Long-term results with primary retroperitoneal tumors. *Arch Surg* 124(10): 1168-1173.

## Citation

---

Sally Emad-Eldin, Youstina G. Shokry, Ahmed Zein, Sameh A. Z. Hanna (2014, Jan. 27)

**Mature benign cystic teratoma of the right adrenal gland in a 21-year-old female patient: A case report {Online}**

URL: <http://www.eurorad.org/case.php?id=11546>