

## Clinical and Radiographic Evaluation of Papilla Preservation Flap with or without Nanocrystalline Hydroxyapatite Bone Graft for Management of Periodontal Intra-bony Defects: A Randomized Controlled Clinical Trial

Research Article

Alaa Ashraf<sup>1</sup>, Weam A. El Battawy<sup>2</sup>, Dina Fahim<sup>3</sup>, Noha A. Ghallab<sup>2\*</sup><sup>1</sup> M.Sc. of Periodontology, Faculty of Dentistry, Cairo University, Egypt.<sup>2</sup> Department of Oral Medicine and Periodontology, Faculty of Dentistry, Cairo University, Egypt.<sup>3</sup> Department of Oral and Maxillofacial Radiology, Faculty of Dentistry, Cairo University, Egypt.

### Abstract

This study assessed clinically and radiographically nanocrystalline hydroxyapatite bone graft substitute (n-HA) with papilla preservation flap (PPF) versus PPF alone in treatment of periodontal intra-bony defects. Thirty patients with periodontitis were randomly allocated to receive either PPF+n-HA (intervention group) or PPF (control group). Plaque index, gingival index, probing pocket depth (PPD), clinical attachment level (CAL), and radiographic bone defect area (BDA) were recorded at baseline, 3 and 6 months postoperatively. Both groups showed a significant improvement ( $P \leq 0.05$ ) in all parameters 6 months postoperatively without significant difference ( $P \geq 0.05$ ) between them. After 6 months, PPF+n-HA demonstrated 3.67 ( $\pm 1.07$ ) mm PPD reduction and 3.33 ( $\pm 0.89$ ) mm CAL gain, while PPF showed PPD reduction of 3.58 ( $\pm 1.31$ ) mm and 2.67 ( $\pm 1.3$ ) mm CAL gain. The BDA reduced by 3.61 ( $\pm 2.46$ ) mm<sup>2</sup> in PPF+n-HA and 2.02 ( $\pm 1.76$ ) mm<sup>2</sup> in PPF group. Both PPF+n-HA and PPF groups improved clinical and radiographic outcomes and were effective in managing intra-bony defects.

**Keywords:** Nanohydroxyapatite; Bone Substitutes; Papilla Preservation Flap; Periodontitis; Periodontal Regeneration.

### Introduction

The main objective of periodontal therapy is to arrest progressive attachment loss through nonsurgical and surgical periodontal therapy [1]. Obtaining true periodontal regeneration is considered by far the most elusive goal for treating periodontal intra-bony defects. Nowadays, variable techniques are used aiming for periodontal regeneration including bone replacement grafts [2, 3] that have been evaluated by previous studies and systematic reviews to enhance regeneration of periodontal defects [4-7]. Bone replacement grafts provide structural scaffolds and matrices for blood clot development, maturation and osteoblasts proliferation [8]. Synthetic hydroxyapatite (HA) is an alloplastic material, chemically like the inorganic component of bone matrix which received great attention as a scaffold for bone tissue engineering. However, HA exhibited decreased osteoconductivity and poor degradation characteristics which limited its clinical use. In addition, they have shown no potential for enhancing new attachment

formation acting primarily as inert biocompatible bone fillers [5, 7, 9].

A newly developed HA was developed containing 65% water and 35% nanostructured apatite particles and was first introduced in an animal study examining the de novo bone formation in osseous defects [10]. The significance of nanotechnology was postulated to generate materials that could mimic the natural nanostructure of the living human tissues and to provide porous bioceramics of high mechanical strength with a large surface-to-volume ratio [11]. Moreover, this technology promotes colonization and adhesion of osteoblasts on nano grained materials besides its high-water content which facilitates blood vessels growth [10, 12, 13]. These nano crystals also allow bone mineral to act as an ion 'reservoir' capable of either capturing or releasing ions under the control of the body to certify homeostasis [14]. Other advantages of using nano HA as a regenerative bone substitute include; minimal patient morbidity, biocompatibility, lack of toxicity and ability to chemically bond to bone [15].

#### \*Corresponding Author:

Noha A. Ghallab,  
Professor of Oral Medicine and Periodontology, Faculty of Dentistry, Cairo University, Egypt.  
Tel: 002-0105263365  
E-mail: noha.ghallab@dentistry.cu.edu.eg

**Received:** June 04, 2021

**Accepted:** August 29, 2021

**Published:** September 03, 2021

**Citation:** Alaa Ashraf, Weam A. El Battawy, Dina Fahim, Noha A. Ghallab. Clinical and Radiographic Evaluation of Papilla Preservation Flap with or without Nanocrystalline Hydroxyapatite Bone Graft for Management of Periodontal Intra-bony Defects: A Randomized Controlled Clinical Trial. *Int J Dentistry Oral Sci.* 2021;8(9):4201-4208.

**Copyright:** Noha A. Ghallab ©2021. This is an open-access article distributed under the terms of the Creative Commons Attribution License, which permits unrestricted use, distribution and reproduction in any medium, provided the original author and source are credited.

Several commercially available nano HA bone substitutes have been clinically and histologically evaluated in management of periodontal intrabony defects [16-19]. Nevertheless, there is a controversy regarding the regenerative potential of nano HA, where clinical outcomes obtained following its use in treating intrabony defects may not always be indicative of true periodontal regeneration. Accordingly, this investigation aimed to evaluate nanocrystalline HA embedded in a silica gel matrix (n-HA) as one of the currently available nanostructured HA bone substitutes. This resorbable n-HA has 60 nm nano-sized particles is non-sintered, highly porous and produced by a sol-gel-method where n-HA is homogeneously distributed into silica forming a nano-porous scaffold during gel transition which connects the loosely packed HA crystallites. This produces an extensive surface with interconnecting pores forming a nano-porous compound with high osteoconductive potential [20, 21].

Modified and simplified papilla preservation flaps (PPF) were developed to maintain primary flap closure and increase the ability to create space for regeneration in the interdental area protecting the regenerating tissues [22, 23]. These procedures aim at complete preservation of the marginal tissue on top of the applied regenerative material during the critical stages of healing [24, 25]. Given the existing gap of knowledge regarding the regenerative potential of n-HA, this randomized clinical trial aimed to assess the clinical and radiographic outcomes following the use of n-HA bone graft substitute with PPF compared to PPF alone in the treatment of periodontal intraosseous defects. The null hypothesis tested is that there should be no difference found regarding CAL gain between PPF+n-HA bone graft and PPF alone after 6 months.

## Materials and Methods

### Study Design and ethics

This is a parallel randomized clinical trial designed to compare clinically and radiographically the use of n-HA bone substitute with PPF versus PPF alone in managing periodontal intrabony defects. The study protocol was registered in ClinicalTrials.gov (ID:NCT03588507) and approved by the Research Ethics committee, Faculty of Dentistry, Cairo University (July 2018) and performed according to the Declaration of Helsinki [26]. This study was reported according to CONSORT guidelines, 2012 [27] (Figure 1).

### Study Population

This investigation included 30 patients (10 males and 20 females, aged 25 to 50 years) suffering from periodontitis stage III or IV [28] recruited from the outpatient clinic, Department of Periodontology, Faculty of Dentistry, Cairo University between September 2018 and November 2019 meeting the following eligibility criteria: 1) systemically healthy patients; 2) at least four non-adjacent teeth sites in each jaw having CAL  $\geq 5$ mm and PD  $\geq 6$ mm in one or more sites; 3) tooth loss due to periodontitis  $\leq 4$  teeth; 4) confirmation of intrabony defects using periapical radiographs and 5) patients who agreed to take part in the study and sign a written informed consent. Exclusion criteria included: 1) pregnant or lactating women; 2) taking any medication 3 months prior to the study; 3) patients receiving any periodontal treatment

6 months prior to study initiation; and 4) former or current smokers.

### Pretreatment

Full mouth clinical and radiographic examination was performed for all recruited patients. Patients' motivation to perform oral hygiene instructions involved brushing twice-daily with soft toothbrush using modified bass technique and once daily interdental cleaning with dental floss and interdental brushes. Full mouth supra and subgingival debridement was performed with ultrasonic device (Woodpecker UDS-P with LED, China) with subgingival scaling inserts (EMS Woodpecker ultrasonic scaler tip, China) followed by Gracy's curettes (Gracy's curette; Hu-Friedy, Chicago, USA) for proper subgingival debridement. Patient preparation was finalized in 2-3 visits, over two weeks. Local anesthesia was used when needed for patient comfort. Chlorhexidine HCL gluconate 0.12% (Hexitol; Chlorhexidine HCL mouthwash, The Arab Drug Company for pharmaceutical & CHEM. IND. CO. Cairo-Egypt) mouth rinse twice daily was prescribed for 2 weeks. Reevaluation was performed after 4-6 weeks from the initial therapy to confirm the need for periodontal surgery. Criteria used to indicate that surgery was necessary included the persistence of an interproximal defect with PPD  $\geq 6$ mm and CAL  $\geq 5$ mm.

### Randomization and blinding

An investigator (GN) generated a simple random allocation sequence via computer program ([www.random.org](http://www.random.org)). Allocation concealment was accomplished by placing this randomization list in opaque, sequentially-numbered, sealed envelopes including the randomization code for each patient that was not unsealed until follow-up was finished. The investigator (GN) who performed the allocation was neither involved in patients' recruitment nor in their treatment. Eligible participants were randomly assigned into two equal groups with a 1:1 allocation ratio to receive either n-HA bone graft (Nano Bone, Dentaaurum, Germany) with PPF (intervention group) or PPF alone (control group). Participants, outcome assessor and statistician were blinded to the type of intervention being allocated.

### Clinical Parameters

Clinical parameters were measured at baseline, 3 and 6 months postsurgically by a single examiner (RA) who was masked, calibrated and trained. Calibration exercises for probing measurements were done in five patients before the study with a good intra-examiner agreement of a 0.82k value. The periodontal parameters recorded for all participants included; plaque index (PI) [29], gingival index (GI) [30], PPD and CAL. PPD was measured from the free-gingival margin to the base of the pocket and CAL was measured from the cemento-enamel junction (CEJ) to the base of the pocket. Measurements were recorded at six sites for all teeth mesio-buccal, mesio-lingual, mid-buccal, disto-buccal, disto-lingual, and mid-lingual using William's graduated periodontal probe (Martin™ graduated periodontal probe No. 43-357-00, KLS martin Group, Germany) and were rounded to the highest whole millimeter.

### Radiographic parameters

Periapical digital radiographs were taken to measure bone defect

area (BDA) using linear measurements immediately preoperative (baseline) and after 6 months using PSP sensors (Eagle eye™ PSP Imaging plate, USA) size 1 or 2 with right angle long cone parallel technique. Planmeca X-ray machine exposure parameters were 63kV, 8mA and 0.10 second exposure time. For image standardization, KCP X-Ray Holder kit was used and custom-made bite block with self-cured acrylic resin was fabricated for each case. Radiological landmarks were defined for metric evaluation of images including; CEJ was the most apical point of enamel at the proximal surface of the tooth on the defect side; alveolar crest was the point on the proximal surface of the defected tooth where the projected alveolar crest intersected with the root surface; and the base of the defect was the most coronal point at the tooth proximal surface on the defect side up where the periodontal ligament space showed a uniform width. Using Digora software (Digora For Windows 2.8™, Soredex Inc., Tuusula, Finland), three linear measurements were linked to form a triangle; 1st from CEJ to the bottom of the intrabony defect; 2nd from CEJ to the alveolar crest of the intrabony defect; and 3rd from the alveolar crest of the intrabony defect to defect base (Figure 2). The area of this triangle, BDA (mm<sup>2</sup>) = 1/2bh was calculated where; b was length of the triangle base; h was height of the triangle represented by the length of a perpendicular from the apex opposite the base of the triangle [31].

### Treatment Protocols

After pretreatment phase, participants were scheduled for surgery. In narrow interproximal spaces (≤2mm) simplified PPF technique was performed [23], whereas in wide interdental spaces (>2mm), modified PPF technique was conducted [22]. Debridement of intrabony defect from inflammatory granulation tissue was achieved until a sound healthy bone surface and roots were thoroughly planed using ultrasonic scalers and Gracy's curettes. After performing PPF and confirming that the intrabony defect depth was ≥3mm intra-operatively (Figure 3), patients were allocated to either placement of n-HA bone graft or PPF alone per the randomization list. After complete debridement of the defect, small fragments of n-HA bone graft were gradually placed using a small papilla elevator up to the existing level of the alveolar crest and care was taken not to overfill the defect. The mucoperiosteal flaps were repositioned using resorbable polyglycolic acid #6-0 suturing material (EGYSORB, Taisier-Med, Egypt). Vertical or horizontal mattress sutures and interrupted sutures were performed to obtain primary closure of the interdental space.

Patients were taught not to brush the surgical site and rinse twice daily with 0.12% chlorhexidine for 2 weeks. Oral analgesics (Brufen, 400 mg tablets, Kahira Pharm. Co. Egypt) were prescribed if needed. Patients were requested to avoid hard food for 1 week post-surgery. Sutures were removed ten days after surgery and patients were educated to brush the surgical area gently with a soft toothbrush using roll technique. No interdental cleaning was performed until one month after the surgery. All participants were followed up weekly and recalled for professional supra-gingival scaling for the first month and every month for 6 months.

### Statistical & Power analysis

Based on a previous study [16], a total sample size of 24 patients was calculated to detect an effect size of 1.21 between the two groups, with level of significance  $\alpha=0.05$  and 80% power which

was increased to 30 patients to compensate for dropouts (Power and sample size program: [biostat.mc.vanderbilt.edu/twiki/bin/view/Main/Power Sample Size](http://biostat.mc.vanderbilt.edu/twiki/bin/view/Main/Power%20Sample%20Size)). Data were explored for normality by Kolmogorov-Smirnov and Shapiro-Wilk tests and presented as; mean, standard deviation (SD), mean difference, 95% confidence interval (CI), median and range. For parametric data, repeated measures ANOVA test was used for comparisons between and within groups. Bonferroni's post-hoc test was used for pair-wise comparisons when ANOVA test was significant. For non-parametric data, Mann-Whitney U test was used to compare between the two groups. Friedman's test was used to study the changes by time within each group. Dunn's test was used for pair-wise comparisons. Significance level was set at  $P \leq 0.05$ . Statistical analysis was performed with IBM SPSS Statistics for Windows, Version 23.0. Armonk, NY: IBM Corp.

## Results

### Clinical and radiographic parameters

The clinical and radiographic parameters recorded for PPF and PPF+n-HA groups throughout the study are shown in table 1. The present results showed no significant difference between the two studied groups regarding all baseline periodontal parameters ( $P \geq 0.05$ ). Both groups showed a significant decrease ( $P < 0.001$ ) in PI and GI at 3 and 6 months postsurgically compared to baseline, with no significant change ( $P \geq 0.05$ ) from 3 to 6 months. However, no significant difference ( $P \geq 0.05$ ) was observed in PI and GI scores between both groups at different time intervals. After 3 and 6 months, a significant improvement in PPD and CAL over baseline findings was observed in PPF and PPF+n-HA groups ( $P \leq 0.05$ ) as well as from 3 to 6 months ( $P < 0.0001$ ). However, no significant difference ( $P \geq 0.05$ ) was noted between both interventions regarding mean mm and % PPD reduction and CAL gain throughout the experimental period (Table 2).

The current statistical analysis showed no significant difference between the two studied groups regarding baseline radiographic parameters ( $P = 0.063$ ). Mean baseline BDA was significantly reduced in both studied groups after 6 months ( $P < 0.0001$ ). However, no significant difference was detected between them regarding both mean absolute mm<sup>2</sup> ( $P = 0.082$ ) and mean percentage ( $P = 0.378$ ) change in BDA after 6 months (Table 2 and Figure 4).

## Discussion

Results from this randomized clinical trial demonstrated that PPF+n-HA bone graft substitute and PPF alone, significantly improved all clinical and radiographic outcomes after 6 months with no significant difference noticed between them in all recorded parameters throughout the study. These observations suggest that both interventions might offer promising regenerative potentials in managing periodontal intrabony defects. The PPF+n-HA group demonstrated a significant reduction in PPD of 3.67mm and 3.33mm CAL gain at 6 months which is in line with previous studies investigating commercially available n-HA bone grafts in management of periodontal intrabony defects [15, 16, 19, 32].

The current findings are consistent with Kasaj et al. [33] who reported a 3.9mm PPD reduction and 3.6mm CAL gain after using a novel n-HA paste in intrabony defects. Similarly, Chitazi et al. [15]

Figure 1. CONSORT flowchart of the study.

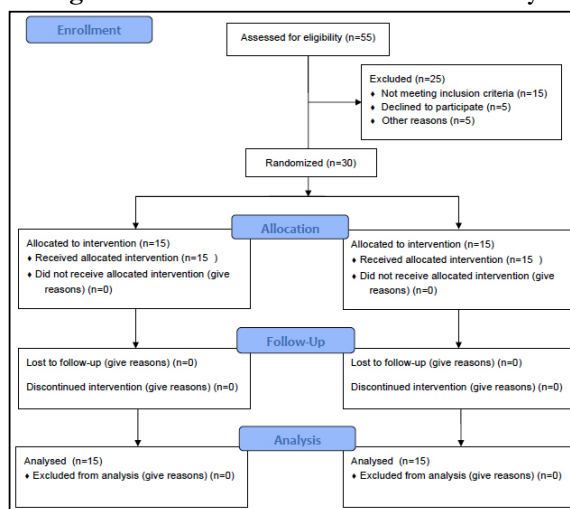


Figure 2. Figure 2: Preoperative radiograph with linear measurement AC = alveolar crest; BD = bottom of the defect and CEJ = cemento-enamel junction.

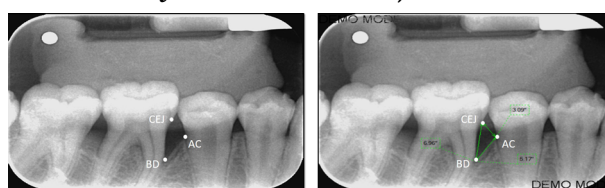


Figure 3. Overview of surgical procedures: (A) Intraoperative 3mm intrabony defect mesial to upper right central incisor after releasing PPF, (B) The flap sutured with 6-0 resorbable PGA horizontal mattress and interrupted sutures. (C) Intraoperative 6mm intrabony defect mesial to upper left central incisor after releasing PPF, (D) n-HA bone graft used to fill the defect.

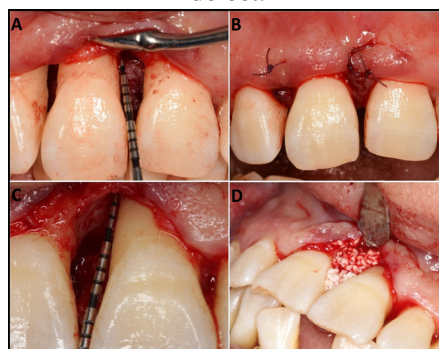
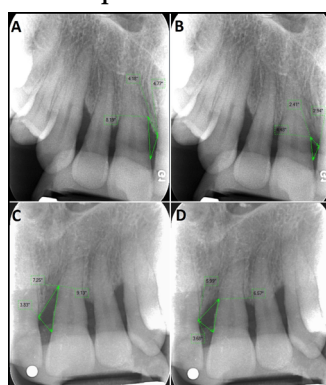


Figure 4. Preoperative and postoperative computerized digital radiographs: (A) Baseline intrabony defect mesial to upper right central incisor treated with PPF; (B) 6 months follow up showing intrabony defect depth resolution. (C) Baseline intrabony defect mesial to upper left central incisor treated with n-HA+PPF; (D) 6 months follow up showing intrabony defect depth resolution.



showed a significant reduction in PPD (3.21mm) and CAL gain (2.62mm) 6 months after using n-HA paste (Ostim) in intrabony defects. Pietruska et al. [34] also showed that intrabony defects treated with open flap debridement (OFD) and n-HA bone substitute embedded in silica resulted in PPD reduction and CAL gain

of 3.3mm and 2.5mm respectively after 6 months. Despite using the same n-HA brand, yet the inferior CAL gain might be due to performing an OFD rather than PPF which helped in preserving the interdental tissues and securing the underlying bone graft in this study. Moreover, Horváth et al. [17] demonstrated a 4mm PPD

Table 1. Clinical periodontal & radiographic parameters in both studied groups throughout the experimental period.

	PPF+n-HAMe-dian (range)	PPF Median (range)	Effect size (d)	P-value
<b>GI</b>				
Baseline	3a (2-3)	2.5a (1-3)	0.201	0.576
3 months	1.5b (1-3)	1.5b (0-3)	0.142	0.707
6 months	1b (0-3)	1b (0-3)	0.261	0.507
P-value	P<0.001*	P<0.001*		
<b>PI</b>				
Baseline	2a (1-3)	2a (1-3)	0	0.511
3 months	1b (0-3)	1b (0-3)	0.201	0.743
6 months	1b (0-3)	1b (0-2)	0	0.45
P-value	P<0.001*	P<0.001*		
	PPF+n-HAMean (±SD)	PPF Mean (±SD)	Mean Difference [95% CI]	P-value
<b>PD mm</b>				
Baseline	7.67a ±1.3	7.5a ±1.68	0.17 [-1.11, 1.44]	0.788
3 months	5.33b ±1.15	5.42b ±1.56	-0.08 [-1.25, 1.08]	0.883
6 months	4.0c ±1.04	3.92c ±0.67	0.08 [-0.66, 0.83]	0.818
P-value	<0.001*	<0.001*		
<b>CALmm</b>				
Baseline	8.25a ±1.91	7.08a±1.78	1.17 [-0.4, 2.73]	0.136
3 months	6.17b ±1.53	5.83b ±1.27	0.33 [-1.25, 1.08]	0.567
6 months	4.92c ±1.51	4.42c ±0.79	0.5 [-0.52, 1.52]	0.32
P-value	<0.001*	<0.001*		
<b>mm<sup>2</sup> BDA</b>				
Baseline	9.39 ±3.88	6.93 ±1.97	2.46 [-0.148, 5.06]	0.063
6 months	5.77 ±2.58	4.91 ±2.17	0.87 [-1.15, 2.89]	0.383
P-value	<0.0001*	<0.001*		
mm PD reduction	3.67 (±1.07)	3.58 (±1.31)	0.17 [-1.11, 1.44]	0.866
% PD reduction	47.89% (±11)	46.68% (±9.33)	1.215 [-7.42, 9.85]	0.773
P-value	<0.001*	<0.001*		
mm CAL gain	3.33 (±0.89)	2.67 (±1.3)	0.67 [-0.28, 1.61]	0.157
% CAL gain	41.06% (±9.6)	35.96% (±11.74)	5.1 [-3.98, 14.19]	0.256
P-value	<0.001*	<0.001*		
mm <sup>2</sup> BDA change	3.61(±2.46)	2.02 (±1.76)	2.46 [-0.148, 5.06]	0.082
% BDA change	35.93 % (±16.88)	29.11% (±20.08)	6.82[-8.89, 22.53]	0.378
P-value	<0.001*	<0.001*		

\*Significant at P ≤0.05, Different superscripts in the same column are statistically significantly different. SD: standard deviation, CI: confidence interval.

reduction and 2.5mm CAL gain after treating intrabony defects with a resorbable, fully synthetic, unsintered, n-HA paste. Further histologic evaluation revealed healing by a long junctional epithelium with remnants of the grafting material encapsulated in connective tissue without signs of bone formation, suggesting that this material has no visible effect on enhancing periodontal regeneration. These findings might be explained by the inclusion of a more complicated one wall defect with a remarkably lower healing potential compared to the two-and three-wall configuration included in this trial.

In a 12-month randomized clinical trial, Bhardwaj et al.[35] reported that intrabony defects treated with a synthesized zinc incorporated n-HA (ZINH) showed superior PPD reduction and CAL gain of 4.37mm and 3.08mm respectively, versus commercially available n-HA which demonstrated 2.81mm PPD reduction and 2.33mm CAL gain. As explained by the authors, these results might be due to the added benefit of zinc which possess a direct stimulatory effect on osteoblasts and inhibited bone resorption, besides its antibacterial effect that was suggested earlier by Bhattacharjee et al. [36]. On the contrary, inferior results were obtained by Kamboj et al. [37] showing a mean PPD reduction

of 2.9mm and CAL gain of 2.8mm 6 months after using n-HA paste in treating intrabony defects and later by Dayashankar et al. [38] who obtained 1.27mm PD reduction and 1.4 mm CAL gain using particulate n-HA in intrabony defects. The different surgical techniques together with differences in patients' selection and defect morphology with low regenerative capacity might explain these inconsistencies.

Recently, Koduru et al. [32] revealed enhanced regenerative outcomes after treating intrabony defects using a 20-nm particle sized n-HA, reporting 4.4mm PPD reduction and 6.2mm CAL gain after 9 months. These superior results could be explained by the longer follow up period and by the differences in the osteoconductive potential owing to the small particle size of the n-HA which was found to be more effective at promoting cell growth and inhibiting cell apoptosis [12].

Regarding radiographic outcomes, PPF+n-HA group showed 35.93% gain in BDA after 6 months which are consistent with few studies assessing the radiographic bone fill after using n-HA in intrabony defects. Superior results were achieved by Kamboj et al. [37] with a 59.8% bone fill measured by CBCT. While Dayashankar et al. [38] reported comparable bone fill (39.89%) in intrabony defects treated by particulate n-HA, yet sites treated with citric acid based n-HA showed superior bone fill of 65.74%. These discrepancies might be attributed to the different materials as well as the more accurate radiographic imaging technique used compared to standard digital radiography. Moreover, Bhardwaj et al. [35] showed superior defect fill after using both n-HA (40.2%) and ZINH (54.7%). This could be owing to the 9-months follow up that might permit further bone deposition in addition to zinc that was suggested to improve the bioactivity of n-HA bone graft material [36].

The clinical and radiographic improvements currently demonstrated by PPF+n-HA bone graft group might be attributed to various properties reported in the literature [11]. Kasaj et al. [39] in an in vitro study observed that n-HA stimulates mesenchymal stem cells, increased protein absorption and has a rough surface favoring adhesion of human osteoblasts due to its small size and huge specific surface area. Their study also showed that n-HA may stimulate human osteoblast-like cell proliferation with subsequent bone formation and could promote human periodontal ligament cell proliferation owing to the activation of epidermal growth factor receptor, thus stimulating periodontal regeneration. The authors suggested that n-HA can act as a promoter of bone regeneration at the bone defect site through two mechanisms; first by inducing osteogenic differentiation and second, by promoting BMP-2 expression, which is essential for osteogenesis, besides inducing the secretion of other growth factors [40, 41]. Nano-sized particles also offer a surface hydrated layer that aid in the interaction with macromolecules through its ability for ion exchange and its capacity for adsorption. Intrinsically, it is presumed that the presence of this layer on the bone mineral nanoparticles is actively involved in the process of homeostasis in addition to other pathways involved in the regulation of osteogenesis [13].

Interestingly, this investigation showed that sites treated with PPF alone improved after 6 months, with 3.58mm PPD reduction and 2.67mm CAL gain. The data presented herein is in accordance with previous studies and systematic reviews supporting the benefit of preserving the papillary tissues, stabilizing the wound

along with protecting the underlying soft and hard tissues [25, 42]. These findings were supported by a systematic review with meta-analysis resulting in 3.59mm PPD reduction and 2.48mm CAL gain following the use of PPF in treating intrabony defects [43]. The authors concluded that PPF increased the blood clot stability at the interproximal area with a more favorable healing of the intrabony defect and was associated with low rates of wound failure during the critical initial weeks of healing.

Furthermore, sites treated with PPF alone showed a 29.11% change in BDA after 6 months which was in line with previous studies evaluating the bone fill capacity after using PPF in intrabony defects [44, 45]. Despite being performed alone with no underlying regenerative material to fill the defect, the improved radiographic outcomes in the PPF group might be due to the inherent characteristics of the 2 and 3 wall structures of the intrabony defects included in this study along with their narrow and deep morphology. It is well established that the defect morphology markedly affects the presented vascular and cellular elements required for the regeneration of intrabony defects as well as the intrinsic structural support provided by the remaining number of osseous walls, which influences space maintenance and clot stability [46].

Current statistical analysis revealed that despite PPF+n-HA and PPF groups showed significant improvements in clinical and radiographic outcomes after 6 months, yet no significant difference was evident between them. In a more clinical sense, this investigation demonstrated that both groups were effective in treating intrabony defects with no superiority detected of one intervention over the other. Up-to-date, there is only one randomized clinical trial that showed a statistically significant improvement in patients treated with n-HA+PPF compared to those with PPF alone [16] reporting PPD reduction and bone probing level gain of 4.3 mm with n-HA+PPF versus 2.9mm and 2.6mm in PPF group. The bone probing level was measured with bone sounding, which might explain these superior observations. Nevertheless, it should be noted that a statistical significance doesn't necessarily dictate clinical significance. The term clinical significance should represent a meaningful change of important parameters used to assess periodontal status. According to evidence-based periodontal practice, for a regenerative procedure to be clinically relevant it should achieve at least 2 mm of CAL gain [47].

## Conclusion

Within the limitations of this study it might be concluded that PPF with n-HA bone graft were effective in managing periodontal intrabony defects. Future longitudinal studies with larger sample sizes are warranted to explore their regenerative potentials. Histological evaluation and analysis of biological mediators might improve our understanding regarding the use of n-HA as a possible regenerative material.

**Conflict of Interest:** Dr. Alaa Ashraf declares that she has no conflict of interest. Dr. Weam Battawy declares that she has no conflict of interest. Dr. Dina Fahim declares that she has no conflict of interest. Dr. Noha Ghallab declares that she has no conflict of interest.

**Funding:** The study was funded by personal resources to be re-

funded later by the Ministry of Higher Education, Cairo, Egypt on international publishing.

## Acknowledgment

The authors would like to thank Dr. Khaled Keraa for his help in statistical analysis of this work.

## References

- Cortellini P, Stalpers G, Mollo A, Tonetti MS. Periodontal regeneration versus extraction and dental implant or prosthetic replacement of teeth severely compromised by attachment loss to the apex: A randomized controlled clinical trial reporting 10-year outcomes, survival analysis and mean cumulative cost of recurrence. *J Clin Periodontol*. 2020 Jun;47(6):768-776. Pubmed PMID: 32249446.
- Kao RT, Nares S, Reynolds MA. Periodontal regeneration - intrabony defects: a systematic review from the AAP Regeneration Workshop. *J Periodontol*. 2015 Feb;86(2 Suppl):S77-104. Pubmed PMID: 25216204.
- Tsai SJ, Ding YW, Shih MC, Tu YK. Systematic review and sequential network meta-analysis on the efficacy of periodontal regenerative therapies. *J Clin Periodontol*. 2020 Sep;47(9):1108-1120. Pubmed PMID: 32592595.
- Sculean A, Nikolidakis D, Nikou G, Ivanovic A, Chapple IL, Stavropoulos A. Biomaterials for promoting periodontal regeneration in human intrabony defects: a systematic review. *Periodontol* 2000. 2015 Jun;68(1):182-216. Pubmed PMID: 25867987.
- Haugen HJ, Lyngstadaas SP, Rossi F, Perale G. Bone grafts: which is the ideal biomaterial? *J Clin Periodontol*. 2019 Jun;46 Suppl 21:92-102. Pubmed PMID: 30623986.
- Temraz A, Ghallab NA, Hamdy R, El-Dahab OA. Clinical and radiographic evaluation of amnion chorion membrane and demineralized bone matrix putty allograft for management of periodontal intrabony defects: a randomized clinical trial. *Cell Tissue Bank*. 2019 Mar;20(1):117-128. Pubmed PMID: 30631986.
- Rosen PS, Reynolds MA, Bowers GM. The treatment of intrabony defects with bone grafts. *Periodontol* 2000. 2000 Feb;22:88-103. Pubmed PMID: 11276519.
- Reynolds MA, Aichelmann-Reidy ME, Branch-Mays GL. Regeneration of periodontal tissue: bone replacement grafts. *Dent Clin North Am*. 2010 Jan;54(1):55-71. Pubmed PMID: 20103472.
- Titsinides S, Agrogiannis G, Karatzas T. Bone grafting materials in den-toalveolar reconstruction: A comprehensive review. *Jpn Dent Sci Rev*. 2019 Nov;55(1):26-32. Pubmed PMID: 30733842.
- Thorwarth M, Schultze-Mosgau S, Kessler P, Wiltfang J, Schlegel KA. Bone regeneration in osseous defects using a resorbable nanoparticulate hydroxyapatite. *J Oral Maxillofac Surg*. 2005 Nov;63(11):1626-33. Pubmed PMID: 16243180.
- Bordea IR, Candrea S, Alexescu GT, Bran S, Băciuț M, Băciuț G, et al. Nano-hydroxyapatite use in dentistry: a systematic review. *Drug Metab Rev*. 2020 May;52(2):319-332. Pubmed PMID: 32393070.
- Shi Z, Huang X, Cai Y, Tang R, Yang D. Size effect of hydroxyapatite nanoparticles on proliferation and apoptosis of osteoblast-like cells. *Acta Biomater*. 2009 Jan;5(1):338-45. Pubmed PMID: 18753024.
- Dziak R, Mohan K, Almaghrabi B, Park Y. Nanoceramics for bone regeneration in the oral and craniomaxillofacial complex. In: *Micro and Nano Technologies*. 2nd ed. Subramani K, Ahmed WBT, editors: Elsevier; 2019. 469-94 p.
- Bayani M, Torabi S, Shahnaz A, Pourali M. Main properties of nanocrystalline hydroxyapatite as a bone graft material in treatment of periodontal defects. A review of literature. *Biotechnol. Equip*. 2017 Mar 4;31(2):1-6.
- Chitsazi MT, Shirmohammadi A, Faramarzie M, Pourabbas R, Rostamzadeh An. A clinical comparison of nano-crystalline hydroxyapatite (Ostim) and autogenous bone graft in the treatment of periodontal intrabony defects. *Med Oral Patol Oral Cir Bucal*. 2011 May 1;16(3):e448-53. Pubmed PMID: 21196864.
- Heinz B, Kasaj A, Teich M, Jepsen S. Clinical effects of nanocrystalline hydroxyapatite paste in the treatment of intrabony periodontal defects: a randomized controlled clinical study. *Clin. Oral Investig*. 2010 Oct;14(5):525-31.
- Horváth A, Stavropoulos A, Windisch P, Lukács L, Gera I, Sculean A. Histological evaluation of human intrabony periodontal defects treated with an unsintered nanocrystalline hydroxyapatite paste. *Clin Oral Investig*. 2013 Mar;17(2):423-30. Pubmed PMID: 22552592.
- Bansal M, Kaushik M, Khattak BB, Sharma A. Comparison of nanocrystalline hydroxyapatite and synthetic resorbable hydroxyapatite graft in the treatment of intrabony defects: A clinical and radiographic study. *J Indian Soc Periodontol*. 2014 Mar;18(2):213-9. Pubmed PMID: 24872631.
- Figliuzzi MM, Giudice A, Pileggi S, Scordamaglia F, Marrelli M, Tarullo M, et al. Biomimetic hydroxyapatite used in the treatment of periodontal intrabony pockets: clinical and radiological analysis. *Ann Stomatol (Roma)*. 2016 Jul 19;7(1-2):16-23. Pubmed PMID: 27486507.
- Götz W, Gerber T, Michel B, Lossdörfer S, Henkel KO, Heinemann F. Immunohistochemical characterization of nanocrystalline hydroxyapatite silica gel (NanoBone(r)) osteogenesis: a study on biopsies from human jaws. *Clin Oral Implants Res*. 2008 Oct;19(10):1016-26. Pubmed PMID: 18828818.
- Latifi SM, Fathi MH, Golozar MA. Preparation and characterization of bioactive hydroxyapatite-silica composite nanopowders via sol-gel method for medical applications. *Advances in Applied Ceramics*. 2011;110(1):8-14. doi: 10.1179/174367510X12753884125325.
- Cortellini P, Prato GP, Tonetti MS. The modified papilla preservation technique. A new surgical approach for interproximal regenerative procedures. *J Periodontol*. 1995 Apr;66(4):261-6. Pubmed PMID: 7782979.
- Cortellini P, Prato GP, Tonetti MS. The simplified papilla preservation flap. A novel surgical approach for the management of soft tissues in regenerative procedures. *Int J Periodontics Restorative Dent*. 1999 Dec;19(6):589-99. Pubmed PMID: 10815597.
- Graziani F, Karapetsa D, Mardas N, Leow N, Donos N. Surgical treatment of the residual periodontal pocket. *Periodontol* 2000. 2018 Feb;76(1):150-163. Pubmed PMID: 29193404.
- Martina BD, Chandra RV, Sneha K. Clinical Efficacy of Papilla Preservation Flaps with Regenerative Biomaterials in the Treatment of Periodontal Intrabony Defects—A Systematic Review and Meta-Analysis. *IOSR J. Med. Dent. Sci*. 2020;9:8-18.
- Palacios R. Post-trial access and the new version of the Declaration of Helsinki. *Colomb Med (Cali)*. 2013 Dec 30;44(4):206-7. Pubmed PMID: 24892235.
- Moher D, Hopewell S, Schulz KF, Montori V, Gøtzsche PC, Devereaux PJ, et al. CONSORT 2010 explanation and elaboration: updated guidelines for reporting parallel group randomised trials. *Int J Surg*. 2012;10(1):28-55. Pubmed PMID: 22036893.
- Caton JG, Armitage G, Berglundh T, Chapple ILC, Jepsen S, Kornman KS, et al. A new classification scheme for periodontal and peri-implant diseases and conditions - Introduction and key changes from the 1999 classification. *J Periodontol*. 2018 Jun;89 Suppl 1:S1-S8. Pubmed PMID: 29926946.
- SILNESS J, LOE H. PERIODONTAL DISEASE IN PREGNANCY. II. CORRELATION BETWEEN ORAL HYGIENE AND PERIODONTAL CONDITION. *Acta Odontol Scand*. 1964 Feb;22:121-35. Pubmed PMID: 14158464.
- Löe H. The Gingival Index, the Plaque Index and the Retention Index Systems. *J Periodontol*. 1967 Nov-Dec;38(6):Suppl:610-6. Pubmed PMID: 5237684.
- Singhal R, Nandlal, Kumar A, Rastogi P. Role of space provision in regeneration of localized two-wall intrabony defects using periosteal pedicle graft as an autogenous guided tissue membrane. *J Periodontol*. 2013 Mar;84(3):316-24. Pubmed PMID: 22612365.
- Koduru S, Aghanashini S, Nadiger S, Apoorva SM, Bhat D, Puvvalla B. A Clinical and Radiographic Evaluation of the Efficacy of Nanohydroxyapatite (Sybograf™) versus Bioactive Calcium Phosphosilicate Putty (Novabone®) in the Treatment of Human Periodontal Infrabony Defects: A Randomized Clinical Trial. *Contemp Clin Dent*. 2019 Jan-Mar;10(1):16-23. Pubmed PMID: 32015636.
- Kasaj A, Röhrig B, Zafropoulos GG, Willershausen B. Clinical evaluation of nanocrystalline hydroxyapatite paste in the treatment of human periodontal bony defects—a randomized controlled clinical trial: 6-month results. *J Periodontol*. 2008 Mar;79(3):394-400. Pubmed PMID: 18315420.
- Pietruska M, Skurska A, Pietruski J, Dolińska E, Arweiler N, Milewski R, et al. Clinical and radiographic evaluation of intrabony periodontal defect treatment by open flap debridement alone or in combination with nanocrystalline hydroxyapatite bone substitute. *Ann Anat*. 2012 Nov;194(6):533-7. Pubmed PMID: 22727935.
- Bhardwaj VA, Deepika PC, Basavarajaiah S. Zinc Incorporated Nano Hydroxyapatite: A Novel Bone Graft Used for Regeneration of Intrabony Defects. *Contemp Clin Dent*. 2018 Jul-Sep;9(3):427-433. Pubmed PMID: 30166839.
- Bhattacharjee P, Begam H, Chanda A, Nandi SK. Animal trial on zinc doped hydroxyapatite: a case study. *J. Asian Ceram. Soc*. 2014 Mar 1;2(1):44-51.
- Kamboj M, Arora R, Gupta H. Comparative evaluation of the efficacy of synthetic nanocrystalline hydroxyapatite bone graft (Ostim®) and synthetic microcrystalline hydroxyapatite bone graft (Osteogen®) in the treatment of human periodontal intrabony defects: A clinical and dental scan study.

- J Indian Soc Periodontol. 2016 Jul-Aug;20(4):423-428.Pubmed PMID: 28298825.
- [38]. Dayashankar CP, Deepika PC, Siddaramaiah B. Clinical and Radiographic Evaluation of Citric Acid-Based Nano Hydroxyapatite Composite Graft in the Regeneration of Intrabony Defects - A Randomized Controlled Trial. *Contemp Clin Dent*. 2017 Jul-Sep;8(3):380-386.Pubmed PMID: 29042721.
- [39]. Kasaj A, Willershausen B, Reichert C, Röhrig B, Smeets R, Schmidt M. Ability of nanocrystalline hydroxyapatite paste to promote human periodontal ligament cell proliferation. *J Oral Sci*. 2008 Sep;50(3):279-85.Pubmed PMID: 18818463.
- [40]. Lock J, Liu H. Nanomaterials enhance osteogenic differentiation of human mesenchymal stem cells similar to a short peptide of BMP-7. *Int J Nanomedicine*. 2011;6:2769-77.Pubmed PMID: 22114505.
- [41]. Pilloni A, Pompa G, Saccucci M, Di Carlo G, Rimondini L, Brama M, et al. Analysis of human alveolar osteoblast behavior on a nano-hydroxyapatite substrate: an in vitro study. *BMC Oral Health*. 2014 Mar 20;14:22.Pubmed PMID: 24650194.
- [42]. Aimetti M, Fratini A, Manavella V, Giraudi M, Citterio F, Ferrarotti F, et al. Pocket resolution in regenerative treatment of intrabony defects with papilla preservation techniques: A systematic review and meta-analysis of randomized clinical trials. *J Clin Periodontol*. 2021 Jun;48(6):843-858.Pubmed PMID: 33476402.
- [43]. Graziani F, Gennai S, Cei S, Cairo F, Baggiani A, Miccoli M, et al. Clinical performance of access flap surgery in the treatment of the intrabony defect. A systematic review and meta-analysis of randomized clinical trials. *J Clin Periodontol*. 2012 Feb;39(2):145-56.Pubmed PMID: 22117895.
- [44]. Aimetti M, Romano F, Pigella E, Pranzini F, Debernardi C. Treatment of wide, shallow, and predominantly 1-wall intrabony defects with a bioabsorbable membrane: a randomized controlled clinical trial. *J Periodontol*. 2005 Aug;76(8):1354-61.Pubmed PMID: 16101369.
- [45]. Liñares A, Cortellini P, Lang NP, Suvan J, Tonetti MS; European Research Group on Periodontology (ErgoPerio). Guided tissue regeneration/deproteinized bovine bone mineral or papilla preservation flaps alone for treatment of intrabony defects. II: radiographic predictors and outcomes. *J Clin Periodontol*. 2006 May;33(5):351-8.Pubmed PMID: 16634957.
- [46]. Reynolds MA, Kao RT, Nares S, Camargo PM, Caton JG, Clem DS, et al. Periodontal Regeneration - Intrabony Defects: Practical Applications From the AAP Regeneration Workshop. *Clin Adv Periodontics*. 2015 Feb;5(1):21-29.Pubmed PMID: 32689725.
- [47]. Chambrone L, Armitage GC. Commentary: Statistical Significance Versus Clinical Relevance in Periodontal Research: Implications for Clinical Practice. *J Periodontol*. 2016 Jun;87(6):613-6.Pubmed PMID: 26751344.