

The Protective effect of Ginger and N- Acetyl Cysteine on Ciprofloxacin-Induced Reproductive Toxicity in Male Rats

Nashwa, A. Abu-Aita^{1*}, Kawkab, A. Ahmed² and Samar M Mounair³

¹Department of Clinical Pathology, ²Department of Pathology and ³Department of Pharmacology, Faculty of Veterinary Medicine, Cairo University, Egypt

*Mostafasta_gogo@yahoo.com

Abstract: This study was conducted to evaluate the reproductive toxicity induced by ciprofloxacin antibiotic and the protective effect of ginger and/or N-acetyl cysteine. For this purpose, forty- nine rats were divided into 7 groups (7 rats/group). Group (1) was orally given distilled water (solvent of the used drugs) and kept as a control. Group (2) was daily administered ginger at a dose of 100 mg/kg.b.wt. by a stomach tube for 65 days (5 days/week). Group (3) was daily administered N-acetyl cysteine (NAC) at a dose of 50 mg/kg.b.wt., by a stomach tube for 65 days (5 days/week). Group (4) was orally administered ciprofloxacin (CPX) at a dose of 12.5 mg/kg. b.wt. for 65 days (5 days/week). Group (5) was concurrently administered ciprofloxacin (12.5 mg/kg. b.wt) with ginger (100 mg/kg. b.wt.) by a stomach tube for 65 days (5 days/week). Group (6) was concurrently administered ciprofloxacin (12.5 mg/kg.b.wt) with N-acetyl cysteine (50 mg/kg.b.wt) by a stomach tube for 65 days. Group (7) was concurrently administered ciprofloxacin (12.5 mg/kg.b.wt.) with ginger (100mg/kg.b.wt.) and N- acetyl cysteine (50 mg/kg.b.wt) by a stomach tube for 65 days. Semen samples were collected at the end of experimental period and were used for sperm functions analysis. Blood samples were collected to separate serum for biochemical and hormonal studies. Testes homogenate was used for oxidative stress biomarkers (lipid peroxidation (TBARS), reduced glutathione (GSH) and DNA fragmentation test). Testes, epididymis and seminal vesicles were collected for histopathological study. The obtained data revealed that CPX promotes reproductive toxicity in rats through generating oxidative damage. It induces an adverse effect on reproductive organs weight, sperm parameters (sperm count, sperm motility and viability), reproductive hormones (testosterone, LH, and FSH) and histological structures. Ginger and/or NAC have an important role in ameliorating reproductive toxicity induced by CPX through restoring the oxidant-antioxidant balance.

[Nashwa, A. Abu-Aita, Kawkab, A. Ahmed and Samar M Mounair. The protective effect of Ginger and N- Acetyl Cysteine on Ciprofloxacin-Induced Reproductive Toxicity in Male Rats. Journal of American Science 2011;7(7):741-752]. (ISSN: 1545-1003). <http://www.americanscience.org>.

Keywords: Ciprofloxacin; Reproductive Dysfunction; Oxidative stress; Ginger; N-acetyl cysteine; Antioxidant effect ; Rat

1. Introduction:

Infertility is one of the major health problems in animals. Several conditions can interfere with spermatogenesis and reduce sperm quality and production. Drug treatment, chemotherapy, toxins and environmental factors can have harmful effect on spermatogenesis and sperm normal production (Amann and Berndtson, 1986).

Antibiotics are used in the treatment of many infections and as anticancer, antiprotozoal and antihelminthic. However, antimicrobial therapy has been shown to significantly affect semen parameters in human and animal models (Schlegel et al., 1991).

Ciprofloxacin (CPX) is one of the newer generations of antibacterial agents. It belongs to the family of fluoroquinolones with a very broad spectrum against many microbial pathogens and has been approved in more than 100 countries world-wide (Wolfson and Hooper, 1985). It is used to combat various infectious diseases in man and animals (Stein, 1996).

In vivo genotoxicity studies suggest ciprofloxacin as safe for therapeutic use (Herbold et al., 2001). However, other studies have demonstrated ciprofloxacin to significantly impair both testicular function and structure (Abd-Allah et al., 2000 and Demir et al., 2007).

Recently, it has been observed that the oxidative damage to testicular cells induced by various xenobiotics can result in testicular dysfunction and male infertility (Aggarwal and Said, 2005 and Shrilata and Muralidhara, 2007).

Oxidants and antioxidants have attracted widespread interest in nutrition research, biology and medicine. It has become clear that constant generation of pro-oxidants, including oxygen free radicals, is an essential attribute of aerobic life (Acharya et al., 2008). Therefore, the role of nutritional and biochemical factors in reproduction and sub- fertility treatment is very important.

Ginger is a strong anti-oxidant substance and may either mitigate or prevent generation of free

radicals. It is considered a safe herbal medicine with only few and insignificant adverse side effects (Ali et al., 2008). The main pharmacological actions of ginger include immuno-modulatory, anti-tumorigenic, anti-inflammatory, anti-apoptotic, anti-hyperglycemic, anti-lipidemic and anti-emetic actions (Arash et al., 2009).

N-acetylcysteine (NAC), a potent antioxidant derives from the amino acid L-Cysteine. It has been used clinically for decades for the treatment of many diseases. It has been also used as a chelator of heavy metals to protect against oxidative stress and prevent damage of cells (De Vries and De Flora, 1993).

The aim of the present study is to evaluate the reproductive toxicity induced by ciprofloxacin antibiotic and the protective effect of ginger and/or N-acetylcysteine in male rats.

2. Materials and Methods

Chemicals and Drugs:

Ciprofloxacin: Ciprofloxacin was purchased from Organopharmaceutical and Chemical Industries Co (Organopharma) in the form of Ciprofloxacin (lactate) infusion.

N-Acetyl cysteine: It was obtained from Sedico Pharmaceutical Co.

Ginger: Ginger was purchased from Mepaco Pharmaceutical Co.

Animals:

The present investigation was carried out on forty-nine apparently healthy male albino rats weighing 120-150 g. Rats were obtained from the Faculty of Vet. Med., Cairo University (laboratory animals housing unit). Rats were left for two weeks for acclimatization before starting the experiment. They were kept in metal cages, fed on basal diet and given water ad-libitum.

Experimental groups:

Rats were randomly divided into (7) groups of 7 rats each and were treated as follows:

Group(1) was orally given distilled water (solvent of the used drugs) and kept as a control.

Group(2) was daily administered ginger at a dose of 100 mg/kg.b.wt. (Arash et al., 2009) by a stomach tube for 65 days (5 days/week).

Group(3) was daily administered N-acetyl cysteine (NAC) at a dose of 50 mg/kg.b.wt (Ebenezer et al., 2008) by a stomach tube for 65 days (5 days/week).

Group(4) was orally administered ciprofloxacin (CPX) at a dose of 12.5 mg/kg.b.wt. (Arash et al., 2008) for 65 days (5 days/week).

Group(5) was concurrently administered ciprofloxacin (12.5 mg/kg.b.wt) with ginger at a dose of 100 mg/kg.b.wt. by stomach tube for 65 days (5 days/week).

Group(6) was concurrently administered ciprofloxacin (12.5mg/kg.b.wt) with N-acetyl cysteine (50 mg/kg.b.wt) by stomach tube for 65 days (5 days/week).

Group(7) was concurrently administered ciprofloxacin (12.5mg/kg.b.wt.) with ginger (100mg/kg.b.wt.) and N-acetyl cysteine (50 mg/kg.b.wt) by stomach tube for 65 days (5 days/week).

Collection and Preparation of Samples:

1. Blood samples:

Blood samples were collected from the retro-orbital venous plexus of rats of each group at the end of the experimental period. Samples were collected in clean centrifuge tubes and were allowed to clot, then centrifuged at 3000 rpm for 10 minutes for serum separation. Serum was used for biochemical and hormonal studies.

2. Semen samples:

Semen samples were collected from cauda epididymis and used for sperm functions analysis.

3. Tissue specimens:

Testes were taken from the sacrificed rats in all experimental groups. They were perfused with PBS (phosphate buffered saline), collected in clean dry plastic bags and kept at -40° c for determination of lipid peroxidation (TBARS), reduced glutathione (GSH) and DNA fragmentation test. Specimens from testes, epididymis and seminal vesicles were fixed in 10 % neutral buffered formalin and were used for the histopathological study.

Methods:

1. Body weight:

At the end of the experimental period, the body weight of each individual rat was measured.

2. Reproductive organ indices:

2.1 Reproductive organs weight:

Rats were sacrificed after the last day of treatment and reproductive organs; testes, caudae epididymis and seminal vesicles were weighed.

2.2 Sperm functions analysis:

Sperm count:

Sperm cell count was determined according to the technique adopted by Bearden and Fuquay (1980) using an improved Neubauer haemocytometer.

Mass motility

The epididymal sperm content was obtained by maceration of the tail of epididymis on a dry, clean and warm slide; mixing well with a drop of warm normal saline solution and immediately examined under (10X) objective lens of a light microscope for determination of mass motility percentage of spermatozoa according

to **Bearden and Fuquay (1980)**.

Live and dead sperms:

A drop of epididymal content of each rat was mixed with an equal drop of eosin-nigrosin stain prepared in accordance with **Barth and Oko (1994)**. Thin films were made by spreading the stained content onto clean slides and quickly dried. Viable sperm remains colorless. One hundred sperm cells per rat were scored for determining the viability percent.

3. Biochemical analysis:

3.1 Serum enzymes

Serum samples were used for determination of the activities of lactate dehydrogenase (LDH) according to the method of **Friedman and young (1997)** and acid phosphatase (ACP) according to **Kind and King (1954)**. Activities of enzymes were assayed using commercial diagnostic kits obtained from Biodiagnostic Co., Egypt.

3.2 Hormonal assay:

Determination of serum Testosterone, Follicle-stimulating hormone (FSH) and Luteinizing hormone (LH)

Testosterone determination was performed according to the method adopted by **Jaffe and Behrman (1974)** by using the coat-A-count technique, (radioimmunoassay). Follicle stimulating hormone (FSH) and Luteinizing hormone (LH) determination were performed according to **Santner et al., (1981)** by the coat-A-count technique (immunoradiometric assay).

3.3 Oxidant –antioxidants parameters:

Lipid peroxidation (LPO) Assay:

Malondialdehyde (MDA) level was estimated in the testicular homogenate according to the method of **Ohkawa et al., (1979)**. Thiobarbituric acid (TBA) reacts with malondialdehyde (MDA) in acidic medium at temperature of 95°C for 30 min. to form thiobarbituric acid reactive substances (TBARS). The absorbance of the resultant pink product can be measured colorimetrically at 534 nm.

Reduced glutathione (GSH):

The reduced glutathione (GSH) content of the testis homogenate was determined using the method described by **Beutler et al., (1963)**. The method based on the reduction of 5,5'-dithiobis (2-nitrobenzoic acid DTNB) with glutathione (GSH) to produce a yellow compound. The reduced chromogen is directly proportional to GSH concentration and its absorbance can be measured at 405 nm.

3.4 DNA fragmentation assay:

DNA fragmentation assay was performed according to **Sellins and Cohen (1987)**. The testes were lysed in 1ml buffer (10 mM Tris-HCl, pH 7.4, 10

mM EDTA, 0.5% Triton x100). The pellets contain total intact DNA (P) and the supernatants contain smaller fragments of DNA (S). They were treated separately with 0.5 ml of 25% trichloroacetic acid (TCA) and then both sets were left overnight at 4°C. DNA precipitated was collected by centrifugation and each sample was treated with 80 µl of 5% TCA followed by heat treatment at (90°C) for 15 min. Freshly prepared 1 ml diphenylamine reagent was added to each sample. The tubes were allowed to stand overnight at room temperature and their optical densities were recorded at 600 nm. DNA samples were electrophoresed in (1.2%) agarose gel for 90 min at 5 V/cm and visualized with ethidium bromide. Percent DNA fragmentation was calculated by the following equation: % DNA fragmentation = $[S/(S + P)] \times 100$.

4. Histopathological examination:

Tissue specimens from testes, epididymis and seminal vesicles of all experimental rats were collected at the end of the study and fixed in neutral buffered formalin, processed by conventional method, embedded in paraffin, sectioned at 4-5 µm and stained by Haematoxylin and Eosin (**Bancroft et al., 1996**).

5. Statistical analysis:

Data were compared across groups using analysis of variance (ANOVA). Data were expressed as mean ± S.D. Levels of significance of $P < 0.05$ were chosen to identify the significant differences (**Snedecor and Cochran, 1982**).

3. Results

Effect on body weight

Mean values of rats' body weight of each experimental group are illustrated in **table (1)**. Non significant difference was recorded between CPX administered group and control group.

Weight of individual male reproductive organs:

Results of reproductive organs (testes, epididymis and seminal vesicles) weights are illustrated in **table (1)**. The obtained data revealed a significant decrease in the absolute weights of testes, epididymis and seminal vesicles in rats received ciprofloxacin compared to control group. Co-administration of either ginger or NAC with ciprofloxacin antibiotic induced significant increase in these reproductive organs weight compared to CPX treated group. While concurrent administration of both ginger and NAC with ciprofloxacin antibiotic (group 7) induced a remarkable increase.

Sperm count, motility and viability:

Data of the epididymal sperm count, sperm motility and viability % are presented in **Table (2)**. A

marked reduction in sperm count, sperm motility and viability was recorded in CPX treated group (group 4) when compared with the corresponding group of control animals. Co-administration of ginger and/or NAC with ciprofloxacin attenuates the decrease in sperm count and motility in comparable to control group. On the other hand, concurrent administration of ginger or NAC with ciprofloxacin improves sperm viability % but not reaching the values of control. Administration of both ginger and NAC with ciprofloxacin induced significant increase in sperm viability % reaching the values of control group.

Results of biochemical analyses:

Serum enzymes

Changes in serum acid phosphatase, and lactate dehydrogenase (LDH) activities are illustrated in **Table (3)**. From the obtained results, it was observed that CPX induced a significant increase in the activities of serum LDH and ACP compared to control group. The concurrent treatment of CPX with ginger and/or NAC decreased the elevated activities of these enzymes to an appreciable extent compared with CPX treated rats.

Results of hormonal study:

Hormonal assay revealed significant decrease in the levels of testosterone, FSH and LH ($p > 0.05$) of CPX treated rats when compared with control group (**Table 3**). The co-administration of ginger with CPX

increased the serum levels of testosterone, FSH and LH reaching that of controls levels. Whereas, co-administration of NAC with CPX significantly elevated the serum levels of testosterone, FSH and LH in comparable to CPX treated rats.

Lipid Peroxidation and anti-oxidative enzyme:

Mean levels of testicular malondialdehyde, and reduced glutathione activity among studied groups are shown in **Table (4)**. The obtained results revealed a significant increase in the mean values of TBARS and significant drop in GSH activity ($p < 0.05$) in CPX treated rats versus control group. Concurrent administration of CPX with ginger and/or NAC caused significant decrease in lipid peroxidation and a remarkable ($p < 0.05$) increase in the GSH level compared with the CPX treated rats.

DNA fragmentation test:

Significant increases in the DNA fragmentation levels were recorded in the testicular homogenates of CPX treated rats in comparable with control group. Administration of ginger and/or NAC to CPX induces a remarkable decrease in testicular DNA fragmentation levels in comparable to CPX treated rats (**Table 4**). Non significant DNA fragmentation levels were recorded in the second group administered ginger compared to control group.

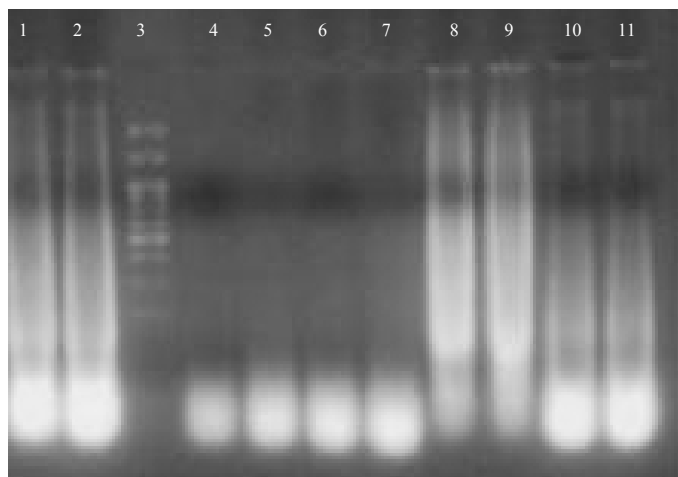


Fig. (1): The DNA was electrophoresed on TAE agarose gel for one hour at 80 V. The DNA fragmentation pattern was visualized by ethidium bromide. Lane1-2: CPX, Lane3: DNA ladder, Lane4-5: Control, Lane6-7: Ginger, Lane8-9: NAC and Lane10-11: CPX+Gin.+NAC

Table 1: Effects of ciprofloxacin (CPX), Ginger (Gin.) and N-acetyl cysteine (NAC) on the body weight and reproductive organs weights of rats.

Parameters	Control	Ginger	NAC	CPX	CPX + Gin.	CPX + NAC	CPX+Gin.+NAC
Body Wt. (g)	267.0 ± 2.65 ^{ab}	269.3 ± 3.06 ^a	264.0 ± 3.61 ^b	268.7 ± 2.31 ^{ab}	270.3 ± 4.51 ^a	268.0 ± 2.00 ^{ab}	269.0 ± 1.00 ^{ab}
Testes (g)	1.61 ± 0.03 ^b	1.72 ± 0.07 ^a	1.59 ± 0.04 ^b	1.26 ± 0.05 ^c	1.47 ± 0.03 ^c	1.40 ± 0.01 ^d	1.65 ± 0.04 ^{ab}
Epididymis (g)	0.36 ± 0.04 ^{ab}	0.41 ± 0.03 ^a	0.35 ± 0.04 ^{ab}	0.22 ± 0.03 ^c	0.32 ± 0.03 ^b	0.31 ± 0.05 ^b	0.37 ± 0.03 ^{ab}
Seminal ves.(g)	0.60 ± 0.04 ^a	0.61 ± 0.06 ^a	0.58 ± 0.04 ^{ab}	0.26 ± 0.03 ^d	0.51 ± 0.03 ^b	0.42 ± 0.03 ^c	0.54 ± 0.04 ^{ab}

Means with different superscripts (a-d) within a row are significantly different at P < 0.05

Table 2: Effects of ciprofloxacin (CPX), Ginger (Gin.) and N-acetyl cysteine (NAC) on sperm parameters.

Parameters	Control	Ginger	NAC	CPX	CPX + Gin.	CPX + NAC	CPX+Gin.+NAC
Sperm count (×10 ⁶ /ml)	71.36 ± 4.51 ^a	70.40 ± 4.51 ^a	65.40 ± 3.97 ^a	51.6 ± 4.45 ^d	67.4 ± 4.67 ^{ab}	61.40 ± 3.97 ^c	66.4 ± 5.94 ^{ab}
Motility (%)	81.67 ± 2.68 ^a	79.80 ± 2.68 ^a	78.80 ± 2.12 ^a	65.00 ± 3.61 ^c	79.6 ± 1.52 ^a	75.00 ± 2.12 ^b	79.4 ± 4.45 ^a
Viability (%)	83.2 ± 2.39 ^a	84.00 ± 2.65 ^a	78.8 ± 3.42 ^{bc}	48.40 ± 3.05 ^d	79.60 ± 1.14 ^{bc}	77.60 ± 1.82 ^c	81.60 ± 2.70 ^{ab}

Means with different superscripts (a-d) within a row are significantly different at P < 0.05

Table 3: Effects of ciprofloxacin (CPX), Ginger (Gin.) and N-acetyl cysteine (NAC) on some serum enzymes and hormones.

Parameters	Control	Ginger	NAC	CPX	CPX + Gin.	CPX + NAC	CPX+Gin.+NAC
ACP (U/L)	12.67 ± 2.57 ^c	15.4 ± 2.60 ^{bc}	14.13 ± 2.27 ^{bc}	22.93 ± 2.53 ^a	18.37 ± 2.18 ^{ab}	17.7 ± 2.61 ^b	16.1 ± 3.57 ^{bc}
LDH (U/L)	208.9 ± 1.87 ^e	206.13 ± 1.80 ^e	205.47 ± 2.84 ^e	300.8 ± 2.88 ^a	259.13 ± 2.72 ^b	223.33 ± 3.06 ^c	214.93 ± 2.61 ^d
FSH (mIU/ml)	0.65 ± 0.04 ^a	0.62 ± 0.04 ^{ab}	0.58 ± 0.05 ^{bc}	0.36 ± 0.04 ^e	0.62 ± 0.04 ^{ab}	0.48 ± 0.03 ^d	0.55 ± 0.03 ^c
LH (mIU/ml)	0.19 ± 0.04 ^a	0.20 ± 0.02 ^a	0.14 ± 0.03 ^{bc}	0.05 ± 0.02 ^d	0.16 ± 0.02 ^{ab}	0.10 ± 0.02 ^c	0.11 ± 0.02 ^c
Testosterone (ng/ml)	1.89 ± 0.11 ^a	1.79 ± 0.17 ^{ab}	1.48 ± 0.15 ^{cd}	0.99 ± 0.10 ^e	1.75 ± 0.08 ^{abc}	1.58 ± 0.17 ^{bcd}	1.35 ± 0.16 ^d

Means with different superscripts (a-e) within a row are significantly different at P < 0.05

Table 4: Effects of ciprofloxacin (CPX), Ginger (Gin.) and N-acetyl cysteine (NAC) on testicular Malondialdehyde (MDA), reduced glutathione (GSH) and DNA fragmentations (Frag.).

Parameters	Control	Ginger	NAC	CPX	CPX + Gin.	CPX + NAC	CPX+Gin.+NAC
MDA (mmol / g. tissue)	18.67 ± 3.57 ^e	15.18 ± 3.07 ^e	19.13 ± 3.25 ^{de}	39.95 ± 3.09 ^a	25.63 ± 3.29 ^{bc}	30 ± 2.00 ^b	24.33 ± 2.52 ^{cd}
GSH (mmol / g. tissue)	0.28 ± 0.04 ^{ab}	0.32 ± 0.04 ^a	0.23 ± 0.04 ^{bc}	0.08 ± 0.02 ^e	0.19 ± 0.03 ^{cd}	0.15 ± 0.04 ^d	0.21 ± 0.04 ^{cd}
DNA Frag. (%)	48.00 ± 0.83 ^d	47.78 ± 1.61 ^d	45.56 ± 0.93 ^e	64.74 ± 1.51 ^a	53.98 ± 0.90 ^c	59.36 ± 1.19 ^b	52.44 ± 1.16 ^c

Means with different superscripts (a-e) within a row are significantly different at P < 0.05

Histopathological results:

Microscopically, testes of rats treated with CPX revealed marked necrosis of spermatogoneal cells lining seminiferous tubules (Fig.2) associated with incomplete spermatogenesis. Degeneration of germ cells lining seminiferous tubules with desquamation of those cells and the tubular lumen were filled with degenerated germ cells (Fig.3). Improvement in the histopathological picture was noticed in examined sections from rats treated with combined CPX and ginger, CPX and N acetyl cysteine as well as rats treated with CPX and ginger and N acetyl cysteine as the examined sections revealed apparent normal seminiferous tubules (Fig.4). Concerning epididymis, examined sections of rats treated with CPX showed interstitial oedema in between the epididymal tubules together with congestion of blood vessels (Fig.5). Hyperplasia of epididymal epithelium with appearance of pale vacuolated

epithelial cells (**PVEC**) containing homogenous amorphous material was noticed in all examined sections (Fig.6). Epididymis of rats treated with both CPX and ginger revealed no histopathological changes (Fig.7). Epididymis of rats treated with CPX and N-acetyl cysteine revealed interstitial oedema in between the epididymal tubules (Fig. 8) together with interstitial inflammatory cells infiltration (Fig.9). No histopathological changes were noticed in examined sections from rats treated with CPX and ginger and N acetyl cysteine.

Regarding seminal vesicles, examined sections from rats treated with CPX showed hyperplasia of epithelial lining (Fig.10) and leucocytic inflammatory cells infiltrating the muscular layer (Fig.11). Conversely, examined sections of rats treated with both CPX and ginger revealed no histopathological changes (Fig.12). Examined sections from rat treated with CPX and N-acetyl cysteine showed no histopathological changes except hyperplasia of epithelial lining (Fig.13). Seminal vesicle of rats treated with CPX and ginger and N-acetyl cysteine revealed no histopathological alterations.

Microscopically, all examined sections from testes, epididymis and seminal vesicles of control untreated rat, rats treated with ginger alone and rat treated with N-acetyl cysteine alone revealed no histopathological alterations.

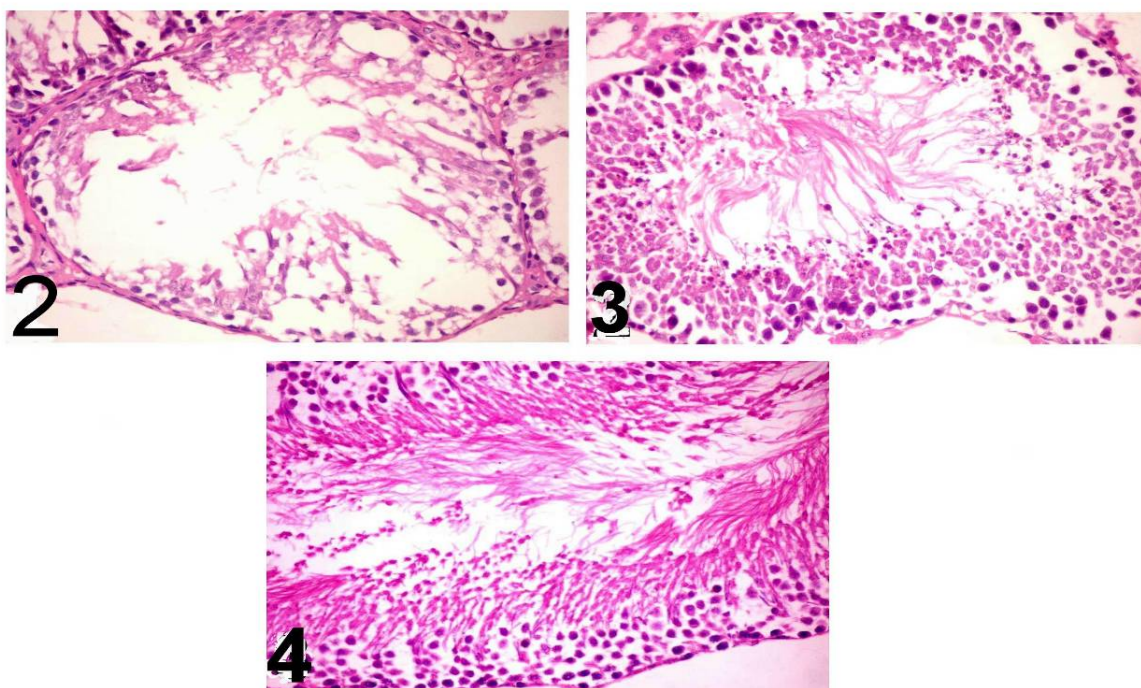
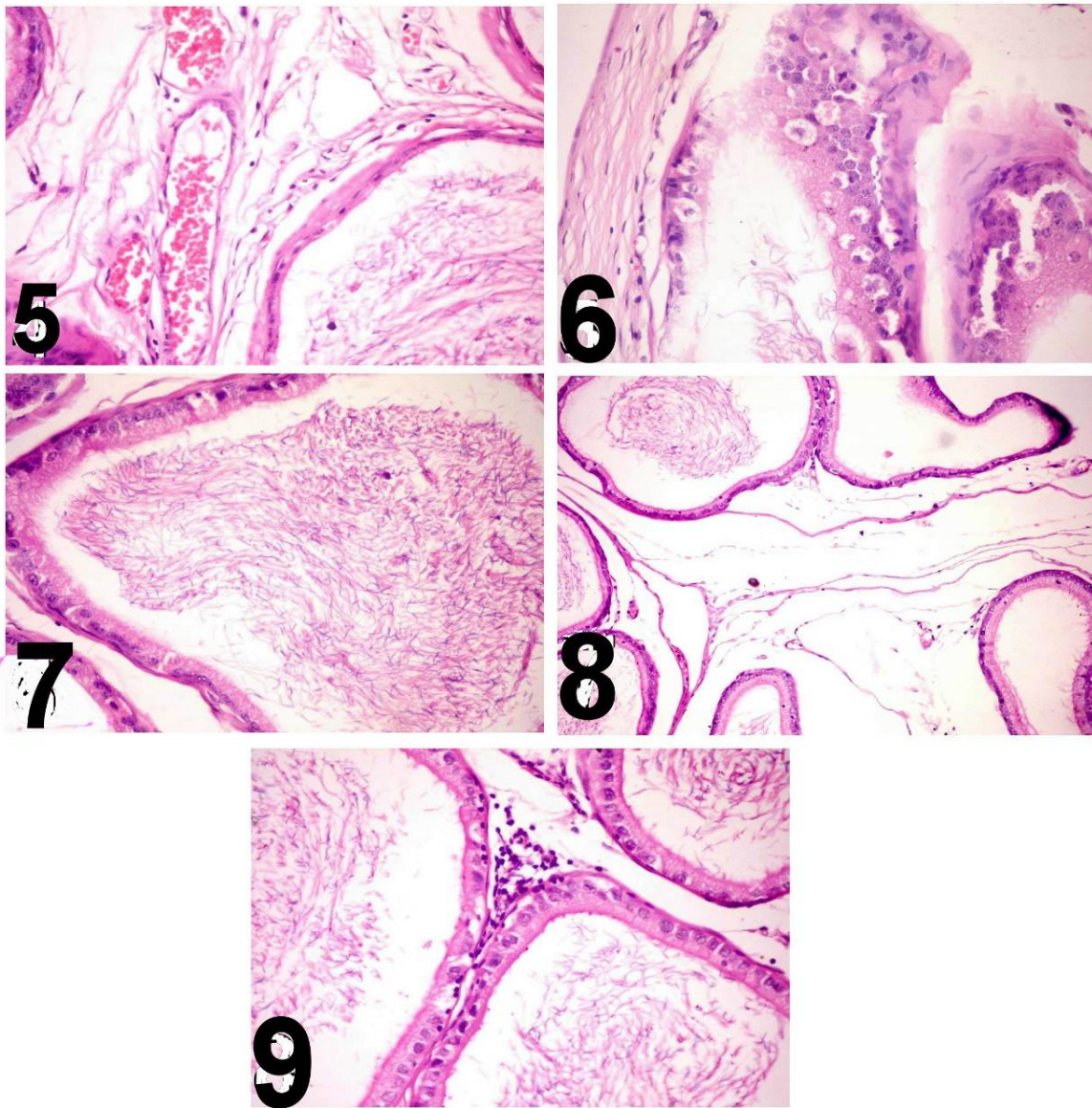


Fig. (2): Testis of rat treated with CPX showing marked necrosis of spermatogoneal cells lining seminiferous tubules (H & E X 400)

Fig. (3): Testis of rat treated with CPX showing degeneration and desquamation of germ cells lining seminiferous tubules and the tubular lumen was filled with degenerated germ cells (H & E X 400)

Fig. (4): Testis of rat treated with both CPX and ginger showing apparent normal seminiferous tubules (H & E X 400)



- Fig. (5): Epididymis of rat treated with CPX showing interstitial oedema in between the epididymal tubules together with congestion of blood vessels (H & E X 400)
- Fig. (6): Epididymis of rat treated with CPX showing hyperplasia of epididymal epithelium with appearance of pale vacuolated epithelial cells (**PVEC**) containing homogenous amorphous material (H & E X 400)
- Fig. (7): Epididymis of rats treated with both CPX and ginger showing no pathological changes (H & E X 400)
- Fig. (8): Epididymis of rats treated with CPX and N-acetyl cysteine showing interstitial oedema in between the epididymal tubules (H & E X 200)
- Fig. (9): Epididymis of rat treated with CPX and N-acetyl cysteine showing interstitial inflammatory cells infiltration (H & E X 400)

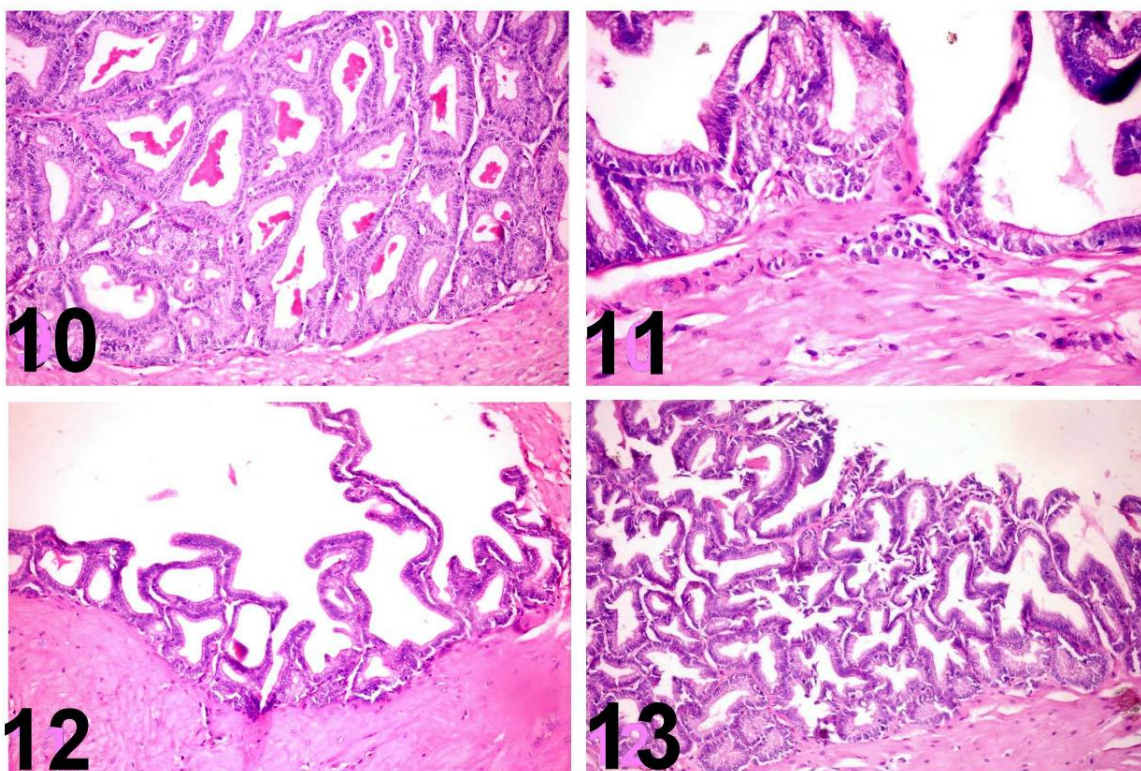


Fig. (10): Seminal vesicle of rat treated with CPX showing hyperplasia of epithelial lining (H & E X 400)

Fig. (11): Seminal vesicle of rat treated with CPX showing leucocytic inflammatory cells infiltrating the muscular layer (H & E X 400)

Fig. (12): Seminal vesicle of rat treated with both CPX and ginger showing no pathological alterations (H & E X 400)

Fig. (13): Seminal vesicle of rat treated with both CPX and N- acetyl cysteine showing hyperplasia of epithelial lining (H & E X 400)

4. Discussion

Ciprofloxacin is known to be one of the best drugs for the treatment of many bacterial infections. However, some reports (**Abd-Allah et al., 2000** and **Demir et al., 2007**) stated that CPX significantly impair testicular function and structure.

In the present study, administration of CPX did not affect the body weight of the animals but caused a significant reduction in the weights of testes, epididymis and seminal vesicles relative to the control group. The weight of the testis is largely dependent on the mass of the differentiated spermatogenic cells; the reduction in the weight of the testis may be due to decreased number of germ cells, inhibition of spermatogenesis and steroidogenic enzyme activity (**Chapin et al., 1997** and **Takahashi and Oishi, 2001**). Our results are confirmed histopathologically as testes of CPX treated rat revealed marked necrosis of spermatogoneal cells lining seminiferous tubules (Fig.1) associated with incomplete spermatogenesis. Degeneration and desquamation of germ cells lining

seminiferous tubules and the tubular lumen was filled with degenerated germ cells. The observed weights loss of the accessory sex organs may be due to reduced bioavailability of sex hormones (**Schrade, 2003**). Our results are in agreement with previous findings of **Sarkar et al., (2003)**. On the other hand, concurrent administration of ginger and/or NAC with CPX clearly restored the reproductive organ weights towards normal which may be due to their androgenic activity (**Kamtchouing et al., 2002** and **Jana et al., 2006**).

Epididymal sperm count, motility and viability provide a direct measure of fertility in animals (**Lemasters and Selevan, 1993**). A marked reduction in sperm count, sperm motility and viability were recorded in CPX treated group as compared to respective control. The diminution of these sperm parameters may be referred to the interference of ciprofloxacin with the energy production process required for sperm vitality and motility (**Folgero et al., 1993**). Furthermore, CPX activates caspase-3, which has an important role in apoptosis resulting in increases

in the percentage of germ cell apoptosis (**Zhang et al., 2003**). This is in agreement with that of **Abd-Allah et al., (2000)** who reported that ciprofloxacin treatment (4.5 and 9 mg/100 gm b.wt.) for 15 days in rats induced a marked reduction in sperm count, motility and daily sperm production. On the other hand, co-treatment of CPX with ginger and/or NAC attenuated spermatogenic and testicular damage induced by CPX treatment as shown by the return of sperm count, motility and viability towards normal control values. The obtained data are parallel with **Ebenezer et al., (2008)** who recorded that co-administration of vitamin C and NAC with tetracycline significantly ameliorated its adverse effect on sperm motility, sperm count and percentage of live spermatozoa. It also agrees with **Zahedi et al., (2010)** who found that administration of ginger at a dose of (100mg/kg) significantly mitigated the toxic effect of gentamicin on sperm parameters (motility % and epididymal sperm reserves) of male rats.

Analysis of serum enzymes revealed a significant increase in lactate dehydrogenase and acid phosphatase activities of CPX treated groups relative to the control group. LDH is an enzyme found in many body tissues that is released into the blood stream when cellular damage occurs. The increased LDH activity in CPX treated rats denotes its cytotoxic effect on germ cells. It may be elevated in most types of testicular cancer (**Stenman and Alftan, 2002**). Acid phosphatase is present in the lysosomes of Sertoli cells (**Peruquetti et al., 2010**). The elevated activity of serum ACP in CPX treated group reflects the release of this enzyme from the lysosomes of the degenerating cells and rapid catabolism of the injured germ cells (**Chidambaram Prahalthan et al., 2005**). Similar changes have been reported with a number of chemicals causing testicular toxicity.

The concurrent treatment of CPX with ginger and/or NAC influences the activities of these enzymes to an appreciable extent and suggests the cytoprotective effect of ginger and NAC in preventing testicular damage.

Concerning reproductive hormonal changes in our study, a significant decrease in the concentrations of testosterone, LH and FSH were recorded in CPX treated group compared to control group.

Testosterone is the main steroid sex-hormone in male albino rats, it is secreted by Leydig cells of the testes under the control of complex neuroendocrine interactions (**Robinson and Hunteable, 1988**). High level of testosterone in testis is critically required for normal spermatogenesis, development and maintenance of sperm morphology and normal physiology of seminiferous tubules (**Sharpe et al., 1988** and **Sharpe et al., 1992**). The significant decrease of testosterone level may be a result of direct

damage of CPX on Leydig cells, which are the main site of testicular androgen biosynthesis. FSH is also critical for sperm production. It supports the function of Sertoli cells, which in turn support many aspects of sperm cell maturation. Normal testicular function is dependent on FSH and testosterone which is absolutely required for normal spermatogenesis. Moreover, decreased testosterone level of CPX treated rats may occur due to the reduced level of LH (**Shaw et al., 1979** and **Kerr and Sharpe, 2006**) as circulating LH is responsible for maintaining normal plasma testosterone concentrations. **Kumari et al., (2008)** recorded that ciprofloxacin induced a significant decrease in the testosterone level associated with degenerative changes in the seminal vesicle.

The restoration of testosterone, LH, and FSH levels to normal after concomitant administration of CPX with ginger and/or N acetyl cysteine might have stimulated the production of quantitatively and structurally normal sperm (**Anahara et al., 2008** and **Ebenezer et al., 2008**).

Sperm plasma membrane has a high content of polyunsaturated fatty acids which is easily susceptible to lipid peroxidation caused by oxidative stress (**Agarwal et al., 2005**). Estimation of end products of lipid peroxidation such as malondialdehyde (MDA) is an index of the extent of oxidative damage to cellular structures (**Sharma and Agarwal, 1996**).

Ciprofloxacin treated rats showed an elevation in MDA level relative to control group. The increased testicular MDA level could be attributed to the concomitant increase in generation of free radicals (ROS), such as peroxide radical in the testes of the ciprofloxacin treated rats (**Weyers et al., 2002**). Meanwhile, there was a significant reduction in the glutathione (GSH) level in the testes of CPX treated rats in comparable to control group. This reduction could be due to the enhanced utilization of antioxidants system as an attempt to detoxify the free radicals generated by CPX treatment.

Excessive ROS production that exceeds critical levels can overwhelm all antioxidants defense strategies of spermatozoa and seminal plasma causing oxidative stress that damages the biological membranes in the testes. This in turn may cause the degeneration of the spermatogenic and Leydig cells, which disrupts spermatogenesis and reduces sperm counts (**Latchoumycandane et al., 2002**). The sperms themselves may also be damaged by the oxidative effects of CPX which affect the activities of mitochondrial enzymes and the structure of the microtubules in the sperm.

The increased lipid peroxidation with the reduced glutathione of testicular homogenates in the present investigation may be the initial event in producing testicular damage by CPX that could be linked to its

effects on reproductive organs weights, sperm parameters (sperm count, sperm motility and viability) and hormonal disturbances. The obtained results are parallel with **Salem et al., (2008)** and **Zahedi et al., (2010)**.

The testicular toxicity induced by CPX in our study is further confirmed by increased DNA fragmentation levels in the testicular homogenates of CPX treated rats in comparable with control group. The obtained results may be attributed to the adverse effect of free radicals induced by CPX on the DNA (**Itoh et al., 2006**).

Since sperm morphology is controlled by various autosomal and Y-specific genes (**Forejt, 1976** and **Krazanowska, 1976**), DNA damage may also reduce sperm motility and fertility. Numerous in vitro studies have documented that oxidative damage to sperm can subsequently lead to DNA damage, alter membrane functions, impair motility characteristics, and alter capacity to undergo acrosomal reaction and fertilization (**Vernet et al., 2004**).

Co- administration of ginger and/or NAC with CPX induced a significant decrease in the MDA and DNA fragmentation level with a remarkable increase in the concentration of the reduced glutathione (GSH) relative to the fourth group which administered CPX.

Ginger increased the activities of testicular antioxidants as it contains a wide variety of active phenolic ingredients (Zingerone, Gingerdiol, Zingibrene, gingerols and shogaols) (**Kamtchouing et al., 2002** and **Jorsaraei et al., 2008**). **Ahmed et al., (2000)** found that ginger significantly lowered lipid per-oxidation by maintaining the activities of the antioxidant enzymes; superoxide dismutase, catalase and glutathione peroxides in rats. Whereas, NAC plays an important role in the production of glutathione, which provides intracellular defense against oxidative stress induced DNA damage (**Shan et al., 1990**). So the antioxidant characters of both NAC and Ginger could protect DNA and other important molecules from oxidation and damage, and can improve sperm quality and consequently increase fertility rate.

Indeed, our study revealed that CPX promotes reproductive toxicity in rats through generating oxidative damage. It induces an adverse effect on reproductive organs weights, sperm parameters (sperm count, sperm motility and viability), reproductive hormones (testosterone, LH, and FSH) and induces histopathological alterations. Ginger and NAC have an important role in ameliorating reproductive toxicity induced by CPX through restoring the oxidant-antioxidant balance.

Corresponding author

Nashwa, A. Abu-Aita Department of Clinical Pathology, Faculty of Veterinary Medicine, Cairo University, Egypt
Mostafasta_gogo@yahoo.com

References

- Abd-Allah, A.R., Aly, H.A., Moustafa, A.M., Abdel-Aziz A.A. and Hamada F.M., 2000.** Adverse testicular effects of some quinolone members in rats. *Pharmacol. Res.*, 41: 211-219.
- Acharya, U.R., Mishra, M., Patro, J. and Panda, M.K., 2008.** Effect of vitamins C and E on spermatogenesis in mice exposed to cadmium. *Reprod. Toxicol.*, 25: 84- 8.
- Aggarwal, A. and Said, T.M., 2005.** Oxidative stress, DNA damage and apoptosis in male infertility: A clinical approach. *Br. J. Urol. Int.*, 95:503-7.
- Agarwal, A., Prabakaran, S.A. and Said T.M., 2005.** Prevention of oxidative stress injury to sperm. *J. Androl.*, 26:654-660.
- Ahmed, R.S., Seth, V. and Banerjee, B.D., 2000.** Influence of dietary ginger on antioxidant defence system in rat: comparison with ascorbic acid. *Ind. J. Exp. Biol.*, 38:604-606.
- Ali, B.H., Blunden, G., Tanira, M.O. and Nemmar, A., 2008.** Some phytochemical, pharmacological and toxicological properties of ginger (*Zingiber officinale* Roscoe): a review of recent research. *Food Chem. Toxicol.*, 46:409-420.
- Amann, R.P. and Berndtson, W.E., 1986.** Assessment of procedures for screening agents for effects on male reproduction: effects of dibromochloropropane (DBCP) on the rat. *Fundam. Appl. Toxicol.*, (7): 244-255.
- Anahara, R., Toyama, Y., and Mori, C., 2008.** Review of the histological effects of the anti-androgen, flutamide, on mouse testis. *Reprod. Toxicol.*, 25: 139- 43.
- Arash, K., Fatemeh, F., Mohammad, N. Amir, A., Khaki, Chelar, C., Marefat G., and Mohammad, H., 2009.** The effects of Ginger on spermatogenesis and sperm parameters of rat. *Iran. J. Rep. Med.*, 7(1):7-12.
- Arash, K., Mahnaz H., Marefat, G. Novin, A., and Afshin, K., 2008.** Adverse effects of ciprofloxacin on testis apoptosis and sperm parameters in rats. *Iran. J. Rep. Med.*, 6:71-76.
- Bancroft, J.D., Stevens, A., and Turner, D.R., 1996.** "Theory and Practice of Histological Techniques". 4th ed. New York, Churchill, Livingstone.
- Barth, A.D. and Oko, R.J., 1994.** "Abnormal Morphology of Bovine Spermatozoa". Iowa State University Press. Ames, Iowa, USA, pp: 8-12.
- Bearden, H.J. and Fuquay, J.W., 1980.** "Applied Animal Reproduction" Reston Publishing Co., Inc. Reston, Virginia, pp: 157- 165.

- Beutler, E., Duron, O. and Kelly, M.B., 1963.** Colorimetric method for determination of glutathione reduced. *J. Lab. Clin. Med.*, 61:882.
- Chapin, R.E., Harris, M.W., Davis, B.J., Ward, S.M., Wilson R.E. and Mauney M.A., 1997.** The effects of perinatal/juvenile methoxychlor on adult rat nervous, immune and reproductive system function. *Fundam. Appl. Toxicol.*, 40: 138–57.
- Chidambaram, P., Elangovan, S. and Palaninathan, V., 2005.** Protective effect of lipoic acid on adriamycin-induced testicular toxicity. *Clinica. Chimica. Acta*, 360: 160–166.
- Demir, A., Turker, P., Onol, F.F., Sirvanci, S., Findik, A. and Tarcan T., 2007.** Effect of experimentally induced *Escherichia coli* epididymo-orchitis and ciprofloxacin treatment on rat spermatogenesis. *Int. J. Urol.*, 14: 268-272.
- De Vries, N. and De Flora, S., 1993.** N-acetyl-L-cysteine. *J. Cell Biochem.*, 17: 270-277.
- Ebenezer, O.F., Mercy, C.U., Teclar, T.E., Matthew, O.O., Martins, E., 2008.** Tetracycline-induced reproductive toxicity in male rats: Effects of vitamin C and N-acetyl cysteine. *Expe. and Toxicol. Pathol.*, 60: 77–85
- Folgero, B.T.K., Lindal, S., Torbergsen, T. and Oian, P., 1993.** Mitochondrial disease and reduced sperm motility. *Hum. Reprod.*, 8:1863-1868.
- Forejt, J., 1976.** Spermatogenic failure of translocation heterozygotes affected by H-2 inbred gene in mouse. *Nature*, 260:143–145.
- Friedman, K. and Young, D.S., 1997.** "Effects of Disease on Clinical Laboratory Tests". 3rd ed. Washington: AACC Press.
- Herbold, B.A., Brendler-Schwaab, S.Y. and Ahr, H.J., 2001.** Ciprofloxacin: in vivo genotoxicity studies. *Mutat. Res.*, 498:193-205.
- Itoh, T., Mitsumori, K., Kawaguchi, S., and Sasaki, Y.F., 2006.** Genotoxic potential of quinolone antimicrobials in the in vitro comet assay and micronucleus test. *Mutat. Res.*, 603: 135-144.
- Jaffe, B.M., and Behrman, N.R., 1974.** "Method of Hormone Radioimmunoassay". Academic Press, New York.
- Jana, K., Jana, S. and Samanta, P.K., 2006.** Effect of chronic exposure to sodium arsenite on hypothalamopituitary- testicular activities in adult rats: possible an estrogenic mode of action. *Reprod. Biol. Endocrinol.*, 4:91-96.
- Jorsaraei, S.G.A., Yousefnia, Y.R., Zainalzadeh, M., Moghadamnia, A.A., Beiky, A.A. and Rayati, D.M., 2008.** The effects of methanolic extracts of ginger (*Zingiber officinale*) on human sperm parameters; an in vitro study. *Pak. J. Biol. Sci.*, 11:1723-1727.
- Kamtchoung, P., Fandio, G.Y.M., Dimo, T. and Jastr, H.B., 2002.** Evaluation of androgenic activities of zingiber officinal and *Pentadiplandra brazzeana* in male rats. *Asian J. Androl.*, 4:299-301.
- Kerr, J.B. and Sharpe R.M., 2006.** Effects and interaction of LH and LHRH agonist on testicular morphology and function in hypophysectomised rats. *J. Reprod. Fertil.*, 76:175-192.
- Kind, P.R.N. and King, E.J., 1954.** Colorimetric method for estimation of acid phosphatase activity. *J. Clin. Pathol.*, 7: 322.
- Krazanowska, H., 1976.** Inheritance of sperm head abnormalities types in mice and the role of Y-chromosomes. *Genet. Res.*, 28:189-198.
- Kumari, G.V., Deivendran, R., Kalaivani, B. and Anbalagan, C., 2008.** Toxicity of ciprofloxacin in the seminal vesicles of rats and the rescue of antioxidant vitamins. "Prespectives in Animal Ecology and Reproduction" 5:382-402.
- Latchomycandane, K.C., Chitra, K.C. and Mathur, P.P., 2002.** The effect of methoxychlor on the epididymal antioxidant system of adult rats. *Reprod. Toxicol.*, 16:161-172.
- Lemasters, G.K. and Selevan, S.G., 1993.** Toxic exposures and reproduction: a view of epidemiology and surveillance. *Reprod. Toxicol. and Infert.*, 31: 307-321.
- Ohkawa, H., Ohishi, W. and Yagi, K., 1979.** Assay of lipid peroxides in animal tissues by thiobarbituric acid reaction. *Analy. Biochem.*, 95(2):351-358.
- Peruquetti, R.L. Taboga, S.R. and Azeredo-Oliveira, M.T.V., 2010.** Expression of acid phosphatase in the seminiferous epithelium of vertebrates. *Genet. Mol. Res.*, 9:620-628.
- Robinson, W.F., and Hunnable, C.R., 1988.** "Clinicopathological Principles for Veterinary Medicine". Cambridge Univ. Press, New York, Sydney
- Salem, A., Hafedh, A., Catherine, G., Pascale, G., hierry, D., Jean-Luc, R., Alain, F., Mohsen, S. and Khémais, B., 2008.** Preventive effect of zinc against cadmium-induced oxidative stress in the rat testis. *J. Rep. Develop.*, 54:129-134.
- Santner, S., Santen, R. and Kulin, H., 1981.** A model for validation of radioimmunoassay kit reagents: measurement of follitropin and lutropin in blood and urine. *Clin. Chem.*, 27:1892-1895.
- Sarkar, M., Chaudhuri, G.R., Chattopadhyay, A. and Biswas, N.M., 2003.** Effect of sodium arsenite on spermatogenesis, plasma gonadotrophins and testosterone in rats. *Asian J. Androl.*, 1:27-31.
- Schlegel, P.N., Chang, T.S., and Marshal, F.F., 1991.** Antibiotics: Potential hazards to male fertility. *Fert. Ster.*, 55:235-242.
- Schrade, S.M., 2003.** Man and the workplace: assessing his reproductive health. *Chem. Health Saf.*, 11-6.

- Sellins, K.S. and Cohen, J.J., 1987.** Gene induction by gamma-irradiation leads to DNA fragmentation in lymphocytes. *J. Immunol.*, 139: 3199.
- Shan, X.Q., Aw, T.Y. and Jones, D.P., 1990.** Glutathione dependent protection against oxidative injury. *Pharmacol. Ther.*, 47: 61-71.
- Sharma, R.K. and Agarwal, A., 1996.** Role of reactive oxygen species in male infertility. *Urology*, 48:835-50.
- Sharpe, R.M., Donachie, K. and Cooper, I., 1988.** Reevaluation of the intratesticular level of testosterone required for quantitative maintenance of spermatogenesis in the rat. *J. Endocrinol.*, 117:19-26.
- Sharpe, R.M., Maddocks, S., Millar, M., Saunders, P.T.K., Kerr, J.B. and Mckinnell, C., 1992.** Testosterone and spermatogenesis: identification of stage dependent, androgen- regulated proteins secreted by adult rat seminiferous tubules. *J. Androl.*, 13:172-184.
- Shaw, M.J., Georgapoulos, L.E. and Payne, A.H., 1979.** Synergistic effect of FSH and LH and testicular $\Delta 5, 3\beta$ - hydroxysteroid dehydrogenase isomerase. Application of a new method for the separation of testicular compartments. *Endocrinol.*, 104:912-918.
- Shrilata, B. and Muralidhara, 2007.** Early oxidative stress in testis and epididymal sperm in streptozotocin-induced diabetic mice: its progression and genotoxic consequences. *Rep. Toxicol.*, 23:578-87.
- Snedecor, G.W. and Cochran, W.G., 1982.** *Statistical Methods*, 6th ed., Iowa Univ. Press, Ames, U.S.A.
- Stein, G.E., 1996.** Pharmacokinetics and pharmacodynamics of newer fluoroquinolones. *Clin. Infect. Dis.*, 23: 19-24.
- Stenman, U.H. and Alfthan, H., 2002.** "Markers for Testicular Cancer" Washington: AACCC Press; p. 351-9.
- Takahashi, O. and Oishi, S., 2001.** Testicular toxicity of dietary 2,2-bis (4hydroxyphenyl) propane (bisphenol A) in F344 rat. *Arch. Toxicol.*, 75:42-51.
- Vernet, P., Aitkin, R.J. and Drevert, J.R., 2004.** Antioxidant strategies in epididymis. *Mol. Cell Endocrinol.*, 216:31-39.
- Weyers, A.I., Ugnia, L.I., Garcia Ovando, H. and Gorla N.B., 2002.** Ciprofloxacin increases hepatic and renal lipid hydroperoxides levels in mice. *Biocell.*, 26:225-228.
- Wolfson, J.S. and Hooper, D.C., 1985.** The fluoroquinolones: structures, mechanisms of action and resistance, and spectra of activity in vitro. *Antimicrob. Agents Chemother.*, 28:581-586.
- Zahedi, A., Khaki, A., Ahmadi-Ashtiani, H.R., Rastegar, H. and Rezazadeh, S.H., 2010.** Zingiber officinale: Protective Effects on Gentamicin's Toxicity on Sperm in Rats. *J. Medic. Plant.*, 9(35): 93-98.
- Zhang, J.H., Zhang, Y. and Herman, B., 2003.** Caspases apoptosis and aging. *J. Ageing Res. Rev.*, 2:357-366.

6/6/2011