



RESEARCH ARTICLE

EXTRACORPOREAL SHOCK WAVE THERAPY VERSUS ULTRASOUND WAVE THERAPY ON VENEUS ULCER

*¹Ahmed Younis Abu Serie, ²Nancy H. Abo elnour and ³Marwa M. Eid

¹Faculty of Physical Therapy, Cairo University, Cairo, Egypt

²Lecturer of Physical Therapy department of Surgery, Faculty of Physical Therapy, Cairo University

³Assistant Professor of Physical Therapy Department of Surgery, Faculty of Physical Therapy, Cairo University

ARTICLE INFO

Article History:

Received 24th June, 2018

Received in revised form

27th July, 2018

Accepted 20th August, 2018

Published online 30th September, 2018

Keywords:

(Venous ulcer- Shock wave therapy- ultrasound therapy)

ABSTRACT

Purpose: To assess the therapeutic efficacy of shock wave therapy and ultrasound therapy on healing of venous ulcer.

Material and Methods: Thirty patients with Lower limb ulcer (second degree)were selected randomly from Kasr- el aine hospitals. Patient's ages were ranged from 30-45 years. These patients were divided into two equal groups:

Group A (Shock wave group): In this group, fifteen patients received unfocused Shock wave therapy (500 pulses /cm² ,0.1 mJ/mm²)two sessions per week for six week plus routine medical treatment (emollient, corticosteroid, antibiotics).

Group B (Ultrasound group):In this group, fifteen patients were received ultrasound therapy (1mHz,0.5w/cm²) plus routine medications. The method of assessment was 3d autocade (photographic; burn depth, size, color). Measurements were conducted before starting the treatment as a first record and at the end of 6 weeks of treatment as second record.

Results showed significant decrease in wound surface area and increase in the rate of epithelialization in shock wave group compared to ultrasound group.

Conclusion: It was concluded that Shock wave therapy had more effect on wound healing of venous ulcer than ultrasound wave.

INTRODUCTION

Lower limb ulceration is reported as a common problem world-wide, and is considered a major social and economic burden (Fioramonti *et al.*, 2012). Lower limb ulceration is associated with numerous comorbidities including, but not limited to; diabetes, peripheral vascular disease and venous insufficiency (Mittermayr *et al.*, 2012). Venous ulcers (venous insufficiency ulceration, stasis ulcers, stasis dermatitis, varicose ulcers, or ulcuscruis) are wounds that are thought to occur due to improper functioning of venous valves, usually of the legs (James *et al.*, 2006). They are the major occurrence of chronic wounds, occurring in 70% to 90% of leg ulcer cases. Venous ulcers develop mostly along the medial distal leg, and can be very painful (Snyder, 2005). Venous ulceration is caused by increased pressure in the venous system. The main cause of venous hypertension is insufficiency of the valves in the deep venous system and the lower perforating veins. These veins and good functioning of their valves are necessary for the return of venous blood to the heart at each contraction of the calf muscles (the muscle pump). Intact valves but absent muscle contraction (immobility, paresis) may also cause oedema and ulceration, a condition known as dependency syndrome.

Valve insufficiency may be acquired as in post-thrombotic syndrome or caused by congenital weakness of valves or vessels. The exact pathogenetic cascade leading from valve insufficiency to ulceration is still not fully elucidated (Leng *et al.*, 2001). The management of ulceration is dependent on the proposed causes, common interventions used include both non-surgical and surgical approaches. Typically, effective ulcer management involves local wound care, compression therapy, pressure redistribution, infection management and optimization of vascular status (Tang *et al.*, 2012). Recently, extracorporeal shock wave therapy, for the treatment of chronic ulceration,¹The use of extracorporeal shock waves in medicine was first reported over 30 years ago as a treatment for kidney stones, and is commonly referred to as 'extracorporeal shock wave lithotripsy', or 'ESWL'. Extracorporeal shock waves are also used as a treatment for musculoskeletal conditions such as plantar heel pain and boney non-union and is commonly referred to as 'extracorporeal shock wave therapy' (ESWT) to differentiate from ESWL (Speed, 2013). Furthermore, the use of ESWT has also been reported in the treatment of arterial aneurysms and intermittent claudication (Serizawa and Matsubara, 2011). Ultrasound therapy is a standard treatment option for soft tissue injuries in physiotherapy clinics, and it is used in some centers for the management of chronic wounds (Moffatt *et al.*, 2007) that using low intensity ultrasound (≤ 3 W/cm²) can be used to stimulate normal physiological

*Corresponding author: Ahmed Younis Abu Serie,
Faculty of Physical Therapy, Cairo University, Cairo, Egypt.

responses to injury to aid repair (Ter Haar, 1999). Several case studies demonstrated that the low frequency ultrasound was a useful tool in the management of chronic wounds, not only for healing but also for pain, pigmentation and odour reduction (Johnson, 2003).

MATERIALS AND METHODS

Thirty patients suffered from Lower limb ulcer (second degree) were selected and recruited randomly from Kasr- el aine hospitals. Patient's ages are ranged from 30-45 years.

Criteria of patient selection

The patients had the following criteria:

Inclusion criteria

patients with age ranged from 30 to 45 years suffering from lower limb venous ulcer for, and the ulcers had grade 2 or 3. patients were conscious, well nourished, co-operative, free from other neurological problems, free hepatic, diabetes mellitus and thyroid diseases.

Exclusion criteria

The current study was excluded the following patients: Uncooperative patients, Instability of patient's medical condition, Association of other medical problems, Presence of any disease that could affect the research results. These patients were divided into two equal groups in number:

Group A (Shock wave therapy)

In this group of the study, fifteen patients were received Shock wave therapy (500 pulses /cm², 0.1 mJ/mm²) three sessions per week for six week plus routine medical treatment. Measurements were conducted before starting the treatment as a first record and at the end of 6 weeks of treatment as second record.

Group B (ultrasound wave therapy group)

In this group, fifteen patients were received ultrasound therapy plus routine medications. Measurements were conducted before starting the treatment as a first record and at the end of 6 weeks of treatment as second record.

Instrumentations and Materials

3D surface imaging autocade: ("Photographic": Burn depth, size and color are evaluated using photographic shots that were measured before starting the treatment and at the end of six weeks of the treatment) this autocadeprogram uses a digital camera (CANONN) that captured the wound ulcers from adistance (15CM).

Therapeutic equipment

Shock wave therapy: (Evotron, High Medical Technologies, Lengwil, Switzerland). After the disinfection of the wound, the shock wave applicator head was placed over the wound, the cleaned wound was covered with sterile ultrasound gel and a sterile drape, over which further coupling was spread to provide an air-free contact for extracorporeal shock wave therapy head (ESWT). The head was then moved directly on the wound and the edges.

Ultrasound therapy: The ultrasound therapy was applied with a SoLo Therasonic 355 machine (EMS Physio, Wantage, UK).

After the disinfection of the wound, the ultrasound applicator head was placed over the wound, the cleaned wound was covered with sterile ultrasound gel and a sterile drape, The head was then moved circular in one direction on the wound and the edges.

Statistical analysis: In this study, the obtained data was recorded on the evaluation sheet. These data was transferred into IBM card using IBM personal computer with statistical program to obtain the following statistical tools:

- **Descriptive statistics:** Descriptive statistics in the form of mean, and standard deviation were calculated for all patients in the two groups of the study to determine the homogeneity and central deviation.
- **Analytic statistics:** In this study, the mean, standard deviation and standard error were calculated for all variables in both groups. Independent "T" test was used also to compare between pre test and post test in each group. Comparison was applied by student T test to compare between the independent means.

RESULTS

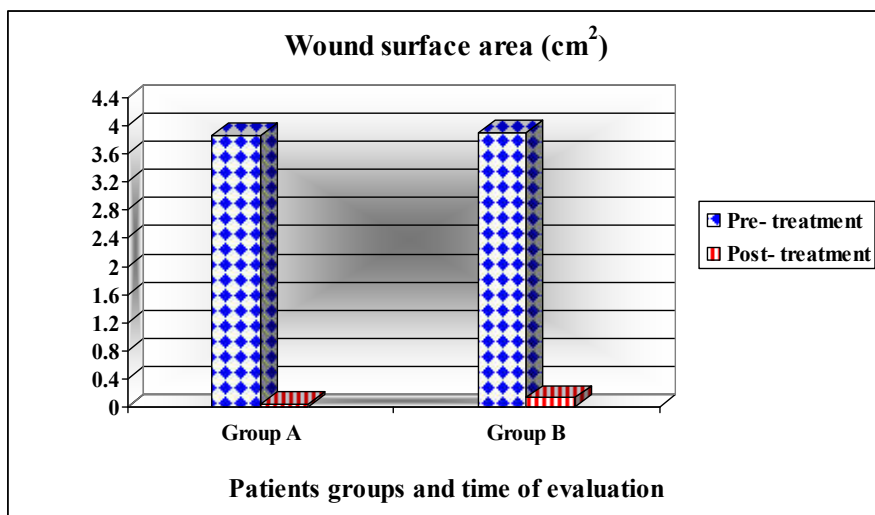
when comparing the two groups (A and B) before treatment, the mean \pm SD values were 3.87 ± 0.43 and 3.9 ± 0.41 respectively which indicated no significant difference ($p=0.841$), while comparing the two groups after six weeks of treatment, the mean \pm SD values were 0.04 ± 0.06 and 0.13 ± 0.12 respectively which indicated a significant difference ($p=0.025$) in favor of group A (MD= 0.09) and % of improvement was 14.82 %.

DISCUSSION

During this study, I meet some limitations as; The shockwave device wasn't available in all time, very expensive, the cases weren't available and some patients were uncooperative in the sessions. At the end of the study, The results of this study revealed that there was a significant difference in wound surface area after 6 weeks (post-treatment) of the treatment between in shock wave group and the ultrasound group (P value = 0.025) although there was no significant difference between the two group at the beginning of the study (pre-treatment). That could prove the efficacy of ESWT in acceleration of wound healing in lower limb venous ulcers. Also, it was found that application of shock waves on lower limb ulcers showed a statistically significant increase in the epithelialization rate after 6 weeks by 14.82% (p value = 0.025). In comparison, the ultrasound group showed a rate of epithelialization after 6 weeks of 12.7%. Although the mechanisms by which SWT improves ulcer healing are not fully understood, it is purported to stimulate vascular ingrowth, neovascularization and cell proliferation (Contaldo *et al.*, 2012), therefore improving healing rates in chronic ulcers (Fioramonti *et al.*, 2012). All of the published clinical studies involved application of US only in conservative therapy of venous leg ulcers. The researchers never applied the US in patients with leg ulcers following a surgical procedure, thus it was estimated whether promising results could be expected in postoperative therapy (Watson and Nelson, 2006).

Table 1 . Comparing the mean values of wound surface area (cm²) among the two groups

Wound surface area (cm ²)	Group (A)		Group (B)	
	Pre Treatment	Post Treatment	Pre Treatment	Post Treatment
Mean ± SD	3.87 ± 0.43	0.04 ± 0.06	3.9 ± 0.41	0.13 ± 0.12
MD	3.83		3.77	
% of improvement	14.82 %		12.7 %	
t-value	35.16		32.3	
p-value	0.000		0.000	
Level of Significant	S		S	



Pre: Before application of treatment Post: After six weeks of treatment.
 SD: Standard Deviation. MD: Mean Difference.
 % of improvement: Percentage of improvement.
 t-value: Paired and Un-paired t- test value.
 p-value: Probability value.
 S: Significant.

Table 2. Comparing between pre and post treatment mean values of wound surface area (cm²) between the two groups

Two Groups	wound surface area (cm ²)			
	Pre- treatment		Post- treatment	
	Group (A)	Group (B)	Group (A)	Group (B)
Mean ± SD	3.87 ± 0.43	3.9 ± 0.41	0.04 ± 0.06	0.13 ± 0.12
MD	0.03		0.09	
t-value	0.2		2.44	
p-value	0.841		0.025	
Level of Significant	NS		S	

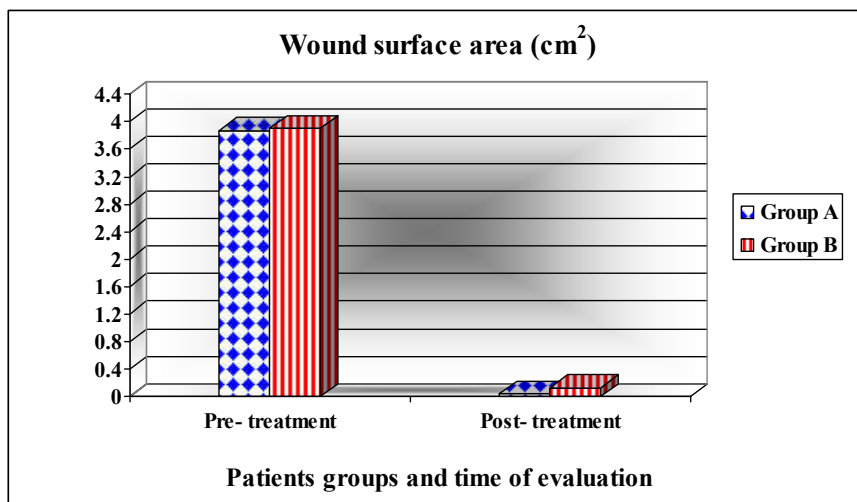


Fig 2. Pre and post treatment mean values of wound surface area (cm²) between the two groups

The results of the present study by ESWT come agree with (Wang, *et al.*, 2011, Otimann, *et al.*, 2010, Arno, *et al.*, 2010, Larking, *et al.*, 2010, Kuo, *et al.*, 2009, (Meirer, *et al.*, 2007, Wang, *et al.*, 2001), Morretti, *et al.*, 2009, Wang, *et al.*, 2009, Saggini, *et al.*, 2008, (Haake, *et al.*, 2002), Dumfartn, *et al.*, 2008, Schaden, *et al.*, 2007, Meirier, *et al.*, 2005, Wang, 2003, wang, *et al.*, 2003, Wang, *et al.*, 2002). So the current study was designed to determine the therapeutic efficacy of Extracorporeal Shock Wave and ultrasound therapy in Patients with Lower limb ulcer. The results of the present study come agreed with (Meirer *et al.* 2005a) (Tan *et al.*, 2007) that direct and indirect effects of ESW may stimulate endothelial organization, with increased deposition of connective tissue and stimulation of epithelialization. Previous studies on shock waves demonstrated rearrangement of the endothelial cells and basal laminae, significant rise of local growth factors, such as nitric oxide synthase, proliferating cell nuclear antigen inducing neovascularization and transforming growth factor- β 1 (Wang, 2003), (Wang *et al.*, 2003), (Wang *et al.*, 2002).

Even if ESWT was postulated to cause microtrauma and hematoma formation, depending on location of treatment and amount of energy (Haake *et al.*, 2002) during all the study period no complications were encountered. ESWT seems to be a safe method to improve wound healing in chronic wounds. Saggini *et al.*, 2008 treated 32 ulcers with ESWT and reported that 16 ulcers healed completely within six sessions of ESWT. In those ulcers that did not completely heal, statistical significance ($p < 0.01$) was reported with regard to decrease in ulcer size, after four to six sessions of ESWT. There was no evidence in this study of a difference between the two groups regarding ulcer healing or change in ulcer size. Wang *et al.*, 2009 found that in the ESWT group, 31% of ulcers completely healed, 58% improved and 11% remained unchanged. In the HBO group 22% completely healed, 50% improved, and 28% remained unchanged. These differences were significant at $p = 0.001$. Furthermore, greater than 50% improvement of the ulcer was observed in 89% of participants in the ESWT group and 72% of participants in the HBO group ($p < 0.001$). In their second study comparing ESWT and HBO, Wang *et al.*, 2011 found completely healed ulcers in 57% and 25% ($p = 0.003$); $\geq 50\%$ improved ulcers in 32% and 15% ($p = 0.071$), and unchanged ulcers in 11% and 60% ($p < 0.001$) respectively.

Schaden *et al.*, 2007, found that venous stasis ulcers demonstrated the worst healing rates (36% versus 66% for all other ulcers, $p = 0.001$). Furthermore, arterial insufficiency ulcers did not completely heal in 33% of cases, the second worst healing rate of all ulcer types. The primary outcome assessed in their study was the safety and feasibility of using ESWT on wounds, the authors concluding that ESWT is a safe and effective treatment. Morretti *et al.*, 2009 conducted a study of 30 diabetic patients with neuropathic foot ulcers treated with debridement followed by unfocused SWT (100 pulses of 0.03 mJ/mm²) for 3 sessions every 72 hours and wound care. The control arm was treated with debridement, pressure relief and treatment of infection. The wounds studied were small (SWT 300 +/- 130 mm², control 250 +/- 100 mm², mean size +/- SD). SWT parameters were based on the authors' clinical experience with SWT in orthopedics. In 20 weeks, the treatment arm had a healing rate of 53% versus 33% in the control. Though randomized, the random allocation sequence, its mechanism and implementation were not explained. The study excluded chronic diabetic ulcers greater than 5 cm to avoid selection bias. Recently, Ottomann *et al.*, 2010

conducted a study with 28 patients with acute traumatic wounds and burns requiring skin grafting treated with unfocused SWT (100 impulses at 0.1 mJ/mm²) to the skin graft donor site immediately after skin harvest. A significantly decreased time for reepithelization of skin graft donor sites in the SWT arm (13.9 +/- 2.0 days) versus control (16.7 +/- 2.0) was reported. The study was powered to detect a difference in time to epithelization with adequate randomization and blinding. However, the sample size was too small to study other outcomes including pain and the cosmesis of donor sites and did not have long-term follow up. Dumfarth *et al.*, 2008 carried out a Level 2b study with 100 patients undergoing vein harvesting for coronary artery bypass graft (CABG) surgery, half of whom received unfocused SWT (25 impulses at 0.1 mJ/mm²) at the wound closure site of the vein graft. Treated patients had lower ASEPSIS scores (serous discharge, erythema, purulent exudates, separation of the deep tissue, isolation of bacteria, and duration of inpatient stay) on postoperative days 3 and 7 with no reported complications from treatment, suggesting better wound healing. Treated patients had a statistically significant lower use of antibiotics for leg wounds. However, the study was not powered for its primary outcome.

The long term effects of SWT in these surgical wounds were not assessed. Larking *et al.*, 2010 investigated the response of decubitus ulcerations to ESWT in a randomized, placebo-controlled crossover study. All included patients (nine ulcers) suffered from severe physical disabilities (Barthel score $< 8/20$) with decubitus ulcerations lasting longer than 3 months in different locations. The design of the study protocol consisted of a 3-week baseline observation period in order to confirm stable wound conditions. Thereafter, ulcers were allocated to ESWT or placebo and followed-up for 4 weeks receiving treatment each week. A 2-week wash-out phase led over to treatment crossover for another 4 weeks with same treatment and evaluation parameters as in the first phase. The main finding was that ulcers that were stable over the baseline observation period showed healing after ESWT. In the group receiving the placebo regimen first (machine with typical noise but without producing shock waves), no substantial differences in wound area were recognized in the 4-week interval, but after receiving ESWT, wounds showed progressively healing.

In the ESWT first group, most of the ulcers decreased in size, which was continued after crossing over in the placebo group. An interesting finding was that some of the wounds initially showed deterioration in size once the shock wave therapy started, which then turned in improvement. This phenomenon was discussed as follows that shock waves may first debride the wounds receiving proper wound bed, which is then conditioned for healing. Arno *et al.*, 2010 conducted a case-series study of 15 patients with $< 5\%$ TBSA deep partial/full thickness skin burns who received unfocused SWT (500 impulses at mJ/mm²) on days 3 and 5 post-burn. Patients underwent debridement and STSG in the absence of burn reepithelization 2.5 weeks or more after SWT therapy. 80% of the patients healed before 3 weeks; 15% of patients required surgical debridement and STSG and 5% developed hypertrophic scarring. Increase in perfusion based on laser Doppler imaging (LDI) images was also observed. The results of the present study by ultrasound come agree with (Serna, *et al.*, 2009, Kuo *et al.*, 2009, Cole, *et al.*, 2009, Bell and Cavorsi, 2008, Kavros, *et al.*, 2007, Kavros and Schenck, 2007, Ennis, *et al.*, 2005, Johnson, *et al.*, 2003 and Jeffry, *et*

al., 2003). Several case studies demonstrated that the low frequency ultrasound was a useful tool in the management of chronic wounds, not only for healing but also for pain, pigmentation and odour reduction (Johnson, 2003). Low frequency ultrasound is also being used in the treatment of pressure sores. To date there was only one study namely a case study that demonstrated a beneficial effect of ultrasound in treatment of pressure ulcers (Ennis *et al.*, 2006). Using ultrasound therapy, a prior retrospective analysis found a reduction in the median wound area from 2.5 to 0.6 cm² and increased percentage of granulation tissue from 32% before ultrasound therapy to 46% after ultrasound therapy (Bell and Cavorsi, 2008). Another retrospective study showed that 30% of 41 patients treated with ultrasound had complete healing and granulation tissue increased from 26% at the beginning of the study to 80% at the end of the study (Cole *et al.*, 2009). Serena *et al.*, 2009 conducted a series of experiments with ultrasound therapy. They found that ultrasound penetrated into both wounded and intact skin in an ex vivo pig model by tracing the presence of a dye that was used in the irrigation preparation. They also performed in vitro experimentation on bacteria survival and showed that 33% of *P. aeruginosa*, 40% of *Escherichia coli* and 27% of *Enterococcus faecalis* disappeared after one-time ultrasound treatment. Additionally in pigs with induced wounds, compared with silver dressings ultrasound therapy reduced bacterial counts, except for *P. aeruginosa*. Finally, patients with stage III pressure ulcers, less than 2 weeks of non contact ultrasound treatment reduced pretreatment bio burden of 4×10^7 to 2×10^7 . In another study, Kavros *et al.*, 2007 assessed ultrasound therapy in the treatment of non-healing leg and foot ulcers associated with chronic critical limb ischemia.

The subjects included 35 patients who received ultrasound therapy plus the standard of wound care for 12 weeks (treatment group) and 35 patients who received the standard of wound care alone (control group). The main outcome measurements showed a significantly higher percentage of patients treated with the treatment group achieved greater than 50% wound healing at 12 weeks than those treated with the standard of care alone (63% vs. 29%; $p < 0.001$). Also, Kavros *et al.*, 2007 in another study indicated healing time reductions (9.8 ± 5.5 weeks vs. 5.5 ± 2.8 weeks ($p < 0.0001$)) and wound volume percent improvement ($37.3\% \pm 18.6\%$ vs. $94.9\% \pm 9.8\%$ ($p < 0.0001$)) in comparing the clinic's standard care with MIST ultrasound therapy (Kavros and Schenck, 2007) in a randomized, controlled, double-blinded study, Ennis *et al.*, 2006. Examined the effectiveness of MIST ultrasound therapy after 12 weeks of care for the healing of recalcitrant diabetic foot ulcers. The authors concluded, the proportion of wounds healed in the active ultrasound therapy device group was significantly higher than that in the control group (40.7% vs. 14.3%, $p = 0.0366$, Fisher's exact test) (Ennis *et al.*, 2005). Also Ennis *et al.*, 2006 in another non-comparative study, used MIST ultrasound during an 8-month period and ultimately concluded that 69% of the wounds were healed and median time to healing was 7 weeks when MIST ultrasound was used as a stand-alone therapy.

Conclusion

From the previous discussion of these results and according to reports of researches in the field related to the present study, it could be concluded that application of shock wave therapy on the lower limb venous ulcer can improve

and accelerate the closure of wound and decrease the time of healing, leading to decrease the physical, psychological and financial complications for these patients and decrease the costs more than the ultrasound therapy. The results of the current study would introduce a scientific applicable protocol for an effective and safe modality that can help physical therapists, physicians and clinicians in their dealing with patients who suffer from lower limb ulceration to overcome this problem and improve the quality of life.

REFERENCES

- Arno, A., Garcia, O., Sancho, H. and Barret, A. 2010. "Extracorporeal shock waves, a new nonsurgical method to treat severe burns" vol 36, No 8, Pp44-9.
- Attinger, C.E., Jani, J.E., Steinberg, J., Schwartz, J., Al-Attar, A. and Couch, K. 2006. "Clinical approach to wounds: debridement and wound bed preparation including the use of dressings and wound-healing adjuvants". *Plast Reconstr Surg.*, 117 Suppl 7:72-109.
- Bell, A.L. and Cavorsi, J. 2008. "Noncontact ultrasound therapy for adjunctive treatment of nonhealing wounds": retrospective analysis. 88:1517-24.
- Cole, P.S., Quisberg, J. and Melin, M.M. 2009. "Adjuvant use of acoustic pressure wave therapy for treatment of chronic wounds: a retrospective analysis." *J Wound Ostomy Continence Nurs.*, 36:171-7.
- Contaldo, C., Högger, D.C., Khorrami, B.M., Stotz, M., Platz, U. and Forster, N. 2012. "Radial pressure waves mediate apoptosis and functional angiogenesis during wound repair in ApoE deficient mice". *Microvasc Res.*, 84:24-33.
- Dissemond, J., Fitz, G. and Goos, M. 2003. "Wound bed preparation of chronic wounds with ultrasound". *Hautarzt.*, Jun; 54 (6): 524-9. Epub Apr 17.
- Dumfarth, J., Zimpfer, D., Voggele-Kadletz, M., Holfeld, J., Sihorsch, F., Schaden, W., Czerny, M., Aharinejad, S., Wlner, E. and Grimm, M. 2008. "Prophylactic low-energy shock wave therapy improves wound healing after vein harvesting for coronary artery bypass surgery: a prospective, randomized trial". *J Thorac Surg.*, 86:1909-13.
- Ennis, W.J., Foremann, P., Mozen, N., Massey, J., Conner-Kerr, T. and Meneses, P. 2005. "Ultrasound therapy for recalcitrant diabetic foot ulcers: results of a randomized, double-blind, controlled, multicenter study". *Ostomy Wound Manage.*, 51, 24-39.
- Ennis, W.J., Valdes, W., Gainer, M. and Meneses, P. 2006. "Evaluation of clinical effectiveness of MIST ultrasound therapy for the healing of chronic wounds". *Adv Skin Wound Care.*, 19, 437-44
- Fioramonti, P., Onesti, M.G., Fino, P., Fallico, N. and Scuderi N, 2012. "Extracorporeal shock wave therapy for the treatment of venous ulcers in the lower limbs". *Ann Ital Chir.*, 83(1):41-4.
- Flemming, K. and Cullum, N. 2004. "(Cochrane Review) Therapeutic ultrasound for pressure sores". The Cochrane library, Issues 3.
- Haake, M., Boddeker, I.R., Decker, T., Buch, M., Vogel, M., Labek, G., Maier, M., Loew, M., Maier-Boerries, O., Fischer, J., Betthausen, A., Rehack, H.C., Kanovsky, W., Muller, I., Gerdesmeyer, L. and Rompe, J.D. 2002. "Side effects of extracorporeal shock wave therapy (ESWT) in the treatment of tennis elbow". *Arch Orthop Trauma Surg.*, 122:222-228.

- James, W. D., Berger, T.G. *et al.* 2006. *Andrews' Diseases of the Skin: clinical Dermatology.* "Saunders Elsevier, ISBN 0-7216-2921-0.
- Johnson, S. 2003. "Low frequency to manage chronic venous ulcers". *Br J Nurs.*, Oct; 12 (19 Suppl) : s14 -24.20.
- Kavros, S.J. and Schenck, E.C. 2007. "Use of noncontact low-frequency ultrasound in the treatment of chronic foot and leg ulcerations: A 51-patient analysis". *J Am Podiatr Med Assoc.*, 97, 95–101.
- Kuo, Y.R., Wang, C.T. and Wang, F.S. 2009. "Extracorporeal shock-wave therapy enhanced wound healing via increasing topical blood perfusion and tissue regeneration in a rat model of stz-induced diabetes." *Wound Repair Regen.*, 17:522–530
- Larking, A.M., Dupont, S., Clinton, M., Hardy, M. and Andrews, K. 2010. "Randomized control of extracorporeal shock wave therapy vs. placebo for chronic decubitus ulceration." *Clin Rehabil.*, 24: 222–9.
- Leng, G.C., Davis, M. and Baker D, 2001. "Bypass surgery for lower leg ischemia (Cochrane Review)". In: *The Cochrane Library, Issue 1.* Oxford: Update Software.
- Mittermayr, R., Antonic, V., Hartinger, J., Kaufmann, H., Redl, H. and Téot, L. 2012. "Extracorporeal shock wave therapy (ESWT) for wound healing: technology, mechanisms, and clinical efficacy." *Wound Repair Regen.*, 20(4):456–65.
- Moffatt, C., Martin, R. and Smithdale, R. 2007. "Leg ulcer management. Blackwell Publishing Ltd".
- NICE, 2013. "Varicose veins in the legs: The diagnosis and management of varicose veins. 1.2 Referral to a vascular service" (National Institute for Health and Care Excellence. Retrieved August 25, 2014.
- Ottomann, C., Hartmann, B., Tyler, J., Maier, H., Thiele, R., Schaden, W. and Stojadinovic, A. 2010. "Prospective randomized trial of accelerated re-epithelization of skin graft donor sites using extracorporeal shock wave therapy": *J Am Coll Surg.*, 211:361-67.
- Qureshi, A.A., Ross, K.M., Ogawa, R. and Orgill, D. 2011. "Shock wave therapy in wound healing." *Plast Reconstruction Surg.*, (2011); 128(6):721–7.
- Rassweiler, JJ., Knoll, T., Köhrmann, K.U., McAteer, J.A., Lingeman, J.E. and Cleveland, R.O. 2011). "Shock wave technology and application." *Eur Urol.*, 59:784–96.
- Saggini, R., Figus, A., Troccola, A., Cocco, V., Saggini, A. and Scuderi, N. 2008. "Extracorporeal shock wave therapy for management of chronic ulcers in the lower extremities". *Ultrasound Med Biol.*, 34(8):1261–71.
- Schaden, W., Thiele, R., Köpl, C., Pusch, M., Nissan, A. and Attinger, CE., 2007. "Shock wave therapy for acute and chronic soft tissue wounds: a feasibility study". *J Surg Res.*, 143(1):1–12.
- Schmitz, C., Császár, N.B., Rompe, J.D., Chaves, H. and Furia, J.P, 2013. "Treatment of chronic plantar fasciopathy with extracorporeal shock waves". *J Orthop Surg Res.*, 8:31.
- Serena, T., Lee, S.K., Lam, K., Attar, P., Meneses, P. and Ennis, W. 2009. "The impact of noncontact, nonthermal, low-frequency ultrasound on bacterial counts in experimental and chronic wounds". *Ostomy Wound Manage.*, 55:22–30.
- Serizawa, F., Ito, K. and Matsubara, M, 2011. "Extracorporeal shock wave therapy induces therapeutic lymphangiogenesis in a rat model of secondary lymphoedema. *Eur J Vasc Endo vasc Surg.*, 42:254–260
- Snyder, R.J., 2005. "Treatment of nonhealing ulcers with allografts". *Clin Dermatol.*, 23 (4): 388–95.
- Speed C. A, 2013: "systematic review of shockwave therapies in soft tissue conditions: focusing on the evidence". *Br J Sports Med.*, 10:136–196.
- Tan, J., Abisi, S., Smith, A. and Burnand K.G.A. 2007:"painless method of ultrasonically assisted debridement of chronic leg ulcers: a pilot study". *Eur Vasc Endovasc Surg.*, 33:234-8
- Tang, J.C., Marston, W.A. and Kirsner, R.S. 2012. "Wound Healing Society (WHS) venous ulcer treatment guidelines: what's new in five years?" *Wound Repair Regen.*, 20 (5):619–37.
- Ter Haar, G, 1999. "Therapeutic ultrasound." *European Journal of Ultrasound* , 199;9(1):3–9.
- Tse, G.H., Qazi, H.A., Halsall, A.K., Nalagatla, S.R.K. 2011. "Shockwave lithotripsy: arterial aneurysms and vascular complications." *J Endourol.*, 25(3):403–11.
- Valencia, I.C., Falabella, A., Kirsner, R.S. and Eaglstein, W.H. 2001."Chronic venous insufficiency and venous leg ulceration". *J Am Acad Dermatol.*, 44: 401–21.
- Wang, C.J. 2003. "An overview of shock wave therapy in musculoskeletal disorders. " *Chang Gung Med J*;26:220–232.
- Wang, C.J., Kuo, Y.R., Wu, R.W., Liu, R.T., Hsu, C.S. and Wang, F.S. 2009. "Extracorporeal shockwave treatment for chronic diabetic foot ulcers. " *J Surg Res.*, 152 (1):96–103.
- Wang, C.J., Wang, F.S., Yang, K.D., Weng, L.H., Hsu, C.C., Huang, C.S. and Yang L.C. 2003. "Shock wave therapy induces neovascularization at the tendon bone junction. A study in rabbits. " *J Orthop Res.*, 21:984–989.
- Wang, C.J., Wu, R.W. and Yang, Y.J. 2011. "Treatment of diabetic foot ulcers: a comparative study of extracorporeal shockwave therapy and hyperbaric oxygen therapy. " *Diabetes Res Clin Pr.*, 92(2):187–93.
- Wang, F.S., Yang, K.D., Chen, R.F., Wang, C.J. and Sheen-Chen, S.M. 2002. "Extracorporeal shock wave promotes growth and differentiation of bone marrow stromal cells towards osteoprogenitors associated with induction of TGF-beta1. " *J Bone Joint Surg Br.*, 84:457–46.
- Watson, T. and Nelson, A . 2006. "the therapeutic efficacy of Extracorporeal Shock Wave and ultrasound therapy in Patients with Lower limb ulcer. " *Elsevier Journal*, 978-0-443-3.
