New Flap for Widening of the Web Space and Correction of Palmar Contracture in Complex Clasped Thumb

Mostafa Mahmoud, MD, Hisham Abdel-Ghani, MD, John C. Elfar, MD

In our experience, previous flaps designed for correction of the skin deficiency in complex clasped thumb do not sufficiently address the palmar contracture of the deformity. Moreover, the index finger flap, previously described by Ezaki and Oishi, provides insufficient skin at its apex with the possibility of incomplete correction and the frequent need of a thenar release incision. This article describes a flap designed for widening of the narrow thumb-index web space and release of the palmar thumb contracture in cases of congenital clasped thumb. This flap provides sufficient correction of the palmar contracture and at the same time provides adequate width and depth of the thumb-index web space. *(J Hand Surg 2013;38A:2251–2256. Copyright © 2013 by the American Society for Surgery of the Hand. All rights reserved.)*

Key words Clasped thumb, index finger flap, palmar flap, palmar contracture.

PALMAR SKIN CONTRACTURE of congenital clasped thumb[1–3] may present with a number of findings including joint contracture,[3–8] tendon[3,7,9] and ligament insufficiency,[6] intrinsic muscle abnormality,[1,3,4,6] and thumb-index web space contracture.[1,3,4,6,10] Complex congenital clasped thumb[1,2] often necessitates surgical intervention in patients who are seen after the age of 2 years and, frequently, in many patients younger than 1 year of age because they respond poorly to splinting.[1,2,5,9]

The commonly used procedure to widen the narrow first web space is the dorsal rotation advancement flap, described by Buck-Gramcko[4] and modified by Ghani.[2] However, these techniques may prove insufficient in resolving severe palmar skin contracture of the thumb encountered in some severe cases. The index rotation flap utilizes skin from the dorsoradial aspect of the index.[10] However, in our hands, this technique fails to augment the palmar aspect of the thumb metacarpophalangeal (MCP) joint owing to the narrow apex of the flap reaching this region. Moreover, a thenar release incision is commonly needed to complete the release of the palmar contracture that is either skin grafted or left to granulate.[4]

Unlike the index flap, adding a dorsal component addresses the problem of the former's compromise between correcting either the first web space or palmar contracture, our modification makes addressing both problems readily feasible; moreover, suturing the palmar component adds more web space depth. This flap addresses both narrowing of the web as well as palmar contracture and skin shortening of the thumb. This technique addresses all skin deficiency and contractures without the need for skin grafting.

INDICATIONS AND CONTRAINDICATIONS

Surgical intervention is indicated in children 2 years old or older with severe complex clasped thumb (McCarroll) with narrow first web space and evident palmar contracture that has failed to respond to splinting.[1,2,5,6,9]

From the Kasr Al Ainy Hospital, Faculty of Medicine, Cairo University, Cairo, Egypt; and the Department of Orthopedics and Rehabilitation, University of Rochester Medical Center, Rochester, New York.

Received for publication March 19, 2013; accepted in revised form August 21, 2013.

No benefits in any form have been received or will be received related directly or indirectly to the subject of this article.

Corresponding author: Mostafa Mahmoud, MD, 21, Gol Gamal St., from Al Batal Ahmed Abdelazeez St., Mohandeseen, Giza, Egypt; e-mail: dr.mostmah@gmail.com.

0363-5023/13/38A11-0032$36.00/0
http://dx.doi.org/10.1016/j.jhsa.2013.08.107

© 2013 ASSH ◆ Published by Elsevier, Inc. All rights reserved.

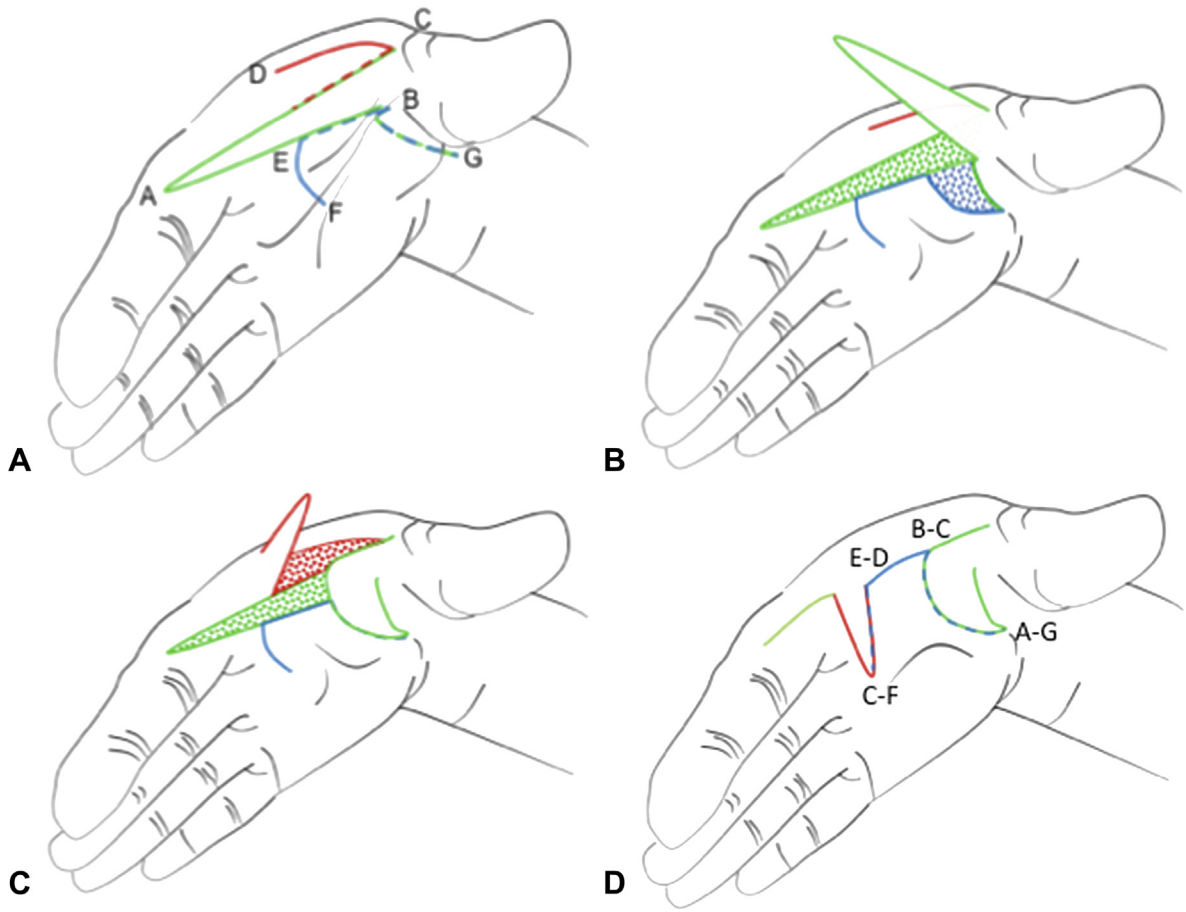

FIGURE 1: Diagrammatic representation of the steps involved with flap planning, elevation and rotation. **A** Diagram shows the 3 components of the flap, the index flap between the points C, A, and B; the palmar rectangular flap between the points G, B, E, and F; and the dorsal triangular flap between the points D, C, and A. **B** Raising the index flap. **C** Rotation of the index flap and raising the dorsal triangular flap. **D** Rotation of the dorsal triangular flap and advancement of the palmar rectangular flap to create the final flap arrangement. Point A sutured to point G; point C sutured to point F; point B sutured to point C; and point E sutured to point D.

In patients with soft tissue contracture limited to the thumb-index web, simple transposition flaps in mild cases or the flap described by Ghani[2] for more severe web contracture may be suitable. These flaps cannot be used if previous soft tissue rearrangement was done, if there is tight skin at the base of the index, for skin diseases limiting flap mobility such as epidermolysis bullosa, and in soft tissue infections. Patients younger than 2 years old were excluded and instructed to continue passive manipulations and splinting. We have applied this flap to cases of congenital clasped thumb only and have not used it in post-traumatic or burn conditions.

SURGICAL TECHNIQUE

The first incision starts at the radial aspect of the index proximal interphalangeal (IP) joint, point A (Fig. 1A), extending proximally in the plane between the dorsal and palmar skin to the level of the thumb MCP joint, point B (Fig. 1A), which is the pivot point of this flap located on the dorsal aspect of the thumb index web commissure.

The second incision passes proximally and dorsally from point A to point C (Fig. 1A), to create an isosceles triangle with the apex not less than 20°. This creates the proximally based index flap (Fig. 1A). A more proximal starting point is recommended for tight index finger digital skin. Ezaki and Oishi[10] recommended a ratio of 3:1 to ensure flap viability. This index flap (Fig 1B) encloses the excess radial skin at the index base and continues over the dorsal aspect of the first web space.

The third incision starts from point C (Fig. 1A) at a 30° to 45° angle, directed distally half the length of the first limb to point D (Fig. 1A) resulting in an unequal "Z" with the formation of the dorsal triangles that comprise the dorsal triangular rotational flap (Fig. 1A, C).

The palmar flap starts at point E (midway between points A and B) to point F at an angle of 60° and

equal in length to line CD (Fig. 1A). The release of the palmar contracture starts from point B (Fig. 1A) as a curved incision across the palmar aspect of the thumb MCP joint crease, reaching the radial midaxial aspect of the thumb MCP joint point G (Fig. 1A). This completes the palmar rectangular flap (Fig. 1A).

Release of the contracted palmar subcutaneous tissues is then performed while protecting and freeing the digital neurovascular bundles of the thumb and that on the radial side of the index finger. Then we release the fascia covering the first dorsal interosseous muscle dorsally and the adductor muscle palmarly. If necessary, we release the first dorsal interosseous muscle from its first metacarpal attachment and the transverse head of the adductor muscle from its origin on the third metacarpal bone. We release the thenar muscle fascia, if needed, through the bed of the palmar flap.

After release of the skin contracture over the MCP joint, we release the thick subcutaneous fascial adhesions with preservation of the digital bundles, and then we manipulate the MCP joint into extension. We do not need to release the volar MCP joint capsule to achieve full extension. Hypoplasia of the volar part of the metacarpal head and adherent capsule to its dorsal part necessitates sharp dissection.

In case of marked instability, we perform chondrodesis of the MCP joint, and in case of mild laxity of the ulnar collateral ligament, we perform a pants-over-vest plication.

We transfer the extensor indices proprius tendon through the bed of the flaps to the remnants of the extensor tendons. One may need to lengthen the flexor pollicis longus (FPL) through a separate incision in the forearm if exaggerated flexion of the IP joint develops after fully extending the MCP joint.

Correction is maintained by insertion of an intramedullary Kirschner wire across both the IP and the MCP joints in an extended position. Then we insert another wire across the first web space to maintain maximum palmar abduction. Next, flaps are rotated to adequately cover the palmar and index-thumb planes (Fig. 1C, D). The index flap rotates palmarly, curving around the base of the thumb at the level of the MCP joint (point A to point G) and the palmar rectangular flap moves dorsally to suture its proximal border to the distal border of the index flap and its advancing border BE to the line CD. The dorsal triangular flap is rotated palmarly, suturing its proximal border to the distal border of the palmar flap. Finally, adjacent borders of the flaps are sutured (Fig. 1D).

The web width increases by the breadth of the 2 triangular flaps collectively. The palmer rectangular flap increases the web depth by suturing it proximally (Fig. 2).

COMPLICATIONS

Flap loss or tip necrosis may occur if thin flaps are dissected with a narrow apex with a length-to-base ratio exceeding 3:1. Suturing under tension leads to ischemic edges, secondary healing, and fibrosis, leading to excessive scarring with possible contracture recurrence.

POSTOPERATIVE PROTOCOL

After surgery, the hand is immobilized in an above-elbow splint. At 6 weeks, Kirschner wires are removed and the splint is discontinued. Parents are instructed to encourage their children to use the affected hands and no splinting is recommended. Patients are assessed for the posture of the thumb with complete relaxation and the wrist in neutral position, the passive range of motion of the thumb joints, and stress varus and valgus testing of the MCP joint to assess its stability.

PEARLS AND PITFALLS

Thorough history taking and general examination are needed for every patient to diagnose associated anomalies and determine whether the patients belong to a special syndrome because this has both clinical and prognostic values.

Keeping the flaps as thick as possible together with respecting the dimensions of the flaps are vital for flap viability and prevention of flap ischemia and subsequent fibrosis and adverse scarring.

Releasing the skin and the tight fascia is sometimes sufficient. However, one may also need to release every structure in the first web including the muscles and carpometacarpal (CMC) joint capsule to achieve adequate web space widening. Additional procedures may be needed for completion of the flexion release such as FPL lengthening and also for regaining thumb extension with an extensor indicis proprius (EIP) transfer to the thumb extensors. We prefer intramuscular fractional lengthening over Z-lengthening for FPL lengthening because it needs no suturing and tension adjustment is easier.

Our threshold to perform chondrodesis is low because the functional outcome is good and it avoids the risk of recurrence of MCP joint instability after ligament plication.

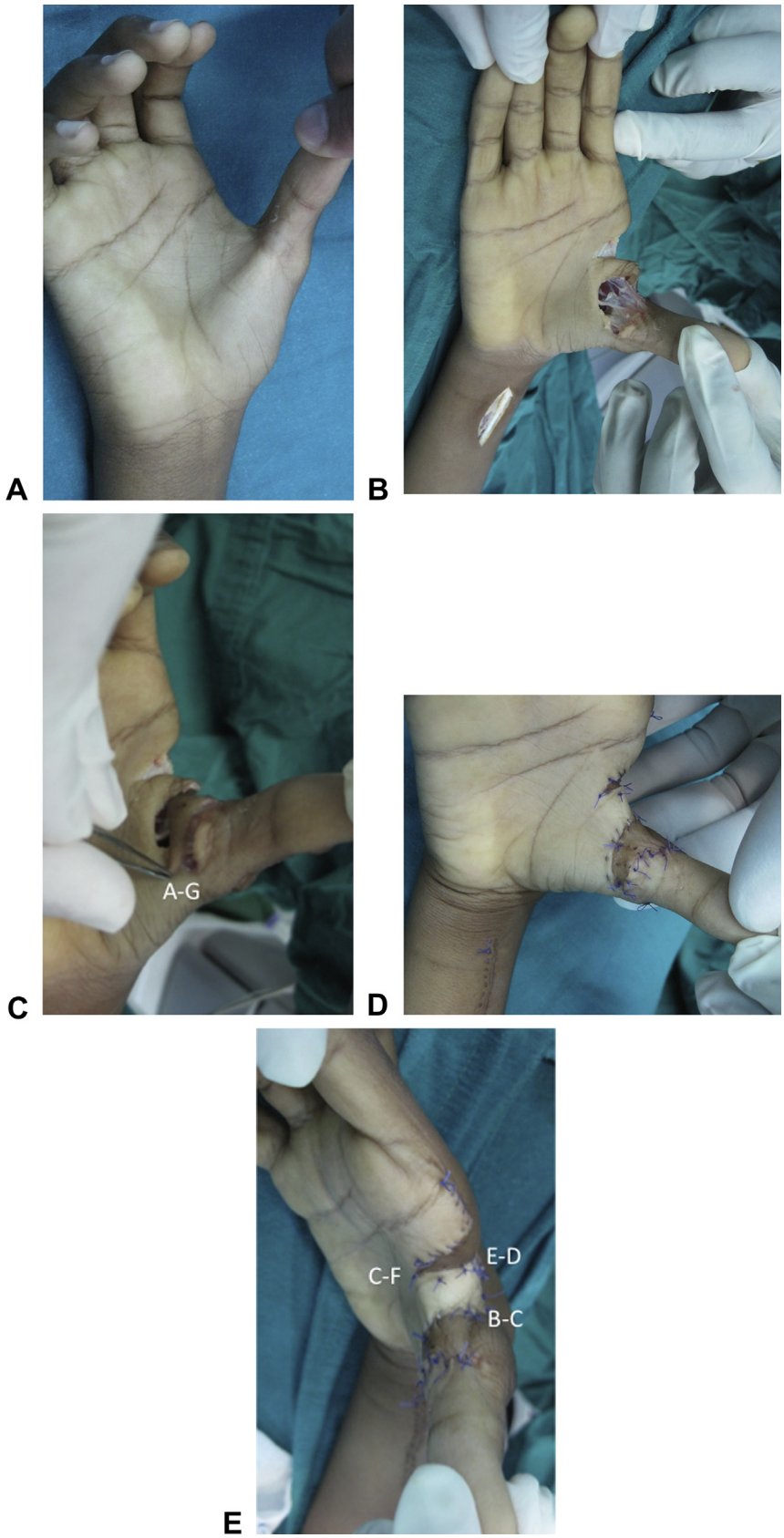

FIGURE 2: A Preoperative view demonstrates the palmar contracture. **B** Intraoperative picture after release of the palmar and web contracture. **C** Coverage of the released palmar contracture by the index triangular flap (point A to point G). **D**, **E** Released web and palmar contractures after rotation and suturing of the flaps (point C to point F; point B to point C; point E to point D).

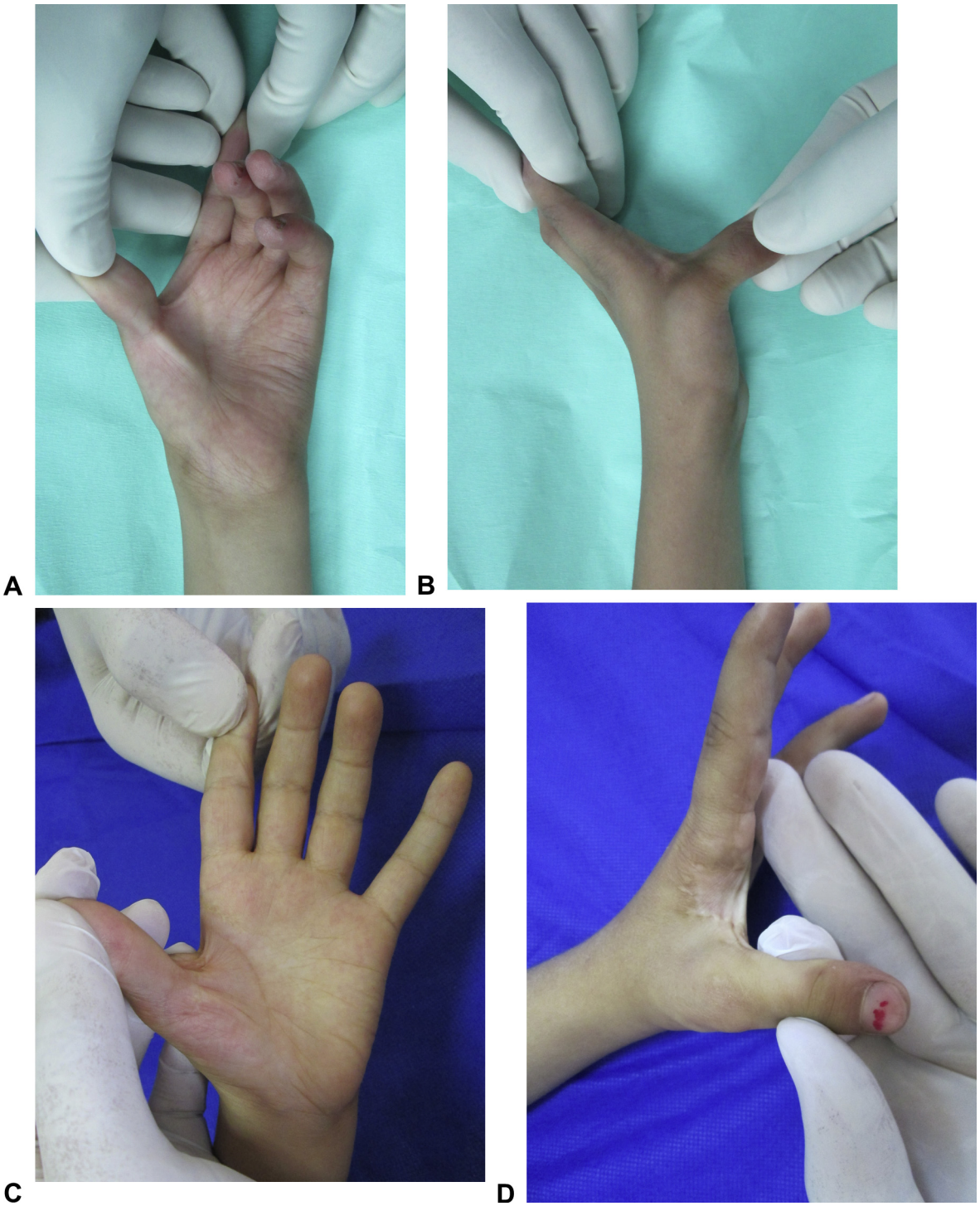

FIGURE 3: A 4-year-old girl with complex clasped left thumb with narrow web space **A** and associated palmar contracture **B**. Picture 12 months after surgery with maintained thumb index web space **C** and corrected palmar contracture **D**.

Protection of the neurovascular structures and tension-free suturing are essential for viability of the flaps and the thumb.

CASE EXAMPLE

We present a young female patient with complex clasped thumb with palmar contracture and webbing, who was 4 years of age with contracture since birth (Fig. 3). In addition to splinting, the parents tried manipulation and stretching of the thumb soft tissues in an attempt to widen the web and straighten the thumb for 18 months, at which time the child rejected the splint and manipulations were abandoned. After thorough history taking and examination, the patient

was found to have noncontributory prenatal, natal, and postnatal history suggesting a reason for this congenital anomaly and absence of syndromal anomalies. Family history for similar conditions was negative. This was a unilateral problem. She had 30° flexion deformity and global instability of the MCP joint. Range of motion of the IP joint was 50° of flexion to 10° short of full extension and there was limited palmar and radial abduction of the CMC joint. A stepwise flap design was performed together with release of the tight fascia of the dorsal and palmar aspects of the first web, release of the dorsal interosseous from the first metacarpal origin, release of the transverse head of the adductor pollicis brevis from the third metacarpal attachment, and release of the CMC joint capsule with protection of the neurovascular structures. Chondrodesis of the MCP joint was performed for the gross instability through existing incisions and fixed by intramedullary 1mm Kirschner wire. Through a separate forearm incision, intramuscular fractional lengthening of the FPL tendon was performed to achieve full IP joint extension. A second Kirschner wire was inserted across the thumb-index web from the first to the second metacarpal to maintain its width. Closure of the flaps was then performed without tension as outlined in the technique (Fig. 2). Above-elbow splinting was performed and then removed with the wires after 6 weeks when a parent-based rehabilitation program was started. At final follow-up, his MCP joint was stable and fused at 10° of flexion, IP joint motion increased from full extension to 70° flexion, CMC joint motion was 50° palmar abduction and 40° radial abduction, and the parents were satisfied with the appearance and function of the thumb.

DISCUSSION

We have designed a new tripartite flap configuration employing the index finger rotational flap in conjunction with a palmar rectangular flap and a dorsal triangular flap to correct all aspects of skin contracture encountered in complex congenital clasped thumb avoiding a thenar release incision and skin grafting. The key goal of the procedure is to provide sufficient palmar coverage and first web space widening and deepening with correction of thumb palmar flexion contracture.

This tripartite flap configuration allows the release of severe contractures without the need for further surgery or revision. We believe that this tripartite flap rearrangement for severe palmar contracture associated with complex congenital clasped thumb is a reliable and promising procedure in selected patients.

REFERENCES

1. Medina J, Lorea P, Marcos A, Martin F, Reboso L, Foucher G. Flexion deformities of the thumb: clasped thumb and trigger thumb [in French]. *Chir Main*. 2008;27(suppl 1):S35–S39.
2. Ghani HA. Modified dorsal rotational advancement flap for release of the thumb web space. *J Hand Surg Br*. 2006;31(2):226–229.
3. Lipskeir E, Weizenbluth M. Surgical treatment of the clasped thumb. *J Hand Surg Br*. 1989;14(1):72–79.
4. McCarroll HR Jr, Manske PR. The windblown hand: correction of the complex clasped thumb deformity. *Hand Clin*. 1992;8(1): 147–159.
5. Weckesser EC. Congenital flexion-adduction deformity of the thumb (congenital clasped thumb). *J Bone Joint Surg Am*. 1955;37(5): 977–983; discussion 983–984.
6. McCarroll HR Jr. Congenital flexion deformities of the thumb. *Hand Clin*. 1985;1(3):567–575.
7. Broadbent TR, Woolf RM. Flexion-adduction deformity of the thumb: congenital clasped thumb. *Plast Reconstr Surg*. 1964;34: 612–616.
8. White JW, Jensen WE. The infant's persistent thumb-clutched hand. *J Bone Joint Surg Am*. 1952;24(3):680–688.
9. Weckesser EC, Reed JR, Heipel KG. Congenital clasped thumb (congenital flexion-adduction deformity of the thumb). A syndrome, not a specific entity. *J Bone Joint Surg Am*. 1968;50(7): 1417–1428.
10. Ezaki M, Oishi SN. Index rotation flap for palmar thumb release in arthrogryposis. *Tech Hand Up Extrem Surg*. 2010;14(1): 38–40.