



## Furlow palatoplasty for previously repaired cleft palate with velopharyngeal insufficiency<sup>☆</sup>



Mosaad Abdel-Aziz<sup>a,\*</sup>, Ahmed Nassar<sup>a</sup>, Mohammed Rashed<sup>b</sup>, Nader Naguib<sup>b</sup>,  
Abdel-Rahman El-Tahan<sup>c</sup>

<sup>a</sup> Department of Otolaryngology, Cairo University, Egypt

<sup>b</sup> Department of Otolaryngology, Beni Suef University, Egypt

<sup>c</sup> Department of Otolaryngology, Aswan University, Egypt

### ARTICLE INFO

#### Article history:

Received 11 June 2015

Received in revised form 30 July 2015

Accepted 31 July 2015

Available online 8 August 2015

#### Keywords:

Furlow palatoplasty

Velopharyngeal insufficiency

Cleft palate

Hypernasality

### ABSTRACT

**Objective:** Velopharyngeal insufficiency (VPI) is a common complication after cleft palate repair, it may be due to lack of levator sling reconstruction and/or palatal shortening. Furlow palatoplasty has the advantages of retro-positioning of levator palati muscles and palatal lengthening. The aim of this study was to assess the efficacy of Furlow palatoplasty in the treatment of VPI in patients who undergone previous palatoplasty.

**Methods:** Twenty-three children with post-palatoplasty VPI were included in the study. Furlow technique which was not used in the primary repair, has been used as a secondary corrective surgery. Preoperative and postoperative evaluation of velopharyngeal function was performed, using auditory perceptual assessment (APA) and nasometry for speech, and flexible nasopharyngoscopy for velopharyngeal closure.

**Results:** Significant improvement of APA and nasalance score for oral and nasal sentences was achieved. Flexible nasopharyngoscopy showed complete velopharyngeal closure in 19 patients (82%) postoperatively.

**Conclusion:** Furlow palatoplasty is considered a useful treatment option for VPI in patients with previously repaired cleft palate, it improves the speech and velopharyngeal closure.

© 2015 Elsevier Ireland Ltd. All rights reserved.

## 1. Introduction

Velopharyngeal insufficiency (VPI) is the inability to completely close the velopharyngeal port during speech. The resultant leakage of air into the nasal cavity during speech can cause hypernasal vocal resonance and nasal emissions [1]. The effect of VPI on speech and resonance ranges from mild speech distortion to a catastrophic disruption of speech intelligibility, leading to social communicative problem for the patients and their families [2].

The commonest cause of VPI is the palatal cleft even after repair, the problem may be due to the incomplete lengthening of the palate, lack of levator sling reconstruction, the scar contracture of the straight line closure that may even shorten the palate, and the occurrence of palatal fistulae [3–5]. The frequency of VPI after cleft palate repair that may need secondary corrective surgery varies

in different literature between 15% and 45%. This wide range of incidence is due to the presence of different techniques for repair of cleft palate, and even the same technique may be done by different ways [6].

Furlow double-opposing Z-plasty was first used in cleft palate repair in 1978 [7], it aims to lengthen the palate through the Z-plasty effect and to prevent the longitudinal scar contracture, it also reconstructs the levator sling by displacement of levator palati muscles of both sides posteriorly overlapping each other after reorientation of their fibers from an abnormal vertical direction to a transverse one [8,9]. Long-term studies have demonstrated improved speech results and reduced rates of secondary surgery for correction of VPI on comparing the Furlow technique to other palatoplasty methods [10]. The aim of this study was to assess the efficacy of performing Furlow double opposing Z-plasty for patients presented with post-palatoplasty VPI.

## 2. Materials and methods

One hundred twenty-two patients were referred to our institutes with hypernasal speech after repair of their clefts in

<sup>☆</sup> The study was carried out in the Departments of Otolaryngology of Cairo University, Beni Suef University and Aswan University, Egypt.

\* Corresponding author at: 2 el-salam st., King Faisal, Above El-baraka bank, Giza, Cairo, Egypt. Tel.: +20 1005140161; fax: +20 225329113.

E-mail address: [mosabeez@yahoo.com](mailto:mosabeez@yahoo.com) (M. Abdel-Aziz).

the period from June 2012 to March 2014. Of these, 23 patients fulfilled the study criteria. The ages of the patients ranged from 5 to 13 years (with a mean of 8.5 years), 14 males and 9 females. The study was conducted in the Departments of Otolaryngology of Cairo University, Beni Suf University, and Aswan University. The original defects included 5 patients with bilateral complete cleft lip and palate, 9 patients with unilateral complete cleft lip and palate and 9 patients with cleft soft palate, complete clefts were repaired by 2 flap palatoplasty while incomplete clefts were repaired by Veau–Wardill–Killner technique. Patients who underwent Furlow Z-plasty or intravelar palatoplasty for repair of their clefts, who presented with palatal fistulae or other craniofacial anomalies, or who were subjected for secondary corrective velopharyngeal surgery were excluded from the study. Informed consents were obtained from the parents of the patients and the principles outlined in the Declaration of Helsinki were followed.

All patients were subjected to the following.

### 2.1. Preoperative assessment

- Otolaryngologic examination: Full ear, nose and throat, and head and neck examination was performed for detection of other associated diseases. Ear examination, including tympanometry, was performed for detection of middle ear effusion, and oral examination was performed to assess the condition of the palate.
- Auditory perceptual assessment (APA) of speech: hypernasality, nasal emission of air, weak pressure consonants were analyzed for every individual patient. Each of these parameters was graded along a 5-point scale (0–4) in which 0: normal, and 4: severely affected, with a total score of 12 on the 3 elements. The lower the score achieved on this rating scale, the less incompetence the patient demonstrates [3]. The APA data were recorded for postoperative review.
- Nasometric assessment: instrumental assessment of nasalance was done using Nasometry (Kay Elemetrics, model 6200, NJ, USA) which provides an acoustic measure of movement of the vibrational energy through the vocal tract. Nasometric data were obtained while the patients read or repeated standardized Arabic nasal and oral sentences.
- Flexible nasopharyngoscopy: to visualize the velopharyngeal port. The nasopharyngoscopy was provided with a high-intensity cold light and a special endoscopic television system for videotape recording. This was accomplished using a high-resolution Karlheinz Hinze S/N 151385 endoscope (Karlheinz Hinze Optoengineering GmbH & Co., Hamburg, Germany), Storz endoscope video camera (Karl Storz GmbH & Co. KG; Tuttlingen, Germany), and Panasonic SR 500 video recorder (Osaka, Japan). The nose was decongested and anesthetized with a mixture of 4% lidocaine and 0.05% oxymetazoline hydrochloride before the procedure. Velopharyngeal closure was assessed while the patients repeating Arabic sentences loaded with high oral pressure consonants. VPI was considered in the presence of velopharyngeal gap and/or bubbles [11].

### 2.2. Operative procedure

Under general anesthesia with oral endotracheal intubation, incisions were marked and the palate was injected with 0.5% Xylocaine in adrenaline (1:100,000). The soft palate was split into 2 halves from the midline recreating a cleft soft palate. Furlow double opposing Z-plasty technique was used for repair [7,10,11].

### 2.3. Postoperative assessment

Patients were seen postoperatively at one week interval for three weeks, then monthly for at least one year. All patients have been received speech therapy one month postoperatively.

By the end of the follow up period; APA, nasometric assessment, and flexible nasopharyngoscopy were performed with recording of the same parameters that had been recorded preoperatively. Comparison of the preoperative and postoperative data was done.

### 2.4. Statistical method

Data were coded and summarized using Statistical Package for Social Sciences version 17.0 for Windows (SPSS Inc., Chicago, IL). Quantitative variables are presented as mean  $\pm$  standard deviation. Comparison of preoperative and postoperative results of auditory perceptual assessment and nasometric assessment was done using paired two-sample *t* test.  $P < 0.05$  was considered statistically significant.

## 3. Results

Twenty three children with previously repaired cleft palate were enrolled in the study, all patients were referred to our institute because of hypernasal speech after failure of speech therapy. Furlow double opposing Z-plasty was selected as the technique of palatal re-repair, all patients demonstrated the disease as an isolated deformity with no other congenital anomalies. No intraoperative complications were encountered, all patients showed complete wound healing with no dehiscence or fistulae (Fig. 1). Myringotomy with T-tubes insertion was performed bilaterally for 17 patients who demonstrated middle ear effusion.

Regarding assessment of speech, the mean preoperative baseline of APA was 7.55 ( $\pm 2.03$ ) that improved to 6.82 ( $\pm 1.81$ ) (Table 1). The difference between preoperative and postoperative scores was significant ( $P$  value = 0.001).

The preoperative nasalance score was 35.82 ( $\pm 3.70$ ) for the nasal sentences and 13.52 ( $\pm 1.62$ ) for the oral sentences, improved to 33.30

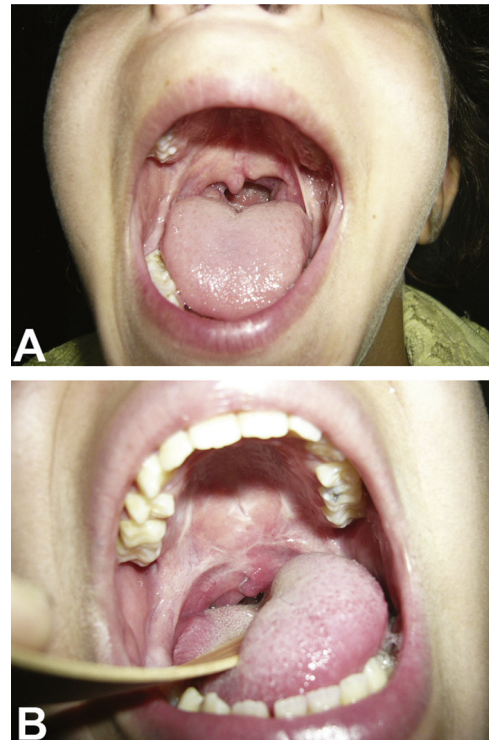


Fig. 1. (A) A preoperative view of a patient with poorly repaired short palate. (B) A postoperative view of the same patient after Furlow palatoplasty.

**Table 1**  
Pre and postoperative assessment of speech parameters.

	Preoperative	Postoperative	P value
APA	7.55 ( $\pm 2.03$ )	6.82 ( $\pm 1.81$ )	0.001
Nasalance score for NS	35.82 ( $\pm 3.70$ )	33.30 ( $\pm 4.12$ )	0.011
Nasalance score for OS	13.52 ( $\pm 1.62$ )	12.45 ( $\pm 1.61$ )	0.002

APA, auditory perceptual assessment; NS, nasal sentences; OS, oral sentences.

( $\pm 4.12$ ) for the nasal sentences and 12.45 ( $\pm 1.61$ ) for the oral sentences (Table 1). The changes were statistically significant for both nasal and oral sentences ( $P$  value = 0.011, 0.002 respectively).

Preoperative flexible nasopharyngoscopy showed VPI in all patients with abnormal shortening of the soft palate that did not touch the posterior pharyngeal wall during articulation (Fig. 2). Also, all patients demonstrated a midline notch of the nasal surface of the soft palate, this notch may be due to inadequate reconstruction of levator sling with gapping between palatal muscles of both sides. Postoperatively, nineteen patients (82%) demonstrated complete velopharyngeal closure without gapping or bubbles, while 4 patients still had VPI that improved in comparison to the preoperative video records. All patients showed absence of the midline notch of the soft palate, it denotes reconstruction of the levator sling.

#### 4. Discussion

The aim of the cleft palate repair is not only to close an anatomical defect, it also includes correction or even prevention of a physiological error. Speech problems after cleft palate repair may be due to palatal shortening and/or weak palatal elevation, shortening may be secondary to fibrous contracture of a straight line closure of the soft palate. In patients with cleft palate, the

levator palati muscles are usually inserted to the posterior border of the hard palate leaving a midline gap, while in normal individuals the muscles of both sides unite together forming a levator sling which elevates the soft palate upwards during speech articulation to close the velopharyngeal port. Inadequate closure of this port leads to excessive nasal resonance of speech with its consequent problems [1,3,5].

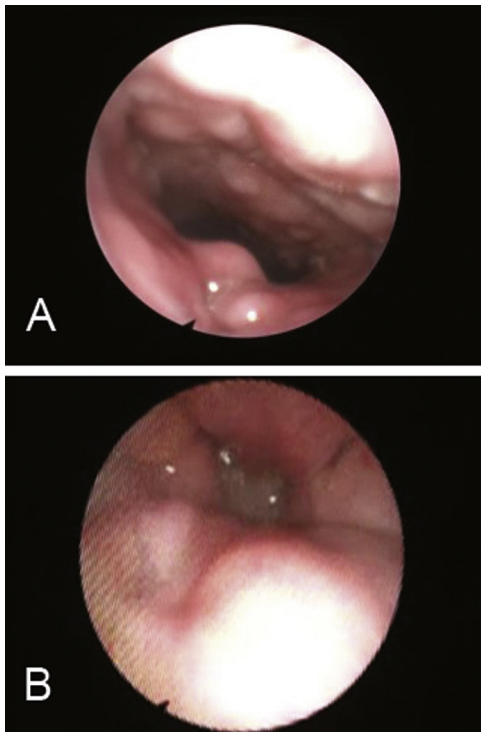
This study included 23 patients with previously repaired cleft palate, all patients presented with hypernasal speech. Furlow technique was used for palatal re-repair. Preoperative and postoperative assessment of velopharyngeal function was performed, using APA, nasometry and flexible nasopharyngoscopy. Postoperatively, 19 patients (82%) achieved complete velopharyngeal closure, and the overall APA, and nasalance score showed significant improvement. Noorchashm et al. [9] used Furlow palatoplasty on 19 patients who had VPI, with a history of prior straight-line palatoplasty, they reported correction of speech error in all patients even those with preoperative palatal fistulae. Also, Deren et al. [12] used the same technique on 27 patients who presented with VPI after Veau–Wardill–Kilner palatoplasty, they achieved correction of hypernasal speech in about 80% of their patients and increase in palatal length by about 44%. Chim et al. [13] advised double-opposing Z-plasty for secondary surgical management of VPI in the absence of a primary Furlow palatoplasty, they achieved an improvement of the total score of APA with complete velopharyngeal closure in 76% of their patients.

Various surgical techniques have been described in the literature for treatment of VPI after cleft palate repair, the common goal of these techniques is to create a permanent partial obstruction of the velopharyngeal port [3]. Pharyngeal flap is created by insertion of an elevated posterior pharyngeal wall flap into the free edge of the soft palate, leaving two lateral ports for breathing. Although, pharyngeal flap is considered the gold standard treatment of VPI, it has a negative impact on the airway with a high rate of obstructive breathing disorder [3,14,15]. Sphincter pharyngoplasty is created by insertion of bilaterally elevated lateral pharyngeal wall flaps into a raw area in the posterior pharyngeal wall, it appears to be a more physiologic solution as it preserves the circumferential nature of the velopharyngeal port. However, the incidence of airway obstruction that may follow pharyngeal flap is lower after sphincter pharyngoplasty [15,16]. Posterior pharyngeal wall augmentation, obtained for example by fat, Teflon, or hydroxyapatite injections, may correct VPI of patients with small velopharyngeal gap [17,18].

Furlow palatoplasty technique has many advantages, it aims mainly to lengthen the soft palate by the Z-plasty effect with no straight line closure that may be followed by fibrous contracture and shortening [7,19]. Also, it aims to reconstruct the levator sling through re-direction of the levator palati fibers so that both muscles overlap each other posteriorly. Good palatal elevation with adequate lengthening could make firm contact of the soft palate to the posterior pharyngeal wall with proper velopharyngeal closure [20]. It has a less airway obstructive effect than the secondary corrective pharyngeal procedures [5,19,21]. It can be used as a single procedure for treatment of VPI, and may be combined with another method as sphincter pharyngoplasty in severe cases [4,22].

#### 5. Conclusion

Velopharyngeal insufficiency may persist after primary repair of cleft palate, it may cause a speech deficit. Although there are many treatment alternatives, Furlow palatoplasty is considered a useful method for management of VPI in patients with previously repaired cleft palate.



**Fig. 2.** Flexible nasopharyngoscopic views during articulation. (A) Preoperative view with incomplete velopharyngeal closure and a notch on the nasal surface of the soft palate. (B) Postoperative view with complete velopharyngeal closure without notching of the soft palate.

**Financial support**

None declared.

**Conflict of interest**

None declared.

**Acknowledgments**

The authors thank the staff members of the Phoniatic unit who carried out the speech evaluation and nasometric assessment.

**References**

- [1] A. Ysunza, M.C. Pamplona, F. Molina, M. Drucker, J. Felemovicus, E. Ramirez, et al., Surgery for speech in cleft palate patients, *Int. J. Pediatr. Otorhinolaryngol.* 68 (2004) 1499–1505.
- [2] V.P.I. Surgical Trial, Group, Pharyngeal flap and sphincterplasty for velopharyngeal insufficiency have equal outcome at 1 year postoperatively: results of a randomized trial, *Cleft Palate Craniofac. J.* 42 (2005) 501–511.
- [3] M. Abdel-Aziz, H. El-Hoshy, H. Ghandour, Treatment of velopharyngeal insufficiency after cleft palate repair depending on the velopharyngeal closure pattern, *J. Craniofac. Surg.* 22 (2011) 813–817.
- [4] M.P(1) Carlisle, K.J. Sykes, V.K. Singhal, Outcomes of sphincter pharyngoplasty and palatal lengthening for velopharyngeal insufficiency: a 10-year experience, *Arch. Otolaryngol. Head Neck Surg.* 137 (2011) 763–766.
- [5] Y. Dong, F. Dong, X. Zhang, F. Hao, P. Shi, G. Ren, et al., An effect comparison between Furlow double opposing Z-plasty and two-flap palatoplasty on velopharyngeal closure, *Int. J. Oral Maxillofac. Surg.* 41 (2012) 604–611.
- [6] S. Bicknell, L.R. McFadden, J.B. Curran, Frequency of pharyngoplasty after primary repair of cleft palate, *J. Can. Dent. Assoc.* 68 (2002) 688–692.
- [7] L.T. Furlow Jr., Cleft palate repair: preliminary report on lengthening and muscle transposition by Z-plasty, in: Presented at the Southeastern Society of Plastic and Reconstructive Surgeons, Boca Raton, Florida, 1978.
- [8] R.E. Kirschner, D. LaRossa, Cleft lip and palate, *Otolaryngol. Clin. N. Am.* 33 (2000) 1191–1215.
- [9] N. Noorchashm, J.R. Dudas, M. Ford, B. Gastman, F.W. Deleyiannis, L. Vecchione, et al., Conversion Furlow palatoplasty: salvage of speech after straight-line palatoplasty and incomplete intravelar veloplasty, *Ann. Plast. Surg.* 56 (2006) 505–510.
- [10] O.A. Arosarena, Cleft lip and palate, *Otolaryngol. Clin. N. Am.* 40 (2007) 27–60.
- [11] J.A. Perkins, C.W. Lewis, J.S. Gruss, L.E. Eblen, K.C.Y. Sie, Furlow palatoplasty for management of velopharyngeal insufficiency: a prospective study of 148 consecutive patients, *Plast. Reconstr. Surg.* 116 (2005) 72–80.
- [12] O. Deren, M. Ayhan, A. Tuncel, M. Görgü, A. Altuntaş, R. Kutlay, et al., The correction of velopharyngeal insufficiency by Furlow palatoplasty in patients older than 3 years undergoing Veau–Wardill–Kilner palatoplasty: a prospective clinical study, *Plast. Reconstr. Surg.* 116 (2005) 85–93.
- [13] H. Chim, Y. Eshraghi, S. Iamphongsai, A.K. Gosain, Double-opposing Z-palatoplasty for secondary surgical management of velopharyngeal incompetence in the absence of a primary Furlow palatoplasty, *Cleft Palate Craniofac. J.* (2014), <http://dx.doi.org/10.1597/13-187> (in press).
- [14] J.E. Riski, G.L. Ruff, G.S. Georgiade, W.J. Barwick, P.D. Edwards, Evaluation of the sphincter pharyngoplasty, *Cleft Palate Craniofac. J.* 29 (1992) 254–261.
- [15] E.F. Rudnick, K.C. Sie, Velopharyngeal insufficiency: current concepts in diagnosis and management, *Curr. Opin. Otolaryngol. Head Neck Surg.* 16 (2008) 530–535.
- [16] L.M. de Serres, F.W. Deleyiannis, L.E. Eblen, J.S. Gruss, M.A. Richardson, K.S. Sie, Results with sphincter pharyngoplasty and pharyngeal flap, *Int. J. Pediatr. Otorhinolaryngol.* 48 (1999) 17–25.
- [17] C. Saint Raymond, G. Bettega, C. Deschaux, J. Lebeau, B. Raphael, P. Lévy, et al., Sphincter pharyngoplasty as a treatment of velopharyngeal incompetence in young people, a prospective evaluation of effects on sleep structure and sleep respiratory disturbances, *Chest* 125 (2004) 864–871.
- [18] J.A. Sipp, J. Ashland, C.J. Hartnick, Injection pharyngoplasty with calcium hydroxyapatite for treatment of velopalatal insufficiency, *Arch. Otolaryngol. Head Neck Surg.* 134 (2008) 268–271.
- [19] E(1) Guneren, O.A. Uysal, The quantitative evaluation of palatal elongation after Furlow palatoplasty, *J. Oral Maxillofac. Surg.* 62 (2004) 446–450.
- [20] M. Abdel-Aziz, H. El-Hoshy, N. Naguib, R. Reda, Furlow technique for treatment of soft palate fistula, *Int. J. Pediatr. Otorhinolaryngol.* 76 (2012) 52–56.
- [21] Y.F. Liao, M.S. Noordhoff, C.S. Huang, P.K. Chen, N.H. Chen, C. Yun, et al., Comparison of obstructive sleep apnea syndrome in children with cleft palate following Furlow palatoplasty or pharyngeal flap for velopharyngeal insufficiency, *Cleft Palate Craniofac. J.* 41 (2004) 152–156.
- [22] L.A. Bohm, N. Padgett, R.J. Tibesar, T.A. Lander, J.D. Sidman, Outcomes of combined Furlow palatoplasty and sphincter pharyngoplasty for velopharyngeal insufficiency, *Otolaryngol. Head Neck Surg.* 150 (2014) 216–221.