

Prediction of Pulmonary Regurge and Right Ventricular Function in Asymptomatic Repaired Tetralogy of Fallot Patients in Developing Countries: A Comparison to Cardiac Magnetic Resonance Imaging

Hala Agha*, Doaa Mahgoub Aly, Fatma Alzahraa Moustafa, Ahmed Kharabish, Yasser Hussein Kamal, Gehan H Hussein, Lamiaa El-Zambely, Hassan El-Kiky, Mohamed Abd El-Raouf and Mohamed Youssef Abd El Rahman

Faculty of Medicine, Cairo University, Egypt

Abstract

Objective: To assess the value of conventional echocardiographic measurements for quantification of pulmonary regurge and right ventricular function in comparison to Cardiac Magnetic Resonance Imaging (CMR) after surgical repair of Tetralogy Of Fallot (TOF).

Methods: Twenty five asymptomatic children after TOF repair (9.2 ± 4 years) were compared to twenty five age matched healthy children. Echocardiographic quantification of pulmonary regurge was assessed by (1) pulmonary regurge jet width/pulmonary artery diameter, (2) pulmonary pressure half time, (3) pulmonary regurge index; pulmonary regurge duration to diastole duration, (4) no flow time; diastole duration - pulmonary regurge duration and (5) diastole/systole velocity time integral ratio. Measurements derived from conventional echocardiography were compared to pulmonary regurgitant fraction, right ventricular volumes and ejection fraction by CMR.

Results: On CMR, the pulmonary regurgitant fraction was $28.64 \pm 10.2\%$. By conventional echocardiography, pulmonary regurge index and no flow time were found to offer the best prediction for severity of pulmonary regurge. Pulmonary regurge index of <0.8 has sensitivity of 86.36% and specificity of 100% (AUC=0.924) and no flow time of >64 msec has sensitivity of 81% and specificity of 100% (AUC=0.894) in identifying significant pulmonary regurge. Compared to controls, patients after TOF repair showed significantly lower right ventricle myocardial velocities, higher E/E' ratio and prolonged MPI. Among the TOF patients, right ventricular MPI showed significant negative correlation ($r=-0.402$; $P=0.008$) with tricuspid valve annulus peak systolic velocity (S') and significant positive correlation ($r=0.413$; $P=0.04$) with right ventricle stroke volume by CMR.

Conclusion: Conventional echocardiography can offer a simple, readily available and accurate tool for quantification of pulmonary regurge and right ventricular function during mid- term follow up after surgical repair of tetralogy of Fallot.

Keywords: Tetralogy of fallot; Echocardiography; Tissue doppler imaging; Pulmonary regurge; Cardiac MRI; Myocardial velocities; Myocardial performance index

Introduction

Although the long-term outcome of surgical repair of Tetralogy Of Fallot (TOF) in developing countries is unknown, Pulmonary Regurgitation (PR) remains an inevitable post repair lesion influencing earlier morbidities [1-3]. Earlier studies reported that PR among this cohort is an important culprit for exercise intolerance, atrial and ventricular arrhythmia, and sudden cardiac death [4-6]. Recent studies have reported improved Right Ventricular (RV) volumes and function, improved exercise capacity, stabilization of QRS duration after Pulmonary Valve Replacement (PVR) [7,8]. Cardiac Magnetic Resonance Imaging (CMR) is now considered the gold standard for non-invasive quantification of PR and RV volumes [9-11]. However, because of the limited availability and high cost of the procedure, replacing CMR with the simple and readily available echocardiography during successive follow-up appointments, has been always a special area of interest to pediatric cardiologists. In recent years, new techniques based on tissue Doppler imaging (TDI) have emerged to aid in assessment of RV function [12-16]. They seemed clinically useful and potentially less load dependent than other echocardiographic markers of RV myocardial performance. Likewise, many attempts in echocardiography were made to detect hemodynamically significant PR and to predict PR severity [17,18]. The aim of the current study is therefore to examine the clinical accuracy of different parameters derived from conventional echocardiography for quantification of

PR assessed by CMR and to suggest a best prediction of its severity. Moreover, we planned to assess the utility of TDI in determining RV function during mid-term follow up of TOF patients after repair.

Patients and Methods

Subject population

We studied twenty five asymptomatic patients (age <18 years) who had corrective intra-cardiac repair for TOF. They were selected on the basis that they were living in the vicinity of Cairo, Egypt and came for regular outpatient visits at least once a year to Pediatric Post-Operative Outpatient Clinic in Cairo University Children Hospital. Their mean

*Corresponding author: Hala Agha, Chief of Echocardiography Laboratory, Children Hospital Cairo University (CUCH), Faculty of Medicine, Cairo University, and Cairo Kinder Clinic; 31 El Marwa Street, Off Shooting Club Street, Mohandesseen, Egypt, Tel: +201001113284, +2035856985; E-mail: halaazza@gmail.com, hala.agma@kasralainy.edu.eg

Received March 25, 2014; Accepted May 30, 2014; Published June 10, 2014

Citation: Agha H, Aly DM, Moustafa FA, Kharabish A, Kamal YH, et al. (2014) Prediction of Pulmonary Regurge and Right Ventricular Function in Asymptomatic Repaired Tetralogy of Fallot Patients in Developing Countries: A Comparison to Cardiac Magnetic Resonance Imaging. J Clin Exp Cardiol 5: 316. doi:10.4172/2155-9880.1000316

Copyright: © 2014 Agha H, et al. This is an open-access article distributed under the terms of the Creative Commons Attribution License, which permits unrestricted use, distribution, and reproduction in any medium, provided the original author and source are credited.

age at the time of the study was 9.2 ± 4 years (3-18 years). Their age at complete repair was 2.5 ± 1.9 years (8 months-8years). The follow up period was 6.7 ± 3.5 years (2-5 years). During surgical repair, the Right Ventricular Outflow Tract (RVOT) was reconstructed by right ventricular outflow patch in all patients. A prior palliative procedure (modified Blalock-Taussig (MBT) shunt) was performed in two patients. None of the examined patients had a second operation. Patients having implanted pacemakers, absent pulmonary valve syndrome or significant residual abnormality (VSD, valvular or peripheral pulmonary stenosis (RV pressure >50 mmHg) were excluded from the study. Echocardiographic data from the TOF group were compared with those from 25 age-matched healthy subjects, who were examined for an innocent murmur. Their mean age was 9.2 ± 4 years (3-18 years). Study was approved by Cairo University Children's Hospital Review Board for Human Research and Ethics, and written informed consent was obtained from patient parents, according to our institute's guidelines. Patients underwent a 12 leads ECG, echocardiogram and CMR scan within 3 months of each other between December 2011 and April 2013.

Electrocardiogram (ECG)

All patients had a 12 leads surface ECG performed using a Bionet Cardio touch 3000 recorder (Bionet America) at a speed of 25 mm/s, and 1 mV/cm standardization. The maximum QRS duration in any lead was measured from the first to the last sharp vector crossing the isoelectric line.

Echocardiogram

All patients and healthy controls were assessed by Vivid 7 GE echocardiography device with 3 and 5 MHz probes. Measurements were recorded on CD/DVD for later offline analysis. Trans-thoracic echocardiography was performed and interpreted by an experienced pediatric cardiologist. The mean value of flow velocities and time intervals was calculated in 3 consecutive heart cycles. Color and continuous wave Doppler assessment of PR was obtained in the parasternal short axis view at the level of the Pulmonary Valve (PV). PR was defined by color Doppler as retrograde diastolic jet in the RVOT, and by Doppler signal as early diastolic flow reversal of at least 2 m/s. Quantification of PR was assessed by (1) Color Doppler flow mapping-ratio between regurgitant jet width at the level of PV and PV annulus diameter; jet less than one-third of PV annulus diameter, starting cranial to the PV was considered mild PR. Jet between one- and two-thirds of the PV annulus diameter, starting up to the middle of the main pulmonary artery was considered moderate PR and jet more than two-thirds of the PV annulus, starting cranial to the bifurcation of the main pulmonary artery was considered severe PR [18]. (2) Continuous wave Doppler echo- Pressure Half Time (PHT) and Deceleration Time (DT); DT was measured from the peak of retrograde diastolic velocity profile to the end of flow, PHT was then automatically calculated as the time required for the peak velocity to fall to one-half the square root of its peak value. PR of PHT <100 ms was considered hemodynamically significant [17]. Pulmonary Regurgitation Index (PRI); ratio between duration of PR flow time (flow time was measured from the beginning till the end of the PR spectrum) and duration of diastole (from electrocardiogram end point of T wave to the beginning of systolic flow of pulmonary valve). Based on previously published data, PRI of <0.77 indicated at least moderate degree of PR [18]. No flow time (NFT); result of subtracting PR flow time duration from entire diastole duration. NFT >80 ms indicated severe PR [19]. (3) Pulsed Wave (PW) Doppler echo; Diastole Systole Time Velocity Integral ratio (DSTVI): we obtained time-velocity integrals of diastolic and systolic flows by

tracing retrograde (diastolic) and antegrade (systolic) flow waves. Ratio between both values was calculated and values greater than 0.49 were considered more than mild [20]. RV function was assessed by (1) Tricuspid Valve (TV) inflow velocity profiles; peak early filling velocity (E wave), peak late filling velocity (A wave) and E/A ratio, with the pulsed wave Doppler sample placed at the tip of the tricuspid valve, in an apical four chamber view (2) TDI derived TV annulus peak systolic velocity (S'), early diastolic (E') and late diastolic (A') velocities, by placing a 2 mm sample volume at the lateral corner of the TV annulus [21,22]. (3) Myocardial Performance Index (MPI) of the RV was also measured by pulsed DTI, from the formula $=a'-b'/b'$, where a' is the time interval between the end of A' wave (the onset of R wave on ECG) to the onset of E' wave and b' is the time interval between the onset to the end of the S' wave [23].

CMR

CMR studies were acquired with 1, 1.5, and 3 Tesla Philips systems by using a phased-array cardiac coil scanner. Sedation was used when appropriate, according to patient's age and ability to lie still for the scan. Ventricular volumetric protocol was followed based on previously published studies using the steady-state, free-precession cine sequence [24]. Ventricular stroke volume (SV) was determined using a routine standard stack of cine short-axis views from the atrio-ventricular junction through the cardiac apex. Typical slice thickness was 6-8 mm inter-slice space 0 to 2 mm. End-systolic and end-diastolic volumes were measured by manually tracing the area of the endocardial surfaces. The RV papillary muscles and infundibulum up to the pulmonary annulus were included in the RV volume. Phases of end systole and end diastole were defined visually, as the phases with the smallest and largest volumes respectively and independently. Dedicated software calculated the SV by subtracting the End-Systolic Volume (ESV) from the End-Diastolic Volume (EDV). The ventricular ejection fraction was calculated as $(\text{end-diastolic volume} - \text{end-systolic volume}) / \text{end diastolic volume} \times 100\%$. All volumes were indexed to body surface area and compared to the published normative data [25,26]. Velocity Encoding Phase Contrast (VENC) flow measurements were also performed based on previously published studies [27]. Velocity maps were generated at 20 equidistant phases of the cardiac cycle, from which time-resolved volume flow curves were generated. Plane gradient-echo sequence was performed in the main pulmonary artery 1 cm distal and perpendicular to the pulmonary valve annulus, to assess the Regurgitant Fraction (RF%). RF% was calculated by dividing the regurgitant volume across the pulmonary annulus by the total forward volume. PR was graded as mild if the RF% was $<20\%$, moderate if it was between 20% and 40%, and severe if $>40\%$ [28]. Using the optimal velocity encoding value, imaging was performed with a breath-hold sequence lasting 15 seconds.

Statistical analysis

Statistical calculations were done using computer programs SPSS (Statistical Package for the Social Science; SPSS Inc., Chicago, IL, USA) version 15 for Microsoft Windows. Continuous variables were described by mean \pm standard deviation (\pm SD), median and ranges when variables were non-parametric. Categorical variables were described using count and percentages. Comparison of numerical variables between the study groups was done using Student *t* test for independent samples when normally distributed and Mann Whitney *U* test for independent samples when not normally distributed. Correlation between various variables was done using Pearson moment correlation equation. *P* values less than 0.05 was considered statistically significant. Sensitivity, specificity and diagnostic accuracies of each

echocardiographic method for quantification of PR were calculated manually, based on previously published cut off values. RF% found on CMR (dichotomized at 20%) was used as the gold standard. Receiver Operating Characteristic (ROC) curves were constructed for the same measurements, to suggest optimal cut-off points with the best possible specificity, sensitivity and diagnostic accuracy in identifying significant PR (RF% obtained by CMR was considered the reference). We also created a binary logistic regression model using hemodynamically significant PR as a dependent variable and CW and PW derived quantitative echocardiographic measures for PR as independent variables. Color Doppler was not included since it was a categoric rather than a continuous variable.

Results

Clinical and demographic patient characteristics

The study cohort consisted of 25 patients with TOF assessed in their mid-term postoperative follow up at a mean age of 9.2 years and at least 1 year after total surgical repair. The majority of patients were in NYHAI. All were in sinus rhythm, but with increased QRS duration; mean QRS duration in ECG of 126 ± 19.8 msec. 52% of patients had Right Bundle Branch Block (RBBB) and none of the patients had ventricular arrhythmias (Table 1).

CMR findings

In our cohort 3 (12%) patients had mild, 17 (68%) had moderate and 5 (20%) had severe degree of PR, with the mean value of RF% in CMR was $28.64 \pm 10.2\%$ (Table 2). In our patients, most of the RV indices were deranged when compared to published references. Mean right ventricular volumes were significantly higher than normal (p values <0.001 for all parameters) (Table 3). However, most of patients had relatively preserved right ventricular ejection fraction (RVEF); mean RVEF was $54\% \pm 5$.

Echocardiographic findings

Quantification of PR: We tested the ability of echocardiography to identify patients with hemodynamically significant PR. Regurgitation was considered significant when associated with a dilated RV end-diastolic volume which was found to be RF% $\geq 20\%$ in our cohort [17,20]. It was clearly evident that echocardiography has high sensitivity in identifying more than mild PR (RF $\geq 20\%$), but less specificity in excluding mild degrees of PR (RF $<20\%$) (Table 4). In our study, PRi of <0.8 and no flow time >64 msec showed the highest specificity and sensitivity among all tested measures in identifying more than mild PR and acted as the best independent predictors for severity of PR (Figure 1, 2 and Table 5).

Assessment of RV function: Compared to healthy controls, patients with TOF showed evidence of RV diastolic dysfunction; lower TV E/A ratio and significantly higher TV A wave velocity, lower TV annulus E' and higher TV E/E' ratio. TV annulus A' and S' wave velocities were significantly lower than normal. A significant difference in RVMPI was also found, with TOF patients having prolonged values than in controls (Table 6). A comparison between RV MPI and other measures obtained by TDI, revealed significant but moderate negative correlation between TV annulus S' and RV MPI ($r=-0.402$; $P=0.008$) in TOF patients (Figure 3). While determining an association between echocardiographic and CMR measurements of RV function, a significant moderate positive correlation between RVMPI and RV stroke volume (RVSV) ($r= 0.413$; $P=0.04$) was revealed (Figure 4). Neither TV annulus S' nor RV MPI showed significant correlation with

Variables	Values	
	patients	Healthy controls
Age at examination (years)	9.2 ± 4	9.2 ± 4
Gender	Males	12 (48%)
	Females	13 (52%)
BSA (m ²)	1.1 ± 0.3	1.2 ± 0.4
QRS duration (msec)	126.8 ± 19.8	120.8 ± 15.7
Age at surgery (years)	2.5 ± 1.9	
Time elapsed since surgery (years)	6.7 ± 3.5	
NYHA	I	20 (80%)
	II	5 (20%)
RBBB	13 (52%)	
Trans-annular patch	25 (100%)	
Previous palliative surgery (MBT shunt)	2 (8%)	

BSA: Body Surface Area; NYHA: New York Heart Association; RBBB: Right Bundle Branch Block; MBT: Modified Blalock Taussig. Data are reported as mean (\pm SD), or as number (%)

Table 1: Demographic and clinical characteristics of patients and healthy controls.

CMR regurgitant fraction	Patients (N=25)	Regurgitant fraction (%)
Mild ($<20\%$)	3 (12%)	13.3 ± 0.577
Moderate (20%-40%)	17 (68%)	26.6 ± 4.7
Severe ($>40\%$)	5 (20%)	44.6 ± 5

CMR: Cardiac Magnetic Resonance Imaging; PR: Pulmonary Regurge; N: Number. Data are expressed as mean (\pm SD) or number (%)

Table 2: CMR quantification of PR.

Measurements	Cases	Published references	P-value
RVEDV (ml)	108 ± 58	82.36 ± 44.7	$<0.001^*$
RVESV(ml)	50 ± 27	42.6 ± 31.69	0.004^*
RVSV (ml)	59.8 ± 33.29	49.76 ± 26.5	$<0.001^*$
RVEF%	$54\% \pm 5$	$53.9\% \pm 3$	0.918

CMR: Cardiac Magnetic Resonance Imaging; RVEDV: Right Ventricular End Diastolic Volume; RVESV: Right Ventricular End Systolic Volume; RVSV: Right Ventricular Stroke Volume; RVEF: Right Ventricular Ejection Fraction. Data are expressed as mean (\pm SD). * $P \leq 0.05$ is of significance

Table 3: CMR measurements of the right ventricle in comparison to published references [25,26].

Methods	Published Cut-off values	Sensitivity	Specificity	Diagnostic Accuracy
Jet width/ PA diameter	$>1/3$	95%	25%	88%
PHT	>100 msec	90.9%	0%	80%
PRi	<0.77	68%	100%	72%
NFT	>80 msec	68%	100%	72%
DSTVI	>49	70%	68%	64%

PA: Pulmonary Artery; PHT: Pressure Half Time; Pri: Pulmonary Regurge Index; NFT: No Flow Time; DSTVI: Diastole Systole Time Velocity Integral Ratio

Table 4: Assessment of echocardiographic measurements for detection of significant PR, based on published cut-off values [17-20].

RVEF ($r=0.239$; $P=0.249$, $r=0.215$; $P=0.324$ respectively). Patients with severe PR (RF derived from CMR $>40\%$) had higher RVMPI (0.56 ± 0.14 vs. 0.42 ± 0.11 ; $P= 0.587$), CMR derived RV EDV (184 ± 86.17 vs. 89.6 ± 28.64 ml; $P=0.697$) and RV SV (100 ± 54.4 vs. 49.76 ± 15.66 ml; $P= 0.107$) when compared to patients with less severe PR (RF derived from CMR $\leq 40\%$).

Discussion

Children who received surgical repair of TOF turn up in steadily increasing numbers, which makes their management a matter of daily

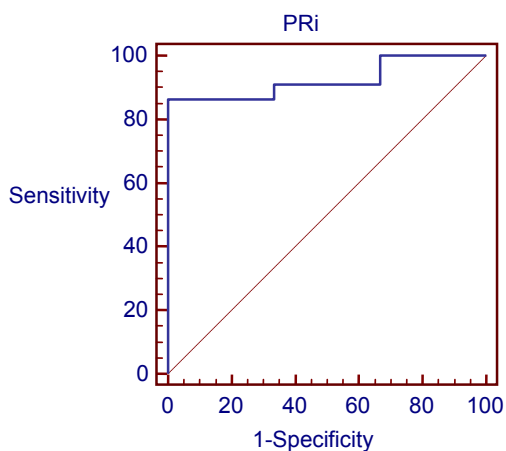


Figure 1: ROC curve analysis of PRi- Pulmonary regurge index. PRi is defined as the ratio between duration of PR and duration of diastole. Using CMR RF % as the gold standard, PRi showed an AUC of 0.924, sensitivity of 86.36% specificity of 100% at cut-off value of 0.8 (This is the cut-off value between mild and more than mild degrees of PR).

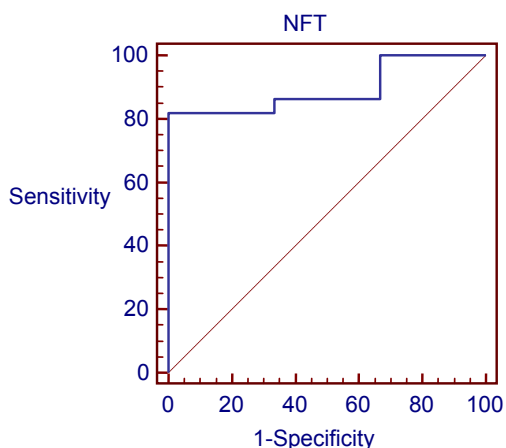


Figure 2: ROC curve analysis of NFT- no flow time. NFT is defined as the result of subtracting duration of PR from duration of diastole. Using CMR RF % as the gold standard, NFT showed an AUC of 0.894, sensitivity of 81% specificity of 100% at cut-off value of 64 (This is the cut-off value between mild and more than mild degrees of PR).

Methods	Suggested Cut-off values	Sensitivity	Specificity	AUC
Jet width/ PA diameter	>50%	59%	100%	0.635
PHT	>77 msec	27.7	100%	0.545
PRi	<0.8	86.36	100%	0.924
NFT	>64 msec	81%	100%	0.894
DSTVI	>0.71	95.4	66.6	0.705

AUC: Area Under The Curve; PA: Pulmonary Artery; PHT: Pressure Half Time; Pri: Pulmonary Regurge Index; NFT: No Flow Time; DSTVI: Diastole Systole Time Velocity Integral Ratio

Table 5: Assessment of echocardiographic measurements for detection of significant PR, based on suggested cut-off values.

concern rather than an occasional academic interest. Since long-term consequences and optimal timing for pulmonary valve replacement are incompletely defined specially in children, proper assessment

of PR and RV function remain a central point during follow ups, in order to suggest each patient's individual plan for interference [29,30]. Through the current study, we aimed at comparing accuracy of the easily obtained and readily available echocardiographic measurements for quantification of PR and RV function to CMR. While conducting

Measurements	Tetralogy of Fallot	Controls	P-value
TV E (cm/s)	77.8 ± 20.5	72.2 ± 8.1	0.293
TV A (cm/s)	52.4 ± 8.7	44.6 ± 5	0.002*
TV E/A	1.5 ± 0.4	1.6 ± 0.2	0.367
TV annulus S' (cm/s)	8.1 ± 2	12.5 ± 2.2	<0.001*
TV annulus E'(cm/s)	12.9 ± 2.9	16.4 ± 3.1	0.001*
TV annulus A'(cm/s)	6.5 ± 1.5	9.3 ± 2.4	<0.001*
TV E/A'	2.1 ± 0.5	1.8 ± 0.4	0.085
RV MPI	0.44 ± 0.11	0.33 ± 0.05	<0.001*
TV E/E'	6.3 ± 2.4	4.9 ± 1.6	0.046*

TV: Tricuspid Valve; E: Early Diastolic Filling; A: Late Diastolic Filling, S': Peak Systolic Velocity; E': Peak Velocity In Early Diastole; A': Peak Velocity In Late Diastole; MPI: Myocardial Performance Index

Data are expressed as mean (± SD). *P<0.05 is of significance

Table 6: Echocardiographic analysis of right ventricular functions in patients with tetralogy of Fallot versus healthy controls.

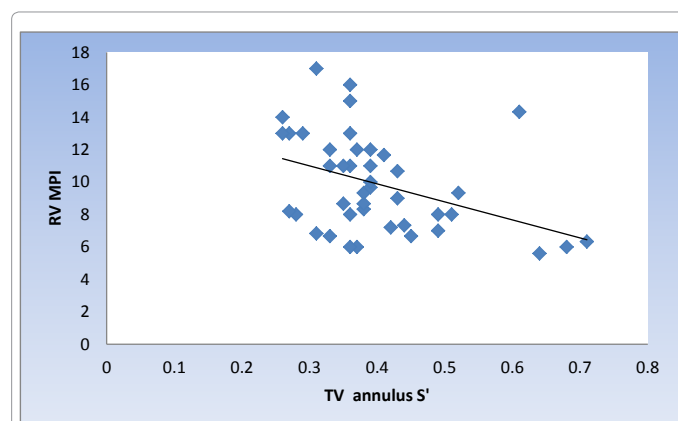


Figure 3: Scatter plot of RV MPI vs. TV annulus S'. Scatter diagram showing negative correlation between RV MPI and TV annulus S'. $r = -0.402$; $P = 0.008$. RV MPI: Right Ventricular Performance Index; TV: Tricuspid Valve; S': Peak Systolic Velocity.

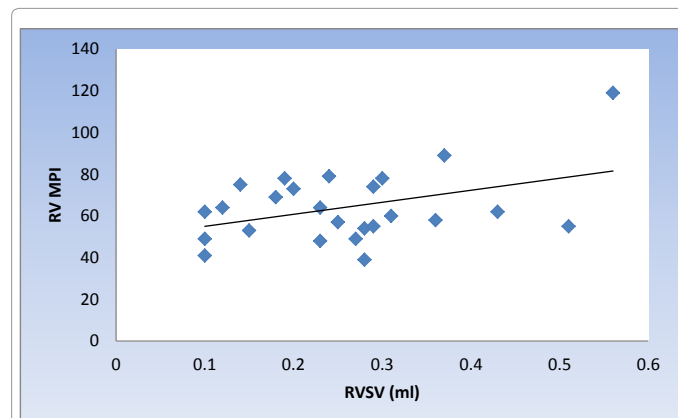


Figure 4: Scatter plot of RV MPI vs RVSV by CMR. Scatter diagram showing positive correlation between right RV MPI and RVSV by CMR. $r = 0.413$; $P = 0.04$. RV MPI: Right Ventricular Myocardial Performance Index; RVSV: Right Ventricular Stroke Volume.

our study in Egypt; one of the developing countries; we were aware of the fact that additional factors (other than PR and RV diastolic dysfunction) may contribute to mid and long-term outcome after TOF repair. These factors may include intra- and postoperative management problems (e.g. trans-annular instead of pulmonary valve sparing technique of surgery), delay in corrective surgery, and more frequent use of palliative surgery (aorto-pulmonary shunts).

Quantification and prediction of severity PR using conventional echocardiography

The present study reviewed 5 easily obtained echocardiographic indices for quantification of PR in comparison to the gold standard RF% obtained by CMR. Color Doppler flow mapping-A retrograde diastolic jet in the RVOT directed to the RV is diagnostic for PR [31]. Although regurgitant jet analysis (jet width, length and duration) has been validated for grading of aortic and mitral regurgitation, the clinical accuracy of this method for grading of PR especially in post TOF repair is not yet confirmed [19]. This may be due to the fact that these measures are dependent on combination of regurgitant volume and driving pressure (gradient between the pulmonary artery and the RV), which may result in wide variability and overlap between different degrees of PR [23]. In addition, the PR flow jet can be overestimated by swirling of blood in the RVOT, flow in a coronary fistula or flow in the left coronary artery which crosses just below the RVOT, accounting for false positive diagnosis. Also the poor acoustic windows in patients with previous operations may be particularly limiting echocardiographic interrogation of the region of the RV outflow tract. The present study revealed that jet width of more than one third the PV annulus diameter can be a useful method in identifying greater than mild degrees of PR (95% sensitive, 20 out of 25 patients, 95% CI: 93%-99%). Same method overestimated mild degrees of PR in 4 out of 5 patients (false positive rate of 80%, 95% CI: 18%-52%). For a better specificity, and based on ROC curve analysis, we suggested a higher cut off value (PR jet/PV annular diameter ratio of $\geq 50\%$) which showed 100% specificity and 60% sensitivity in identifying significant PR. This partially agreed with the results of recent study which recommended this type of measurement at the same cut off value ($\geq 50\%$) as a valuable grading tool for PR [32]. CW Doppler echocardiography-PR waves are frequently used to estimate the mean and the end-diastolic pulmonary pressure. However, there is no agreement on a clinically accepted method for quantifying pulmonary regurgitation using CW Doppler [19,33,34]. In our cohort CW Doppler PR flow pattern in patients with significant PR was characterized by short PHT, brief PR flow period and eventually longer no flow time in the second half of diastole. These results could be explained based on the fact that in severe PR, a rapid equalization of RV and pulmonary artery pressures can occur before the end of diastole. Thus, an intense signal with rapid deceleration rate and termination of flow in mid to late diastole can be seen [17,18]. The present study agreed with published results of many studies [17-19]. The CW Doppler derived measurements (PHT, no flow time and PRi) were all concordant with the results of CMR. Each was able to discriminate mild from more than mild degrees of PR, but with varying sensitivity and specificity. For an optimal accuracy we suggested a cut off value of 0.8 for PRi and 64 msec for PHT. Both methods were found to offer the highest specificity and sensitivity in identifying cases with hemodynamically significant PR, as well as the most reliable prediction for severity of PR. Although highly specific, PHT of <77 ms was found to be a poorly sensitive index (sensitivity 27%). This can be explained by its high dependence on dynamic pressure gradients and less dependence on total flow volume [17]. Meaning that situations when RV filling pressure rise more significantly than usual (as in restrictive

dysfunction), less regurgitant volumes develop and hence falsely lower PHT may be detected. In favor of this, our patients showed significantly increased E/E', indicating stiffer RV and a state of restrictive diastolic dysfunction.

Assessment of RV function

In our cohort, RV systolic and diastolic indices (TV annulus velocities and MPI) were impaired in TOF patients as compared to normal children. This happened even though our patients were asymptomatic, which shows that TDI could unmask silent RV dysfunction, even before RVEF on CMR was significantly impaired. Our results were similar to those obtained by a recent study where 32 patients after TOF repair at mean age of 6.4 years were evaluated. Patients showed significant decrease of myocardial tissue velocities (S' and A') of the RV than in healthy controls; (S' 8.6 ± 8.9 cm/sec, E' 10.9 ± 3.3 cm/sec and A' 5.9 ± 1.8 cm/sec) [3]. Another study also showed a remarkable decrease of the TV annular velocities in 137 patients who needed trans-annular patch repair of TOF [35,36]. In the current study, RVMPI among postoperative TOF patients was more prolonged than controls despite it is well known that among those groups the RV is restrictive in its diastolic function and the isovolumic relaxation time is shortened; a phenomenon previously described as pseudo-normalization [36,37]. Accordingly, we hypothesize that the observed RVMPI in our cohort may reflect a pure systolic dysfunction. In favor of this hypothesis speaks the observed correlation between the TV annular S' velocity and the RVMPI. On the other hand, CMR derived RVEF did not correlate to TDI. This may appear initially not expected. However one should remember that the right ventricular lateral free wall where the RVMPI is measured may be less affected compared to the outflow tract, where repaired TOF patients have a ventriculotomy scar or insertion of a non-contractile materials or trans-annular patch. Other possible explanation for the absence of significant correlation between the global right ventricular ejection fraction and the RVMPI is the after-load dependency of the ejection fraction. The MPI as shown by Tei et al., is comparatively after-load independent [38]. Unlike previous studies, our study failed to demonstrate correlation between RVMPI and severity of PR, which may suggest that the global RV dysfunction in our cohort can be attributed to other factors which were present since early periods after repair [36,39]. In spite of this, RVMPI was prolonged in patients with severe PR, near normal RVEF and greater than normal RVSV. The latter seems to reflect a compensatory mechanism for an already developed myocardial dysfunction, in order to maintain RVEF relatively normal at least during earlier postoperative periods. Thus, it appears that RVMPI can facilitate the diagnosis of RV dysfunction in clinically silent patients and even before affection of RVEF on CMR. It can hence provide an accurate tool to determine longer term prognosis in the setting of severe PR and good functional capacity.

Study limitations

Small sample size and short period of observation with no patient having a follow-up period longer than two decades make it likely that different predictors for RV dysfunction and severe PR may exist. Also, all our patients had prolonged RV MPI than normal, which reflected global RV dysfunction. However, we couldn't suggest the exact mechanism for dysfunction. We recommend analyzing each of the isovolumic Relaxation Time (IRT), isovolumic Contraction Time (ICT) and Ejection Time (ET) individually and in correlation with CMR measurements, through further longitudinal studies.

Conclusion

Conventional echocardiography can offer a simple, readily available

and accurate tool for quantification of pulmonary regurge and right ventricular function during mid- term follow up after surgical repair of tetralogy of Fallot.

References

1. Ho KW, Tan RS, Wong KY, Tan TH, Shankar S, et al. (2007) Late complications following tetralogy of Fallot repair: the need for long-term follow-up. *Ann Acad Med Singapore* 36: 947-953.
2. Rao SG (2007) Pediatric cardiac surgery in developing countries. *Pediatr Cardiol* 28: 144-148.
3. Tanasan A, Zanjani KS, Kocharian A, Kiani A, Navabi MA. (2012) Right ventricular myocardial tissue velocities, myocardial performance index, and tricuspid annular plane systolic excursion in totally corrected tetralogy of fallot patients. *J Tehran Heart Cent*: 4: 160-163
4. Nørgaard MA, Lauridsen P, Helvind M, Pettersson G (1999) Twenty-to-thirty-seven-year follow-up after repair for Tetralogy of Fallot. *Eur J Cardiothorac Surg* 16: 125-130.
5. Roos-Hesselink J, Perloth MG, McGhie J, Spitaels S (1995) Atrial arrhythmias in adults after repair of tetralogy of Fallot. Correlations with clinical, exercise, and echocardiographic findings. *Circulation* 91: 2214-2219.
6. Gatzoulis MA, Balaji S, Webber SA, Siu SC, Hokanson JS, et al. (2000) Risk factors for arrhythmia and sudden cardiac death late after repair of tetralogy of Fallot: a multicentre study. *Lancet* 356: 975-981.
7. Eyskens B, Reybrouck T, Bogaert J, Dymarkowsky S, Daenen W, et al. (2000) Homograft insertion for pulmonary regurgitation after repair of tetralogy of fallot improves cardiorespiratory exercise performance. *Am J Cardiol* 85: 221-225.
8. Discigil B, Dearani JA, Puga FJ, Schaff HV, Hagler DJ, et al. (2001) Late pulmonary valve replacement after repair of tetralogy of Fallot. *J Thorac Cardiovasc Surg* 121: 344-351.
9. Lotz J, Meier C, Leppert A, Galanski M (2002) Cardiovascular flow measurement with phase-contrast MR imaging: basic facts and implementation. *Radiographics* 22: 651-671.
10. Rebergen SA, van der Wall EE, Doornbos J, de Roos A (1993) Magnetic resonance measurement of velocity and flow: technique, validation, and cardiovascular applications. *Am Heart J* 126: 1439-1456.
11. Grothoff M, Spors B, Abdoul-Khalik H, Gutberlet M. (2008) Evaluation of postoperative pulmonary regurgitation after surgical repair of tetralogy of Fallot: comparison between Doppler echocardiography and MR velocity mapping. *Pediatr Radiol*. 38: 186-191.
12. Krishna Kumar Mohanan Nair, Sanjay Ganapathi, Bijulal Sasidharan, Anees Thajudeen, et al. (2013) Asymptomatic right ventricular dysfunction in surgically repaired adult tetralogy of Fallot patients. *Ann Pediatr Cardiol*. 6: 24-28.
13. Meluzin J, Spinarova L, Bakala J, Toman J, Krejci J, et al. (2001) Pulsed Doppler tissue imaging of the velocity of tricuspid annular systolic motion; a new, rapid, and non-invasive method of evaluating right ventricular systolic function. *Eur Heart J*. 22: 340-348.
14. Schwerzmann M, Samman AM, Salehian O, Holm J, Provost Y, et al. (2007) Comparison of echocardiographic and cardiac magnetic resonance imaging for assessing right ventricular function in adults with repaired tetralogy of fallot. *Am J Cardiol* 99: 1593-1597.
15. Van der Zwaan HB, Helbing WA, Boersma E, Geleijnse ML, McGhie JS, et al. (2010) Usefulness of real time three-dimensional echocardiography to identify right ventricular dysfunction in patients with congenital heart disease. *Am J Cardiol*. 106: 843-850.
16. Grewal J, Majdalany D, Syed I, Pellikka P, Warnes CA (2010) Three-dimensional echocardiographic assessment of right ventricular volume and function in adult patients with congenital heart disease: comparison with magnetic resonance imaging. *J Am Soc Echocardiogr*. 23: 127-133
17. Silversides CK, Veldtman GR, Crossin J, Merchant N, Webb GD, et al. (2003) Pressure half-time predicts hemodynamically significant pulmonary regurgitation in adult patients with repaired tetralogy of Fallot. *J Am Soc Echocardiogr*. 16: 1057-1062.
18. Li W, Davlouros PA, Kilner PJ, Pennell DJ, Gibson D, et al. (2004) Doppler-echocardiographic assessment of pulmonary regurgitation in adults with repaired tetralogy of Fallot: comparison with cardiovascular magnetic resonance imaging. *Am Heart J*. 147: 165-172.
19. Yang H, Pu M, Chambers CE, Weber HS, Myers JL, et al. (2008) Quantitative assessment of pulmonary insufficiency by Doppler echocardiography in patients with adult congenital heart disease. *J Am Soc Echocardiogr* 21: 157-164.
20. Mercer-Rosa L, Yang W, Kutty S, Rychik J, Fogel M, et al. (2012) Quantifying pulmonary regurgitation and right ventricular function in surgically repaired tetralogy of Fallot: a comparative analysis of echocardiography and magnetic resonance imaging. *Circ Cardiovasc Imaging* 5: 637-643.
21. Jaffe WM, Dewhurst TA, Otto CM, Pearlman AS (1991) Influence of Doppler sample volume location on ventricular filling velocities. *Am J Cardiol* 68: 550-552.
22. O'Leary PW, Durongpisitkul K, Cordes T (1998) Diastolic ventricular function in children: A Doppler Echocardiographic study establishing normal values and predictors of increased ventricular end-diastolic pressure. *Mayo Clin Proc*. 73: 616-628.
23. Zoghbi WA, Enriquez-Sarano M, Foster E, Grayburn PA, Kraft CD, et al. (2003) Recommendations for evaluation of the severity of native valvular regurgitation with two-dimensional and Doppler echocardiography. *J Am Soc Echocardiogr* 16: 777-802.
24. Fratz S, Schuhbaeck A, Buchner C, Busch R, Meierhofer C, et al. (2009) Comparison of accuracy of axial slices versus short-axis slices for measuring ventricular volumes by cardiac magnetic resonance in patients with corrected tetralogy of fallot. *Am J Cardiol* 103: 1764-1769.
25. Sarikouch S, Peters B, Gutberlet M, Leismann B, Kelter-Kloeping A, et al. (2010) Sex-specific pediatric percentiles for ventricular size and mass as reference values for cardiac MRI: assessment by steady-state free-precession and phase-contrast MRI flow. *Circ Cardiovasc Imaging* 3: 65-76.
26. Robbers-Visser D, Boersma E, Helbing WA (2009) Normal biventricular function, volumes, and mass in children aged 8 to 17 years. *J Magn Reson Imaging* 29: 552-559.
27. Weber OM, Higgins CB (2006) MR evaluation of cardiovascular physiology in congenital heart disease: flow and function. *J Cardiovasc Magn Reson* 8: 607-617.
28. Oosterhof T, Mulder BJ, Vliegen HW, de Roos A (2006) Cardiovascular magnetic resonance in the follow-up of patients with corrected tetralogy of Fallot: a review. *Am Heart J* 151: 265-272.
29. Tekten T, Onbasili AO, Ceyhan C, Unal S, Discigil B (2003) Novel approach to measure myocardial performance index: pulsed-wave tissue Doppler echocardiography. *Echocardiography* 20: 503-510.
30. Knauth AL, Gauvreau K, Powell AJ, Landzberg MJ, Walsh EP, et al. (2008) Ventricular size and function assessed by cardiac MRI predict major adverse clinical outcomes late after tetralogy of Fallot repair. *Heart* 94: 211-216.
31. Oosterhof T, van Straten A, Vliegen HW, Meijboom FJ, van Dijk AP, et al. (2007) Preoperative thresholds for pulmonary valve replacement in patients with corrected tetralogy of Fallot using cardiovascular magnetic resonance. *Circulation* 116: 545-551.
32. Renella P, Aboulhosn J, Lohan DG, Jonnala P, Finn JP, et al. (2010) Two-dimensional and Doppler echocardiography reliably predict severe pulmonary regurgitation as quantified by cardiac magnetic resonance. *J Am Soc Echocardiogr* 23: 880-886.
33. Lei MH, Chen JJ, Ko YL, Cheng JJ, Kuan P, et al. (1995) Reappraisal of quantitative evaluation of pulmonary regurgitation and estimation of pulmonary artery pressure by continuous wave Doppler echocardiography. *Cardiology* 86: 249-256.
34. Ensing G, Seward J, Darragh R, Caldwell R (1994) Feasibility of generating hemodynamic pressure curves from noninvasive Doppler echocardiographic signals. *J Am Coll Cardiol* 23: 434-442.
35. Nair KK, Ganapathi S, Sasidharan B, Thajudeen A, Pillai HS, et al. (2013) Asymptomatic right ventricular dysfunction in surgically repaired adult tetralogy of fallot patients. *Ann Pediatr Cardiol* 6: 24-28.
36. Abd El Rahman MY, Abdoul-Khalik H, Vogel M, Alexi-Meskischvili V, Gutberlet M, et al. (2002) Value of the new Doppler-derived myocardial performance index for the evaluation of right and left ventricular function following repair of tetralogy of fallot. *Pediatr Cardiol* 23: 502-507.
37. Yasuoka K, Harada K, Toyono M, Tamura M, Yamamoto F (2004) Tei index determined by tissue Doppler imaging in patients with pulmonary regurgitation after repair of tetralogy of Fallot. *Pediatr Cardiol* 25: 131-136.

38. Tei C, Nishimura RA, Seward JB, Tajik AJ (1997) Noninvasive Doppler-derived myocardial performance index: correlation with simultaneous measurements of cardiac catheterization measurements. J Am Soc Echocardiogr 2: 169-178.
39. Frigiola A, Redington AN, Cullen S, Vogel M (2004) Pulmonary regurgitation is an important determinant of right ventricular contractile dysfunction in patients with surgically repaired tetralogy of Fallot. Circulation 110: 153-157.

Citation: Agha H, Aly DM, Moustafa FA, Kharabish A, Kamal YH, et al. (2014) Prediction of Pulmonary Regurge and Right Ventricular Function in Asymptomatic Repaired Tetralogy of Fallot Patients in Developing Countries: A Comparison to Cardiac Magnetic Resonance Imaging. J Clin Exp Cardiol 5: 316. doi:[10.4172/2155-9880.1000316](https://doi.org/10.4172/2155-9880.1000316)

Submit your next manuscript and get advantages of OMICS Group submissions

Unique features:

- User friendly/feasible website-translation of your paper to 50 world's leading languages
- Audio Version of published paper
- Digital articles to share and explore

Special features:

- 350 Open Access Journals
- 30,000 editorial team
- 21 days rapid review process
- Quality and quick editorial, review and publication processing
- Indexing at PubMed (partial), Scopus, EBSCO, Index Copernicus and Google Scholar etc
- Sharing Option: Social Networking Enabled
- Authors, Reviewers and Editors rewarded with online Scientific Credits
- Better discount for your subsequent articles

Submit your manuscript at: www.editorialmanager.com/clinicalgroup

