

Phacoviscocanalostomy in pseudoexfoliation glaucoma versus primary open-angle glaucoma

Mohamed A. Awadalla,* MD, FRCSEd; Khaled M. Hassan,† FRCSEd

ABSTRACT • RÉSUMÉ

Objective: To compare the outcome of phacoviscocanalostomy in pseudoexfoliation glaucoma (PEXG) versus that in primary open-angle glaucoma (POAG).

Design: Prospective comparative study.

Participants: Sixty eyes of 60 patients who underwent phacoviscocanalostomy for cataract and medically uncontrolled PEXG (30 eyes) or POAG (30 eyes).

Methods: Success rate was based on intraocular pressure (IOP) reduction and need for antiglaucoma medication. Visual acuity (VA) and complication rates were secondary outcomes.

Results: The mean follow-up was 19.7 months (range, 12–36 months). The mean IOP values in both groups were significantly less than the preoperative values at all postoperative intervals ($p < 0.001$). From 1 month onward, the decrease in IOP was more dramatic in PEXG eyes than in POAG eyes ($p < 0.05$). At last visit, the mean percentage of IOP reduction was 49.7% in the PEXG group and 30.9% in the POAG group. All study eyes required decreased antiglaucoma medications and showed improved VA postoperatively. Transient complications included Descemet's membrane microperforations, macroperforation, zonular dehiscence, and postoperative IOP spike. No eyes developed trabeculectomy-type bleb, hyphema, fibrin exudation, or bleb-related complications.

Conclusions: Phacoviscocanalostomy achieved excellent IOP control and VA improvement in both PEXG and POAG groups. PEXG demonstrated greater IOP reduction and fewer postoperative medications than POAG. The complication rate was low and did not affect surgical outcome. Phacoviscocanalostomy can be an effective and safe surgical alternative to phacotrabeulectomy in both groups of patients.

Objet : Comparaison entre les résultats de la phacoviscocanalostomie du glaucome capsulaire avec pseudoexfoliation (GCPE) et du glaucome primaire à angle ouvert (GPAO).

Nature : Étude prospective comparative.

Participants : Soixante yeux de 60 patients ayant subi une phacoviscocanalostomie pour la cataracte avec GCPE (30 yeux) ou GPAO (30 yeux) non contrôlé médicalement.

Méthodes : Le taux de réussite reposait sur la réduction de la pression intraoculaire (PIO) et le besoin de médicament antiglaucome. L'acuité visuelle (AV) et les taux de complication de étaient des résultats secondaires.

Résultats : Le suivi a été de 19,7 mois en moyenne (écart 12–36 mois). Dans les deux groupes, la PIO était en moyenne significativement inférieure à la valeur préopératoire à tous les intervalles ($p < 0,001$). À partir du premier mois, la baisse de PIO était plus remarquable dans les yeux avec GCPE que ceux avec GPAO ($p < 0,05$). À la dernière visite, la réduction du pourcentage moyen de PIO était de 49,7 % dans le groupe GCPE et de 30,9 % dans le groupe GPAO. Dans tous les cas, les yeux ont demandé une réduction des médicaments antiglaucome et montré une amélioration postopératoire de l'AV. Les complications transitoires comprenaient des microperforations et des macroperforations de la membrane de Descemet, une déhiscence zonulaire et une pointe de PIO postopératoire. Aucun œil n'a développé de bulle de type trabéulectomie, d'exsudation de fibrine ou de complications associées à la bulle.

Conclusions : La phacoviscocanalostomie a donné un excellent contrôle de la PIO et une amélioration de l'AV dans les deux groupes, GCPE et GPAO. Le GCPE a présenté une réduction plus prononcée de la PIO et moins de médicaments postopératoires que le GPAO. Le taux de complication était faible et n'a pas affecté le résultat de la chirurgie. La phacoviscocanalostomie peut présenter une alternative efficace et sécuritaire à la phaco-trabéulectomie chez les deux groupes de patients.

Viscocanalostomy, a nonpenetrating glaucoma surgery described by Stegmann et al.,¹ consists of deroofting Schlemm's canal, creating a Descemet's "window," and injecting a high-molecular-weight viscoelastic material into the ostia. Phacoemulsification combined with viscocanalostomy effectively reduces intraocular pressure (IOP), and has a high safety profile in cataractous eyes with medically uncontrolled primary open-angle glaucoma (POAG).^{2–7} Phacoviscocanalostomy represents an attractive alternative to standard phacotrabeulectomy with antimetabolites. The use of antimetabolites is associated with a significant increase in the risk for vision-threatening complications of trabeculectomy as bleb leaks, hypotony, choroidal detachment, and endophthalmitis.⁶

Pseudoexfoliation (PEX) syndrome, first characterized by Lindberg,⁸ features progressive deposition of abnormal fibrillar material in intraocular and systemic tissues.⁹ PEX is the most common identifiable condition causing open-angle glaucoma.¹⁰ Pseudoexfoliation glaucoma (PEXG) tends to run a more aggressive clinical course than POAG and tends to require earlier surgery.^{11,12} In addition to being a risk factor for glaucoma, there has been increasing evidence for an etiological association of PEX with cataract formation.^{13,14}

Previously we reported that phacoviscocanalostomy effectively lowers IOP and improves visual acuity (VA) in patients having PEXG and cataract.¹⁵ The aim of this study was to compare the surgical outcome and complications of phacoviscocanalostomy in PEXG versus POAG.

From the *Ophthalmology Department, Cairo University, Cairo, Egypt; and the †Magrabi Eye Center, Riyadh, Saudi Arabia

Correspondence to Mohamed A. Awadalla, MD, 18C, 198 St, Maadi, Apt 13, Giza, Egypt; awadalla_mo@yahoo.com

Originally received Dec. 13, 2009. Final revision Apr. 8, 2010

Accepted May 11, 2010

Available online Jan. 31, 2011

Can J Ophthalmol 2011;46:77–82

doi:10.3129/i10-076

METHODS

This prospective interventional study included 60 consecutive eyes of 60 patients with medically uncontrolled PEXG (30 eyes) or POAG (30 eyes) in association with cataract. Ethical approval was obtained from the Research Ethics Committee (Maghrabi Eye Center, Riyadh, Saudi Arabia) and the tenets of the Declaration of Helsinki were followed. Informed written consent was obtained from all participants.

Inclusion criteria were patients with visually significant cataract in addition to uncontrolled PEXG or POAG. Visually significant cataract was defined as a cataract of sufficient density to lead to a VA \leq 0.6 (20/30) and that adversely affects the patient's daily activities. Uncontrolled PEXG or POAG was indicated for surgery for 1 or more of the following reasons IOP $>$ 21 mm Hg despite maximally tolerated medical therapy or IOP \leq 21 mm Hg under medical therapy with poor patient compliance, medication intolerance, or inability to achieve target IOP (i.e., pressure levels which limit or halt visual field [VF] progression).

Exclusion criteria were patients with other types of glaucoma, any other form of ocular disease, or previous ocular surgery. PEX patients with angle-closure glaucoma, occludable angles, peripheral iridectomies, or previous laser trabeculoplasty were also excluded.

A full history and complete ocular assessment were done preoperatively; all patients underwent uncorrected visual acuity (UCVA) and best-corrected VA (BCVA), Goldmann applanation tonometry, gonioscopy, slit-lamp biomicroscopy, and indirect ophthalmoscopy. All participants had an automated VF assessment, dated at least 3 months before surgery, using the Humphrey Visual Field Analyzer 24-2 program (Carl Zeiss Ophthalmic Systems Inc, Dublin, Calif.).

After surgery the same examinations, except for VF and gonioscopy, were performed at 1 day, 1 week, 4 weeks, 3 months, 6 months, and 1 year. Thereafter, examinations were at 3-month intervals. VF examination and gonioscopy were repeated every 3 months. IOP measurement was performed by a separate ophthalmologist blinded to the procedure to reduce bias in IOP recording. VA was converted to decimal values before statistical analysis.

Phacoviscocanalostomy was performed, under peribulbar anaesthesia, by a single surgeon (K.M.H.) to avoid potential bias among multiple surgeons. In all cases, no antifibrotic agents were used.

Standard phacoemulsification through a temporal 3 mm clear corneal incision with implantation of a foldable acrylic intraocular lens (IOL) was completed first. A capsular tension ring was used prior to IOL implantation in PEX eyes that had unstable capsular bags. Next, the surgeon shifted his position from temporal to superior in preparation for the viscocanalostomy using a method similar to that described by Stegmann et al.¹ A triangular superficial scleral flap, 4 mm wide and 5 mm long, was dissected up to 2 mm into clear cornea. A second deeper scleral flap was fashioned

0.5 mm inside the margins of the superficial flap just above the level of the choroid. With forward dissection of this flap, Schlemm's canal could be identified approximately 1.0 mm posterior to the limbus and deroofed, where the glistening floor and the mild blood ooze from its ostia marked it. Using a dry cellulose sponge, Descemet's membrane was detached from the overlying corneal stroma by applying gentle pressure on Schwalbe's line to create an intact Descemet's "window," at least 1.00 mm wide and 3.00 mm long. The deep flap was then excised using Vannas scissors. Sodium hyaluronate 1% (Provisc, Alcon, Fort Worth, Tex.) was injected into the open ostia of Schlemm's canal. The superficial scleral flap was tightly sutured in place using 3 interrupted 10/0 nylon sutures. The resulting intrascleral "lake" was filled with sodium hyaluronate 1% to avoid fibrinous activity and scarring in the early postoperative period. The conjunctiva was approximated by 8/0 vicryl sutures.

Postoperative management included a tapered schedule of steroid (prednisolone acetate 1%) and antibiotic (ofloxacin 0.3%). Preoperative glaucoma medications were stopped after surgery. During follow-up, if target IOP was not achieved by the surgical procedure, glaucoma medication was restarted.

The postoperative IOP was the primary outcome measure. In accordance with the international consensus statements on success criteria for glaucoma surgery, success rates for IOP of \leq 21 mm Hg and IOP of \leq 15 mm Hg were reported and compared. Complete success was defined as an IOP of \leq 21 mm Hg and an IOP of \leq 15 mm Hg achieved without additional glaucoma medication; qualified success was applied for the same IOP limitation but with or without medication. Failure was defined as IOP $>$ 21 mm Hg with or without medication or when an eye required further glaucoma drainage surgery. Recorded secondary outcomes included VA and postoperative complication rates.

A sample size of 60 eyes (30 in each group) was chosen to achieve a power of 97% in detecting a 3 mm Hg IOP difference, assuming a standard deviation (SD) of 3 mm Hg and a 2-sided type 1 error of 0.05. Descriptive statistics were calculated as the mean \pm SD. Student's *t* tests were used to compare continuous variables. Dichotomous variables were compared using the χ^2 and Fisher exact tests. A *p* value of $<$ 0.05 was considered statistically significant. Kaplan–Meier survival curves were constructed to analyze the long-term success rate. Analyses were performed using the Software Package for the Statistical Sciences 10.1 (SPSS Inc, Chicago, Ill.)

RESULTS

Table 1 shows the demographics and preoperative characteristics of the enrolled patients. Age was the only preoperative criterion that demonstrated a statistically significant difference ($p <$ 0.05) with a higher mean age in the PEXG group than in the POAG group.

All patients completed at least 12 months of follow-up. The follow-up time was comparable in both groups (Table 1), with an average of 19.7 months (range, 12–36 months).

In both groups, the procedure resulted in an immediate and statistically significant decrease of mean IOP from its preoperative value ($p < 0.001$). This was maintained at all time points until the last follow-up (Fig. 1).

Mean IOP was significantly lower in the PEXG group than in the POAG group at 1, 3, 6, and 12 months ($p < 0.01$). This trend continued until the last follow-up (see Appendix 1, available online).

At the last follow-up visit, mean IOP reduction was 12.2 mm Hg (49.7%) in the PEXG group and 6.7 mm Hg (30.9%) in the POAG group.

Two patients (6.6%) in the PEXG group required anti-glaucomatous medication to achieve target IOP. The number of antiglaucomatous medications required decreased from a mean preoperative level of 2.6 ± 0.72 (range, 1–4) to 0.1 ± 0.4 (range, 0–2) at final follow-up ($p < 0.001$).

In comparison, 5 patients (16.6%) in the POAG group required anti-glaucomatous agents to achieve IOP control. The number of medications required declined from a mean preoperative level of 2.3 ± 0.79 (range, 1–3) to 0.20 ± 0.48 (range, 0–2) at last follow-up ($p < 0.001$).

Comparing the postoperative need for glaucoma eye drops in study groups was not statistically significant ($p = 0.26$).

At the last visit, a complete surgical success at IOP criterion of ≤ 21 mm Hg was achieved in 93.3% (28 eyes) of the PEXG group and in 83.3% (25 eyes) in the POAG group ($p > 0.05$). Comparing both groups at a lower cut-off IOP level (≤ 15 mm Hg), the PEXG group scored a significantly higher percentage of success. At the last follow-up, 25 eyes (83.3%) in the PEXG group achieved an IOP ≤ 15 mm Hg without antiglaucoma medication, compared with 16 eyes (53.3%) in the POAG group ($p < 0.05$).

A qualified success was achieved in all eyes (100%) in both study groups ($p > 0.05$). In Figures 2 and 3, a Kaplan–Meier survival curve compares the cumulative probability

of complete success of both groups at both IOP cut-off levels. A stable level of surgical success was maintained during the different follow-up periods. No eyes required goniotomy or further glaucoma surgery.

All patients had a significant postoperative improvement in VA. For the PEXG group, the mean postoperative UCVA and BCVA were 0.52 ± 0.25 and 0.76 ± 0.26 , respectively. The POAG group had a mean postoperative UCVA and BCVA of 0.50 ± 0.28 and 0.74 ± 0.25 , respectively. The change in both postoperative UCVA and BCVA was statistically significant ($p < 0.005$) at all follow-up intervals compared with their preoperative levels in both groups.

Complications encountered in the study are detailed in Table 2. Overall, the frequency of complications was comparable in both groups ($p > 0.05$). However, zonular dehiscence was reported only in the PEXG group. Eyes that sustained macroporation of the trabeculo-Descemet's window with iris prolapse were managed either by viscoelastic-aided iris reposition through the perforation site (3 eyes) or, if difficult, by iridectomy (2 eyes). No cases required conversion to either extracapsular cataract extraction or trabeculectomy.

Transient postoperative IOP spike was the only complication reported in both groups. There were no postoperative hyphema, fibrin deposition, or excessive iritis in either group. No eyes developed shallowing of the anterior chamber, hypotony (IOP < 5 mm Hg), choroidal detachment, or endophthalmitis.

DISCUSSION

Viscocanalostomy is a nonpenetrating glaucoma surgery that has the potential to significantly reduce complications associated with trabeculectomy.^{1–7} PEXG patients are more susceptible to trabeculectomy-related surgical complications due to the characteristic pathological changes of the disease.¹⁶ Iris vasculopathy, with consequent blood-aqueous barrier impairment, carries a greater risk of postoperative fibrin exudation and pupillary membrane formation.¹⁷

Table 1—Demographic data and characteristics of the study groups

Characteristic	PEXG (n = 30)	POAG (n = 30)	p value
Mean age (years) \pm SD	70.7 \pm 9.5	58.6 \pm 9.6	0.001*
Sex (male:female)	20:10	15:15	0.19
Antiglaucoma medications (n)			
Single topical	3	6	—
Double topical	6	9	—
Triple topical	20	15	—
> 3 topical	1	0	—
Oral CAI	0	0	—
Mean preoperative glaucoma medications \pm SD	2.6 \pm 0.72	2.3 \pm 0.79	0.11
Mean preoperative IOP (mm Hg) \pm SD	24.5 \pm 6.7	21.7 \pm 7.0	0.13
Mean preoperative BCVA \pm SD [†]	0.27 \pm 0.21	0.25 \pm 0.20	0.66
Mean follow up (months) \pm SD (range)	19.6 \pm 6.6 (12–36)	19.8 \pm 7.5 (12–36)	0.90

*Statistically significant difference ($p < 0.05$).

[†]Visual acuity stated in decimal values.

Note: PEXG, pseudoexfoliation glaucoma; POAG, primary open-angle glaucoma; SD, standard deviation; CAI, carbonic anhydrase inhibitor; IOP, intraocular pressure; BCVA, best-corrected visual acuity.

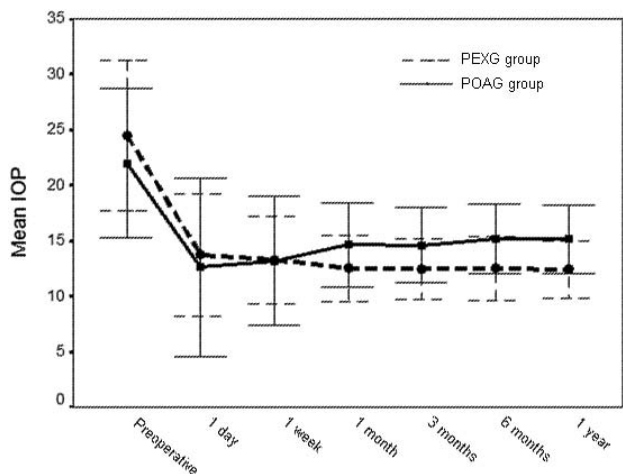


Fig. 1—Mean intraocular pressure (IOP) ± standard deviation with time. (PEXG, pseudoexfoliation glaucoma; POAG, primary open-angle glaucoma.)

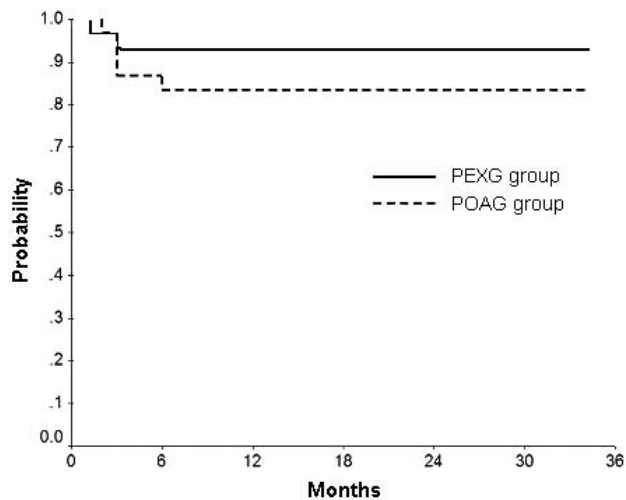


Fig. 2—Kaplan–Meier survival curve of complete success (IOP ≤ 21 mm Hg without medication). (PEXG, pseudoexfoliation glaucoma; POAG, primary open-angle glaucoma.)

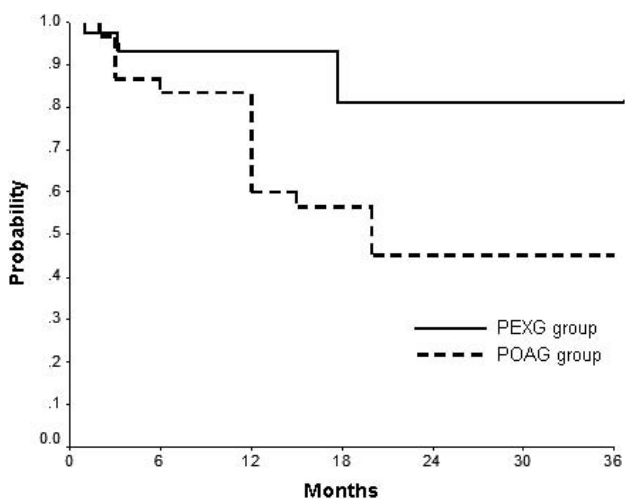


Fig. 3—Kaplan–Meier survival curve of complete success (IOP ≤ 15 mm Hg without medication). (PEXG, pseudoexfoliation glaucoma; POAG, primary open-angle glaucoma.)

Undetected iris microneovascularization may lead to intraoperative or delayed hyphema from the iridectomy and may contribute to the eventual failure of trabeculectomy.^{18,19} In addition, the markedly elevated preoperative IOP in PEXG eyes may predispose patients to post-trabeculectomy choroidal hemorrhage or effusion.¹⁰ Therefore, reducing iris manipulation and avoiding peripheral iridectomy and direct penetration into the anterior chamber make viscocanalostomy particularly advantageous in PEXG patients.

In this study, PEXG eyes demonstrated a statistically significant mean IOP reduction from the first postoperative month onward. In addition, the PEXG group achieved significantly better results at the lower IOP cut-off level (IOP ≤ 15 mm Hg). This reflects greater pressure-lowering efficacy of the phacoviscocanalostomy in PEXG patients. To our knowledge, there are no previously published reports comparing the surgical outcome of phacoviscocanalostomy in PEXG with that in POAG. However, the success rate of phacoviscocanalostomy in this study was comparable to other published data of the same procedure in POAG (see Appendix 2, available online). Some of those reports included PEXG as a subgroup within POAG.^{4,6}

A literature review revealed that penetrating glaucoma procedures in PEXG achieve a success rate that is comparable to, or even better than in POAG.^{12,20–22} However, 1 study reported a worse long-term outcome of trabeculectomy in PEXG patients.²³ The same trend seems to apply when reviewing the results of different nonpenetrating glaucoma procedures in PEXG such as deep sclerectomy^{24,25} and phacotrabeculectomy.^{26,27}

Microperforation of the TDW was found to be the most common viscocanalostomy-related complication encountered in our study, which agrees with previous reports.^{1–7} This complication did not affect the surgical outcome in any of the involved eyes. Microperforations may occur even with skilled surgeons; they appear to be unrelated to the learning curve and may be correlated to the individual anatomical characteristics of the eye. Phacoemulsification-related complications were comparable to those obtained in previous studies of phacoemulsification in PEX eyes.^{28,29}

No severe or vision-threatening complications were encountered in either group in the study. This represents a high index of safety with phacoviscocanalostomy,

	PEXG (n = 30) (%)	POAG (n = 30) (%)	p value
Intraoperative			
Zonular dehiscence ± vitreous loss	2 (6.6)	0	0.49
Microperforation of Descemet	6 (20)	4 (13.3)	0.73
Macroperforation ± iridotomy	2 (6.6)	3 (10)	1.00
Postoperative:			
Transient IOP spike (> 25 mm Hg)	1 (3.3)	2 (6.6)	0.99

especially in the inherently higher-risk PEXG eyes. However, viscocanalostomy is a procedure that has a steep learning curve and the surgical outcome may reflect the experience of the operating surgeon.

Most authors believe that aqueous drainage in viscocanalostomy occurs via enhanced uveoscleral outflow and (or) through Schlemm's canal. Therefore, the use of antimetabolites to improve filtration success is uncommon in viscocanalostomy; this may reduce the need for antimetabolites and their attending drawbacks. O'Brart et al.³⁰ however, proposed that the subconjunctival route of drainage plays a major role as evidenced by the presence of conjunctival epithelial microcysts and drainage blebs in eyes with successful postviscocanalostomy drainage. Accordingly, they theorized that antimetabolites might improve the results of viscocanalostomy. Although the current study achieved a good surgical outcome without the adjunctive use of antimetabolites, their potential to further improve success of phacoviscocanalostomy warrants further investigation.

Several studies have reported IOP decrease following phacoemulsification in patients without pre-existing ocular disease and in those with an elevated preoperative IOP.^{31–34} One study³⁵ found that patients with PEXG and a normal preoperative IOP had a significantly greater drop in postoperative IOP than similarly matched patients without the syndrome. Another study³⁶ found that PEXG patients experience a significantly greater drop in IOP after phacoemulsification than POAG patients and cataract control groups. Recently, Shingleton et al.³⁷ demonstrated that IOP reduction following phacoemulsification occurs in PEX eyes with or without glaucoma and is proportional to the preoperative IOP; higher preoperative IOP was associated with a greater reduction in IOP. Phacoemulsification might remove a source of pseudoexfoliative material (the anterior lens capsule) and result in, or stimulate clearance of, pseudoexfoliative and pigment debris from the anterior segment, in particular the trabecular meshwork.³⁶ In addition, removal of a cataractous lens increases anterior chamber depth, thus reducing crowding of the anterior segment.³⁴ In phacoviscocanalostomy, these factors could influence the outflow mechanism by allowing better access of aqueous to the TDW and through the trabecular meshwork to Schlemm's canal.⁶ Consequently, we think that a better understanding of the behaviour of viscocanalostomy in PEXG compared with that in POAG would be achieved by doing the procedure in patients who do not need cataract removal.

Other limitations of this study are nonrandomization and the middle-term time span. Another randomized study of longer follow-up may be necessary to confirm our results. Also in view of the claim that phacoviscocanalostomy has the potential to be a good alternative to the gold standard, phacotrabeculectomy, in PEXG patients, it seems prudent to directly compare both procedures in future research.

Online-only material: This article includes online-only material. Appendices 1 and 2 can be found on the *CJO* web site at <http://pubs.nrc-cnrc.gc.ca/cjo/cjo.html>. It is linked to this article in the online contents of the February 2011 issue.

Disclosure: The authors have no proprietary or commercial interest in any materials discussed in this article.

REFERENCES

1. Stegmann R, Pienaar A, Miller D. Viscocanalostomy for open-angle glaucoma in black African patients. *J Cataract Refract Surg.* 1999; 25:316–22.
2. Gimbel HV, Penno EE, Ferenowicz M. Combined cataract surgery, intraocular lens implantation, and viscocanalostomy. *J Cataract Refract Surg.* 1999;25:1370–5.
3. Uretmen O, Ates H, Guven S, Andaç K. Comparison of outcomes of viscocanalostomy and phacoviscocanalostomy. *Can J Ophthalmol.* 2003;38:580–6.
4. Wishart MS, Shergill T, Porooshani H. Visvocanalostomy and phacoviscocanalostomy: long-term results. *J Cataract Refract Surg.* 2002; 28:745–51.
5. Tanito M, Park M, Nishikawa M, Ohira A, Chihara E. Comparison of surgical outcomes of combined viscocanalostomy and cataract surgery with combined trabeculectomy and cataract surgery. *Am J Ophthalmol.* 2002;134:513–20.
6. Wishart MS, Dages E. Seven-year follow-up of combined cataract extraction and viscocanalostomy. *J Cataract Refract Surg.* 2006;32:2043–9.
7. Park M, Hayashi K, Takahashi H, Tanito M, Chihara E. Phacoviscocanalostomy versus phaco-trabeculectomy: a middle-term study. *J Glaucoma.* 2006;15:456–61.
8. Lindberg JG. Kliniska undersökningar över depigmentering av pupillarranden och genomlysbarhet av iris vid fall av alderstrarr samt i normala ögon hos gamla personer. *Inaug Diss Helsingfors.* 1917.
9. Naumann GOH, Schlötzer-Schrehardt U, Kuchle M. Pseudoexfoliation syndrome for the comprehensive ophthalmologist; intraocular and systemic manifestations. *Ophthalmology.* 1998;105:951–68.
10. Ritch R, Schlotzer-Schrehardt U. Exfoliation syndrome. *Surv Ophthalmol.* 2001;45:265–315.
11. Pohjanpelto P. Influence of exfoliation syndrome on prognosis in ocular hypertension greater than or equal to 25 mm. *Acta Ophthalmol (Copenh).* 1986;64:39–44.
12. Popovic V, Sjöstrand J. Course of exfoliation and simplex glaucoma after primary trabeculectomy. *Br J Ophthalmol.* 1999; 83:305–10.
13. Puska P, Tarkkanen A. Exfoliation syndrome as a risk factor for cataract development; five-year follow-up of lens opacities in exfoliation syndrome. *J Cataract Refract Surg.* 2001;27:1992–8.
14. Hietanen J, Kivela T, Vesti E, Tarkkanen A. Exfoliation syndrome in patients scheduled for cataract surgery. *Acta Ophthalmol (Copenh).* 1992;70:440–6.
15. Hassan KM, Awadalla MA. Results of combined phacoemulsification and viscocanalostomy in patients with cataract and pseudoexfoliative glaucoma. *Eur J Ophthalmol.* 2008;18:212–9.
16. Conway RM, Schlotzer-Schrehardt U, Kuchle M, Naumann GO. Pseudoexfoliation syndrome: pathological manifestations of relevance to intraocular surgery. *Clin Experiment Ophthalmol.* 2004;32: 199–210.
17. Kuchle M, Nguyen NX, Hannappel E, Naumann GO. The blood-aqueous barrier in eyes with pseudoexfoliation syndrome. *Ophthalmic Res.* 1995;27:136–42.
18. Brooks AM, Gillies WE. The development of microneovascular changes in the iris in pseudoexfoliation of the lens capsule. *Ophthalmology.* 1987;94:1090–7.
19. Friedburg D, Bischof G. Fluorescein angiographic features of the pseudoexfoliation syndrome. *Glaucoma.* 1982;4:13–16.
20. Landa G, Pollack A, Rachmiel R, Bukelman A, Marcovich A, Zalish M. Results of combined phacoemulsification and trabeculectomy with mitomycin C in pseudoexfoliation versus non-pseudoexfoliation glaucoma. *Graefes Arch Clin Exp Ophthalmol.* 2005;243:1236–40.
21. Konstas AG, Jay JL, Marshall GE, Lee WR. Prevalence, diagnostic features, and response to trabeculectomy in exfoliation glaucoma. *Ophthalmology.* 1993;100:619–27.

22. Serguhn S, Spiegel D. Comparison of postoperative recovery after trabeculectomy for pseudoexfoliation glaucoma and chronic primary open angle glaucoma. *Klin Monatsbl Augenheilkd*. 1999;215:281–6.
23. Ehrnrooth P, Lehto I, Puska P, Laatikainen L. Long-term outcome of trabeculectomy in terms of intraocular pressure. *Acta Ophthalmol Scand*. 2002;80:267–71.
24. Drolsum L. Deep sclerectomy in patients with capsular glaucoma. *Acta Ophthalmol Scand*. 2003;81:567–72.
25. Drolsum L. Longterm follow-up after deep sclerectomy in patients with pseudoexfoliative glaucoma. *Acta Ophthalmol Scand*. 2006;84:502–6.
26. Honjo M, Tanihara H, Inatani M, Honda Y, Ogino N, Ueno S, Negi A, et al. Phacoemulsification, intraocular lens implantation, and trabeculectomy to treat pseudoexfoliation syndrome. *J Cataract Refract Surg*. 1998;24:781–6.
27. Tanihara H, Negi A, Akimoto M, et al. Surgical effect of trabeculectomy ab externo on adult eyes with primary open angle glaucoma and pseudoexfoliation syndrome. *Arch Ophthalmol*. 1993;111:1653–61.
28. Drolsum L, Haaskjold E, Sandvig K. Phacoemulsification in eyes with pseudoexfoliation. *J Cataract Refract Surg*. 1998;24:787–92.
29. Shingleton BJ, Heltzer J, O'Donoghue MW. Outcomes of phacoemulsification in patients with and without pseudoexfoliation syndrome. *J Cataract Refract Surg*. 2003;29:1080–6.
30. O'Brart DPS, Shiew M, Edmunds B. A randomised, prospective study comparing trabeculectomy with viscocanalostomy with adjunctive antimetabolite usage for the management of open angle glaucoma uncontrolled by medical therapy. *Br J Ophthalmol*. 2004;1012–7.
31. Suzuki R, Tanaka K, Sagara T, Fujiwara N. Reduction of intraocular pressure after phacoemulsification and aspiration with intraocular lens implantation. *Ophthalmologica*. 1994;208:254–58.
32. Gimbel HV, Meyer D, DeBroff BM, Roux CW, Ferensowicz M. Intraocular pressure response to combined phacoemulsification and trabeculectomy ab externo versus phacoemulsification alone in primary open-angle glaucoma. *J Cataract Refract Surg*. 1995;21:653–60.
33. Yalvac I, Airaksinen PJ, Tuulonen A. Phacoemulsification with and without trabeculectomy in patients with glaucoma. *Ophthalmic Surg Lasers*. 1997;28:469–75.
34. Hayashi K, Hayashi H, Nakao F, Hayashi F. Changes in anterior chamber angle width and depth after intraocular lens implantation in eyes with glaucoma. *Ophthalmology*. 2000;107:698–703.
35. Dosso AA, Bonvin ER, Leuenberger PM. Exfoliation syndrome and phacoemulsification. *J Cataract Refract Surg*. 1997;23:122–5.
36. Merkur A, Damji K, Mintsoulis G, Hodge WG. Intraocular pressure decrease after phacoemulsification in patients with pseudoexfoliation syndrome. *J Cataract Refract Surg*. 2001;27:528–32.
37. Shingleton BJ, Laul A, Nagao K, et al. Effect of phacoemulsification on intraocular pressure in eyes with pseudoexfoliation Single-surgeon series. *J Cataract Refract Surg*. 2008;34:1834–41.