

Submitted: 09/04/2018

Accepted: 19/10/2018

Published: 15/11/2018

The prevalence of *Gasterophilus intestinalis* (Diptera: Oestridae) in donkeys (*Equus asinus*) in Egypt with special reference to larvicidal effects of neem seed oil extract (*Azadirachta indica*) on third stage larvae

Marwa M. Attia*, Marwa M. Khalifa and Olfat A. Mahdy

Department of Parasitology, Faculty of Veterinary Medicine, Cairo University, Giza, P.O. Box 12211, Egypt

Abstract

Gasterophilus larvae are of veterinary and medical importance caused specific equine intestinal myiasis. *Gasterophilus intestinalis* (Botfly larvae) had a wide geographical distribution. The present study explores the prevalence rate of *G. intestinalis* 3rd stage larvae in Egypt from January- December 2017; besides, in vitro trials to control of this larvae and evaluation of this trial using Scanning Electron Microscope (SEM) and histopathology of treated larvae. In the present study, the 3rd larval stage of *G. intestinalis* was found in clusters in the epithelium of the investigated stomach and infested with prevalence rate 97.2%. The highest collected numbers of larvae were found in two months; March and August (570 & 520 larvae) and lowest numbers (200 larvae) were collected in October, November, and December. The calculated LC₅₀ and LC₉₀ values of neem seed extract were 707.9 ppm and 1090.7 ppm. The different alteration was recorded after exposure to oil extract which showed some destruction on cuticle surface as folded and corrugated cuticle, destruction of maxillae with pits on its surface, disfigure and irregularity of cephalic spines. Histopathology of exposed *G. intestinalis* larvae showed different changes as thinning of cuticle at the different level (exocuticle, endocuticle, cell layers), degeneration of epithelial cells of the gut and different degree of necrosis was described. Life cycle of *G.intestinalis* was followed up after treatment with neem seed extract.

Keywords: Donkeys, Egypt, *Gasterophilus intestinalis*, Larvicide, Neem seed extract.

Introduction

Gasterophilus intestinalis (Diptera: Oestridae) is a specific obligatory parasitic myiasis larvae infesting family equidae stomach (equine, donkeys and Zebra) mainly in the Mediterranean regions as well as U.S.A and China (Otranto *et al.*, 2005; Colwell *et al.*, 2006; Huang *et al.*, 2016).

Life cycle ranged from 8-10 months which begins with the adult female which deposits its eggs on host's hair mainly forelegs. The 1st instar larvae hatch in the mouth and moult to 2nd larval stage, then the L₃ (3rd stage) remains attached to the mucosa of stomach for 8-10 month according to temperature and humidity (Zumpt, 1965).

Invasion of *G. intestinalis* described by gastrointestinal irritation including ulceration, volvulus, looseness of the bowels; peritonitis may happen which prompts intestinal break (Otranto *et al.*, 2005). There are numerous reports of human myiasis caused by *Gasterophilus* spp. larvae causing ophthalmo-myiasis (Anderson, 2006; Yang *et al.*, 2013).

Gasterophilus intestinalis had a wide geographical distribution in different countries as Morocco, Europe, Italy, Turkey and Saudi Arabia (Pandey *et al.*, 1992; Colebrook and Wall, 2004; Otranto *et al.*, 2005; Gökçen *et al.*, 2008 ; Al Anazi and Alyousif, 2011) but

the highest prevalence was found in warm areas from Italy and Brazil (Otranto *et al.*, 2005; Felix *et al.*, 2007). While in Egypt Hilali *et al.* (1987) recorded 98.3% infestation with *G. intestinalis* larvae in donkeys.

In a long time, after using of synthetic larvicides. They contaminate the earth besides its poisonous quality to non-target life forms, protection improvement, and dangerous impacts on human and all living wellbeing (Pretty, 2009).

Thus, controlling of insects and its larval stages required natural alternative methods without harming the environment. Nowadays, the plant extract is a new protocol study for controlling the disease as well as the parasite and pests. Neem seed oil has been more effective in controlling some parasitic disease as lice, ticks and many parasites (Okumu *et al.*, 2007; Girish and Bhat, 2008; Giglioti *et al.*, 2011; Abdel-Ghaffar *et al.*, 2012; Ruchi *et al.*, 2014).

The previous literature reveals that still no work had been done on this Egyptian neem seed extract by the scientist on equine botfly larvae. Along with this lines, the present study explores the prevalence rate of *G. intestinalis* 3rd stage larvae in Egypt from January-December 2017; besides, in vitro trials to control of this larvae and evaluation of this trial using Scanning Electron Microscope (SEM) and histopathology of treated larvae.

*Corresponding Author: Marwa Mohamed Attia. Department of Parasitology, Faculty of Veterinary Medicine, Cairo University, Egypt. Fax: +202-35725240; +202-35710305. Email: marwaattia.vetpara@yahoo.com

Materials and Methods

Collection of *Gasterophilus intestinalis* larvae

A total of 144 stomach donkeys (12 stomach /month) were inspected during a period from January-December 2017 from the slaughtered house in Giza, Zoo abattoir (Giza, Egypt) for detection of infestation of *Gasterophilus* spp. 3rd stage larvae. The donkeys were collected from three governorates Giza (40), Fayoum (48) and Beni Sweif (56). The governorates were located south of Cairo city at a distance of 2.5, 103 and 119 Km., respectively. Each stomach was examined with naked eyes and *Gasterophilus* larvae were collected from each infested donkey and counted then placed in a separate vial containing the saline solution (0.9% NaCl, GmbH, Germany). All larvae were examined on the same day of collection at the Parasitology Department, Faculty of Veterinary Medicine, Cairo University, Giza, Egypt for further studies. This study was approved from The Animal Ethical Committee of Faculty of Veterinary Medicine, Cairo University number: CU/II/F/18/104.

The Collected larvae

All larvae subjected to two processes; identification study and control one. Therefore, 10 larvae from each governorate were identified using a stereoscopic microscope (LEICA M60, United states) then (scanning electron microscope) study. Other fresh active instar larvae were used in control study using neem seed oil.

Morphological identification of 3rd instar larvae

For SEM, ten larvae were collected. They were prepared by serial washing in saline solution and fixed in 2.5% glutaraldehyde as previously described by Colwell *et al.* (2007), Hilali *et al.* (2015) and Attia (2018). Larvae were dehydrated through passage in ascending ethanol degrees, which dried in CO₂ critical drier (Autosamdri-815, Germany) and glued over stubs; coated with gold in a sputter coater (Spi-Module sputter Coater, UK). Specimens were photographed using SEM (JSM 5200, Electron prob Microanalyzer, Jeol, Japan) at Faculty of Agriculture, Cairo University, Egypt. Identification was done according to the morphological keys described by Zumpt (1965).

Neem oil preparation

According to Dua *et al.* (2009), the neem seed oil, *Azadirachta indica*; was obtained from 100 g of fresh neem seeds by grinding up the seeds and covered the grounded up materials with water. Hydrodistillation using a steam in a Clevenger- type apparatus for 4 h. Then condensing the neem oil in a condenser. The essential oil was taken in diethyl ether, dried over sodium sulphate and stored in amber- colored vials at 4°C until use.

Larvicidal assay

Larvicidal effects were tested by using different concentrations from neem oil (50 ppm, 100 ppm, 150

ppm, 300 ppm, 500 ppm, 700 ppm, 900 ppm and 1000 ppm) which were freshly prepared in distilled water with few drops of Tween 80 as an emulsifier. Fifty fresh, actively movement *G. intestinalis* L₃ were used in each test. Each group of larvae was placed in 100 ml solution of each concentration, immersed for 10 minutes and then the solution was continuously stirred during the test; Each concentration was tested in two replicates; each replicate was 50 larvae (Smith *et al.*, 2000; Khater *et al.*, 2009, 2013).

The negative control groups (non - exposed groups) of larvae was kept in (group with distilled water alone and group in distilled water with few drops of Tween 80). Then, treated larvae with neem oil were removed from oil and kept in plastic cups with filter papers (Whatman No. 1) and kept at 27 ± 2 °C and 80±5 % relative humidity (RH). The mortality of larvae in all cups was followed up in the same day of treatment. Larvae were considered alive or dead according to larval motility (Khater and Ramadan, 2007; Khater *et al.*, 2013).

Larval mortality was determined daily until pupation occurred. The larvae were incubated at 32°C and 80-85% RH. Then each concentration was divided into four beakers (each beaker had 25 larvae) containing a sterile sand and covered with gauze. The beakers were put in a large dissector containing a suitable amount of salt solution to adjust the humidity. The larvae examined daily for any mortality and pupal formation. The developed pupae, at each concentration, were counted and placed in separate cages until adults emergence.

Assessment of larvicidal efficacy of neem oil extract Scanning electron microscope (SEM) study

Five larvae were chosen from the last two concentrations (900 ppm and 1000 ppm) and five from control group (non treated) prepared by serial washing in saline solution and fixed in 2.5% glutaraldehyde as described by Hilali *et al.* (2015) and Attia (2018). Specimens were processed as previously described.

Histopathological studies

Larvae were taken from those exposed groups to neem oil at 900 ppm and 1000 ppm concentrations (5 larvae from each concentration) as well as from control group (5 larvae) fixed in 10% formalin and processed according to Bancroft *et al.* (1996). The body wall and the cells of larvae were studied and photographed using an Olympus CX41 microscope, Japan.

Climatological data

Data of mean monthly temperature (minimum and maximum), mean rainfall and RH in Egypt were obtained from Egyptian Meteorological Authority during the investigation period (January- December 2017). Average temperatures recorded in wintertime 9.5-17 °C (49.1-62.6 °F) to 23-32 °C (73.4-89.6 °F) in the summertime. Egypt receives between 20 mm. and 200 mm. of annual average rainfall in Cairo, Giza, but

south to Cairo, the average drops to nearly 0 mm. in the central and the southern part of the country. During the study period RH was ranging from (40-60%).

Statistical analysis

A logistic regression analysis to test the association between the occurrence of infection and the different months all over the year.

In an initial step, univariate logistic regression statistics was done. In such process, the category of the donkey (infected or non-infected) was the dependent dichotomous variable, but the suggested time factor was the independent variables. Therefore, the parameters included, p-value, odds ratio (OR), confidence interval (CI: 95%), regression coefficient (β), and standard error, significance was considered when $P \leq 0.05$.

Differences between mean intensity in donkeys were determined using Chi-square test. All analyses were performed using the SPSS v.11.0. Larval mortality was calculated by probit analysis followed by linear regression to determine LC_{50} and LC_{90} according to Finney (1971).

Results

Monthly intensity with *G. intestinalis* third instar larvae

One hundred and forty out of 144 donkeys (97.2%) were infested with 3rd larvae of *G. intestinalis*. During the period of examination a total number of 4630 *G. intestinalis* 3rd stage larvae were collected from the Giza zoo (Fig. 1).

The monthly larval intensity of infestation showed two peaks; in March followed by August (570 & 520 larvae; Table 1). The total number of the larvae increase non-significantly from January to February to reach its highest value in March (570 larvae). Then, the number decreased non-significantly in April, May, June and July to reach its second peak in August (520 larvae).

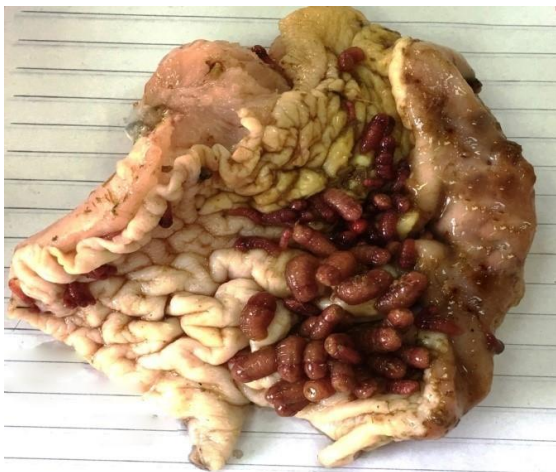

Fig. 1. Stomach of donkey infested with *G. intestinalis* larvae.

There were non-significant decrease between August and September and between September and October. While during October, November, and December (200 larvae collected) no significant differences in these months were recorded.

A logistic regression was performed to ascertain the effect of the month of the year on the likelihood that animals have infection. The logistic regression model was not statistically significant ($P = 0.366$). The model explained 35.6% (Nagelkerke R^2) of the variance in infection and correctly classified 97.2% of cases. Months of the year had no significance on the occurrence of infection (P -value ranged from 0.999 to 1.000).

Odd ratios (OR) were 0.000 for November, December and February, and were 1.000 for all other months.

Morphological identification of 3rd stage larvae

G. intestinalis 3rd instar larvae obtained from the stomach of Egyptian inspected donkeys were reddish in colour, fusiform in shape (Fig. 1).

These larvae consisted from 12 segments: the 1st segment with 6-7 rows of denticles ventrally, 3-4 rows dorsally at pseudocephalon (around mouth opening). The pseudocephalon consist of a pair of maxillae (mouth hooks) which has several ovoid pits or ridges that regularly spaced; a pair of serrated mandibles and antennal lobes were present.

Each body segment from 3-10 provided with anterior transverse 2 rows of spines in dorsal and ventral surfaces (Fig. 2), the L3 had 6 spiracular openings in posterior end, the posterior end composed from dorsal and ventral lip which had sensory papillae (Fig. 3).

Larvicidal effects of neem seed oil extract

Concerning the treatment trial of 3rd instar larvae in the present study (Tables 2, 3; Fig. 4), the concentrations of neem oil extract which less than 300 ppm did not cause any mortality in the exposed stage. Mortalities in *G. intestinalis* larvae start as $5.0 \pm 1.9\%$ after exposure to 300 ppm.

Mortalities increase 45 and 75% with increasing the oil concentration up to 700 and 900 ppm respectively. After increasing the concentration to 1000 ppm, the effects increased to $90 \pm 1.1\%$.

The calculated LC_{50} values of neem seed extract (*Azadirachta indica*) was 707.9 ppm while LC_{90} was 1090.7 ppm (Table 3).

Effects of neem seed oil extract on the *G. intestinalis* larvae, pupae and adult (life cycle follow up)

Morphological abnormalities were noticed on treated larvae by tested material (neem seed extract) till pupation and adult emergence (Fig. 5).

Malformations of larvae included shorten and damaged larvae with weak, damage and soften cuticle with different coloration (yellow, brown and black cuticle).

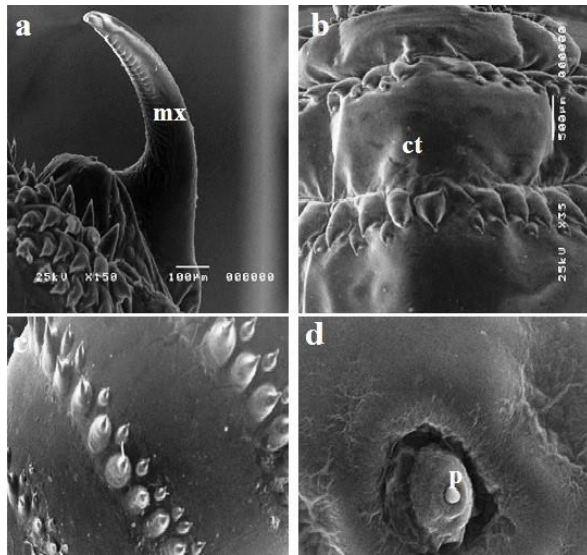


Fig. 2. Scanning electron image showing normal 3rd instar larvae of *G. intestinalis*. (a): showing normal maxillae (mx) note the ovoid pits or ridges which regularly spaced. (b): normal cuticle (ct) with regular spines. (c): normal arrangement of spines on normal cuticle. (d): normal papillae (p) which surrounds posterior spiracles.

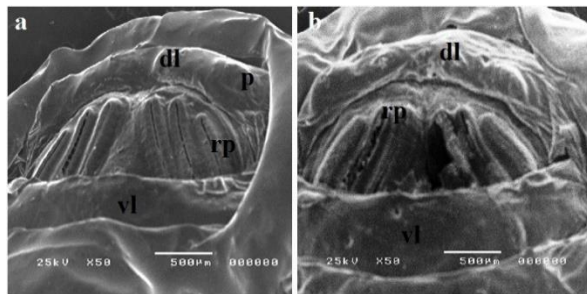


Fig. 3. Scanning electron image of abdominal spiracles of the 3rd instar larvae of *G. intestinalis*. (a): The third instar larvae showing anterior sensory papillae (p) on dorsal lip (dl) and ventral lip (vl). In addition, it had three respiratory openings (rp). (b): The abdominal spiracles of third instar larvae after treatment with neem seed oil showing destroyed abdominal spiracles.

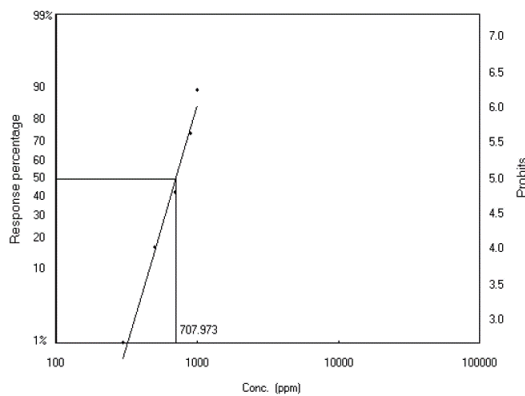


Fig. 4. Probit analysis curve of mortality rate after exposure to neem seed extract.



Fig. 5. Morphological abnormalities after exposure to neem seed extract. (A): different shape of moribund larvae after treated with neem extract with different stage of mortality. (B): Normal pupa (Np); other pupae were persistent and dead pupa, inability of adult to emerge. (C): other adults showing different malformation with poorly developed adults; either with deformed wing and legs, sac like abdomen, persistent ptilinal sac in the head (F: normal female, M: normal male).

Abnormalities of pupae included dead, distorted and larviform pupae, different colouration of moribund pupae from dark yellow to black colour. The adults deformity included an incomplete emergency from the pupae, small sized adult and malformed. The ptilinal sac in the head was persistent. The wings were poorly developed and deformed, either alone or in combination with legs. The legs and wings may be not formed. Abdomen in form of sac - like and become enlarged (Fig. 5).

Scanning Electron Microscope (SEM) study

The non exposed control groups of 3rd instar larvae of *G. intestinalis* with neem extract which examined by SEM showed some alterations on the dorsal and ventral surface.

There were small areas of swelling appeared at the ventral surface with severely corrugated cuticle which leads to disappearance and destruction as well as irregularity of spines, the maxillae appeared to have a destructed pits in comparison of its normal one (Fig. 6 and 7).

Table 1. Monthly prevalence of *G. intestinalis* larvae with monthly intensity of infestation with 3rd stage larvae in donkeys during January-December, 2017.

Month	No. examined donkeys	No. positive (%)	Number of larvae	Mean intensity	regression coefficient (β)	95% CI	standard error	P
January	12	12 (100)	210	17.5	-	-	-	1.000
February	12	10 (83.3)	400	40	0.000	0.000	16408.710	1.000
March	12	12 (100)	570	47.5	-18.805	0.000	11602.709	0.999
April	12	12 (100)	500	41.6	-19.593	0.000	11602.709	0.999
May	12	12 (100)	480	40	0.000	0.000	16408.710	1.000
June	12	12 (100)	430	35.8	0.000	0.000	16408.710	1.000
July	12	12 (100)	470	39.2	0.000	0.000	16408.710	1.000
August	12	12 (100)	520	43.3	0.000	0.000	16408.710	1.000
September	12	12 (100)	450	37.5	0.000	0.000	16408.710	1.000
October	12	12 (100)	200	16.7	-18.805	0.000	11602.709	0.999
November	12	11 (91.7)	200	18.2	0.000	0.000	16408.710	1.000
December	12	11 (91.7)	200	18.2	0.000	0.000	16408.710	1.000
Total	144	140 (97.2)	4630	33.1				

Table 2. Larvicidal efficacy of neem seed oil extract on 3rd larval instar.

Conc.	Percentage (%) \pm SE			
	Larval mortality	Pupation	Fly emergence	Deformed fly
Control	4.0 \pm 1.6 ^a	96.0 \pm 1.6 ^e	91.0 \pm 1.9 ^e	0.0 \pm 0.0 ^a
300	5.0 \pm 1.9 ^a	94.0 \pm 1.1 ^e	88.0 \pm 1.6 ^e	12.0 \pm 1.6 ^b
500	20.0 \pm 1.6 ^b	80.0 \pm 1.6 ^d	69.0 \pm 1.9 ^d	26.0 \pm 2.5 ^d
700	45.0 \pm 2.5 ^c	55.0 \pm 2.5 ^c	39.0 \pm 1.0 ^c	20.0 \pm 1.6 ^c
900	75.0 \pm 1.9 ^d	25.0 \pm 1.9 ^b	18.0 \pm 1.1 ^b	18.0 \pm 1.1 ^c
1000	90.0 \pm 1.1 ^e	7.0 \pm 1.0 ^a	0.0 \pm 0.0 ^a	0.0 \pm 0.0 ^a
F	393.6	469.3	693.4	0.0
P	<0.001	<0.001	<0.001	<0.001

All values are expressed as means \pm SE. (^{a, b, c, d, e}): explain the significant difference between the percent of mortalities within rows at P<0.05; means with the same superscripts do not differ significantly. (Conc.): Concentration; (F): F values; (P): Significance.

Table 3. Different lethal concentrations after exposure of neem seed oil extract to 3rd stage larvae of *G.intestinalis*.

Lethal concentration	Concentration (ppm)	Lower limit (ppm)	Upper limit (ppm)
25	563.92	524.815	597.157
50	707.973	674.714	741.291
75	888.824	844.495	945.201
90	1090.793	1017.031	1195.402
95	1232.984	1133.447	1379.729
99	1551.555	1385.65	1809.803

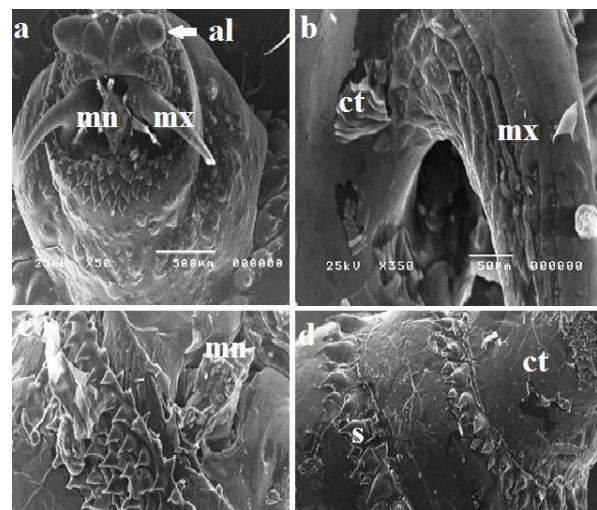


Fig. 6. Scanning electron image of *G. intestinalis* 3rd stage larvae after exposure to neem seed oil showing in a, b: severe destruction on its cuticle (ct) and maxillae (mx), oedema present in cuticle, antennary lobes (al). c, d: destruction of mandible (mn) with disarrangement of spines (s) after treatment with neem seed oil.

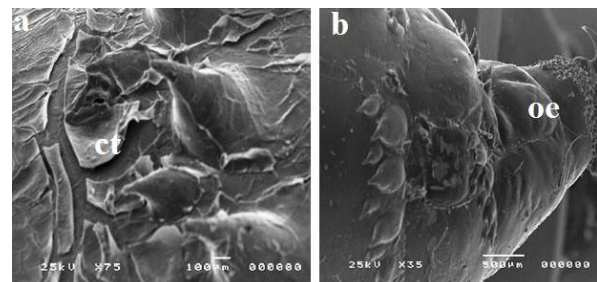


Fig. 7. Scanning electron image of the treated *G. intestinalis* 3rd stage larvae showing in a, b: severe shrinkage on its cuticle (ct) after treatment with neem seed oil and oedema (oe).

At the dorsal surface, there were extensive areas of swelling so spines of the dorsal surface appeared submerged or sunken in the swelling. In addition to swelling, large area appeared to be eroded anteriorly while degeneration of some papillae with sever wrinkled and folded cuticle posteriorly (Fig. 7).

Histopathology of exposed instar larvae versus control one

Normal control larvae

Histological sections of non exposed normal control group of *G. intestinalis* larvae; showed normal structures of cuticle which composed from outer-thick layer (exocuticle) which was thick, rigid and forms the main skeletal layers of normal larvae, followed by, endocuticle which represents the main part of the cuticle consisting of the outermost layer and the inner-most layer (epidermis) which consisted from the dermal glands (Fig. 8).

Somatic cells appeared normal with its clear nucleus and cytoplasm (Fig. 8).

Exposed and treated larvae

The larvicidal effect of neem seed extract on 3rd larvae of *G. intestinalis* showed thinning of the cuticular surface with separation of the inner cellular layer of epidermal cells.

Epithelial cells of gut were destructed, reduced in size, separated from each other and some of them detached in the lumen (Fig. 8). Vacuolization and necrosis of epithelial cells layers were noticed with disorganization in exposed larvae (Fig. 8).

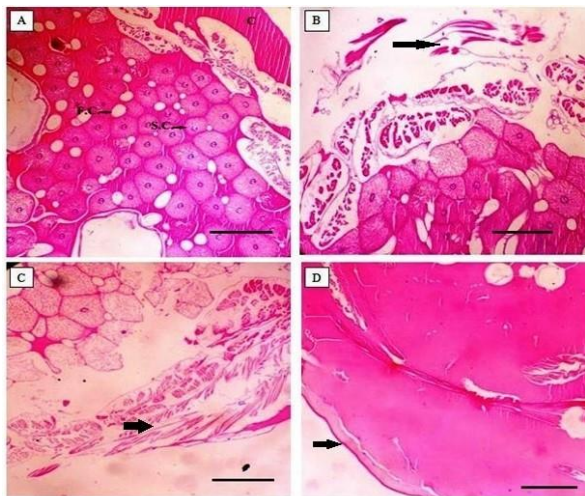


Fig. 8. Section of control and treated larvae stained with H&E. (A): normal histological sections of control group of *G. intestinalis* larvae showed normal structure of thick cuticle followed by large number of somatic cells (S.C.) and fat cell (F.C.) which appeared normal with its clear nucleus. (B and C): treated larvae showing destruction of cuticle layers; referred by arrow. (D): vacuolization and complete necrosis of fat and somatic cells with disorganization and disappearance of cell structure; referred by arrow (Scale bar = 100µm).

Discussion

This study was performed to record the update knowledge of prevalence rate of the most infectious bot fly in donkeys *G. intestinalis* 3rd instar larvae during January to December, 2017. Beside the main aim to assess and evaluate the larvicidal activity of widely used plant extract (*Azadirachta indica*) to eliminate this infestation. In the present study, the total prevalence rate 97.2% with the two peak of infestation in March & August (570 & 520 larvae). The monthly prevalence was of great interest that gives good idea on life cycle and dynamics of adult fly. The prevalence result agreed with the prevalence by Hilali *et al.* (1987) who recorded 98.3% prevalence rate and disagreed with the result by the same author of the monthly intensity of infestation, who recorded the monthly peak of infestation in the year (July, 157 larvae) this may be due to change in climatic condition from 1987 to 2017. Our opinion similar to Otranto *et al.* (2005) who recorded two bimodal of intensity in April and August, so the adult fly activity with two cycles during early summer and autumn. In other countries, prevalence rate 9.9% recorded by Høglund *et al.* (1997) in Sweden; 43% by Sweeney (1990) in Ireland; 95.2% by Otranto *et al.* (2005) in Italy; 2.25% Rehbein *et al.* (2013) in Germany and 28.57% by Nalan *et al.* (2010) around Mediterranean region and almost all the world. So, *G. intestinalis* is the predominant bot fly in Egyptian donkeys.

Therefore, this prevalence data is update knowledge resulted in Egypt since Hilali *et al.* (1987) and recorded two life cycles per year. So, this is important in the medical care of donkeys as well as horses.

The concentration of neem oil are compelling against many protozoal pathogens as *Trypanosoma* and *Leishmania*, *Plasmodium* (Tapanelli *et al.*, 2016) which prove to have antiplasmodium activity due to its contents of limonoids (*Azadirachtin*) appeared to interfere in *Plasmodium* stages. Alcoholic concentrate of neem seeds has an antifilarial action against *Setaria cervi* (Tahir *et al.*, 1998; Mishra *et al.*, 2005). Remedio *et al.* (2016) studied the effects of neem seed oil had *azadirachtin* against *Rhipicephalus sanguineus* ticks with demonstration the effects of this plant extract on salivary glands of the ticks, with results that; the cells were distorted, cytoplasmic disorganization, and some endoplasmic changes of its lumen, besides several alteration in mitochondrial membrane.

Neem had been utilized as antiparasitic in a few types of ectoparasites and some pests because of its quick action. Hormone copying of neem oil cause interfere with the parasitic life cycle which suppresses their capacity to sustain (Kumar and Navaratnam, 2013; Ruchi *et al.*, 2014). Neem plant extract have been recorded to be a compelling bioinsecticide (Chary, 2011; Ruchi *et al.*, 2014) and discovered to be helpful

in controlling of numerous insects pests (Karunamoorthi *et al.*, 2009; Kudom *et al.*, 2011; Mehlhorn *et al.*, 2011; Abdel-Ghaffar *et al.*, 2012; Walldorf *et al.*, 2012).

Neem plant extract was used as anthelmintic in different helminths as in bovine strongylosis as recorded by Nirmala *et al.* (2015) which proved that the neem had anthelmintic effects through inhibition of excitatory cholinergic transmission which interferes with nervous system of the parasite (Veerakumari and Priya, 2006; Qiao *et al.*, 2014).

Dealing with the larvicidal effect of neem seed extract in the present study, the different concentrations of neem extract that less than 300 ppm did not cause any mortality in the exposed stage. Mortalities in *G. intestinalis* larvae start as 5 ± 1.9 % after exposure to 300 ppm.

This finding indicates that other limonoids present in the seeds might influence the obtained results. A hypothesis is that considering the Azadirachtin concentrations, which might have been a gradual reduction in the amount of other limonoids present in the basic extract produced (Kraus, 2002).

In the present study, SEM microphotographs as well as histopathological studies of 3rd stage larvae, after exposure to neem seed extract versus the non exposed larvae showed alterations on the dorsal and ventral surface. This change of larvae may be due to the active component of Azadirachtin containing the limonoid as the main component which is a natural plant defence and prove to be very toxic to the arthropods larvae, pupae and adults, as described by Mordue and Blackwell (1993). As well as, this component is affecting the larvae feeding through blocking of input chemoreceptors (primary anti-feedancy) which responsible in the phago-stimulants. Also, this component disrupts the moulting and inhibits the growth of larval arthropods as in malaria vector (Dua *et al.*, 2009) from this point which explains that the neem seed oil disrupts the life cycle by death of pupae as well as emergence of deformed adults.

In the present study, neem oil extract showed promising larvicidal activity against the important equine pest. Development of resistance to many synthetic insecticides is a matter of concern for operational use as larvicides. The neem has the advantage of being eco-friendly, effective and able to prevent the development of insect resistance, as well as disrupt the life cycle of this equine pest.

Conclusion

Since our study reveals two cycles of *G. intestinalis* per year so it advisable to treat animals two times in March and August during the highest prevalence of studied larvae. Also, neem extract has good larvicidal properties for *G. intestinalis* 3rd stage larvae which has clear distinct degeneration on the cuticular surface of

exposed larvae by SEM and histopathological description versus to non exposed control larvae. Considering the wide distribution and availability of neem tree with its products along the East African coast, this may prove a readily available and cheap alternative to conventional chemical insecticides. With the best; of our knowledge it recommended using 707.9 ppm for LC₅₀ and 1090.7 ppm for LC₉₀ in controlling of *G. intestinalis* larvae.

Conflict of interest

The authors declare that there is no conflict of interest.

References

- Abdel-Ghaffar, F., Al-Quraishy, S., Al-Rasheid, K.A.S. and Mehlhorn, H. 2012. Efficacy of a single treatment of head lice with a neem seed extract: An *in vivo* and *in vitro* study on nits and motile stages. *Parasitol. Res.* 110, 277-280.
- AL Anazi, A.D. and Alyousif, M.S. 2011. Prevalence of non- gastrointestinal parasites strongyle of horses in Riyadh region of Saudi Arabia. *Saudi J. Biol. Sci.* 18, 299-303.
- Anderson, J.R. 2006. Asteroid myiasis of humans. In: Colwell DD, Hall MJR, Scholl PJ (Eds.), *The Oestrid Flies: Biology, Host-Parasite Relationships, Impact and Management*. CAB International.
- Attia, M.M. 2018. Micromorphological studies of adult stages of *Haematopinus asini* (Equine sucking lice; Phthiraptera: Haematopinidae) with its eggs from donkeys (*Equus asinus*). *J. Entomol. Zool. Stud.* 6(2), 3062-3068.
- Bancroft, J.D., Stevens, A. and Turner, D.R. 1996. *Theory and Practice of Histological Techniques*. 4th Edn., Churchill, Livingstone, New York, London, San Francisco, Tokyo.
- Chary, P. 2011. A comprehensive study on characterization of elite Neem chemotypes through mycofloral, tissue-cultural, ecomorphological and molecular analyses using azadirachtin-A as a biomarker. *Physiol. Mol. Biol. Plants* 17, 49-64.
- Colebrook, E. and Wall, R. 2004. Ectoparasites of livestock in Europe and the Mediterranean region. *Vet. Parasitol.* 120, 251-274.
- Colwell, D.D., Hall, M.J.R. and Scholl, P.J. 2006. *The oestrid flies: biology, host-parasite relationships, impact and management*. (CABI Publishing).
- Colwell, D.D., Otranto, D. and Horak, I.G. 2007. Comparative scanning electron microscopy of *Gasterophilus* third instars. *Med. Vet. Entomol.* 21, 255-264.
- Dua, V.K., Pandey, A.C., Raghavendra, K., Gupta, A., Sharma, T. and Dash, A.P. 2009. Larvicidal activity of neem oil (*Azadirachta indica*) formulation against mosquitoes. *Malaria J.* 8, 124.
- Felix, R.S., Silva, C.E., Schmitt, E., Quintana, L., Mendes, M. and Silva, S. 2007. Presence of

- Gasterophilus* (Leach, 1817) (Diptera: Oestridae) in horses in Rio Grande do Sul State, Brazil. *Parasitol. Latinoam.* 62, 122-126.
- Finney, D.J. 1971. Probit analysis. Cambridge University Press, Cambridge, pp: 303.
- Gökçen, A., Sevgili, M., Altas, M. and Camkerten, I. 2008. Presence of *Gasterophilus* species in Arabian horses in Sanliurfa region. *Türkiye Parazitoloji Dergisi* 32, 337-339.
- Girish, K. and Bhat, S.S. 2008. Neem-a green treasure. *J. Biol.* 4, 102-111.
- Giglioti, R., Forim, M.R., Oliveira, H.N., Chagas, A.C.S., Ferrezini, J., Brito, L.G., Falcoski, T.O.R.S., Albuquerque, L.G. and Oliveira, M.C.S. 2011. In vitro acaricidal activity of neem (*Azadirachta indica*) seed extracts with known azadirachtin concentrations against *Rhipicephalus microplus*. *Vet. Parasitol.* 181, 309-315.
- Hilali, M., Derhalli, F.S. and Baraka, A. 1987. Incidence and monthly prevalence of *Gasterophilus* spp. Larvae (Diptera: Gasterophilidae) in the stomach of donkeys (*Equus asinus*) in Egypt. *Vet. Parasitol.* 23, 297-305.
- Hilali, M., Mahdy, O.A. and Attia, M.M. 2015. Monthly variations of *Rhinoestrus* spp. (Diptera: Oestridae) larvae infesting donkeys in Egypt: Morphological and molecular identification of third stage larvae. *J. Adv. Res.* 6, 1015-1021.
- Hoglund, J., Ljungstrom, B.L., Nilsson, O., Lundquist, H., Osterman, E. and Ugglå, A. 1997. Occurrence of *Gasterophilus intestinalis* and some parasitic nematodes of horses in Sweden. *Acta Vet. Scand.* 38, 157-165.
- Huang, H., Zhang, B., Chu, H., Zhang, D. and Li, K. 2016. *Gasterophilus* (Diptera, Gasterophilidae) infestation of equids in the Kalamaili Nature Reserve, China. *Parasite* 23, 36.
- Karunamoorthi, K., Mulelam, A. and Wassie, F. 2009. Assessment of knowledge and usage custom of traditional insect/mosquito repellent plants in Addis Zemen Town, South Gonder, North Western Ethiopia. *J. Ethnopharmacol.* 121, 49-53.
- Khater, H.F. and Ramadan, M.Y. 2007. The acaricidal effects of peracetic acid against *Boophilus annulatus* and *Argas persicus*. *Acta Sci. Vet.* 35(1), 29-40.
- Khater, H.F., Ramadan, M.Y. and El-Madawy, R.S. 2009. The lousicidal, ovicidal, and repellent efficacy of some essential oils against lice and flies infesting water buffaloes in Egypt. *Vet. Parasitol.* 164, 257- 266.
- Khater, H.F., Seddiek, S.A., El-Shorbagy, M.M. and Ali, M.M. 2013. The acaricidal efficacy of peracetic acid and deltamethrin against the fowl ticks, *Argas persicus*, infesting laying hens. *Parasitol. Res.* 112(1), 259-269.
- Kraus, W. 2002. Biologically active ingredients. In: Schmutterer, H. (Ed.), *The Neem Tree: Sources of Unique Natural Products for Integrated Pest Management, Medicine, Industry and Other Purposes.* second ed. Neem Foundation, Mumbai, pp: 39-110.
- Kudom, A.A., Mensah, B.A. and Botchey, M.A. 2011. Aqueous neem extract versus neem powder on *Culex quinquefasciatus*: Implications for control in anthropogenic habitats. *J. Insect Sci.* 11, 142.
- Kumar, V.S. and Navaratnam, V. 2013. Neem (*Azadirachta indica*): Prehistory to contemporary medicinal uses to humankind. *Asian Pac. J. Trop. Biomed.* 3, 505-514.
- Mehlhorn, H., Abdel-Ghaffar, F., Al-Rasheid, K.A., Schmidt, J. and Semmler, M. 2011. Ovicidal effects of a neem seed extract preparation on eggs of body and head lice. *Parasitol. Res.* 109, 1299-1302.
- Mishra, V., Parveen, N., Singhal, K.C. and Khana, N.U. 2005. Antifilarial activity of *Azadirachta indica* on cattle filarial parasite *Setaria cervi*. *Fitoterapia* 76, 54-61.
- Mordue, A.J. and Blackwell, A. 1993. Azadirachtin: an update. *J. Insect Physiol.* 39, 903-924.
- Nalan, Ö., Kamile, B., Özlem, O. and Serdar, D. 2010. Presence of *Gasterophilus* Species in Horses in Van Region. *Veteriner Fakültesi Dergisi*, 21(2), 87-90.
- Nirmala, J., Giridhari, Das., Priyanka, S. and Manjural, H. 2015. Anthelmintic efficacy of crude neem (*Azadirachta indica*) leaf powder against bovine strongylosis. *J. Parasit. Dis.* 39(4), 786-788.
- Okumu, F.O., Knols, B.G.J. and Fillinger, U. 2007. Larvicidal effects of a neem (*Azadirachta indica*) oil formulation on the malaria vector *Anopheles gambiae*. *Malaria J.* 6, 63.
- Otranto, D., Milillo, P., Capelli, G. and Colwell, D.D. 2005. Species composition of *Gasterophilus* spp. (Diptera, Oestridae) causing equine gastric myiasis in southern Italy: parasite biodiversity and risks for extinction. *Vet. Parasitol.* 133, 111-118.
- Pandey, V.S., Ouhelli, H. and Verhulst, A. 1992. Epidemiological observations on *Gasterophilus intestinalis* and *Gasterophilus nasalis* in donkeys from Morocco. *Vet. Parasitol.* 41(3-4), 285-292.
- Pretty, J. 2009. *The pesticide detox, towards a more sustainable agriculture.* Earth scan, London.
- Qiao, J., Zou, X., Lai, D., Yan, Y., Wang, Q., Li, W., Deng, S., Xu, H. and Gu, H. 2014. Azadirachtin blocks the calcium channel and modulates the cholinergic miniature synaptic current in the central nervous system of *Drosophila*. *Pest. Manag. Sci.* 70(7), 1041-1047.
- Rehbein, S., Visser, M. and Winter, R. 2013. Prevalence, intensity and seasonality of gastrointestinal parasites in abattoir horses in Germany. *Parasitol. Res.* 112, 407-413.

- Remedio, R.N., Nunes, P.H., Anholeto, L.A., Oliveira, P.R., Sá, I.C. and Camargo-Mathias, M.I. 2016. Morphological alterations in salivary glands of *Rhipicephalus sanguineus* ticks (Acari: Ixodidae) exposed to neem seed oil with known azadirachtin concentration. *Micron* 83, 19-31.
- Ruchi, T., Amit, K.V., Sandip, C., Kuldeep, D. and Shoor, V.S. 2014. Neem (*Azadirachta indica*) and its Potential for Safeguarding Health of Animals and Humans: A Review. *J. Biol. Sci.* 14, 110-123.
- Smith, K.E., Wall, R. and Howard, J.J. 2000. In vitro insecticidal effect of fipronil and beta cyfluthin on larvae of the blowfly *Lucilia sericata*. *Vet. Parasitol.* 88, 261-268.
- Sweeney, H.J. 1990. The prevalence and pathogenicity of *Gasterophilus intestinalis* larvae in horses in Ireland. *Irish Vet. J.* 43, 67-73.
- Tapanelli, S., Chianese, G., Lucantoni, L., Yerbanga, R.S., Habluetzel, A. and Taglialatela-Scafati, O. 2016. Transmission blocking effects of neem (*Azadirachta indica*) seed kernel limonoids on *Plasmodium berghei* early sporogonic development. *Fitoterapia* 114,122-126.
- Tahir, A.I., Ibrahim, A.M., Satti, G.M.H., Theander, T.G., Kharazmi, A. and Khalid, A.S. 1998. The potential antileishmanial activity of some Sudanese medicinal plants. *Phytotherapy Res.* 12(8), 576-579.
- Veerakumari, L. and Priya, P. 2006. In vitro effect of azadirachtin on the motility and acetylcholinesterase activity of *Cotylophoron cotylophorum* (Fischöeder, 1901). *J. Vet. Parasitol.* 20, 1-5.
- Walldorf, V., Mehlhorn, H., Al-Quraishy, S., Al-Rasheid, K.A., Abdel-Ghaffar, F. and Mehlhorn, J. 2012. Treatment with a neem seed extract (MiteStop®) of beetle larvae parasitizing the plumage of poultry. *Parasitol. Res.* 110, 623-627.
- Yang, J.Y., Zhang, D., Hu, D.F., Chu, H.J., Tao, Y.S., Fan, X.Z. and Li, K. 2013. The injury caused by myiasis of *Gasterophilus* in horse. *China Anim. Husb. Vet. Med.* 40(5), 177-180.
- Zumpt, T.F. 1965. *Myiasis in Man and Animals in the Old World*. Butterworths, London.