

# Trial to Alleviate Ascites Syndrome in Broiler Chickens

H .A.Kaoud , Khalf M.A and T.F.Ismail

Department of Veterinary Hygiene, Environmental Pollution and Management,  
Faculty of Veterinary Medicine, Cairo University, Giza 11221,  
Egypt. \*Email: [ka-oud@link.net](mailto:ka-oud@link.net)

Department of Veterinary Hygiene, Environmental Pollution and Management,  
Faculty of Veterinary Medicine, Cairo University,  
Giza 11221, Egypt. Email: [ubiomahmoud@yahoo.com](mailto:ubiomahmoud@yahoo.com)

Department of Veterinary Hygiene, Environmental Pollution and Management,  
Faculty of Veterinary Medicine, Cairo University, Giza 11221,  
Egypt. Email: [drtamer2009@yahoo.com](mailto:drtamer2009@yahoo.com)

**Abstract:** The ascites syndrome (AS), also known as Pulmonary Hypertension Syndrome (PHS), can be a major problem in the poultry industry, especially in the case of poor-managed flocks. The results are slowing down the body growth and high outbreaks of mortality. The environmental temperature was found to have a profound and highly significant effect on the etiology and morbidity of ascites incidence. Zeolite and ionized water can act as an anti-stress factor and has positive effects on broiler chickens performance (decreased mortality rate, feed intake, feed gain, feed conversion, and body weight). The addition of micronized zeolite or ionized water in drinking water has been successful in alleviating the effects of various intestinal diseases, with its action against ascites in broilers.

**Keywords:** Broiler chickens, Poor Ventilation, Pulmonary Hypertension, Right Ventricular Failure, Ascites, Alleviation.

## Introduction

Ascites is an increase in the amount of lymph typically found in the peritoneal space. If there is an excess of protein in the glands or edema fluid, they may contain blocks or fibrin strands. Since edema liver is the height of lymph protein [1], accumulation of fluid in the peritoneal spaces liver diseases often contain fibrin. Fibrin elsewhere indicates vascular damage.

Bird has eight cavities [2], depending on the cause of ascites is usually found on a greater amount of fluid in the peritoneal spaces of abdomen and liver disease, in (pericardia bag) heart and intestines in the peritoneal space. Also may be found fluid in the peritoneal space right hepatic dorsal. There were no reports of fluid in the peritoneal space hepatic left dorsal. It can be found in very small amounts of liquid in the surrounding coeloma lung spaces, especially in birds with lung edema, but these are the tight spaces and do not tend to become swollen [3], [4].

It is not registered normal amount of fluid in the coelomic cavity, but with the exception of the pericardial sac, and is likely to be abnormal accumulation of any visible. Regular chicken meat type is often 1-3 ml of fluid in the pericardial

sac at 6-8 weeks of age, but any amount more than 4 ml is likely to be abnormal.

Ascites is not a disease, it is a mark or damage that may result from one or more of the four physiological changes that cause increased production or lowering the removal of lymph peritoneal [5].

Ascites syndrome has become one of the fastest emerging conditions that cause significant losses to the broiler chicken industry. Aetiopathology have not yet been identified, but is generally believed to be multifactorial. It agrees most workers in this field with Julian [1] [3] that the basic condition suffering birds are hypoxemia. This may be hypoxic hypoxaemia such as in high altitude disease [6], [7] due to poor ventilation giving a low oxygen concentration at sea level [8], or pre-existing respiratory system pathology [9] [10]. Anemic hypoxemia may be due to low hemoglobin levels (anemia) or abnormal hemoglobin inducing a reduced oxygen capacity in arterial blood [11] [12].

## Materials and Methods

### Experimental design

The effect of the ionized water and micronized zeolite on ascites incidence under poor environmental conditions was tested on a commercial broiler farm (Egypt). 1500 day-old Cobb male broiler chicks were divided into **five** groups (300 chicks of each). The birds were fed a basal diet (3500 kcal ME and 24% crude protein) from day one up to the age of 28 days. **The negative control group (G<sub>0</sub>)** was put under controlled conditions, whereas **the positive control group** put under poor environmental conditions. The trial subgroups 1, 2, 3 and 4 were separately supplemented with: G1; ionized water in drinking water at a rate of 5% micronized G2; zeolite at an inclusion rate of 1.5 kg/t feed, G3; micronized zeolite at an inclusion rate of 1.5 kg/t feed + ionized water in drinking water at a rate of 5% and G4; untreated. The duration of the trial was 42 days. The weight of the birds was recorded on days 7, 14, 28, 35 and 42. Mortality and observations of the birds were carried out daily. Ascites incidence was characterized by clinical signs (panting, gurgling sounds, cyanotic combs and wattles, excessive abdominal fluid accumulation) and mortality rates. The incidence of ascites was confirmed by post-mortem examination.

### Birds housing

The poultry building was on an experimental farm near Giza province, Egypt and consisted of two identical houses joined by a working area. The houses were each divided into 20 floor pens. The ambient temperature was thermostatically controlled, heat being provided by gas radiant heaters in the houses. Up to the age of 7 days the houses were not mechanically ventilated. Ventilation was carried out by fans extracting air on one side and vents automatically opening on the opposite side according to the speed of the fans.

House of the **positive experimental groups** was ventilated after 7 days according to the experimental requirements and continued to be mechanically unventilated in an attempt to produce a hypoxic hypoxemia in the birds, by reducing levels of oxygen in the air. The birds of the positive groups (experimental groups: G<sub>1</sub>, G<sub>2</sub>, G<sub>3</sub> and G<sub>4</sub>) were exposed in the cages to the ambient low temperature and poor ventilation; the temperature varied between a minimum of 15°C and a maximum of 20°C until 6 weeks of age with a mean of 17.5°C.

**The negative control group (G<sub>0</sub>)** was subjected to a step down temperature programme of 1°C per 2 days, starting from 32°C (day 1) down to 26°C (day 28). **Then** maintained at maximum daily temperature between 22 °C and 28°C with a mean of 25°C until 6 weeks of age. The lighting programme was 23 h light and 1h dark for all groups.

#### (1) Air measurements

Relative humidity was determined by recording hygrometers placed in each house. Oxygen levels were measured using an oxygen analyzer. Ammonia and carbon monoxide concentrations were made using a Kitasawa aspirating pump and appropriate detection tubes (detection limits 0.5 and 2 ppm, respectively).

### Histopathological Examination

Liver samples from birds fed on the control and contaminated diets were obtained to evaluate lesions and other abnormalities. Samples were obtained from the birds with intermediate weight in each cage (5 chickens from each group) and were fixed in 10% neutral buffered formalin solution, dehydrated in graded alcohol, and embedded in paraffin. Sections of 3 to 5 mm were obtained and stained with hematoxylin-eosin.

Two sections of liver tissue from each chick were examined by light microscopy for previously described lesions: vacuolar degeneration of hepatocytes; inter- and peribular inflammations; bile duct hyperplasia or hypertrophy, or both; and necrosis [13].

### Alleviating agents

1. The clinoptilolite zeolite powder: Clinofitsiso Pulver Product of-VITARING-biomedsystems GmbH, Germany.
2. Envirolite-Egypt (non toxic, contains various mixed oxidants predominantly hypochlorous acid and sodium hypochlorite [(HClO, ClO<sub>2</sub>, HClO<sub>3</sub>, HClO<sub>4</sub>, H<sub>2</sub>O<sub>2</sub>, O<sub>2</sub>, ClO<sup>-</sup>, ClO<sub>2</sub><sup>-</sup>, ClO<sub>3</sub><sup>-</sup>, O<sup>-</sup>, HO<sub>2</sub><sup>-</sup>, OH<sup>-</sup> - working substances), pH 2.5-3.5, ORP>1150mV, active chlorine ~500mg/l.

### Growth performance

Feed consumption (FC) throughout the experimental period (6 wks), feed efficiency (FE), and final Live body weight (LBW) as well as body weight gain were determined for each group separately [14].

### Statistical Analysis

Data were analyzed by using the GLIMMIX procedure of SAS software [15]. Tukey's test was used for multiple comparisons when a significant interaction was detected. All statements of significance were based on probability (P < 0.05).

paper. Number illustrations sequentially (but number tables



Fig.1: Micronized clinoptilolite zeolite powder. B: Envirolite reactor: [(HClO, ClO<sub>2</sub>, HClO<sub>3</sub>, HClO<sub>4</sub>, H<sub>2</sub>O<sub>2</sub>, O<sub>2</sub>, ClO<sup>-</sup>, ClO<sub>2</sub><sup>-</sup>, ClO<sub>3</sub><sup>-</sup>, O<sup>-</sup>, HO<sub>2</sub><sup>-</sup>, OH<sup>-</sup> - working substances), pH 2.5-3.5, ORP>1150mV, active chlorine ~500mg/l.

### Results and discussion

#### Performance

**Under cold environment** for the initial 30 days, the broilers did not show any obvious clinical signs of ascites in all groups. On Day 35 an outbreak of ascites was observed on the untreated broiler group under poor conditions (G<sub>4</sub>) with typical ascetic symptoms (such as gasping, show open beak

breathing, cyanosis of the comb and wattles, dullness and/or depression, abnormally slow heart rate and/or red abdominal skin with congested blood vessels and increased mortality rates up to 25% in untreated group as shown in Table 1. In the treated groups G<sub>1</sub>, G<sub>2</sub> and G<sub>3</sub>; the mortality rate was 1.2 %, 1% and 1.2% in the ionized water treated group, zeolite

treated group and ionized water + zeolite treated group, respectively. Whereas, the mortality rate in the environmentally controlled group (G<sub>0</sub>) was 1%. On Day 42 the outbreak of ascites was increased in the untreated broiler group under poor conditions (G<sub>4</sub>) with typical ascetic symptoms and increased mortality rates up to 60 %.

**Table 1: Effect of Low Temperature and Poor Ventilation on Broilers Performance.**

Low Temp. and Poor Ventilation			Control Group	
Z	I	Z+I	Untreated	Controlled Environment
<b>Day 7</b>				
138.50+2.7	142.33+3.9	138.50+2.7	142.33+3.	138.50+2.7
126.51+6.40	127.21+4.5	126.51+6.40	126.51+3.60	125.41+6.40
100.34+1.68	98.5+1.87	100.34+1.68	100.34+1.58	100.44+1.38
1.25	1.29	1.25	1.25	1.25
1.2%	1%	1.2%	1.2%	1%
<b>Day 14</b>				
409.1+4.8 b	408.1+4.8 b	409.1+4.86 b	407.1+4.8 b	408.1+4.8 b
374.3+7.50 a	372.3+8.50 a	370.3+9.50 a	370.3+7.30 a	372.3+7.50 a
268.76+5.13 b	267.76+5.13 b	269.76+5.13 b	263.76+5.13	269.76+8.13 b
1.40	1.40	1.40	1.40	1.40
1.2% b	1.2% b	1.2% b	2% c	0.5% a
<b>Day 21</b>				
880.42+4.5 b	890.42+4.5 b	870.42+4.5 b	840.42+4.5 a	880.42+4.5 b
570.90+2.14b	572.90+2.14b	584.90+2.14 a	564.90+2.14b	570.90+2.14b
444.84+5.72 b	454.84+7.82 b	464.84+5.82 a	434.84+5.82 b	444.84+5.72 b
1.32 b	1.32b	1.31 b	1.32 b	1.31 b
2%b	1%b	1.2%b	2%	1% b
<b>Day 28</b>				
1300.40+7.38 b	1299.50+8.48 b	1300.50+7.38 b	1174.50+7.38 a	1299.50+8.48b
1067.34+12.45 b	1077.20+11.65 b	1087.50+12.55 b	867.30+10.65 a	1067.34+12.45 b
455.08+13.68 b	445.06+14.68 b	455.08+13.68 b	355.08+13.68 a	445.06+14.68 b
2.3	2.31	2.3	2.32	2.31
1% b	2% b	1.2% b	5% c	1% b
2.3	2.31	2.3	2.32	2.31
1% b	2% b	1.2% b	5% c	1% b
<b>Day 35</b>				
1855.88+6.25 b	1835.78+7.45 b	1845.98+8.55b	1735.78+6.45 a	1835.78+7.45 b
976.78+10.42b	976.58+10.40b	899.68+10.33a	856.68+10.43c	976.58+10.40b
682.29+5.19 b	599.49+4.30 a	682.29+4.19 b	562.29+4.19 c	682.29+4.19 b
1.32b	1.35b	1.35b	1.44a	1.35b
1.2%b	1%b	1.2%b	25% c	1%b
<b>Day 42</b>				
2602.58+44.58b	2592.85+24.48 b	2602.78+24.58 b	2202.88+24.58 c	2692.85+24.48 b
925.66+23.52 b	925.86+26.42 b	925.86+22.52 b	725.86+23.52 c	925.86+26.42 b
667.07+22.86 b	677.12+24.66 b	667.07+22.88 b	467.07+22.86 c	677.12+24.66 b
1.81 b	1.81 b	1.81 b	1.8 b	1.81 b
7.2%a	4%b	3.2%b	60% c	1.5%b

Figures in the same row with different letters are statistically significantly different ( $P < 0.05$ )

- 1: Body weight (gm)
- 2: Feed Intake (g/bird)
- 3: Body weight gain (g/bird)
- 4: FCR

5: Mortality rate

In the treated groups, the mortality rate was 7.2%, 4% and 3.2% in the ionized water treated group, zeolite treated group and ionized water + zeolite treated group, respectively.

Whereas, the mortality rate in the environmentally controlled group was 1.5%, Table 1.

Results in treated group, showed that addition of the zeolite and ionized water supplementation improved significantly ( $P < 0.05$ ) performance (feed gain and feed conversion), increase final body weights and significantly reduce mortality rates as compared with the untreated group ( $G_4$ ). Broiler chicks in the environmentally controlled group ( $G_0$ ) recorded highest performance compared with the groups exposed to poor ventilation under low temperature, Table 1.

Furthermore, addition of the zeolite and ionized water affected positively the chicken performance under the stress of low temperature and poor ventilation similar to the bird performance parameters recorded in that environmentally controlled group.

**Table 2: Effect of Low Temp. and Poor Ventilation on Relative humidity and some gaseous parameters.**

Treatment Parameter	Low Temp. and Poor Ventilation			Controlled Environment	
	Z	I	Z+I	Untreated	
O <sub>2</sub> %	20.0-19.2	20.0-19.4	20	20.0-19.4	20.8- 20.7
NH <sub>4</sub> ppm	48 -50	50 - 70	50-52	50 - 70	5 -10
CO <sub>2</sub> %	3	1 - 5	1-4	2 - 5	Less than 1
CO %	-	-	-	-	-
RH%	78	70 -83	70-87	70 -83	65 -72

**Pathological lesions**

**Gross lesions**

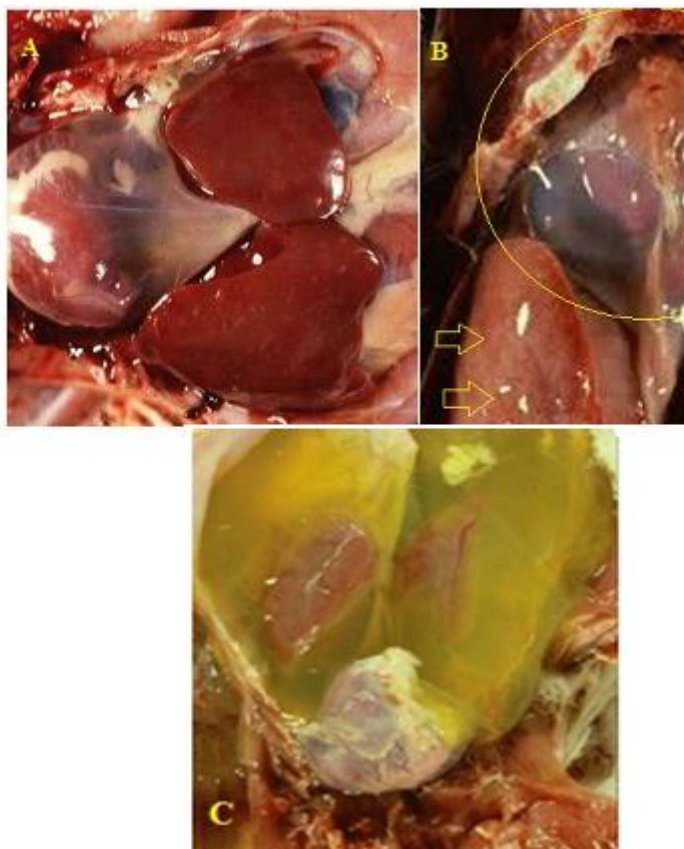


Fig.2 : A:The liver be swollen and congested, and irregular with edema, and have clotted protein adherent to the surface.

B:Hydropericardium is mild to marked, and occasionally there is pericarditis with adhesions. Right ventricular dilatation and mild to marked hypertrophy of the right ventricular wall. The right atrium and vena cava are markedly dilated in most cases.C: Collection of yellowish fluid in the coelomic cavity.

At post-mortem (Fig.2), there was a large or small quantity of clear yellow fluid and clots of fibrin in the abdomen. There was a variable amount of clear yellow fluid and clots of fibrin in the hepatoperitoneal spaces. The liver be swollen and congested, and irregular with edema, and have clotted protein adherent to the surface. Hydropericardium was mild to marked, and occasionally there was pericarditis with adhesions. Right ventricular dilatation and mild to marked hypertrophy of the right ventricular wall. The right atrium and vena cava are markedly dilated in most cases. The lungs are extremely congested and edematous. The intestine may or may not be empty. Swollen livers, characterized by rounding of liver margins with prominent hydropericardium are commonly seen on gross pathologic examination. The lungs are extremely congested and edematous.

**Histopathological Examination**

Hepatic histologic changes (hepatocytic degeneration/necrosis and hepatic capsule fibrosis) were seen in most cases of ascites as shown in Fig.3. There was dilation of periacinar sinusoids and atrophy of intervening hepatocytes. In addition there was a decrease in the amount of vacuolation of hepatocytes, and cholangioles are frequently filled with bile and in some casts hepatocyte necrosis was present.

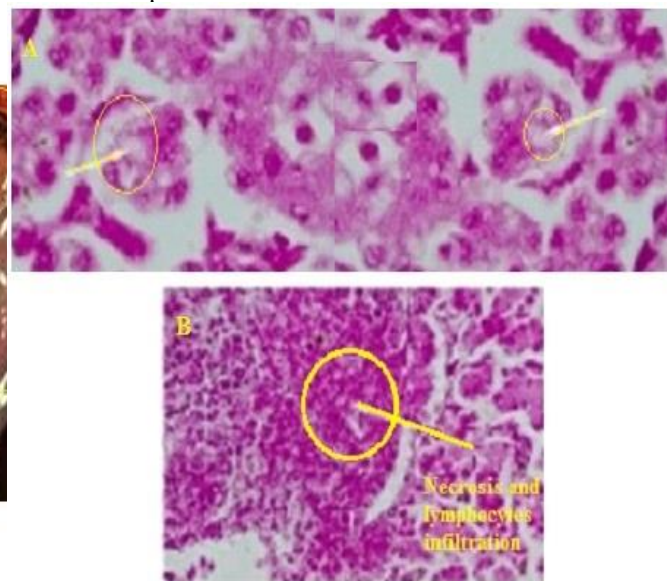
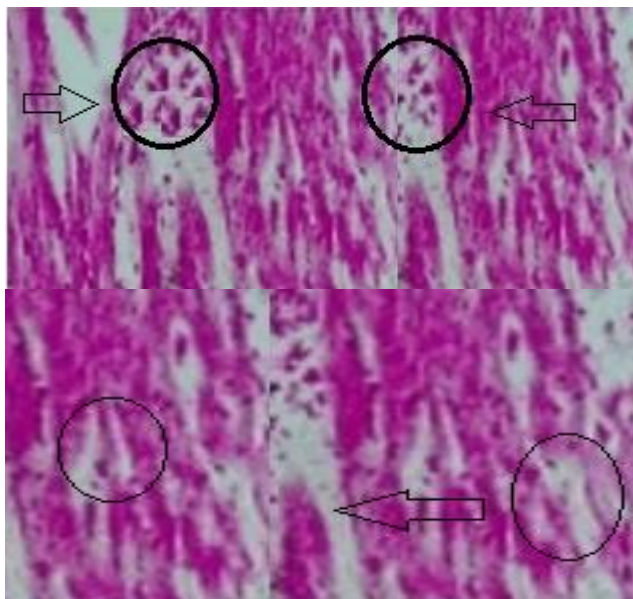


Fig.3: Hepatic histologic changes: A: Fatty degeneration in the liver (H&E staining, 400X) B: (hepatocytic degeneration/necrosis and hepatic capsule fibrosis) were seen in most cases of ascites also there is dilation of periacinar sinusoids and atrophy of intervening hepatocytes (H&E staining, 200X).

Cardiac histologic changes were seen in half cases (50%) in the recorded cases (Fig.4). Changes in the myocardium were mild. Edema of the myocardium and slight proliferation of loose connective tissue in some areas. Myocardial fibres showed pallor of cytoplasm and atrophy or hypertrophy, with variation in size of myofibres and their nuclei. Also,there was

an increase in the number of heterophils between myocardial fibres and fibrosis of the atrial endocardium.



**Fig. 4 :** Cardiac histologic changes :Cardiac myofibril degeneration and hemorrhageand Cardiac fatty degeneration in cardiac muscle cells (H&E staining,400X).

As shown in Table 2, the concentration of oxygen in the houses varied between 20 and 20.5%, compared with 20.5 % in the air outside the houses. Oxygen concentrations did not fall below 20 % and ammonia levels varied from 5 to 10 ppm. Thereafter, in controlled groups (well ventilated) oxygen levels reached a minimum of 20.7%, but were invariably 20.7 to 20.8%.

In un and treated groups, the oxygen concentration fell gradually to a minimum of 20 %, by day 12; by this time the air quality was very poor, with ammonia levels being about 60-70 ppm, relative humidity 80 to 90% and the birds suffering from coughing and smarting eyes.

In our experiment was tried, through the provision of a very bad ventilation, to obtain the concentration of oxygen, which would be a hypoxia. However, it was found that lower concentration of 19.4% with no detrimental effect physiological. In this class of poor ventilation, and the relative humidity in the house of poultry is very high, and garbage increasingly wet and prove concentrations were unacceptably high ammonia enough to be a serious inconvenience. There were no increase monoxide concentration of carbon under these conditions of poor ventilation and the figure was much lower than the 50 ppm recorded as being associated with ascites [12]. Ammonia, dust and humidity could also play a role, where a low concentration of oxygen and a high amount of ammonia were detected. High level of ammonia could predispose to AS/PHS since it reduces cilia motility favoring the appearance of respiratory diseases [16] [17]. The presence in polluted air of reactive oxygen species (superoxide radical, hydroxyl radical, hydrogen peroxide, peroxy radical, hypochlorous acid, nitrogen dioxide radical), that are responsible for lipid peroxidation [18], have been considered to have an important role in determining PH [19].

Inadequate ventilation, leading to concentrations reduced ambient oxygen, and the focus may be elevated from carbon dioxide and carbon monoxide, has been suggested as a catalyst for ascites [20] [9][21], although it was not what it seems to have been tested under controlled conditions. The only experimental data for examining this hypothesis seems to be that of Maxwell et al., [22]. It found that the temperature of the environment have a profound and very large effect on pathogens and diseases of the occurrence of ascites. Cold -mediated polycythaemia occurs, perhaps this is a manifestation of the launch Alkatikolamin induced stress which causes both re-fluid from the blood circulation, especially to the lungs [23].

It was noted that the recent increase in ascites both at high altitude and low for the more pronounced in cold weather [7] [8] [24]. Recent research shows that increase metabolism rate caused by the cold causes a marked increase in the need for oxygen and heart disease production resulting in a PH change.

This study suggests that in birds reared at low sanitary environmental conditions the addition of micronized zeolite (50 mg/kg) in the diet of broilers and ionized water (5ml/L) in drinking water has effect on growth and weight gain.

Our results confirm the finding of Agudelo [25], who observed that vitamin C supplementation of broiler diets reduced ascites incidence. Enkvetchakul *et al.* [26], and Al- AL-Tavpeil & Kassab [27], suggested that the reduction of ascites mortality may be a consequence of depression in antioxidant status by vitamin C supplementation [26]. Furthermore, [28], found higher plasma lipid peroxides and low concentrations of vitamin E in tissues of broilers with PHS.

The actual *Clinoptilolite Zeolite* molecule is shaped like a honey-comb and carries a natural negative (-) charge. When this type of Zeolite is ingested into the body all of the positively charged (+) heavy metals, toxins, and harmful chemicals bond with the zeolite and are flushed out. It provides protection against oxidative damage and maintains the endogenous antioxidant defense capacity [29]. Ammonia is a toxin that has no place in a healthy body. A healthy liver converts ammonia into urea, which is then eliminated in urine. A key benefit of dietary zeolite is its ability to directly remove ammonia, which means less stress on liver and kidneys

Electrochemically activated water (ECA-water) Hypothetical mechanisms of ECA-solutions' action on a cellular level. Water as a pure chemical substance or as a solvent of aqua-mineral media of mineralization no higher than ~ 5 g/l subjected to unipolar electrochemical treatment, metastable, possessing anomalous reactional and catalytic activity and relaxation electron-unbalanced (electron-donor or electron-acceptor) qualities. Action of ECA-solutions on cellular objects seems to be carried out in several conventional ways. Stable and metastable products of electrochemical synthesis directly affect lipid membranes, cell organoids and intracellular molecular complexes and chemical compounds. Oxidizing and reducing agents of ECA-solutions alter the ORP of peri- and intracellular media, thus regulating the

activity of endogenous biooxidants and bioantioxidants. Shifts of ORP gradient on biological membranes affect transfer of substances in the cell due to electroosmosis. Penetration of structurally altered water inside the cell activates aqueous media of cytoplasm and speeds up biochemical reactions taking place there. Oxidative phosphorylation reaction goes on according to the following formula:  $RN + NaClO \rightarrow ROH + NaCl$ , where R stands for organic radical, RH is organic hydrophobic compound, ROH – oxidative hydroxylation product. ROH derivatives are low toxic, hydrophilic and can be easily removed thanks to physiological excretion. It can be added that balance of anti-radical chain elements seems to be a necessary but insufficient prerequisite for efficient suppression of free radicals' activity, since electron transfer in accordance with the system: enzymatic oxidation products NADP-H glutathione ascorbate tocopherol, depends on the ORP value of fluid media, among which there is an anti-radical defense system. Catholyte is the only means of non-reagent shift of biological fluids ORP towards electron-donor values. Increased tissue reductive potential ( $\Delta ORP < 0$ ) stimulates the transfer of two hydrogen atoms from the substrate to NADP. At that, NADP is reduced: a proton and an electron add to a nicotine-amide radical, and another electron adds to its N-atom, which due to that loses its charge. A proton corresponding to this electron remains in the medium and raises its [H+] content. According to the findings of studying laboratory and agricultural animals, receiving catholyte for drinking, the following conclusions can be made.

The supplementation of feed with Clenbuterol [30], Atenolol, [31] and Aspirin [32],) have reduced the incidence of ascites

Dietary supplementation with zeolite or ionized water in drinking water is known to decrease the occurrence of pathogenic bacteria in the gastrointestinal tract thus improving the animals' health status. This was confirmed by the reduction of mortality rates in the trial group compared with the negative control and positive control groups. In this trial, the addition of zeolite to the feed was effective in alleviating the effect of **ascites** caused by microbial factors in broilers.

## Conclusion

The environmental temperature was found to have a profound and highly significant effect on the etiology and morbidity of ascites incidence. Dietary micronized zeolite contributes to environmental hygiene, with a continued function through either the feed or water into the animals' gastrointestinal tract. Zeolite and ionized water can act as an anti-stress factor and has positive effects on broiler chickens performance (decreased mortality rate, feed intake, increased feed gain, feed conversion, and body weight). The addition of micronized zeolite or ionized water in drinking water has been successful in alleviating the effects of various intestinal diseases, with its action against **ascites** in broilers.

## References

- [1] R. J. Julian, "The response of the heart and pulmonary arteries to hypoxia, pressure, and volume," *A short review*, *Poult Sci*, 86,pp,1006–1011,2007.
- [2] A.S. King, & J. Mclelland (1984). *Birds their Structure and Function*, 2nd ed (Eastbourne, Balliere-Tindall).
- [3] R.J. Julian "Are we growing them too fast? Ascites in meat-type chickens," *Highlights of Agricultural Research in Ontario*, 10, pp,27-30,1987.
- [4] A.J. Bezuidenhout, "Ascites and the anatomy of the peritoneal sacs of broilers," *Onderstepoort Journal of Veterinary Research*, 55, pp,23-25,1988.
- [5] Baghbanzadeh , Decuyper , "Ascites syndrome in broilers: physiological and nutritional perspectives," *Avian Pathol*, 37(2),pp,117-26,2008.
- [6] S. Cueva, H. Sillau, A. Valenzuela, H. Ploog, "High altitude induced pulmonary hypertension and right heart failure in broiler chickens," *Research in Veterinary Science*, 16,pp, 370-374,1974.
- [7] A. Hernandez, "Hypoxic ascites on broilers: A review of several studies done of Columbia," *Avian Dis*, 31,pp, 358–361,1987.
- [8] R.J. Julian, I. McMillan, M. Quinon, *Avian Pathology*, 18 (4), pp,675-684,1989.
- [9] F. Robert , JR Wideman, Yvonne Kochera Kirby Mohammad Ismail , Walter G. bottje , W. Robert Moore , C. Randy Vardeman , "Supplemental L-Arginine Attenuates Pulmonary Hypertension Syndrome (Ascites) in Broilers," *Oxford Journals Science & Mathematics, Poultry Science* ,74, Issue 2 pp, 323-330,1994.
- [10] R.J. Julian, "Pulmonary hypertension: a cause of right heart failure, ascites in meat-type chickens," *Feedstuffs*, 29, pp,19-22,1990.
- [11] J.P. Peters, D.D. van Slke, "Quantitative Clinical Chemistry: Interpretations," 2<sup>nd</sup> ed., vol. I, pp 344,345. Baltimore: Williams and Wilkins Co. 1946.
- [12] R.J., Julian, J. Summers, J.B. Wilson, "Right ventricular failure and ascites in broiler chickens caused by phosphorus-deficient diets," *Avian Diseases*, 30, pp,453-459, 1986.
- [13] I. Pandey, S. S. Chauhan, "Studies on production performance and toxin residues in tissues and eggs of layer chickens fed on diets with various concentrations of aflatoxin AFB1," *Br Poult Sci*, 48,pp,713-723, 2007.
- [14] J.J.R., Feddes, E.J. Emmanuel, M.J. Zuidhof, "Broiler performance, body weight variance, feed and water intakes, and carcass quality at different stocking densities," *Poultry Science*, 81, pp,774 – 779, 2002
- [15] SAS Institute, 1988. *SAS/STAT\_ User's Guide*. 1988 Edition. SAS Institute Inc., Cary, NC.
- [16] M. Coletti, M.P. Franciosini., R. Galli , B. Tesei., M.E. Rossodivita, G. Asdrubali, C.G.T. Sannipoli , *Zootecnica International*, 6(3),pp, 65-74,1990.
- [17] M. Terzich., C. Quarles, M.A. Goodwin, J. Brown, *Avian Diseases*, 42(2), pp, 385-387, 1998.
- [18] C.E. Cross, A. Van der Vleit, C.A. O' Neill, J.P. Eiserich , *Lancet*, 344(8927), pp,930-933,1994,19994.
- [19] W.B. Bottje, R.F. Jr. Wideman , *Poultry and Avian Biology Reviews* , 6,pp, 221-231,1995.
- [20] N.M. Dale., A Villacres, Georgia Nutrition Conference, Athens, GA., 75-79,1986.
- [21] M.M. Ahmad., R.E. Moreng, H.D. Mueller," Breed responses in body temperature to elevated environmental

temperature and ascorbic acid,” *Poultry Science*, 46,pp, 6-15,1967

[22] M.H Maxwell, S Spence, G.W Robertson, M.A Mitchell, “Haematological and morphological responses of broiler chicks to hypoxia,” *Avian Pathology*, 19,pp, 23-40,1990.

[23] A. Shlosberg, E Berman, U. Bendheim, I. Plavnik, “Controlled early feed restriction as a potential means of reducing the incidence of ascites in broilers,” *Avian Diseases*, 35,pp, 681-684,1991.

[24] A. Shlosberg , U. Zadikov , V Bendheim , I Handj , E. Berman , “ The effects of poor ventilation, low temperatures, type of feed and sex of bird on the development of ascites in broilers,”physiopathological factors, *Avian Pathology*, 21:3, pp,369-382,1992.

[25] L.G. Agudelo, “Possible causes of avian oedema,” *Poultry International*, 22, pp,8-14, 1983.

[26] B.Enkvetchakul, W Bottje, N Anthony, R. Moore, “ Compromised antioxidant status associated with ascites in broilers,” *Poultry Science*, 72,,pp, 2272-2280,1993.

[27] R.N. AL-Tavpeil, A. Kassab, “ Effect of dietary vitamin C on ascites in broiler chicks,” *International Journal of Vitamin and Nutrition Research*, 60, pp,307-313,1990

[28] W. Bottje,B. Enkvetchakul, R. Moore, R. McNew, *Poultry Science*, 74(8),pp, 1356-1369, 1995.

[29] R. J Gau, H. L Yang, J. L. Suen, F.Lu, “Induction of oxidative stress by humic acid through increasing intracellular iron; a possible mechanism leading to atherothrombotic vascular disorder in black foot disease,” *J Biochem Biophys Res Commun*, Vol 283( 4), pp,743-749,2002.

[30] L. Ocampo, U. Cortez, H. Sumano, E. Avial, “Use of low doses of Clenbuterol to reduce the incidence of ascites syndrome in broilers,” *Poultry Science* , 77,pp,1297-1299,1998.

[31] M. Hassanzadeh, J. Buys, E. Decuyper., “ Further evidence for the involvement of the cardiac I2 adrenergic receptors in right ventricle hypertrophy and ascites in broiler chickens,” *Avian Pathology*,31,pp,177-181, 2002.

[32] J.M. Balog, G.R. Huff, N.C. Rath, W.E. Huff, “ Effect of dietary aspirin on ascites in broilers raised in hypobaric chamber,” *Poultry Science*; 79,pp,1101-1105, 2000.