

Safety and Efficacy of Supracostal Access in Percutaneous Renal Surgery

A. SHABAN, M.D., A. KODERA, MD, MOHAMED N. ELGHONEIMY, M.D., T.Z. ORBAN, M.D.,
K. MURSI, M.D., and A. HEGAZY, M.D.

ABSTRACT

Background and Purpose: During percutaneous renal surgery, subcostal access is preferred because it carries no risk of injury to either the lungs or pleura. However, in some situations, a supracostal approach may provide more direct access and achieve a more satisfactory result than the subcostal approach. In this prospective study, we evaluated the safety and efficacy of supracostal approaches in percutaneous renal surgery.

Materials and Methods: Between 2004 and 2006, 30 patients underwent percutaneous renal surgery with a supracostal approach either as the sole or as a secondary access. The indications were staghorn stones, upper caliceal stones, upper ureteral stones, secondary ureteropelvic junction obstruction, disturbed lower caliceal anatomy, and high-lying kidneys. The puncture was above the eleventh rib in six procedures and above the twelfth rib in 24 procedures. All patients were examined for equal air entry on both sides of the chest, and all had chest radiography performed immediately after surgery to exclude pneumothorax or hydrothorax. Bleeding was assessed with evaluation of preoperative and postoperative hemoglobin, levels and vital signs; urine was also examined for gross hematuria. A routine nephrostogram was obtained for all patients.

Results: Supracostal was the sole access in 63.3% of patients and a secondary access in 36.7% of patients. Intraoperatively, bleeding occurred in one patient. Hydrothorax in another patient necessitated insertion of an intercostal chest drain. A renopleural fistula developed in another patient 2 days postoperatively that necessitated placement of a chest drain and Double J stent. Access in both patients with pleural complications had been above the eleventh rib. The mean drop in hemoglobin level was 0.79 ± 0.72 g/dL. Our overall stone-free rate was 88.9%.

Conclusion: Supracostal access above the twelfth rib is relatively safe; however, access above the eleventh rib should be limited to necessity because a higher incidence of pleural complications can be expected. A chest radiograph should be obtained immediately postoperatively for early detection of hydrothorax or pneumothorax.

INTRODUCTION

THE PERCUTANEOUS APPROACH to the kidney has advanced to a remarkable degree since the first percutaneous nephrostomy was performed by Goodwin and colleagues¹ in 1955. In addition to its use in nephrolithotomy, percutaneous renal access is often used for the management of ureteropelvic junction (UPJ) obstruction, proximal ureteral stricture, and upper collecting system tumors. Obtaining intrarenal access through an appropriate calix is essential for satisfactory results.

The traditional subcostal access is preferred in percutaneous renal surgery to avoid injury to the lungs and pleura.²

However, in some patients, such as those with upper caliceal stones, impacted upper ureteral stones, staghorn calculi, and in obtaining access to the UPJ, the supracostal approach may be the most direct means to achieve a satisfactory result. In such cases, the subcostal approach may fail to provide optimal access.

The supracostal approach used to be avoided for fear of potential chest complications. However, knowledge of the pleural and diaphragmatic anatomy and refinement of the surgical technique have reduced these complications to a minimum.³ Early recognition of pleural injury is critical, and the injury can be managed with relatively low morbidity.⁴

PATIENTS AND METHODS

Between 2004 and 2006, 30 patients in our institution had percutaneous renal surgery performed through a supracostal access. This access was chosen because the traditional subcostal approach was deemed unsatisfactory and we believed that the supracostal one would achieve a more direct approach and a more satisfactory result. Other patients had percutaneous nephrolithotomy (PCNL) performed through a subcostal access for the same or other routine indications, if this approach was considered satisfactory. A comparison is not the aim of this study and might be presented in other studies. The mean age of these patients was 33.9 ± 11 years. There were 25 men and 5 women.

The indications were:

- Large upper caliceal stones (stone burden = 2 cm) (Fig. 1).
- Staghorn and branched kidney stones.
- Secondary UPJ obstruction.
- Stones in the upper ureter with failure of other treatment modalities (such as failed shockwave lithotripsy [SWL]).
- Disturbed lower caliceal anatomy because of chronic pyelonephritic changes or previous surgery.
- High-lying kidneys (Fig. 2).

The distribution of these indications is shown in Table 1.

We excluded from the study patients who were unfit for general anesthesia, patients with an uncontrollable coagulation dis-

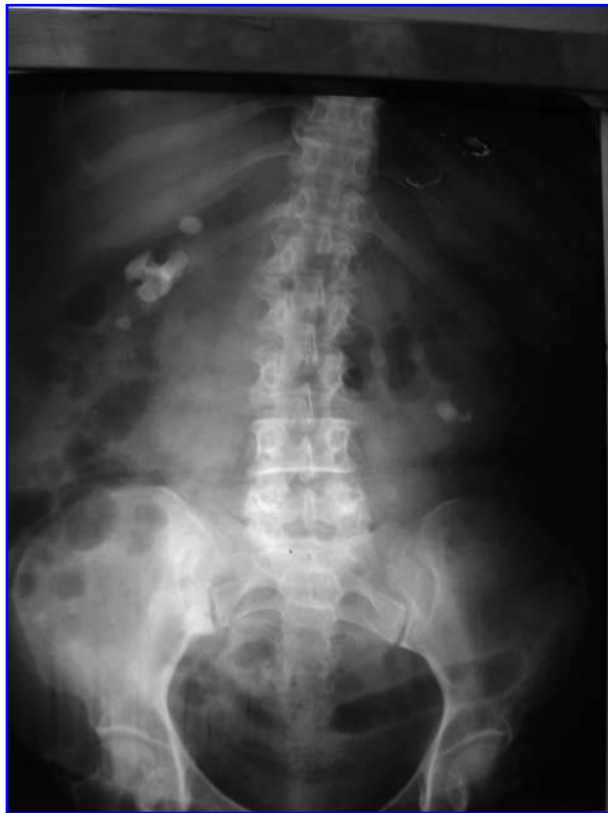

FIG. 1. Radiograph shows large upper caliceal stones.

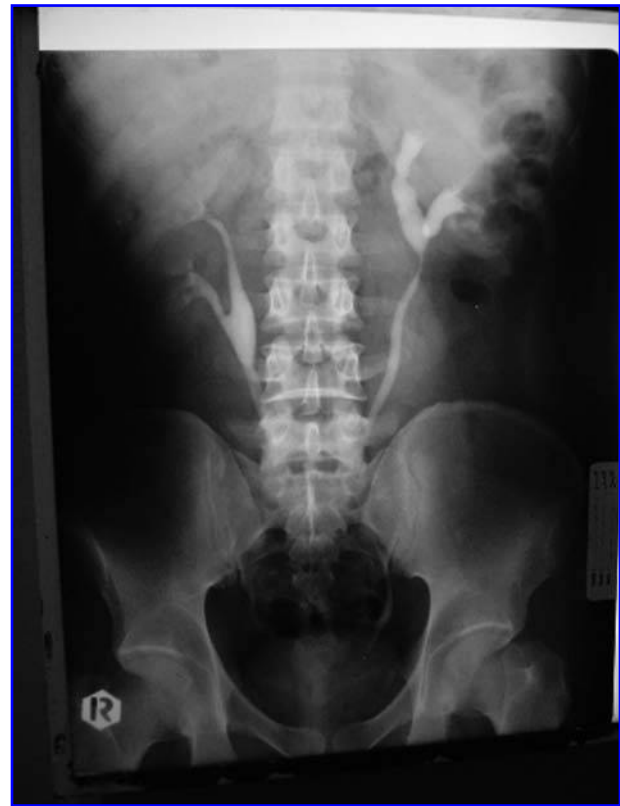

FIG. 2. High-lying kidneys: Lower calyx is above the level of the costal margin.

order, patients with extreme obesity (when the distance between the skin and the kidney was expected to exceed the working length of the nephroscope), and patients with active pulmonary or pleural disease.

After induction of general anesthesia, the patient was placed in the lithotomy position and a ureteral catheter was inserted. The patient was then turned to the prone position, and retrograde installation of dye through this catheter was used to select an appropriate calix to be punctured under fluoroscopic guidance.

The puncture was performed above the eleventh rib in six procedures and above the twelfth rib in 24 procedures. The puncture was always in the lateral half of the intercostal space.

TABLE 1. INDICATIONS FOR THE SUPRACOSTAL APPROACH

Indications	Frequency	Percent
Upper caliceal stones	8	26.7
Large stone burden	11	36.7
Narrow neck of lower calix	1	3.3
Upper ureteral stones	6	20
Abnormal renal anatomy (high-lying kidneys)	1	3.3
Secondary UPJ obstruction	3	10
Total	30	100

UPJ = ureteropelvic junction.

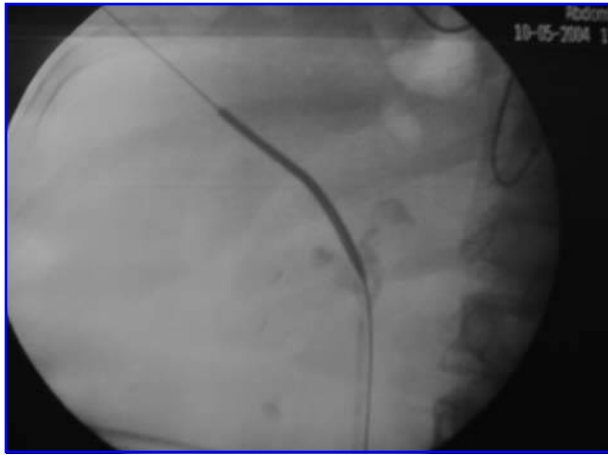


FIG. 3. A guidewire is passed down the ureter.

The puncture was always made during breath holding in full expiration, and the needle was advanced immediately above the upper border of the rib to avoid the intercostal vessels.

Once the collecting system was entered, a guidewire was passed and manipulated down the ureter (Fig. 3). After the passage of the first guidewire, a safety guidewire was placed using a double lumen catheter.

For the patients in whom we believed a second puncture was necessary for complete stone clearance, we preferred to pass another guidewire at this stage of the procedure to be used later for the creation of a second access tract.

Subsequently, our access tract was dilated first using the fascial dilators, and then continuing with the standard Alken dilators until an Amplatz sheath was placed. The stones were extracted by an alligator grasper or disintegrated by a standard pneumatic EMS Swiss LithoClast® before extraction by grasper. After stone removal, careful inspection of the accessible calices, the renal pelvis, and the UPJ was performed to exclude the presence of residual stones, injury, or edema of the UPJ. Fluoroscopy was also used to check for any residual stones.

Retrograde pyelography was performed with closure of Amplatz sheath to check the integrity of the pelvicaliceal system. A 28F Nelaton catheter was then inserted through the Amplatz sheath into the renal pelvis.

In cases in which endopyelotomy was planned—alone or after management of the stones—the incision was made under vision using the cold knife incision in the lateral position until the fat was visualized. A Double J ureteral stent (8F) was then passed in an antegrade fashion down the ureter into the bladder.

All patients were examined at the end of the procedure for equal air entry on both sides of the chest, and adequate oxygen saturation was confirmed. Chest radiography was also performed immediately after surgery to exclude pneumothorax or hydrothorax. In the immediate postoperative period, patients were observed for signs of bleeding by recording the vital signs and observing the urine output for gross hematuria. Preoperative and postoperative hemoglobin level and hematocrit were measured, and any drop in hemoglobin level was recorded.

Pain related to respiration or pain at the site of the tract was observed. Stone clearance was assessed on by plain abdominal

radiography 1 or 2 days after surgery. The nephrostomy tube was removed when hematuria resolved. A routine nephrostogram was obtained in all patients (Fig. 4).

Successful stone removal was defined as complete clearance of the stone. Insignificant residuals were defined as residual fragments <2 mm.

RESULTS

In our 30 patients, the surgery was on the right side in 16 and on the left side in 14. Renal access was obtained above the twelfth rib in 24 procedures and above the eleventh rib in six. Operative time ranged between 45 minutes and 120 minutes, with a mean of 66.43 ± 29.03 minutes.

In this study, 27 renal units were managed by percutaneous renal surgery for stone clearance and three units for secondary UPJ obstruction. A renal unit was considered stone free when the postoperative radiograph of kidneys, ureters, and bladder (KUB) showed no or clinically insignificant stone fragments (<2mm). Twenty-four renal units were rendered free of stone material (88.9%), as evidenced by intraoperative fluoroscopy and postoperative KUB radiography and/or ultrasonography.

Of the 11 patients treated for staghorn stones, eight were cleared and three required SWL later (our only three patients with residual stones).

Nineteen procedures (63.3%) were completed with a single puncture and 11 procedures (36.7%) were completed with two punctures, one of which was supracostal and the other was either through the middle area or the lower calix because of staghorn stones. In this study, all renal units were managed by single-session percutaneous renal surgery.

Intraoperative bleeding occurred in one patient at the end of the percutaneous session. He had multiple stones in his left kidney, which necessitated two punctures for clearance. Bleeding occurred because of injury of the lower caliceal infundibulum during dilatation of the second puncture. This was a complication of the standard and not the supracostal access; the upper calix in most of our procedures did not require any dilation and

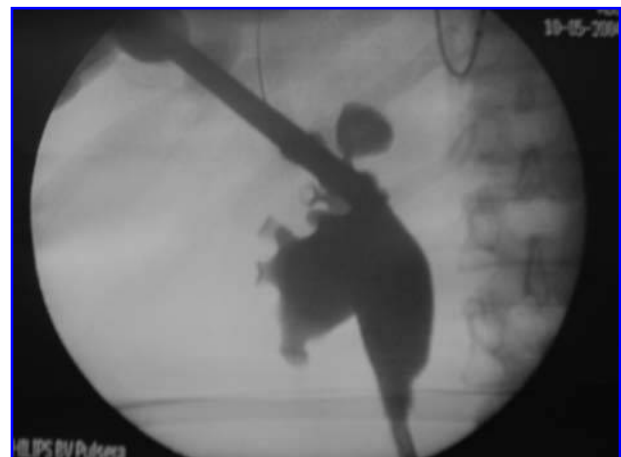

FIG. 4. Post-operative routine nephrostogram.

TABLE 2. DURATION OF TUBES AND HOSPITAL STAY

	<i>Minimum (days)</i>	<i>Maximum (days)</i>	<i>Mean (days)</i>
Nephrostomy tube	2	5	2.4
Ureteral catheter	2	6	3.5
Hospital stay	2	10	3.7

was wide enough to admit the nephroscope. Blood transfusion was needed, but the procedure was completed.

This was the only patient in whom there was a significant drop in hemoglobin level. In the rest of the study patients, the mean change in hemoglobin was 0.79 ± 0.72 g/dL.

Early postoperative complications developed in two patients. Hydrothorax, which developed in one patient, was suspected intraoperatively and confirmed immediately postoperatively. An intercostal chest tube was inserted for 48 hours. The ureteral catheter was kept in place until the hydrothorax resolved. A high-grade fever developed postoperatively in one patient. The fever subsided with conservative management.

In one patient, complications were delayed. A renopleural fistula was diagnosed 2 days postoperatively. Fever, dyspnea, and chest pain occurred in this patient. Chest radiography showed moderate left-sided pleural effusion. An antegrade nephrostogram revealed that one side-hole of the nephrostomy tube was outside the kidney, and leakage was occurring freely in the pleural cavity. A chest tube and a Double J stent were placed, and the nephrostomy tube was removed. Follow-up of the patient by chest examination and chest radiography showed that the effusion resolved after 3 days. The patient was discharged with the Double J stent, which was removed 6 weeks later. Visceral injury, pneumothorax, and significant bleeding because of injury to intercostal vessels were not seen in any patient (Tables 2 and 3).

DISCUSSION

Percutaneous renal surgery is an essential procedure for managing a number of renal and ureteral conditions that are not amenable to other management options. The supracostal approach has the advantage of providing direct access to upper pole calculi, the UPJ, and the proximal ureter. It also allows the

TABLE 3. INCIDENCE OF COMPLICATIONS

<i>Complication</i>	<i>Number</i>	<i>Percent</i>
Intraoperative bleeding	1	3.3
Pleural effusion	1	3.3
Postoperative high fever	1	3.3
Renopleural fistula	1	3.3
Total	4	13.3

surgeon to manipulate the nephroscope along the longitudinal access of the kidney, which causes less torque by the rigid nephroscope and ultimately causes less bleeding.

The upper pole of the kidney lies anterior to the posterior part of the eleventh and twelfth ribs. During exhalation, the lower limit of the parietal pleura crosses the ribs obliquely, such that the lateral portion of the twelfth rib is inferior and lateral to the lower limit of the pleura.⁵ If the collecting system is entered via a supracostal puncture over the lateral portion of the twelfth rib, this will avoid potential pleural injury.

Supracostal access is associated with a higher incidence of intrathoracic complications because of the anatomic relations of the kidney. For this reason, some have argued against entry above the twelfth rib, while others have stated that entry above the eleventh rib should be entirely avoided.⁶

The supracostal approach continues to be used because it provides better access to the upper renal collecting system and the proximal ureter. In our study, we targeted the upper pole calix, which lies above the eleventh and twelfth ribs and was not accessible through a subcostal access. Our overall intrathoracic complications rate was 6.6%. Other studies that have used the supracostal approach for percutaneous renal surgery reported a complication rate varying from 0% to 12%. A comparison of various published series is shown in Table 4.

Although we believed that most pleura-related complications should be identified intraoperatively or during the early postoperative period, a nephropleural fistula was identified a few days postoperatively as a unilateral pleural effusion that compromised respiratory functions.

Our results imply that the more cranial the location of the percutaneous nephrostomy tract, the greater the risk of intrathoracic complications. There is a great difference between the supra twelfth rib approach, which is transthoracic but extrapleural, and the supra eleventh rib access, which is both

TABLE 4. INTRATHORACIC COMPLICATIONS ASSOCIATED WITH SUPRACOSTAL RENAL ACCESS AND/OR RENAL SURGERY

<i>Published work</i>	<i>No. of supracostal access complications/total no. (%)</i>		
	<i>Supra 11th rib</i>	<i>Supra 12th rib</i>	<i>Totals</i>
Younging <i>et al.</i> , 1985 ¹⁰	0/2	3/22 (13.6)	3/24 (12.5)
Forthyth and Fuchs, 1987 ¹¹	2/2 (100)	1/94 (1.1)	3/96 (3.1)
Narasimhan <i>et al.</i> , 1991 ¹²	2/3 (66.7)	3/53 (5.7)	5/56 (8.9)
Lashley and Fuchs, 1998 ¹³	4/15 (26.7)	12/152 (7.9)	16/167 (9.5)
Munver <i>et al.</i> , 2001 ⁷	6/26 (23.1)	1/72 (1.4)	7/98 (7.1)
Nitin <i>et al.</i> , 2001 ³	Not available	10/102 (9.8)	10/102 (9.8)
Gupta <i>et al.</i> , 2002 ²	Not available	4/63 (4.03)	4/63 (4.03)
Our work	2/6 (33.3%)	0/24 (0%)	2/30 (6.7%)

trans thoracic and transpleural.⁷ In our study, both pleural-related complications occurred after a supra eleventh rib approach. One was on the right side and the other was on the left side.

We thought that access above the eleventh rib would produce a higher percentage of complications on the left side because of the higher position of the left kidney. But because the anatomy of the lung and pleura is identical on both sides, once the choice is made, we think the incidence of complications should be the same. Because of the small number of the punctures above the eleventh rib, we cannot draw solid conclusions regarding this issue.

Our stone-free rate after PCNL was 88.9%; this is comparable to the stone-free rate of other studies, such as the 87% rate reported by Golijanin and coworkers⁸ for staghorn calculi. Only 36.7% of our patients had complex or staghorn calculi. In our study, an additional puncture for the middle caliceal extension of the staghorn stones was needed in most cases. Other series reported only a 58% rate of additional punctures with nearly similar stone-free rates for staghorn stones.²

For percutaneous renal surgery, the size and the location of the lesion and its relation to the anatomy of the upper urinary tract must be considered. The access route chosen must be individualized based on the clinical scenario, surgical expertise, and the available facilities to manage any complications related to the procedure.

When the supracostal approach is used, complications may be limited by positioning an Amplatz sheath well into the collecting system and placing a well-draining nephrostomy tube to minimize the leakage of urine into the pleural space. The puncture should be made during breath holding in full expiration and should avoid the lower rib margin to avoid the intercostal vessels. The puncture should be over the lateral half of the rib and should always be kept below the tenth rib.

Routine chest radiography should be performed early in the postoperative period to detect any complications. Whenever a chest collection is seen, a chest drain with an underwater seal should be inserted.⁹

CONCLUSION

The supracostal approach to percutaneous renal surgery is an important modification of the traditional approach to the kidney. The supracostal approach above the twelfth rib provides a relatively safe access, when subcostal angulation is not feasible. This approach has the advantage of managing complex renal stones and proximal ureters; calculi, as well as providing endoscopic management of UPJ obstruction.

Supracostal access above the eleventh rib should be performed only by surgeons with expertise in obtaining the access and when the benefits outweigh the increased risk of intrathoracic complications. Appropriate patient counseling regarding

the inherent risks and potential solutions for managing complications should be provided. Chest radiography immediately after surgery is mandatory.

REFERENCES

1. Goodwin WE, Casey WC, Wolf W. Percutaneous trocar (needle) nephrostomy in hydronephrosis. *JAMA* 1955;157:891.
2. Gupta R, Kumar A, Kapoor R, Srivastava A, Mandhani A. Prospective evaluation of safety and efficacy of the supracostal approach for percutaneous nephrolithotomy. *BJU Int* 2002;90:809–813.
3. Kekre NS, Gopalakrishnan GG, Gupta GG, Abraham BN, Sharma E. Supracostal approach in percutaneous nephrolithotomy: Experience with 102 cases. *J Endourol* 2001;15:789–791.
4. Lallas CD, Delvecchio FC, Evans BR, Silverstein AD, Preminger GM, Auge BK. Management of nephropleural fistula after supracostal percutaneous nephrolithotomy. *Urology* 2004;64:241–245.
5. Preminger GM, Schultz S, Clayman RV, Curry T, Redman HC, Peters PC. Cephalad renal movement during percutaneous nephrostolithotomy. *J Urol* 1987;137:623–625.
6. Fuchs EF, Forsyth MJ. Supracostal approach for percutaneous ultrasonic lithotripsy. *Urol Clin North Am* 1990;17:99–102.
7. Munver R, Delvecchio FC, Newman GE, Preminger GM. Critical analysis of supracostal access for percutaneous renal surgery. *J Urol* 2001;166:1242–1246.
8. Golijanin D, Katz R, Verstandig A, Sasson T, Landau EH, Merytyk S. The supracostal percutaneous nephrostomy for treatment of staghorn and complex kidney stones. *J Endourol* 1998;12:403–405.
9. Maheshwari PN, Chapade DK, Andankar HG. Comment on "Supracostal approach in percutaneous nephrolithotomy experience of 102 cases." *J Endourol* 2003;17:529–530.
10. Young AT, Hunter DV, Castaneda-Zuniga WR, Hulbert JC, Lange P, Reddy P, Mercado S, Amplatz K. Percutaneous extraction of urinary calculi: Use of the intercostal approach. *Radiology* 1985;154:633–638.
11. Forsyth MJ, Fuchs EF. The supracostal approach for percutaneous nephrostolithotomy. *J Urol* 1987;137:197–198.
12. Narasimham DL, Jacobsson B, Vijayan P, Bhuyan BC, Nyman U, Holmquist B. Percutaneous nephrolithotomy through an intercostal approach. *Acta Radiol* 1991;32:162–165.
13. Lashley DB, Fuchs EF. Urologist-acquired renal access for percutaneous renal surgery. *Urology* 1998;51:927–931.

Address reprint requests to:
 Mohamed N. El Ghoneimy, M.D.
 Cairo University
 14 Abed El Hady St., El Manial
 Cairo, Egypt 11451

E-mail: mghon@hotmail.com

ABBREVIATIONS USED

PCNL = percutaneous nephrolithotomy; SWL = shock-wave lithotripsy; UPJ = ureteropelvic junction.

This article has been cited by:

1. Pankaj N. Maheshwari , Deepakkumar A. Mane , Ashish B. Pathak . 2009. Management of Pleural Injury After Percutaneous Renal Surgery. *Journal of Endourology* **23**:10, 1769-1772. [[Abstract](#)] [[PDF](#)] [[PDF Plus](#)]
2. Gary J. Faerber. 2009. Editorial Comment. *Urology* **74**:4, 755-756. [[CrossRef](#)]