

The Journal of Laryngology & Otology

<http://journals.cambridge.org/JLO>

Additional services for *The Journal of Laryngology & Otology*:

Email alerts: [Click here](#)

Subscriptions: [Click here](#)

Commercial reprints: [Click here](#)

Terms of use : [Click here](#)



Comparative study of management of inferior turbinate hypertrophy using turbinoplasty assisted by microdebrider or 980 nm diode laser

A N Kassab, M Rifaat and Y Madian

The Journal of Laryngology & Otology / Volume 126 / Issue 12 / December 2012, pp 1231 - 1237

DOI: 10.1017/S0022215112002320, Published online:

Link to this article: http://journals.cambridge.org/abstract_S0022215112002320

How to cite this article:

A N Kassab, M Rifaat and Y Madian (2012). Comparative study of management of inferior turbinate hypertrophy using turbinoplasty assisted by microdebrider or 980 nm diode laser. The Journal of Laryngology & Otology, 126, pp 1231-1237
doi:10.1017/S0022215112002320

Request Permissions : [Click here](#)

Comparative study of management of inferior turbinate hypertrophy using turbinoplasty assisted by microdebrider or 980 nm diode laser

A N KASSAB¹, M RIFAAT², Y MADIAN²

¹Otorhinolaryngology Unit, Department of Medical Laser Applications, National Institute of Laser Enhanced Sciences, Cairo University, and ²Otorhinolaryngology Department, Faculty of Medicine, Suez Canal University, Ismailia, Egypt

Abstract

Objective: This study aimed to compare the outcomes of turbinoplasty assisted by microdebrider and by diode laser (980 nm wavelength).

Methods: Forty patients suffering from bilateral nasal obstruction were randomly divided into two equal groups. One group was managed with microdebrider-assisted turbinoplasty and the other with diode laser assisted turbinoplasty. The patients were followed up for six months post-operatively.

Results: After six months, total success rates were 90 per cent for the microdebrider group and 85 per cent for the diode laser group. There were no significant differences between the two groups regarding success rate, post-operative complications or operative time.

Conclusion: These two techniques are equally safe, reliable, successful and non-invasive.

Key words: Turbinate; Nasal Cavity; Diode Lasers; Rhinitis; Hypertrophy; Otorhinolaryngologic Surgical Procedures

Introduction

Nasal obstruction is one of the most frequent symptoms encountered by otorhinolaryngological surgeons. Hypertrophy of the inferior turbinates is the most common, and often only, triggering factor.^{1–4} Enlargement of the nasal turbinates can be due to either mucosal or bony hypertrophy, and surgery is usually reserved for bony abnormalities or cases in which mucosal congestion is unresponsive to topical vasoconstriction.⁵ Enlargement of the erectile mucosa of the inferior nasal concha significantly increases nasal airway resistance, contributing greatly to symptoms of nasal airway obstruction. Common belief ascribes most of the enlargement of the inferior nasal concha to mucosal elements. However, Fairbanks stated that such enlargement involves the bone as well as the mucosa, and reported that the inferior nasal concha becomes thicker and spongier and arches further medially into the airway.⁶ A study of the nasal valve confirmed that most nasal resistance occurs at the level of the anterior end of the inferior nasal concha.⁷

Chronic nasal obstruction restricts the patient's nasal breathing. The usual treatment is decongestant nasal drops. However, extensive use of nasal decongestants often leads to damage of the nasal mucosa.^{8,9}

Therefore, conservative therapy is restricted to decongestion with antihistamines, topical and systemic steroids, allergen avoidance, and specific immunotherapy involving hyposensitisation.¹⁰ Since these treatment modalities last only for a short period, surgery is necessary in many cases.¹¹

A review by Hol and Huizing evaluated a variety of surgical treatments for the reduction of hyperplastic inferior nasal turbinates, and concluded that most of these techniques provided satisfactory results although their duration of effect varied.¹² However, no technique is perfect, and each is associated with known short- and long-term complications such as post-operative bleeding, crusting, foul odour, pain, hyposmia and synechia.^{4,13–15}

With the introduction of microdebriders to rhinosurgery by Setcliff and Parsons, many surgeons began to perform submucosal resection during inferior turbinoplasty, utilising the advantages of the powered system.¹⁶ The common complications of standard submucosal resection of the inferior turbinates (e.g. excessive resection, post-operative bleeding and crusting) were largely avoided. In addition, this technique of turbinate reduction has been shown to be reliable, safe and mucosa-sparing.^{17–19}

Endonasal laser surgery techniques were first applied to inferior turbinate surgery by Lenz in 1977.²⁰ The principal use was the treatment of nasal turbinates in patients with vasomotor rhinitis, and the main advantage was reduced mucosal bleeding.²¹ Now, there are many published studies assessing the value of different laser systems for the treatment of hyperplastic inferior nasal turbinates. As a result, many different findings, and interpretations thereof, have been reported and summarised in comparative reviews.^{22–25}

In the present study, we aimed to compare the clinical efficacy of diode laser (one of the most popular laser types for turbinate ablation) versus endoscopic microdebrider (a convenient and minimally invasive method), for inferior turbinoplasty.²⁶ To our best knowledge, such a comparison has not previously been conducted.

Materials and methods

This study was conducted in the Otorhinolaryngology Department, Suez Canal University Hospital, Ismailia, in association with the Otorhinolaryngology Unit, Department of Medical Laser Applications, National Institute of Laser Enhanced Sciences, Cairo University, Egypt. Before conducting the study, detailed information about the treatment was related to the patients, and full, written consent was obtained from all patients. The study was approved by the Suez Canal University Ethical Committee.

This study included 40 adult patients complaining of bilateral chronic nasal obstruction, who had a previous history of failed medical treatment for at least 2 months, in the form of systemic antibiotics, oral decongestants and/or topical steroid treatment. The inclusion criterion was nasal obstruction due to grade 2 or 3 mucosal hypertrophy (according to the turbinate size evaluation system of Yañez and Mora).²⁷ Exclusion criteria comprised bony hypertrophy of the inferior turbinate, rhinosinusitis, nasal polyposis, antrochoanal polyps, enlarged adenoids or any other nasopharyngeal lesion, deviated septum, and previous nasal surgery. None of the patients had a history of allergy.

All patients were required to complete a questionnaire assessing their nasal symptoms, pre-operatively and one and six months post-operatively. In all patients, a visual analogue scale (VAS) was used to assess subjective symptoms, with 0 indicating no symptoms and 10 indicating severe and/or constant symptoms.

Anterior rhinoscopic and rigid nasal endoscopic examinations (the latter using a 4 mm diameter, 0°, Hopkins II endoscope; Karl Storz, Tuttlingen, Germany) were performed to assess the size of the inferior turbinate pre- and post-operatively. Cottele's test was performed to ensure that the obstruction was in the nasal valve area at the anterior end of the hypertrophied inferior turbinate. Nasal and paranasal sinus computed tomography scanning was also performed.

Acoustic rhinometry using the Personal Computer based Eccovision system (Model AR-1003; Hood Laboratories, Pembroke, Massachusetts, USA) was performed. The nasal cavity volume from the nostril to 5 cm inside the nasal cavity was assessed, pre-operatively and one and six months post-operatively. The total nasal cavity volume (comprising the right plus left nasal cavity volumes) was calculated for each patient.

The 40 patients were randomly divided into two groups prior to study commencement, as follows. Opaque envelopes were numbered sequentially from 1 to 40. A computer-generated table of random numbers was used for treatment assignment: if the last digit of the random number was from 0 to 4, a note was placed into the envelope specifying endoscopic microdebrider assisted turbinate reduction, while if the last digit was from 5 to 9 the note specified turbinate reduction using the 980 nm diode laser. The envelopes were sealed. As eligible participants were entered into the trial, the envelopes were opened in sequential order to give each patient his or her randomised group assignment. The envelopes were opened by the operating surgeon after patient consent had been obtained, just prior to surgery.

Both treatment groups consisted of 20 patients: 15 men and 5 women in the microdebrider-assisted turbinate reduction group, and 13 men and 7 women in the laser-assisted turbinate reduction group. The mean patient age was 28.1 years in the microdebrider group and 29.2 years in the laser group.

In the microdebrider-assisted turbinate reduction group, procedures were performed under general anaesthesia. Nasal packing with oxymetazoline 1 per cent was done 10 minutes pre-operatively. Both inferior turbinates were injected with 2–3 ml of local anaesthesia containing lidocaine 1 per cent with 1:100 000 adrenaline. Injections were performed along the inferior and medial edges of both turbinates. An incision was made into the anterior aspect of the inferior turbinate, using a number 15 blade aligned vertically. A Hall Linvatec straight microdebrider 4.2 mm blade (largo, FL, USA) was applied through the incision (Figure 1). The speed was gradually increased to 3000 cycles per second with the suction level set to low. Cautious circular movements of the tip were made, so that debridement was limited to the stromal tissue of the turbinate and spared the bony portion. The entire procedure was performed under endoscopic guidance. The mean operation time was 8 minutes per turbinate. The reduction in inferior turbinate size was easily seen immediately after the procedure. Finally, nasal sponge packing was inserted, then removed after 48 hours. Systemic antibiotics were prescribed for 7 days post-operatively.

In the laser-assisted turbinate reduction group, procedures were performed under local anaesthesia using lignocaine spray 10 per cent (Xylocaine; AstraZeneca, Luton, UK) and topical application of

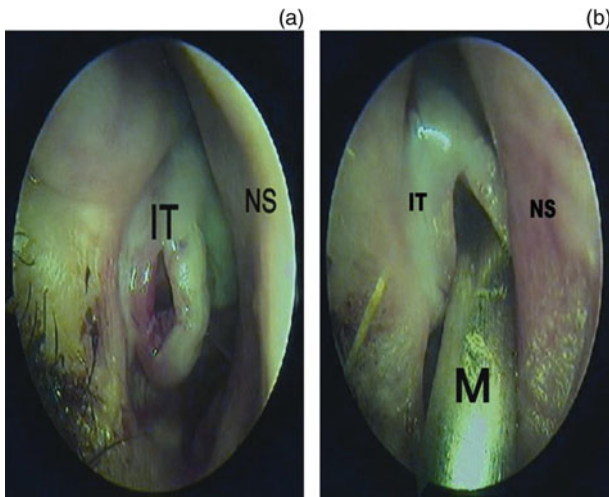


FIG. 1

Nasendoscopic views showing: (a) the incision at the anterior aspect of the inferior turbinate; and (b) introduction of the microdebrider through this incision. M = microdebrider; IT = inferior turbinate; NS = nasal septum

lidocaine–prilocaine cream (Emla; AstraZeneca) applied 10 minutes before surgery. The turbinate was subjected to 980 nm wavelength diode laser pulses (Quanta, Solbiate Olona, Italy) using a bare optical fibre (320 µm). The procedure was performed under 0° and 30° endoscopic guidance, to enable delivery of laser pulses to the turbinate in an anterior–posterior sequence as much as possible. Laser pulses were delivered, under aseptic conditions, to adjacent, non-overlapping sites, sparing islands of healthy mucosa in between contact points (Figure 2). Single, repeated, 3 second applications were used, using 5 W power with an energy fluence of 15 J/cm². The number of pulses ranged from 7 to 10. The mean operative time was 6 minutes per turbinate. During the laser session, the patient and the medical personnel wore safety goggles for the appropriate wavelength. Following the

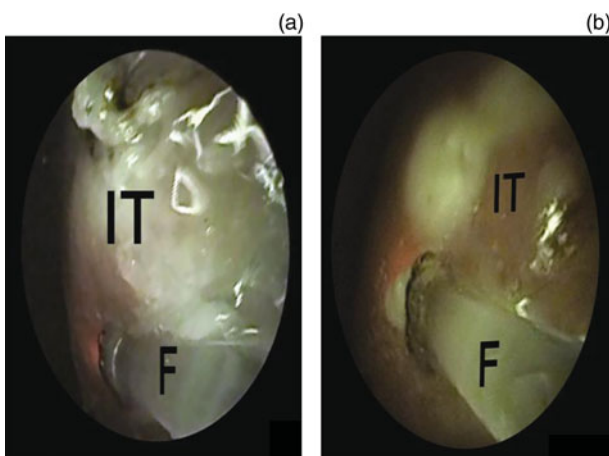


FIG. 2

Nasendoscopic views showing the delivery of diode laser pulses via an optic fibre, during ablation of the inferior turbinate. F = optic fibre; IT = inferior turbinate

procedure, anterior nasal packing was not needed and systemic antibiotics were not used.

Patients in both groups performed alkaline nasal douching for 7 days post-operatively.

Patients in both groups were followed up weekly for four weeks. Their subjective and objective outcomes were assessed one and six months post-operatively, as described above.

Statistical analysis

Data were processed using the Statistical Package for the Social Sciences version 15 software program (SPSS Inc, Chicago, Illinois, USA). Quantitative data were expressed as means ± standard deviations, while qualitative data were expressed as numbers and percentages. The Student *t*-test was used to test the significance of differences in quantitative variables which followed a normal distribution.

Results

The study included 40 patients all suffering from bilateral nasal obstruction. Twenty patients underwent microdebrider-assisted turbinate reduction and 20 laser-assisted turbinate reduction. Pre-operatively, the mean nasal obstruction VAS score was 8.5 in the microdebrider group and 8.3 in the laser group. The patients’ nasal symptoms, including nasal discharge, hyposmia and snoring, are listed in Table I.

Nasal endoscopy in the microdebrider and laser groups identified grade 3 turbinates in 75 and 70 per cent and grade 2 turbinates in 25 and 30 per cent, respectively. Pre-operative acoustic rhinometry indicated a mean total nasal cavity volume of 8.5 ± 0.5 cm³ in the microdebrider group and 8.3 ± 0.8 cm³ in the laser group. There were no statistically significant differences between the two groups pre-operatively, for either subjective or objective parameters (*p* > 0.05). There was no intra- or post-operative bleeding in the laser group, while in the microdebrider group there was a mean 15 ml of intra-operative blood loss. There was no statistically significant difference between the two groups concerning mean operative time and immediate post-operative pain.

In the first three weeks following surgery, crust formation was not observed in the microdebrider group, while in the laser group a few isolated crusts were

TABLE I
PRE-OPERATIVE NASAL SYMPTOMS

Symptom	Microdebr grp*		Laser grp*	
	<i>n</i>	%	<i>n</i>	%
Obstruction	20	100	20	100
Discharge	12	60	13	65
Hyposmia	3	15	2	10
Snoring	3	15	4	20

**n* = 20. There was no statistically significant difference between the two groups (*p* > 0.05). Microdebr grp = microdebrider group

seen which disappeared during the fourth post-operative week.

One month post-operatively, 17 (85 per cent) microdebrider group patients described significant subjective improvement, while 3 in this group (15 per cent) were still suffering nasal obstruction. In the laser group, 15 patients (75 per cent) described satisfactory improvement in nasal breathing 1 month post-operatively, while 5 (25 per cent) were still suffering nasal obstruction.

Six months post-operatively, 18 (90 per cent) microdebrider group patients and 17 (85 per cent) laser group patients were completely relieved of their nasal obstruction. In the remaining patients, objective improvements were indicated by both endoscopic (Table II) and acoustic rhinometric (Table III) findings. Figures 3 and 4 give examples of the improvement in endoscopic appearance following microdebridement and laser ablation, respectively.

There were no statistically significant differences between the two groups ($p > 0.05$). However, there were statistically significant differences between pre- and post-operative findings, within both groups ($p < 0.05$).

Discussion

The inferior turbinates serve several important functions, including warming, humidifying and cleansing the inspired air.²⁸ However, they are also the main structures contributing to chronic nasal obstruction. Chronic inflammatory conditions result in the deposition of collagen beneath the basement membrane of the sinonasal mucosa, together with mucous gland hyperplasia and resultant hyperactive secretion.²⁹

Several surgical techniques have been used to reduce the turbinate, including turbinectomy, submucous turbinectomy, inferior turbinoplasty, cryotherapy and submucous electrocautery.³⁰⁻³⁷ Most of the described techniques involve submucous tissue treatments which require sacrifice of the mucosa, thereby interfering with nasal physiology.^{14,18} Nasal mucociliary function is also impaired in the majority of patients undergoing surgical reduction of the inferior turbinates.^{38,39}

TABLE III
TOTAL NASAL CAVITY VOLUME*

Time point	tNCV (mean \pm SD; cm ³)	
	Microdebr grp	Laser grp
Pre-op	8.5 \pm 0.5	8.3 \pm 0.8
1 mth post-op	12.6 \pm 0.7	12.2 \pm 0.6
6 mth post-op	13.3 \pm 0.8	13.2 \pm 0.5

There was no statistically significant difference between the microdebrider (microdebr) and laser groups ($p > 0.05$). Within both groups, there was a statistically significant difference between pre-operative (pre-op) and post-operative (post-op) findings ($p < 0.05$). *Measured by acoustic rhinometry. tNCV = total nasal cavity volume; SD = standard deviation; grp = group; mth = month

The introduction of microdebrider-assisted endoscopic partial turbinectomy has enabled optimal volume reduction of the turbinate, in order to alleviate nasal obstruction, together with preservation of function.¹⁶ Power-assisted turbinoplasty has since been used by many surgeons, and has been reported to be fast and effective, with success rates ranging from 90 to 100 per cent, and with a low morbidity rate.^{17-19, 27,40-44}

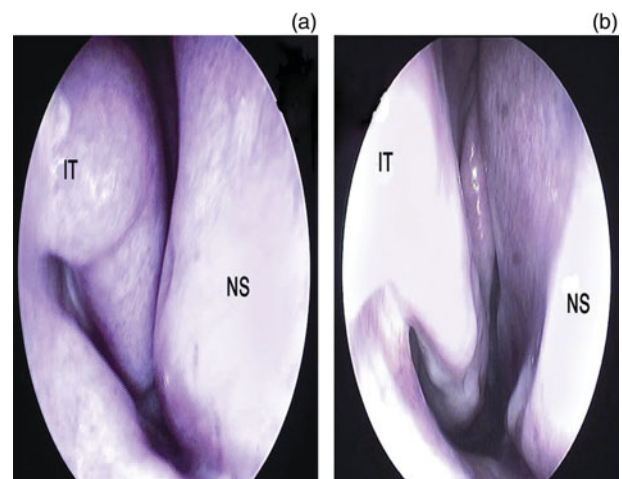


FIG. 3

Nasendoscopic views showing a hypertrophied turbinate (a) before debridement and (b) after debridement with the microdebrider. IT = inferior turbinate; NS = nasal septum

TABLE II
ENDOSCOPIC FINDINGS

ITH grade	Microdebrider group*								Laser group*			
	Pre-op		Post-op				Pre-op		Post-op			
	n	%	1 mth		6 mth		n	%	1 mth		6 mth	
			n	%	n	%			n	%	n	%
1	0	0	18	90	18	90	0	0	16	80	17	85
2	5	25	2	10	2	10	6	30	4	20	3	15
3	15	75	0	0	0	0	14	70	0	0	0	0

*n = 20. There was no statistically significant difference between the microdebrider and laser groups ($p > 0.05$). Within both groups, there was a statistically significant difference between pre-operative (pre-op) and post-operative (post-op) findings ($p < 0.05$). ITH = inferior turbinate hypertrophy; mth = months

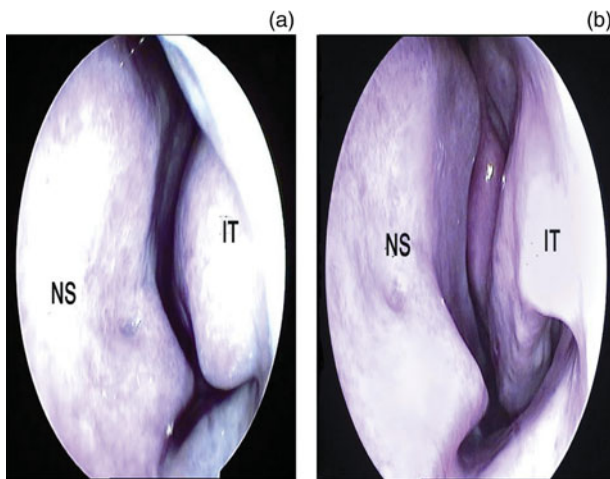


FIG. 4

Nasendoscopic views showing a hypertrophied turbinate (a) before ablation and (b) after ablation with the diode laser. IT = inferior turbinate; NS = nasal septum

The need for a less traumatic and minimally invasive procedure for the treatment of hyperplastic inferior turbinates has led to the introduction of laser surgery. Lenz and colleagues reported high success rates following inferior turbinate surgery using an argon laser.^{20,21} Lenz *et al.* also described delayed healing and significant crusting for a period of four to six weeks, as well as complications and side effects such as nasal dryness and bony sequestra.⁴⁵

Carbon dioxide lasers have been widely used to treat inferior turbinate hypertrophy, with great success.^{46–50} However, carbon dioxide laser has the lowest thermal tissue effect of all the surgical lasers, and therefore has the highest risk of intra-operative bleeding, and the greatest possibility that more than one therapeutic session will be required to obtain an adequate result.²⁴

Unlike the carbon dioxide laser, the Ho:YAG laser has good coagulation capability and is therefore suitable for inferior turbinate treatment, enabling minimal carbonisation and satisfactory haemostasis.^{51,52} However, a study of the long-term efficacy of diode versus Ho:YAG laser found success rates of 74.4 and 67.5 per cent, respectively, after three years' follow up.⁵³

Other authors have reported on the use of the Nd:YAG laser for the treatment of inferior nasal turbinate hypertrophy.^{54–57} However, a potential disadvantage of this laser is the observed reactive post-operative swelling of the nasal mucosa, which may cause worsening of nasal breathing for the first one to two post-operative months.⁵⁷

The diode laser enables effective reduction in hyperplastic inferior turbinate size with good haemostasis, similar to the Nd:YAG laser.^{26,58} Due to the diode laser's deeper penetration depth and strong scattering within tissue, larger coagulation zones can be obtained in comparison with the argon and KTP lasers.²³ However, the diode laser's coagulation capabilities are not as great as those of the Nd:YAG laser; therefore,

a large but controlled coagulation zone can be created within the venous plexus of the nasal turbinate, with little risk to the turbinate periosteum.^{22,24} Moreover, a shorter period of post-operative nasal mucosa swelling (three to four weeks) has been reported.^{26,53,58,59} Considering the aforementioned clinical findings, a 980 nm wavelength diode laser was chosen for the current study.

Janda *et al.* have reported the use of a continuous, 940 nm wavelength diode laser in non-contact mode, with a power setting of 8–10 W, in the treatment of inferior turbinate hypertrophy.²⁶ They found a subjective improvement in 86 per cent of their patients after six months, which decreased to 76 per cent after one year. In another study using a diode laser with the same parameters, this same group reported a success rate of 74.4 per cent after three years' clinical follow up.⁵³ Patients treated with the diode laser showed moderate to severe nasal obstruction due to immediate post-operative swelling of coagulated tissue, which sloughed off within four post-operative weeks and was replaced by scar tissue. Subsequently, nasal crusting subsided, the turbinate re-epithelialised, and subjective relief of the nasal obstruction became apparent.

Other clinical studies have used a continuous wave, 810 nm wavelength diode laser in contact mode with different power settings, and reported subjective improvement of nasal air flow in all patients over a six-month follow-up period.^{58,60}

In contrast to the above reports, DeRowe *et al.* reported subjective improvement in nasal breathing at one year post-operatively in 41 per cent of patients treated with continuous wave, 805 nm wavelength diode laser in contact mode with a power setting of 8 W.⁶¹

In the current study, we used previously unreported laser parameters: the patients in our laser group received 980 nm wavelength, 5 W, pulsed diode laser used at non-overlapping contact sites along the turbinate, sparing islands of healthy mucosa in-between in order to enhance re-epithelialisation. The pulsed diode laser created controlled coagulation zones on the turbinate, which necrosed and detached from the healthy underlying tissue within four weeks of surgery. This resulted in increased nasal cavity volume and improved nasal breathing.

Our diode laser results are comparable to those of Janda *et al.* up to six post-operative months.²⁶ We observed subjective improvement in nasal breathing in 85 per cent of our laser group patients. In addition, endoscopic examination showed a significant reduction in turbinate size, confirmed by an increase in total nasal cavity volume of 46.9 and 56.6 per cent after one and six post-operative months, respectively, compared with pre-operative values. Laser group patients suffered transient nasal obstruction between two and four weeks post-operatively, but at the end of the first post-operative month 75 per cent of patients reported significant relief of their nasal obstruction.

In our microdebrider group, subjective improvement was reported by 17 (85 per cent) patients after 1 post-operative month and by 18 (90 per cent) patients after 6 months. The turbinate size was significantly reduced after the surgery and the total nasal cavity volume increased by 48.2 per cent at one post-operative month and by 56.4 per cent at six months, respectively. Patients in this group also complained of nasal congestion at one to three weeks post-operatively.

In our study, comparison of the microdebrider and laser group results indicated no statistically significant differences at one and six months post-operatively, for either subjective or objective parameters. This is in contrast to a recent comparative clinical study with three months' follow up, which reported success rates of 60 per cent in the carbon dioxide laser group versus 86.4 per cent in the microdebrider group.⁶² Hence, in agreement with Newman and Anand, it can be concluded that 980 nm wavelength diode laser is ideally suited for intranasal use, resulting in controlled coagulation and soft tissue ablation in a short treatment time.⁵⁹ In addition, this therapeutic modality is favoured for its facility for bloodless operation under local anaesthesia, and for its highly satisfactory results compared with many surgical techniques which risk intra- and/or post-operative bleeding and require nasal packing, antibiotic administration, general anaesthesia and hospitalisation.

- **This study assessed outcomes for microdebrider versus laser assisted turbinoplasty**
- **Success rates were 85–90 per cent at six months for both techniques**
- **There were no significant differences in operative time, post-operative complications or outcomes between the two techniques**

Microdebrider-assisted turbinoplasty is also a safe technique for achieving turbinate size reduction, with acceptable morbidity. Bleeding is a minor complication, and preservation of mucosa facilitates early healing and the absence of crusting or exposed bone.

Conclusion

This clinical study, with six months' follow up, indicates that both microdebrider and 980 nm diode laser techniques are effective and equally successful in reducing inferior turbinate hypertrophy. Unfortunately, for reasons beyond our control, it was impossible follow up our patients for a longer period. Therefore, we are not able to comment on the long-term outcomes of these two techniques.

References

- 1 Courtiss EH. Management of inferior turbinate hypertrophy. *Plast Reconstr Surg* 1999;**104**:1197–8

- 2 Garth RJ, Cox HJ, Thomas MR. Haemorrhage as a complication of inferior turbinectomy: a comparison of anterior and radical trimming. *Clin Otolaryngol* 1995;**20**:236–8
- 3 Jackson LE, Koch RJ. Controversies in the management of inferior turbinate hypertrophy: a comprehensive review. *Plast Reconstr Surg* 1999;**103**:300–12
- 4 Passali D, Lauriello M, De Filippi A, Bellussi L. Comparative study of most recent surgical techniques for the treatment of the hypertrophy of inferior turbinates [in Italian]. *Acta Otorhinolaryngol Ital* 1995;**15**:219–28
- 5 Friedman M, Vidyasagar R. Surgical management of septal deformity, turbinate hypertrophy, nasal valve collapse and choanal atresia. In: Bailey BJ, Johnson JT, Newlands SD, eds. *Head & Neck Surgery – Otolaryngology*. Philadelphia: Lippincott Williams & Wilkins, 2006;**1**:328–30
- 6 Fairbanks DN. Snoring: surgical vs. nonsurgical management. *Laryngoscope* 1984;**94**:1188–92
- 7 Haight JS, Cole P. The site and function of the nasal valve. *Laryngoscope* 1983;**93**:49–55
- 8 Hofmann T, Wolf G, Koidl B. In vitro studies of the effect of vasoconstrictor nose drops on ciliary epithelium of human nasal mucosa [in German]. *Laryngorhinootologie* 1995;**74**:564–7
- 9 Tasman AJ, Soor A, Zaiss M, Weidauer H. The septal mucosa decongests with naphazoline: a study of mucosal dynamics with sonography. *Am J Rhinol* 1999;**13**:411–17
- 10 Baumgarten CR, Nichols RC, Naclerio RM, Lichtenstein LM, Norman PS, Proud D. Plasma kallikrein during experimentally induced allergic rhinitis: role in kinin formation and contribution to TAME-esterase activity in nasal secretions. *J Immunol* 1986;**137**:977–82
- 11 Haackevon NP, Hardcastle PF. Submucosal diathermy of the inferior turbinate and the congested nose. *ORL J Otolaryngol Relat Spec* 1985;**47**:189–93
- 12 Hol MK, Huizing EH. Treatment of inferior turbinate pathology: a review and critical evaluation of the different techniques. *Rhinology* 2000;**38**:157–66
- 13 Kimmelman CP, Gamal HA. Vasomotor rhinitis. *Otolaryngol Clin North Am* 1986;**65**:65–71
- 14 Dawes PJ. The early complications of inferior turbinectomy. *J Laryngol Otol* 1987;**101**:1136–9
- 15 Passali D, Lauriello M, Anselmi M, Bellussi L. Treatment of hypertrophy of the inferior turbinate: long-term results in 382 patients randomly assigned to therapy. *Ann Otol Rhinol Laryngol* 1999;**108**:569–75
- 16 Setcliff R, Parsons D. The hummer: new instrumentation for functional endoscopic sinus surgery. *Am Rhinol J* 1994;**8**:275–7
- 17 Yañez C. New technique for turbinate reduction in chronic hypertrophic rhinitis intratubinal stroma removal using the microdebrider. *Oper Tech Otolaryngol Head Neck Surg* 1998;**9**:135–7
- 18 Friedman M, Tanyeri H, Lim J, Landsberg R, Caldarelli D. A safe, alternative technique for inferior turbinate reduction. *Laryngoscope* 1999;**109**:1834–7
- 19 Lee KC, Hwang PH, Kingdom TT. Surgical management of inferior turbinate hypertrophy in the office: three mucosal sparing techniques. *Oper Tech Otolaryngol Head Neck Surg* 2001;**12**:107–11
- 20 Lenz H, Eichler J, Schafer G, Salk J. Parameters for argon laser surgery of the lower human turbinate. *Acta Otolaryngol* 1977;**83**:360–5
- 21 Lenz H. 8 years' laser surgery of the inferior turbinates in vasomotor rhinopathy in the form of laser strip carbonization [in German]. *HNO* 1985;**33**:422–5
- 22 Janda P, Sroka R, Baumgartner R, Greevers G, Leunig A. Laser treatment of hyperplastic inferior nasal turbinates. *Lasers Surg Med* 2001;**28**:404–13
- 23 Eichler J, Alves OG. A review of different lasers in endonasal surgery: Ar-, KTP-, Dye-, Diode-, Nd-, Ho- and CO₂-Laser. *Med Laser Appl* 2002;**17**:190–200
- 24 Janda P, Sroka R, Betz CS, Baumgartner R, Leunig A. Comparison of laser induced effects on hyperplastic inferior nasal turbinates by means of scanning electron microscopy. *Lasers Surg Med* 2002;**30**:31–9
- 25 Janda P, Sroka R, Mundweil B, Baumgartner R, Leunig A. Comparison of thermal tissue effects induced by contact application of fiber guided laser systems. *Lasers Surg Med* 2003;**33**:93–101

- 26 Janda P, Sroka R, Stefan T, Baumgartner R, Greevers G, Leunig A. Diode laser treatment of hyperplastic inferior nasal turbinates. *Lasers Surg Med* 2000;**27**:129–39
- 27 Yañez C, Mora N. Inferior turbinate debriding technique: ten-year results. *Otolaryngol Head Neck Surg* 2008;**138**:170–5
- 28 Abramson M, Harker LA. Physiology of the nose. *Otolaryngol Clin North Am* 1973;**6**:625–35
- 29 Cook PR. Sinusitis and allergy. *Curr Opin Otolaryngol Head Neck Surg* 1997;**5**:35–9
- 30 Principato JJ. Chronic vasomotor rhinitis: cryogenic and other surgical modes of treatment. *Laryngoscope* 1979;**89**:619–37
- 31 Mabry RL. Inferior turbinoplasty: patient selection, technique, and long-term consequences. *Otolaryngol Head Neck Surg* 1988;**98**:60–6
- 32 Elwany S, Harrison R. Inferior turbinectomy: comparison of four techniques. *J Laryngol Otol* 1990;**104**:206–9
- 33 Rakover Y, Rosen G. A comparison of partial inferior turbinectomy and cryosurgery for hypertrophic inferior turbinates. *J Laryngol Otol* 1996;**110**:732–5
- 34 Salam MA, Wengraf C. Concho-antropexy or total inferior turbinectomy for hypertrophy of the inferior turbinates? A prospective randomized study. *J Laryngol Otol* 1993;**107**:1125–8
- 35 Ophir D, Shapira A, Marshak G. Total inferior turbinectomy for nasal airway obstruction. *Arch Otolaryngol Head Neck Surg* 1985;**111**:93–5
- 36 Moore GF, Freeman TJ, Ogren FP, Yonkers AJ. Extended follow-up of total inferior turbinate resection for relief of chronic nasal obstruction. *Laryngoscope* 1985;**95**:1095–9
- 37 Jones AS, Lancer JM. Does submucosal diathermy to the inferior turbinates reduce nasal resistance to airflow in the long term? *J Laryngol Otol* 1987;**101**:448–51
- 38 Sapci T, Sahin B, Karavus A, Akbulut UG. Comparison of the effects of radiofrequency tissue ablation, CO₂ laser ablation, and partial turbinectomy applications on nasal mucociliary functions. *Laryngoscope* 2003;**103**:514–19
- 39 Nuutinen J. Asymmetry in the nasal mucociliary transport rate. *Laryngoscope* 1996;**106**:1424–8
- 40 Kizilkaya Z, Ceylan K, Emir H, Yavanoglu A, Unlu I, Samim E. Comparison of radiofrequency tissue volume reduction and submucosal resection with microdebrider in inferior turbinate hypertrophy. *Otolaryngol Head Neck Surg* 2008;**138**:176–81
- 41 Lee CF, Chen TA. Power microdebrider-assisted modification of endoscopic inferior turbinoplasty: a preliminary report. *Chang Gung Med J* 2004;**27**:359–65
- 42 Lee JY, Lee JD. Comparative study on the long-term effectiveness between coblation- and microdebrider-assisted partial turbinoplasty. *Laryngoscope* 2006;**116**:729–34
- 43 Medtronic: Risks and benefits – septoplasty associated with turbinoplasty with microdebrider [in Italian]. In: <http://www.medtronic.it/tua-salute/infezioni-seni-paranasali/nostraterapia/settoplastica-turbinoplastica/rischi-benefici/index.htm> [23 August 2012]
- 44 Liu CM, Tan CD, Lee FP, Lin KN, Huang HM. Microdebrider-assisted versus radiofrequency-assisted inferior turbinoplasty. *Laryngoscope* 2009;**119**:414–18
- 45 Lenz H, Preussler H. Histologic changes in the epithelium of the respiratory mucosa of the lower turbinates following argon laser strip carbonization in vasomotor rhinitis [in German]. *Laryngol Rhinol Otolol (Stuttg)* 1986;**65**:438–44
- 46 Elwany S, Abdel-Moniem MH. Carbon dioxide laser turbinectomy. An electron microscopic study. *J Laryngol Otol* 1997;**111**:931–4
- 47 Katz S, Schmelzer B, Vidts G. Treatment of the obstructed nose by CO₂-laser reduction of the inferior turbinates. Techniques and results. *Am J Rhinol* 2000;**14**:51–5
- 48 Lippert BM, Werner JA. CO₂ laser surgery of hypertrophied inferior turbinates. *Rhinology* 1997;**35**:33–6
- 49 Lippert BM, Werner JA. Treatment of the hypertrophic inferior turbinate [in German]. *HNO* 2000;**48**:170–81
- 50 Tanigawa T, Yashiki T, Hazshi K, Sato T. Carbon dioxide laser vaporization for turbinate: optimal conditions and indications. *Auris Nasus Larynx* 2000;**27**:137–40
- 51 Leunig A, Janda P, Sroka R, Baumgartner R, Grevers G. Holmium: YAG laser treatment of hyperplastic inferior nasal turbinates. *Laryngoscope* 1999;**109**:1690–5
- 52 Oswal VH, Bingham BJC. A pilot study of the holmium YAG laser in nasal turbinate and tonsil surgery. *J Clin Laser Med Surg* 1992;**10**:211–16
- 53 Sroka R, Janda P, Killian T, Vaz F, Betz C, Leunig A. Comparison of long term results after Ho:YAG and diode laser treatment of hyperplastic inferior nasal turbinates. *Lasers Surg Med* 2007;**39**:324–31
- 54 Kirschner RA, McDonnell BC, Brodtkin AC. Nd: YAG laser turbinectomy. *Laser Surg Med* 1988;**8**:195
- 55 Lachiver X, Blondel J, Ouayoun M, Mosnier I, Dupuy MA, Freche C, Chabolle F. Ambulatory laser and turbinectomy in the treatment of nasal obstruction. Apropos of 68 cases [in French]. *Ann Otolaryngol Chir Cervicofac* 1995;**112**:285–92
- 56 Olthoff A, Martin A, Liebmann F. Nd:YAG laser treatment of the lower turbinates with contact in hyperreflexic and allergic rhinopathy [in German]. *Laryngorhinootologie* 1999;**78**:240–3
- 57 Lippert BM, Werner JA. Nd:YAG laser light-induced reduction of the nasal turbinates [in German]. *Laryngorhinootologie* 1996;**75**:523–8
- 58 Hopf JUG, Hopf M, Koffroth BC. Minimal invasive surgery of obstructions of the nasal cavity by diode laser [in German]. *Lasermmedizin* 1999;**14**:106–15
- 59 Newman J, Ananad V. Applications of the diode laser in otolaryngology. *Ear Nose Throat J* 2002;**81**:850–1
- 60 Min YG, Kim HS, Yun YS, Kim CS, Jang YG, Jung TG. Contact laser turbinate surgery for the treatment of idiopathic rhinitis. *Clin Otolaryngol Allied Sci* 1996;**21**:533–6
- 61 DeRowe A, Landsberg R, Leonov Y, Katzir A, Ophir D. Subjective comparison of Nd:YAG, diode, and CO₂ lasers for endoscopically guided inferior turbinate reduction surgery. *Am J Rhinol* 1998;**12**:209–12
- 62 Lee DH, Kim EH. Microdebrider-assisted versus laser-assisted turbinate reduction: comparison of improvement in nasal airway according to type of turbinate hypertrophy. *Ear Nose Throat J* 2010;**89**:541–5

Address for correspondence:

Dr Ahmed Nazmi Kassab,
Otorhinolaryngology Unit,
Department of Medical Laser Applications,
National Institute of Laser Enhanced Sciences,
Cairo University,
Cairo, Egypt

E-mail: Kassabahmed28@yahoo.com

Dr A N Kassab takes responsibility for the integrity
of the content of the paper
Competing interests: None declared
