

'Wipe-out' after subscleral trabeculectomy in advanced glaucoma patients

Ahmed M. Abdelrahman, Heba M.A. ElSaied, Riham S.H.M. Allam, Moataz H. Osman

Department of Ophthalmology, Kasr Al-Ainy School of Medicine, Cairo University, Dokki, Egypt

Correspondence to Riham S.H.M. Allam, MD, FRCS Glasgowb, Department of Ophthalmology, Kasr Al-Ainy School of Medicine, Cairo University, 4 Omar Ebn Alkhattab Street, Dokki - 12311, Egypt; Tel: 01001873843; e-mail: ryham_allam@yahoo.com

Received 4 December 2016

Accepted 21 February 2017

Delta Journal of Ophthalmology
2017, 18:94-98

Purpose

The aim of this study was to evaluate the safety of trabeculectomy in advanced glaucoma patients in the Egyptian population, and to detect postoperative wipe-out syndrome in high-risk patients.

Patients and methods

Thirty-six eyes of 33 patients with advanced glaucoma were included in the study. All patients underwent subscleral trabeculectomy. The patients were followed up for 3 months during which intraocular pressure (IOP), best-corrected visual acuity (BCVA), slit lamp biomicroscopy, fundus examination, and perimetry were done.

Results

The mean age of the study group was 51.17 ± 2.64 years. The study included 24 males and nine females. The mean preoperative BCVA was 0.36 ± 0.33 , the mean IOP was 31 ± 8.75 mmHg and the mean number of medications was 3.08 ± 0.1 . In all cases, complete success was achieved except for two cases with qualified success. The BCVA at day 90 showed no change in 21 eyes, visual decline in three eyes and visual gain in 12 eyes. A negative linear correlation was noticed between the percent reduction in IOP and the reduction in BCVA in the first postoperative day ($r = -0.239$) which was not statistically significant ($P = 0.162$). The color of the neuroretinal rim was not a significant determinant for the final BCVA ($P = 0.48$). Visual field changes showed no statistically significant differences.

Conclusion

Wipe-out phenomenon is not an ultimate postoperative outcome for filtering surgery in patients with advanced glaucoma. Pale neuroretinal rim and postoperative hypotony are risk factors for postoperative visual deterioration.

Keywords:

advanced glaucoma, subscleral trabeculectomy, wipe-out

DJO 18:94-98

© 2017 Delta Journal of Ophthalmology

1110-9173

Introduction

The phenomenon of severe visual loss after surgery, with no obvious cause is known as wipe-out or snuff syndrome. Wipe-out may affect patients who have severe glaucomatous damage. Overall it is a very uncommon complication but remains an important concern among glaucoma surgeons [1].

There are few studies that have evaluated the incidence of wipe-out syndrome after trabeculectomy. The reported incidence ranged from 0 to 0.95% of the surgeries with some identified risk factors such as retrobulbar anesthesia, old patients with high preoperative intraocular pressure (IOP) and advanced visual field (VF) defects affecting the central field with split fixation. Postoperative complications appear to increase the risk [2].

Possible mechanisms of wipe-out syndrome include direct damage to the optic nerve from anesthetic technique as local pressure to the optic nerve either by optic nerve sheath hematoma or simply by the volume of the injected anesthesia which may cause

further damage to a severely damaged optic nerve [3]. Accordingly, anterior placement of anesthesia as subconjunctival anesthesia is preferable [4].

Early undiagnosed postoperative IOP spikes could potentially inflict further insult to a severely damaged optic nerve. Accordingly, IOP should be monitored few hours after surgery and also the following day, thus if there is an early IOP spike, it can be treated [2]. Postoperative profound hypotony has been associated with increased incidence of wipe-out [5].

The aim of this study was to evaluate the safety of subscleral trabeculectomy and to detect postoperative wipe-out syndrome (represented by unexplained deterioration of visual acuity) in patients having

This is an open access article distributed under the terms of the Creative Commons Attribution-NonCommercial-ShareAlike 3.0 License, which allows others to remix, tweak, and build upon the work noncommercially, as long as the author is credited and the new creations are licensed under the identical terms.

advanced glaucomatous optic neuropathy (in the form of tubular field with macular splitting).

Patients and methods

This is a prospective noncomparative interventional case series.

All patients received a thorough explanation of the study design and aims. Study participants gave an informed consent before initiation of any study-related procedures. The study adhered to the tenets of declaration of Helsinki and was approved by the Research Ethics Committee of the Faculty of Medicine, Cairo University.

All patients were subjected to full ophthalmological examination, including full medical and ophthalmic history taking, number of antiglaucoma medications taken by the patients, assessment of best-corrected visual acuity (BCVA) by Landolt's C chart, assessment of the IOP using Goldman's applanation tonometry, gonioscopy, and slit lamp biomicroscopy.

The color of the neuroretinal rim (NRR) was assessed by the four authors and was classified as normal or pale after agreement of at least three of the authors (Fig. 1) and the continuity of the NRR was evaluated according to the Disc Damage Likelihood Scale [6].

VF testing was done using Humphrey SITA standard perimetry (central 24-2 and central 10-2 SITA standard strategy) to detect the mean deviation (MD), pattern SD, depth of scotomata in the four points of fixation and the number of quadrants with split fixation.

The enrolled patients of the study were at least 18 years of age with a clinical diagnosis of advanced glaucoma uncontrolled with maximum tolerated topical treatment having severe glaucomatous VF defects defined as any of the following criteria: MD less than -12 dB, on pattern deviation plot greater than 50% of points depressed below the 5% level and greater than 25% of points depressed below 1%, any point within the central 5° with sensitivity lower to 0 dB, both hemifields containing a point(s) with sensitivity lower to 15 dB within 5° of fixation [7].

After meeting these inclusion criteria, all participants confirmed their ability to follow study instructions and complete all required visits.

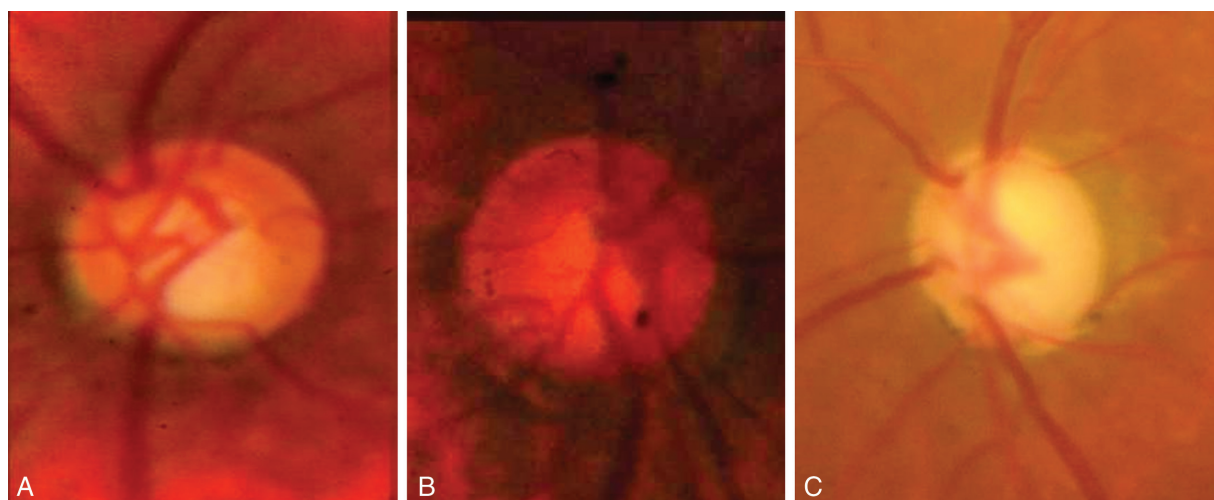
Exclusion criteria included active ocular disease other than advanced glaucoma that would interfere with study outcomes, neovascular, uveitic, and aphakic glaucoma.

Split macular fixation was defined for the study as one of the four points abutting fixation on the macular field having a sensitivity of less than 10 dB with an adjacent point on the same side of fixation being less than 10 dB [8].

Intervention and outcome measures

After meeting all inclusion criteria these eyes were subjected to subcleral trabeculectomy with a fornix-based conjunctival flap, rectangular scleral pocket 4×3 mm, application of mitomycin C 0.4 mg/ml for 2 min, paracentesis for gradual decompression, then excision of the inner block by Kelly punch, followed by peripheral iridectomy. Closure of the flap was done by

Figure 1



Colored fundus photos demonstrating the neuroretinal rim color evaluation. (a) Normal pale pink NRR with a DDLS of 5; (b) normal pale pink NRR with a DDLS of 4; (c) pale NRR with a DDLS of 7. DDLS, Disc Damage Likelihood Scale; NRR, neuroretinal rim

two 10/0 nylon sutures aiming for filtration on minimal pressure and a formed anterior chamber at the end of surgery. Instillation of atropine eye drops was done.

Postoperatively patients were prescribed topical combined antibiotics and steroids eye drops and were instructed for gradual tapering over 6 weeks. Postoperative cycloplegia was prescribed only when needed.

The patients were evaluated postoperatively on the first day, first week, second week, and third month. Evaluation included the BCVA using Landolt's C chart, IOP using Goldman's applanation tonometry, slit lamp examination to detect the bleb morphology, slit lamp biomicroscopy, any postoperative complication, and VF testing using Humphrey SITA standard perimetry (central 10-2) after 2 weeks as well as after 3 months, but in cases with visual deterioration, VF testing was done every 2 weeks through the follow-up period. Trabeculectomy was considered a complete success when IOP was 21 mmHg or less without additional therapy, qualified success when IOP was 21 mmHg or less with a single topical medication and failure when IOP was 21 mmHg or more when patients required two or more topical medication to control the IOP [9].

Wipe-out was considered when unexplained visual decline (more than two lines on Landolt's C chart) occurred during the first postoperative 2 weeks and persisted for 3 months.

All data were collected in an Excel database and transferred to the statistical package for the social sciences (SPSS; SPSS Inc., Chicago, Illinois, USA). The statistical data were expressed in terms of mean, range, and SD. *P* values less than 5% were considered statistically significant.

Results

The present study was performed on 36 eyes of 33 patients (three patients underwent bilateral surgeries) who underwent filtering surgeries for uncontrolled glaucoma with advanced optic neuropathy between February 2014 and July 2014 at the Ophthalmology Department, Kasr Al-Ainy School of Medicine.

The mean age of the study group was 51.17±2.64 years (range: 18–88 years). The study included 24 (72.73%) males and nine (27.27%) females (male : female ratio was 8 : 3).

The study included 26 eyes having primary open angle glaucoma, eight eyes having chronic angle closure glaucoma, one eye having secondary open angle

glaucoma (pseudoexfoliation syndrome) and one eye having secondary angle closure glaucoma (pseudophakia).

The preoperative data of the study group are summarized in Table 1.

The postoperative BCVA and IOP are summarized in Table 2. In all cases, complete success was achieved where the IOP was controlled without medications except for two cases in which qualified success was achieved (with one medication in one case and two medications in the other).

Postoperative complications were recorded. Shallow anterior chamber occurred in six cases, disc edema in one case, hypotony in four cases, and peripheral choroidal detachment in four case, all were managed conservatively and resolved by the second postoperative week.

The postoperative course of IOP and BCVA is illustrated in Fig. 2. Comparing the preoperative BCVA to the BCVA at day 90, no change was encountered in 33 eyes while visual decline by up to two lines was observed in three eyes (one of them due to galloping cataract considered when cataract progression becomes visually significant).

Further analysis revealed a negative linear correlation between the percent reduction in IOP (Δ IOP%) and the reduction in BCVA in the first postoperative day ($r=-0.239$) which was not statistically significant ($P=0.162$) as illustrated in Fig. 3.

Table 1 The preoperative data of the study group

Data	Mean±SD	Range
BCVA	0.36±0.33	CF at 50 cm to 1.00
IOP (mmHg)	31±8.75	16–50
Number of medications	3.08±0.1	2–6
Optic nerve head		
DDLS	8.17±1.2	5–9
NRR	32 pale; 4 pale pink	
Visual field		
MD (dB)	-20.4±7.94	-34 to -5.71
PSD	7.2±3.64	2.32–14.22
Quadrants of split fixation	2.2±0.77	1–4

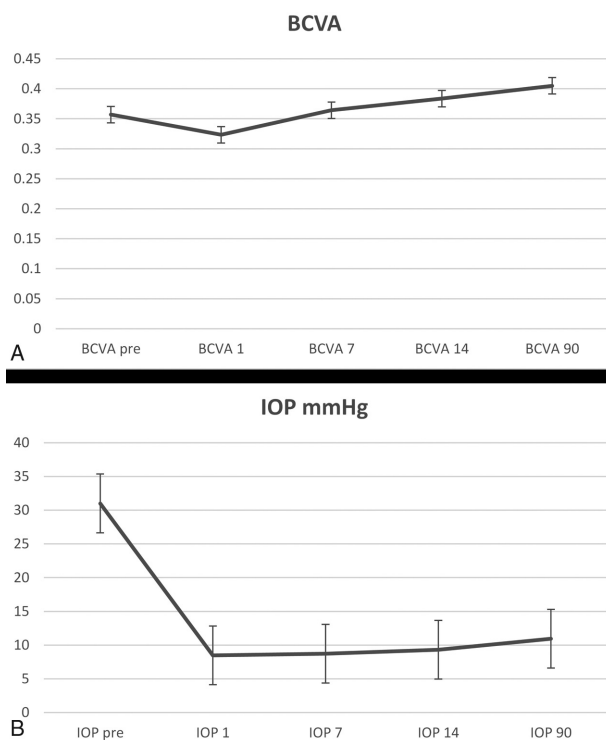
BCVA, best-corrected visual acuity; CF, counting fingers; DDLS, Disc Damage Likelihood Scale; IOP, intraocular pressure; MD, mean deviation; NRR, Neuroretinal Rim; PSD, pattern SD.

Table 2 The postoperative best-corrected visual acuity and intraocular pressure of the study group

Postoperative	BCVA	IOP
Day 1	0.323±0.30	8.47±2.80
Day 7	0.364±0.31	8.72±1.95
Day 14	0.38±0.32	9.3±2.13
Day 90	0.4±0.34	10.94±2.08

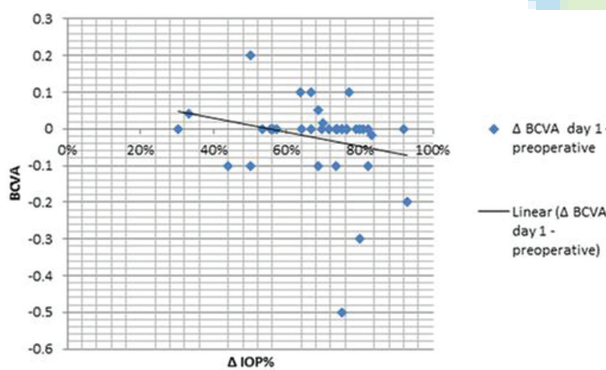
BCAV, best-corrected visual acuity; IOP, intraocular pressure.

Figure 2



Line graph representation of postoperative course of BCVA and IOP in the study group. (a) BCVA; (b) IOP in mmHg. BCVA, best-corrected visual acuity; IOP, intraocular pressure

Figure 3



A scatter plot showing a negative linear correlation between the percent reduction of intraocular pressure (Δ IOP %) and the change in best-corrected visual acuity on the first postoperative day

In addition, the color of the NRR was not shown to be a significant determinant for the final BCVA ($P=0.48$).

The VF changes showed no statistically significant differences between the preoperative and postoperative data (Table 3).

Discussion

Glaucoma filtering procedures have been incriminated as a cause of visual loss in patients with advanced

Table 3 The visual field changes in the study group

Period	Mean deviation (MD) (decibels)	Pattern SD	Number of quadrants of split fixation
Preoperative	-20.4 ± 7.94	7.2 ± 3.64	2.2 ± 0.77
Day 90	-18.017 ± 11.02	6.74 ± 3.5	2.24 ± 0.87
P-value	0.35	0.63	0.87

glaucomatous optic neuropathy. It has been reported that filtering procedures in advanced glaucoma may be associated with a risk of immediate unexplained postoperative VF loss involving fixation with an accompanying change in central visual acuity ('wipe-out' or 'snuff' phenomenon) [10].

There are no exact reports about the true incidence of wipe-out phenomenon. Kolker [11] reported an incidence of 13.6% (3/22) of central vision loss in the immediate postoperative period and suggested that this complication is very rare when central vision is spared. On the other hand Costa *et al.* [12] showed that the risk of unexplained postoperative loss of central VF does exist but is lower than 1% and is more likely to occur in older patients with macular splitting in the preoperative VF. Aggarwal and Hendeles [13], in a prospective study, reported three cases of central VF loss after trabeculectomy out of nine patients with very small VF because of advanced glaucoma. However, two of those cases had developed postoperative cystoid macular edema or persistent hypotony with only the third patient having no identifiable cause of this visual loss.

Although the exact mechanism of the 'wipe-out' phenomenon remains elusive, it has been suggested that it may be associated with the occurrence of sudden, intraoperative ocular hypotony during glaucoma surgery. This may result in optic nerve hemorrhage and decreased perfusion pressure to an already compromised optic nerve blood supply. It may also induce a microembolic episode that could damage the remaining nerve fibers [14]. Conversely, other investigators suggested that surgical intervention in advanced glaucoma is seldom, if ever, associated with reduction of central VFs [14–16].

In the present study, the incidence and possible risk factors for the occurrence of unexplained visual loss after glaucoma filtering surgery in patients having advanced glaucoma with split fixation in one or more quadrants of the VF were evaluated prospectively.

The results of the present study revealed visual decline in only 3 of 36 patients in which galloping cataract (considered when cataract progression becomes visually

significant) was enough to explain visual loss in one case while in the other two cases no identifiable cause was found yet both cases shared pale preoperative NRR and one case experienced hypotony in the first postoperative day.

The change in BCVA showed a negative linear correlation with the percent reduction in IOP which was statistically nonsignificant.

The results of the present study showed no statistically significant differences between the preoperative and postoperative VF parameters regarding the MD, the PSD, and the number of quadrants of split fixation.

It can be concluded that the wipe-out phenomenon; as reported in the present study; can occur as a postoperative outcome in patients with advanced glaucoma. However, it is not an ultimate postoperative outcome. Pale NRR and postoperative hypotony are risk factors for postoperative visual deterioration.

The present study is, however, limited by the relatively small number of patients and lack of optic nerve head blood flow analysis which would have documented any possible optic nerve head ischemic or embolic insults.

Financial support and sponsorship
Nil.

Conflicts of interest

There are no conflicts of interest.

References

- 1 Jampel HD, Quigley HA, Kerrigan-Baumrid LA, Melia BM, Friedman D, Barron Y The glaucoma surgical outcomes study group. Risk factors for late onset infection following glaucoma filtration surgery. *Arch Ophthalmol* 2001; 119:1001–1008.
- 2 Song A, Scott IU, Flynn HW Jr, Budenz DL. Delayed onset bleb-associated endophthalmitis: clinical features and visual acuity outcomes. *Ophthalmology* 2002; 109:985–991.
- 3 Reynolds AC, Skuta GL, Monlux R, Johnson J. Management of blebitis by members of the American Glaucoma Society, a survey. *J Glaucoma* 2001; 10:340–347.
- 4 Yarangumeli A, Koz OG, Kural G. Encapsulated blebs following primary standard trabeculectomy course and treatment. *J Glaucoma* 2004; 13:251–255.
- 5 Wand M, Quintilini R, Robinson A. Antibiotic prophylaxis in eyes with filtration blebs. Survey of glaucoma specialists, microbiological study and recommendations. *J Glaucoma* 1995; 4:103–109.
- 6 Spaeth GL, Henderer J, Liu C, Kesen M, Altangerel U, Bayer A, *et al*. The disc damage likelihood scale: reproducibility of a new method of estimating the amount of optic nerve damage caused by glaucoma. *Trans Am Ophthalmol Soc* 2002; 100:181–186.
- 7 Hodapp E, Parrish RK, Anderson DR. *Clinical decision in glaucoma*. St. Louis: The CV Mosby Company; 1993. pp. 52–61.
- 8 Thomas R, George R. Interpreting automated perimetry. *Indian J Ophthalmol* 2001; 49:125–140.
- 9 Bhatia J. Outcome of trabeculectomy surgery in primary open angle glaucoma. *Oman Med J* 2008; 23:86–89.
- 10 Topouzis F, Tranos P, Koskosas A, Pappas T, Anastasopoulos E, Dimitrakos S, Wilson MR. Risk of sudden visual loss following filtration surgery in end-stage glaucoma. *Am J Ophthalmol* 2005; 661–667
- 11 Kolker AE. Visual prognosis in advanced glaucoma: a comparison of medical and surgical therapy for retention of vision in 101 eyes with advanced glaucoma. *Trans Am Ophthalmol Soc* 1977; 75:539–555.
- 12 Costa VP, Smith M, Spaeth GL, Gandham S, Markovitz B. Loss of visual acuity after trabeculectomy. *Ophthalmology* 1993; 100:599–612.
- 13 Aggarwal SP, Hendeles S. Risk of sudden visual loss following trabeculectomy in advanced primary open-angle glaucoma. *Br J Ophthalmol* 1986; 70:97–99.
- 14 Lichter PR, Ravin JG. Risks of sudden visual loss after glaucoma surgery. *Am J Ophthalmol* 1974; 78:1009–1013.
- 15 O'Connell EJ, Karseras AG. Intraocular surgery in advanced glaucoma. *Br J Ophthalmol* 1976; 60:124–131.
- 16 Chandler PA, Grant WM. *Lectures on glaucoma*. Philadelphia: Lea and Febiger 1965. p. 136.