

Single Port Laparoscopic Colorectal Surgery: Prospective Study of 20 Egyptian Patients Having Different Indications

KARIM G. MOUSTAFA, M.D.*; HANY M. MIKHAIL, M.D.**; ABDRABOU N. MASHHOUR, M.D.** and AHMED F. FARAG, M.D.**

The Department of General Surgery, National Research Centre, Ministry of Scientific Research, Egypt and The Department of General Surgery, Faculty of Medicine, Cairo University***

Abstract

Background: Though less invasive than open and standard laparoscopic surgery, there are not enough data in the literature regarding evaluation of Single Incision Laparoscopic Surgery (SILS) for diverse colorectal diseases, including malignancy. Lately, we planned to implement this technique in our institution by a prospective study including 20 Egyptian patients. The objective was to master a technique preferred by most patients who are always fascinated by a scarless operation with a short hospital stay.

Patients and Methods: For a complete year ending December 2012, 20 patients having different indications for colorectal surgery were enrolled in the study. All were subjected to SILS. Exclusion criteria included: Patients with Body Mass Index (BMI) >35, T4 cancer and recurrent and emergency cases.

Results: Patient list included 12 females and 8 males having mean age 50 years (range: 18-70). Median ASA (American Society of Anaesthesiologists) grade was I-II and mean BMI was 31 (range 22-35). The indication for the procedure was 17 malignant and 3 benign lesions. The operative time ranged from 60 to 300 minutes. The period of postoperative hospital stay ranged from 3-15 days. The intra-operative blood loss ranged from was 0-1700ml. Incidence of postoperative wound infection was 5%, a bit higher in rectal procedures. Conversion rate was 15% and the overall mortality rate was 5%.

Conclusion: SILS colectomy with or without proctectomy is a feasible and safe procedure for both benign and malignant colorectal diseases.

Key Words: *Single port laparoscopic surgery – Colectomy – SILS.*

Introduction

THE original rationale for replacing open surgery by laparoscopic surgery in the near past was to use

smaller wounds and reduce hospital stay, with consequent increase in patient satisfaction and reduction in treatment costs [1]. As a natural improvement, this was followed in the last two decades by the development of three outstanding changes in the procedure: Natural Orifice Transluminal Endoscopic Surgery (NOTES), Single Incision Laparoscopic Surgery (SILS) and Robotic Surgery. These techniques were apparently easy and acceptable for surgeons, cancer surgeons and gynaecologists who used them for multitudes of indications in their specialities. In this respect, colorectal surgeons were not an exception using the SILS, but unfortunately with higher incidence of complications that improved by time [2,3]. Additionally, laparoscopy here has the advantage of dissection of the mesocolon and mesorectum under vision by a true non touch technique [4]. The higher incidence of complications didn't cause any dispirit, thanks to patients' wish, as the procedure was preferred by most of them as a scarless operation and in the same time avoiding the use of natural orifices [5]. On a questionnaire-based study conducted by Rao et al., on 2010 patients' preferences between different available surgical options were recorded along with their choices for new innovative techniques. Single-port surgery was on the top (80.6%) [5]. The aim of the present study was to assess the feasibility of single port technique for doing colectomy with or without proctectomy for different indications including malignancy. The safety, limitations and complications of this new technique are also presented.

Patients and Methods

The study was conducted at the Surgery Department, Kasr Al Aini University Hospital, Cairo, Egypt from December 2011 through December

Correspondence to: Dr. Karim G. Moustafa,
The Department of General Surgery, National Research Centre,
Ministry of Scientific Research, Egypt

2012. It included 20 candidates with the following inclusion criteria: Having benign and operable malignant colorectal tumors and inflammatory bowel diseases not responding to medical treatment. All patients were fit for major surgery and a written informed consent was provided by all, after giving them the option to do open, standard multiport laparoscopic procedure or SILS. Exclusion criteria included obesity, emergency cases or medically unfit patients and also those with T4 malignancy even in the absence of systemic dissemination. Approval from the Ethical Committee of the Institution was taken before starting the work. The procedures performed were: Right hemicolectomy (7 cases), left hemicolectomy (6 cases), anterior rectal resection (2 cases), total colectomy (2 cases) and a single case for each of the following: Abdominoperineal resection, Hartman's reversal, and upper proctectomy with excision of a recto-vaginal fistula (Table 1). The device used for all was the rubber SILSTM Port by Covidien that accommodates up to three conventional straight laparoscopic instruments and separate insufflation attachment. (Fig. 1).

Technique: We adopted a relatively simple technique (described in details by Ramos-Valadez et al., in 2011 and refined by Rodrigo Pedraza et al., in 2012) [6,7] through a 5cm incision classically at or near the umbilicus. A medial to lateral approach was used as a standard technique in all cases with high ligation of the main vessel- in

malignancy-according to the site of tumour. Sealing the vessels was performed using the LigaSure and the stapled anastomosis was always done extracorporeally. It was essential in all cases particularly on the left side to expose the ureter and gonadal vessels. In rectal resection, the distal end was stapled using laparoscopic articulating stapler and on finishing dissection an end-to-end intracorporeal anastomosis was performed using circular stapler under direct vision. In all operations, the umbilical fascia was closed using interrupted vicryl sutures.

Results

The series included 20 patients, 12 females and 8 males. The mean age was 50 years (range: 18-70). Median ASA grade was II and mean BMI was 31 (range 22-35). Three cases were converted to open (15%), one due to left ureteric injury during rectal dissection as a part of excision of a recto-vaginal fistula, the second was due to distended ileum obstructing the view, and the third was due to a technical problem during closure of colostomy. The operative time ranges between 60 to 300 minutes. Postoperative hospital stay ranged from 3 to 15 days. Intra-operative blood loss ranged between 0-1700ml, and postoperative wound infection occurred only in one case (Table 1). In malignant cases, adequate proximal and distal safety margin was attained in all cases. There was a single mortality (5%) due to undetected duodenal injury in the course of performing total colectomy.

Table (1): SILS Procedure, Egyptian Series (2014) Operative and Postoperative Data.

Procedure	Number of cases	No.	Disease	MOT	Bl. L	H. stay
R. hemicolectomy	7	5	Cecal mass	120	1300	7
		2	Hepatic flexure mass			
L. hemicolectomy	6	4	Sigmoid mass	150	1430	9
		1	Sigmoid ulcer			
		1	Descending colon mass			
Upper proctectomy *	1		Recto-vaginal fistula	240	1700	12
LAR	2		High rectal mass	300	1600	15
APR	1		Low rectal mass	300	1600	15
Total colectomy **	2		Colorectal mass	250	1200	9
Closure of colostomy	1		Following Hartmann's procedure	60	—	3
Total	20					

Abbreviations:

LAR : Low anterior resection.
 APR : Abdomino-perineal resection.
 MOT : Mean operative time (in minutes).
 Bl. L : Amount of operative blood loss (mean in mls.).
 H. : Period of hospital stay in days.

Notes:

* Wound infection in one case (5%).
 Conversion rate was 15% (3 cases).
 In malignant masses the average number of lymph nodal retrieval 13-17.
 **Mortality: 5% (one case) due to undetected duodenal injury.

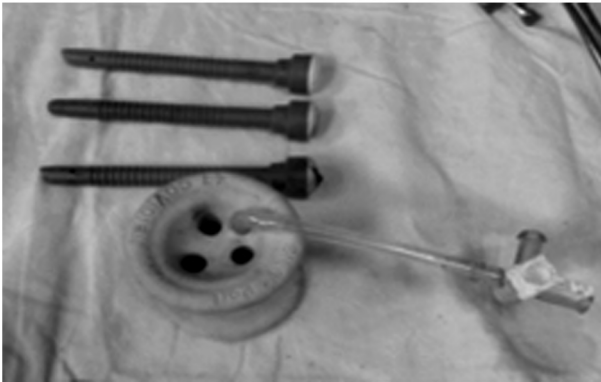


Fig. (1): The device rubber SILSTM Port by Covidien.

Discussion

Minimally invasive colorectal surgery is a safe and easy to learn approach for the management of many inflammatory and neoplastic (benign and malignant) diseases of the colon and rectum. This was further refined and advanced aiming at making it less invasive and diminishing potential complications, this was possible by the trend to reduce port modalities. This has also been shown to lower surgical blood loss and provides a quicker recovery [7]. The present study represents a single-institution single-surgeon experience, in single-incision colorectal laparoscopic surgery, an operation that exerts some technical challenges on the part of the surgeon, resulting from the coaxial instrumentation alignment including a reduced visual field, increased internal and external instrument clashing, and diminished range of motion [7]. Luckily enough these challenges did not tarnish- in the present series- the principles of surgery for malignant diseases, and the team succeeded in attaining adequate safety resection margins in all cases with adequate number of lymph nodes (mean 15.86). This gave a comparable result to those reported in recent international studies [5]. The wound used in the present work was a 5cm trans-umbilical midline incision extended to 8cm for extraction of the specimen. The site of the incision is subjected to variations according to the tumour size and site. For example, in a case of a right hemicolectomy, the caecal mass was 10x9cm and encroaching the umbilicus, making it impossible and even dangerous to place the SILS port through the umbilicus. A transverse suprapubic incision was used in this case. The length and the site of the incision seems to depend on many factors and is not unvarying Wong et al., in 2010 pointed that the trans-umbilical off-midline incision with average length of 5cm (range 4-8cm) was ideal, though in many studies the incision length extended up to 8cm for specimen

extraction and extracorporeal anastomosis [8]. An interesting incident in the present work was to use a colostomy site to insert the SILS port in a case of Hartman reversal. Cahill et al., was the first to use this technique [9]. The complication rate in the present series was acceptable 2/20 (10%) and comparable to previous reports [2,3,10,11] and also to classical laparoscopic surgery. This included wound infection, postoperative ileus, prolonged fever due to chest infection and vomiting. Although no anastomotic leakages have been reported in this work, there are two serious complications that warrant attention: The first was a ureteric injury that occurred during dissection of the rectum in the presence of extensive adhesions in a trial to repair a recto-vaginal fistula. This necessitated conversion to the open technique. This accident is not rare, as ureteric injury was commonly observed after sigmoid colon resections, low anterior resections, and abdominoperineal resections, and even during right hemicolectomies [8], and can be avoided by proper identification of the ureter along its entire course especially at the pelvic brim. The second was a thermal duodenal injury that was not detected intraoperatively and evidence for its presence was found on the second day and confirmed by abdominal ultrasonography. Conversion to laparotomy during SILS has been reported to be as high as 29%, and it has been associated with slow recovery and high postoperative morbidity. Morbid obesity may be a factor predicting conversion [7], but it is not an absolute contraindication. We had three cases that required conversion (15%). This conversion rate is acceptable compared to 17% in a similar study conducted in Poland [12]. However, it is higher than the conversion rate of 7% reported by Makino et al., [13]. Conversion is not always to the fully open procedure, but can be to multiple ports technique or even to hand assisted technique. The operative time in our series is reasonably short, ranging from 30-300 minutes. This short operative time is acceptable compared to previous reports. William et al. showed that the mean operative time for SILS colorectal surgery was 175min (range 145-280) [14]. The same results were shown by Gaujoux et al., with a median operating time of 150 (100-240)min [15], and by Leblanc et al., with a mean operative time of 155 minutes (range 90-280) [16].

Conclusion:

The present work proves that the SILS method is feasible in colorectal surgery and safe for cancer resections even in large tumors. The need for additional ports may be warranted in the learning period. The procedure is also feasible in palliative

stoma creation and reversal of Hartman's with no scars other than the stoma site. Conventional straight laparoscopic instrument can be used safely with comparable results with the usage of curved instrument.

References

- 1- SZINICZ G., RIEGLER M., MÜLLER W. and BELLER S.: Minimally invasive surgery (MIC) in the area of the colon and rectum: Technique of minimally invasive colorectal surgery. *Chirurg. Apr.*, 72 (4): 362-7, 2001.
- 2- KIM S.J., RYU G.O., CHOI B.J., et al.: The short-term outcomes of conventional and single-port laparoscopic surgery for colorectal cancer. *Ann. Surg.*, 254: 933-40, 2011.
- 3- WATERS J.A., RAPP B.M., GUZMAN M.J., et al.: Single-port laparoscopic right hemicolectomy: The first 100 resections. *Dis. Colon. Rectum.*, 55: 134-9, 2012.
- 4- FABIO CIANCHI^{1,2}, FABIO STADERINI^{1,2} and BENEDETTA BADI^{1,2}: Single-Incision Laparoscopic Colectomy: A New Era in the Treatment of Colorectal Cancer? "Colorectal Cancer-Surgery, Diagnostics and Treatment", book edited by Jim S. Khan, ISBN 978-953-51-1231-0, Doi: 10.5772/56871, 2011
- 5- RAO A., KYNASTON J., MACDONALD E.R. and AHMED I.: Patient preferences for surgical techniques: Should we invest in new approaches? *Surg. Endosc. Dec.*, 24 (12): 3016-25, 2010.
- 6- D.I. RAMOS-VALADEZ, C.B. PATEL, M. RAGUPATHI, M.B. BOKHARI, T.B. PICKRON and E.M. HAAS: "Single-incision laparoscopic colectomy: Outcomes of an emerging minimally invasive technique", *International Journal of Colorectal Disease*, Vol. 26, pp. 761-767, 2011.
- 7- RODRIGO PEDRAZA^{1,2}, ALI AMINIAN^{1,2}, JAVIER NIETO^{1,2}, CHADI FARAJ^{1,2}, T. BARTLEY PICKRON^{1,2} and ERIC M. HAAS: In Minimally invasive colorectal surgery/Cirugía colorrectal mínimamente invasiva. *Cirugía y Cirujanos*, Vol. 80, No. 1, pp. 1-2, 2012.
- 8- WONG M.T., NG K.H., HO K.S. and EU K.W.: Single-incision laparoscopic surgery for right hemicolectomy: Our initial experience with 10 cases. *Tech. Coloproctol. Sep.*, 14 (3): 225-8, 2010.
- 9- CAHILL R.A., LINDSEY I., OLIVER J., GUY R., MORTENSEN N. and CUNNINGHAM C.: Single-port laparoscopic total colectomy for medically uncontrolled colitis. *Diseases of the Colon and Rectum*, 53: 1143-7, 2010.
- 10- RIEGER N.A. and LAM F.F.: Single-incision laparoscopically assisted colectomy using standard laparoscopic instrumentation. *Surg. Endosc.*, 24: 888-890, 2010.
- 11- STOCCHI L. and NELSON H.: Laparoscopic colectomy for colon cancer: Trial update. *J. Surg. Onc.*, 68: 255-267, 1998.
- 12- MYNSTER T., HAMMER J. and WILLE-JØRGENSEN P.: Preliminary results after single-port laparoscopic colonic surgery. *Dan. Med. J. Dec.*, 59 (12): A4551, 2012.
- 13- MAKINO T., MILSOM J.W. and LEE S.W.: Feasibility and safety of single-incision laparoscopic colectomy: A systematic review. *Ann. Surg.*, 255: 667-76, 2012.
- 14- WILLIAM T., SHENG-CHI C., HUA-CHE C., WAN-YU L., LONG-BIN J., CHRISTINA W., et al.: Single-incision laparoscopic versus conventional laparoscopic right hemicolectomy: A comparison of short-term surgical results. *Surg. Endosc.*, 25: 1887-1892, 2011.
- 15- GAUJOUX S., BRETAGNOL F., FERRON M. and PANIS Y.: Single-incision laparoscopic colonic surgery. *Colorectal Disease*. Volume 13, Issue 9, pp. 1066-1071, 2011.
- 16- LEBLANC F., CHAMPANGE B.J., AUGESTAD K.M., et al.: Single incision laparoscopic colectomy: Technical aspects, feasibility, and expected benefits. *Diagn. Ther. Endosc.*, 913216, 2010.