

From the Faculty of Medicine, Ain Shams University, Cairo,  
and the Faculty of Veterinary Medicine, Cairo University, El-Gizeh

## Tinea capitis in Egypt

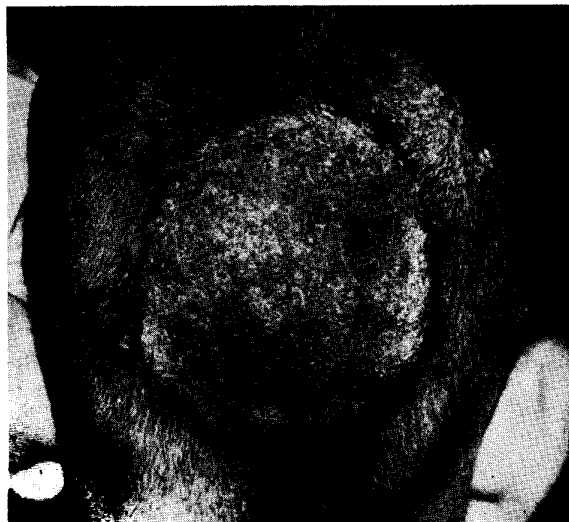A. ABDEL FATTAH, M. REFAI and ZENAB EL-GOTHAMY

Ringworm of the scalp still represents a major problem among children of school-age in Egypt. One of the earliest reports which dealt with this subject was that by SCANDER (7) in 1928 who isolated *Trichophyton violaceum*, *T. crateriforme*, *T. acuminatum* and *T. gypseum* in this order of frequency from cases of tinea capitis among children. GOHAR (3) in his book „Mycosis and Practical Mycology“ did not mention the relative frequency of species causing tinea capitis in Egypt but he briefly stated that *T. violaceum* is common in Mediterranean countries.

In 1953 KENEDY (4) examined 217 cases of tinea capitis in Alexandria and reported that *T. violaceum*, *T. ectoendothrix*, *T. ectothrix*, *M. audouinii*, *favus* and *M. canis* are the responsible species. His report depended mainly on clinical and microscopical examination and occasionally on cultural identification.

The value of accurate laboratory diagnosis of dermatophytosis should be reemphasised due to its importance in determining the source of infection, mode of treatment, general management and prognosis. Reviewing the world literature we found that reports coming out from Egypt dealing with the subject of dermatophytes causing ringworm of the scalp are relatively few.

In the last two years we examined 250 cases referred to the mycology laboratory with the clinical diagnosis of either tinea capitis, especially the black dotted form (*fig. 1*),



**Fig. 1:** Black dotted tinea capitis due to *Trichophyton violaceum* in a boy 10 years old

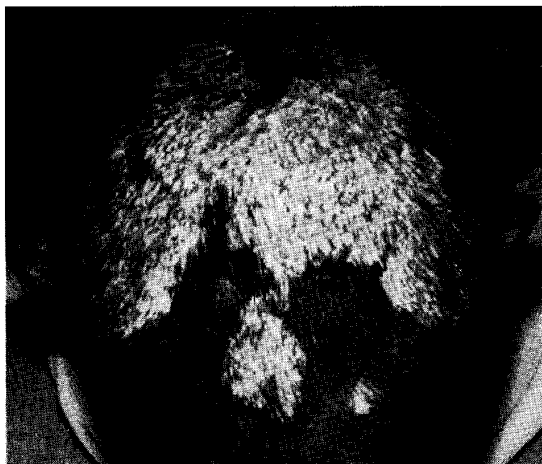


Fig. 2: A white-headed case of favus due to *Trichophyton schoenleinii*

or favus (fig. 2 and 3), sometimes the white-headed form. The method used by us is the usual one, the area affected is cleaned at first with 70% alcohol, few hairs are plucked off with previously heated non-toothed forceps and scales are collected by scraping with a sterile blunt scalpel. Some of the material collected are put on a slide in one or two drops of 15% KOH and covered with a coverglass, heated gently and left for 15—20 minutes to be examined microscopically. The remaining portion of the specimen is inoculated on the spot in SABOURAUD-chloramphenicol-cycloheximide agar.

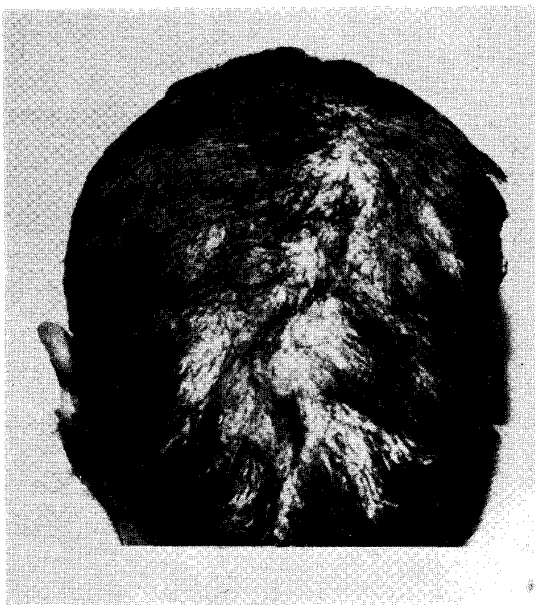

Fig. 3: Scaly favus due to *Trichophyton schoenleinii* in a boy

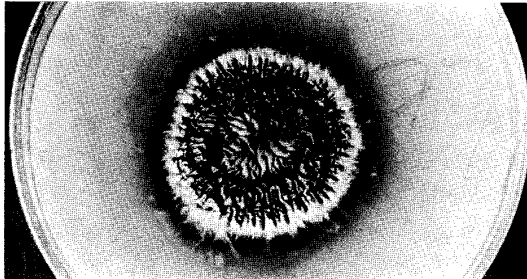


Fig. 4: *Trichophyton violaceum*. Culture on SABOURAUD's pepton agar, 40 days, at room temperature

#### Results:

In the 250 cases examined by us, *T. violaceum* (fig. 4) was the commonest cause of scalp ringworm (53%), then comes *T. schoenleinii* (26.7%) (fig. 5), followed by *M. canis* (18.8%) and small percentages due to *T. mentagrophytes* and *T. tonsurans*.

The results of the laboratory investigation are shown in table 1

Table 1

Method of examination		Number of cases	%
microscopic +	culture +	150	60%
microscopic +	culture $\phi$	18	7.2%
microscopic $\phi$	culture +	22	8.8%
microscopic $\phi$	culture $\phi$	60	24%
total		250	

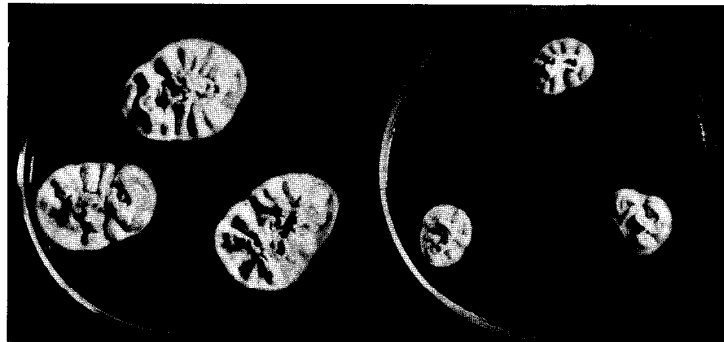

Fig. 5: *Trichophyton schoenleinii*. Left PETRI dish: Culture on SABOURAUD's glucose agar; right PETRI dish: Culture on SABOURAUD's pepton agar

Table 2

Dermatophyte	Number of cases	%
<i>T. violaceum</i>	92	53.3%
<i>T. schoenleinii</i>	46	26.7%
<i>T. tonsurans</i>	1	0.6%
<i>T. mentagrophytes</i>	1	0.6%
<i>M. canis</i>	32	18.8%
total	172	

Species identified in 172 positive cultures are shown in table 2.

#### Discussion

Probably the first reliable mycological study on tinea capitis in Egypt was the work done by MIKHAIL (5) in 1953 who reported that between 303 cases of ringworm of the scalp, 76% were found due to *T. violaceum*, 6% *M. canis* and 5% due to *T. sulfureum*, *T. schoenleinii*, *T. discoides*, *T. mentagrophytes* and *T. ferrugineum*. In 13% of the cases he failed to determine the causative fungi.

In the 250 cases examined by us, *T. violaceum* was the commonest cause of scalp ringworm (53%) then comes *T. schoenleinii* (26.7%) in the second place, followed by *M. canis* (18.8%) and small percentages due to *T. mentagrophytes* and *T. tonsurans*.

The prevalence of *T. violaceum* as a cause of Tinea capitis (fig. 6) found in this survey is in agreement with the finding of COUTELEN et al (1) in Tunisia, Tripoli, Morocco, Algeria and Egypt. In a clinical laboratory study of tinea capitis in Egypt GALLOWAY et al (2) found that by direct examination of 300 consecutive cases, 184 showed endothrix

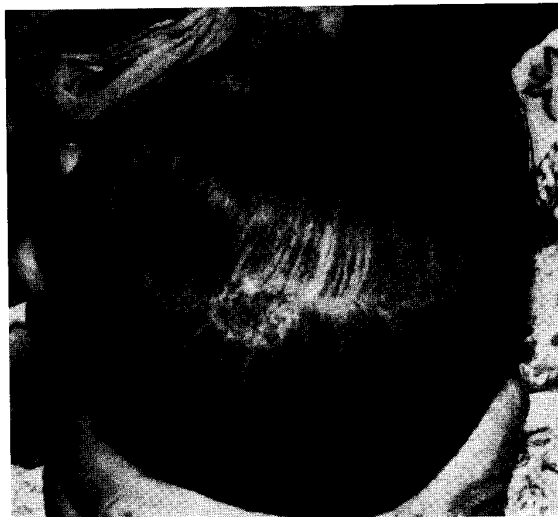

Fig. 6: Black dotted ringworm due to *Trichophyton violaceum* in a girl 8 years old

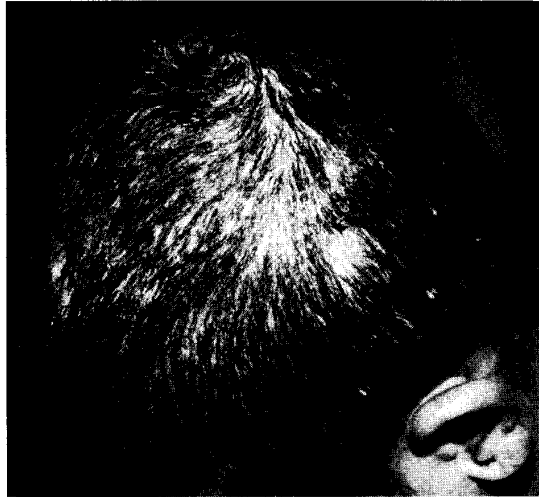

Fig. 7: Scaly ringworm due to *Microsporum canis* in a boy

infection and 116 endothrix infection of favic type. Cultural examination of „40 Random Cases“ yielded 20 isolates of *T. schoenleinii*, 16 of *T. violaceum* 2 *T. mentagrophytes* and 2 *M. canis*. The author stated that *T. schoenleinii* and *T. violaceum* caused the majority of the tinea capitis infections seen in both rural and urban Egypt. They also reported that although they isolated *T. mentagrophytes* and *M. canis* from a few cases only, the latter organism seemed to be rapidly increasing in the larger cities. This would appear to have been borne out this present study carried out 10 years later. TAYLOR and BASSALY (8) reported in 1964 on 400 cases of tinea capitis among Egyptians, of these 162 were due to *T. violaceum*, 139 *M. canis*, 19 *T. schoenleinii*, 30 *T. violaceum* + *M. canis*, 1 *T. violaceum* + *T. schoenleinii* and 1 due to *T. schoenleinii* + *M. canis*. *T. violaceum* and *M. canis* (fig. 7 and 8) were predominantly urban and *T. schoenleinii* rural.

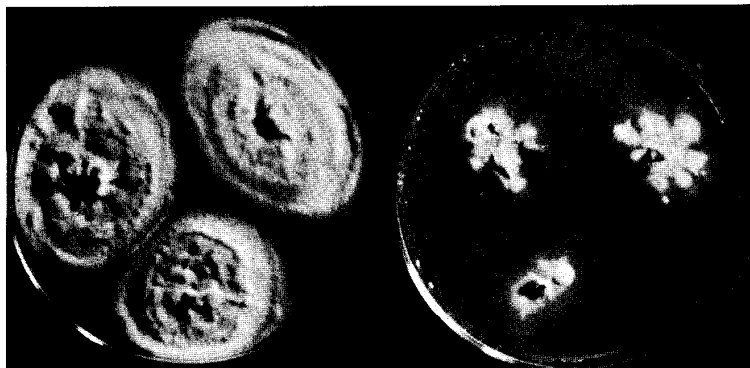

Fig. 8: *Microsporum canis*. Left PETRI dish: Culture on SABOURAUD's glucose agar; right PETRI dish: Culture on SABOURAUD's pepton agar

In a recent report of a survey of small Egyptian mammals for pathogenic fungi, TAYLOR et al (9) reported the isolation of *T. mentagrophytes* and *M. gypseum* from rodents. These two ringworm fungi were found very infrequently, only 15 isolates being made from over 2000 animals examined, and no lesions were detectable on the animals which probably acted only as passive carriers of the spores. The authors stated that *M. gypseum* has not been reported in Egypt and no cases were seen in the present survey to be due to this dermatophyte. However, REFAI and RIETH (6) were able to isolate *M. gypseum* and *T. mentagrophytes* from Egyptian soil. They stated that the soil can be incriminated as a source of infection to man and animals. Further investigations regarding *T. violaceum*, which is the commonest cause of tinea capitis in Egypt, are in progress.

### Summary

In 250 cases of tinea capitis in Egypt *T. violaceum* was isolated from 92 cases, *T. schoenleinii* from 46 cases, *M. canis* from 24 cases. *T. mentagrophytes* and *T. tonsurans* each was isolated once. The literature dealing with ringworm of the scalp in Egypt all pointed to *T. violaceum* being the commonest causative fungus. *M. audouinii* is not encountered in our survey.

### Zusammenfassung

In den letzten zwei Jahren wurden 250 Fälle von Kopfpilzkrankungen mykologisch untersucht. In 172 Fällen konnte der Erreger kulturell nachgewiesen werden. In 92 Fällen (53,3%) wurde *Trichophyton violaceum* isoliert, in 46 Fällen (26,7%) war *Trichophyton schoenleinii* der Erreger, in 32 Fällen (18,8%) *Microsporum canis*. *Trichophyton mentagrophytes* und *Trichophyton tonsurans* wurden je einmal isoliert. *Microsporum audouinii* wurde nicht angetroffen.

Aus einer Übersicht über die Literatur ergibt sich, daß *Trichophyton violaceum* der häufigste Erreger der Kopfpilzkrankungen in Ägypten ist.

### References

1. COUTELEN, F., COCHET, G., BIGUET, J., MULLET, S., DOBY-DUBOIS, M. and DE BLOCK, S.: Contribution à la connaissance épidémiologique et mycologique des teignes infantiles de Tunisie. *Annales de parasitologie Humaine et comparée*, 31, 4 : 449—469 (1956).
2. GALLOWAY, C. B., SOLIMAN, A. A. and NEPTUNE, M. C.: *Tinea capitis* — a clinical laboratory study of 1000 cases. Collected papers of Medical Research Unit No. 3, vol. 13, Abbassia.
3. GOHAR, N.: *Mycosis and Practical Mycology*. London: Ballière, Tindall and Cox 1948.
4. KENEDY, A. A.: Is thallium epilation dangerous in childhood? *J. Egypt. Med. Ass.* 36, 59 (1953).
5. MIKHAIL, G. R.: *Tinea capitis*. A mycological study of three hundred and three cases. *J. Egypt. Med. Ass.* 37, 538 (1954).
6. REFAI, M. and RIETH, H.: Das Vorkommen von Dermatophyten in ägyptischem Erdboden. *Zbl. Vet.-Med.* 11, 200—206 (1964).
7. SCANDER, N.: *Comptes Rendus du Congrès International de Médecine Tropicale et d'Hygiène*, le Caire. Government Press. vol. 3 (1931).
8. TAYLOR, W. W. and BASSALY, M.: *Tinea capitis* — a study of 400 Egyptian cases. *J. Trop. Med. Hyg.* 67, 180—182 (1964).
9. TAYLOR, W. W., RADCLIFFE, F. and VAN PEENEN, P. F. D.: A survey of small Egyptian mammals for pathogenic fungi. *Sabouraudia* 3, 2 : 140—142 (1964).

Anschr. d. Verf.: Dr. A. ABDEL FATTAH and Dr. ZENAB EL-GOTHAMY, Faculty of Medicine, Ain Shams University, Cairo; Dr. M. REFAI, Faculty of Veterinary Medicine, Cairo University, El-Gizeh, U. A. R.