

**RINGWORM IN CATTLE CAUSED  
BY TRICHOPHYTON VERRUCOSUM**

BY

M. REFAI\* and M. MILIGY\*

**SUMMARY**

- The literature on cattle ringworm and its transmission to man is reviewed.
- In 24 animal out of 55 clinically suffering from ringworm, *T. verrucosum* was isolated and identified as well as 14 cases was positive only microscopically constituting totally a rate of incidence equals 69%.
- *Trichophyton verrucosum* is still the predominant cause of cattle ringworm in U.A.R.

In previous works the authors described ringworm in cats caused by *Microsporum canis* and *Trichophyton rubrum* and discussed their role in transmission of infection to man.

In cattle, ringworm is a disease frequently seen on markets, slaughter-houses and governmental farms. As far as we know, no attempts has been performed to study the causative organisms.

Ringworm in cattle was recorded as an earliest accounts of fungal disease in domesticated animals. Blank, 1953; Ford, 1956; Hajsig, 1957, and Even-Paz and Raubitschek, (1960). In Britain, Jillson and Buckley (1952) stated that *T. verrucosum* var *discoides* is the commonest cause of ringworm in cattle. La Touche (1952) reported 24 cases of *T. verrucosum* ringworm from the Leeds area. and stated that *T. verrucosum* was the only fungus isolated.

Ozegovic and Grin (1957) in Yugoslavia and Klokke (1961) in Netherlands, found that *T. verrucosum* constituted about 93% and 93.3% of the dermatophytes causing infection in cattle.

Although accurate figures of the incidence of this infection among cattle are not available, it is generally stated to be high and the disease appears to vary widely in different localities of

\* Faculty of Veterinary Medicine, Cairo University.

the world and fluctuates greatly from year to year, calves were found to be more susceptible than older animals (La Touche 1952; Sartory et al., 1957; Ozegovic and Grin, 1957; and Hajsig and Zukovic 1961) which are less susceptible unless they are in poor condition from any disease or bad hygienic measures (Hagan, 1957).

In 1820, Ernst was the first to record a case of young girl that have been infected through contact with a cow suffering from ringworm. Since that time, an increase interest has been evoked in ringworm in animals and it was frequently reported as a source of infection to man. *Trichophyton verrucosum*, which was the usual cause of cattle ringworm, produced marked inflammatory reaction in man accompanied by exudate with pus formation; Blank, 1953; Saunders, 1954; Main, 1959; and English, 1961).

## MATERIALS AND METHODS

### **Clinical Findings :**

A total of 55 animals were clinically examined. They showed sharply defined lesions which more or less rounded, vary in size, often fuse together and form large irregular areas measuring up to several cms. in diameter.

The affected areas were covered with thick greyish white crusts with numerous embedded hairs which were dry & broken off easily leaving short stumps. When the crusts were removed forcibly, a moist bleeding base was seen (Photo 1).

It was difficult to clean the lesions as usual with alcohol as the animals were frightened & nsteady. The hairs and scales were collected in paper envelop on which the clinical symptoms were summarized.

### **Microscopical Examination :**

One part of the sample was examined directly under the microscope. The hairs & scales were put on a slide with few drops of 15% KOH and covered by cover glass. The preparation was heated gently over a low flame & left for two hours then examined under the microscope.

### **Culture method :**

The other part of the sample was inoculated on the surface of Sabouraud dextrose agar to which antibiotics were added (40 I.U.

Penicillin, 20 I.U. Streptomycin+0.5 gm. Actidione/liter) to inhibit growth of contaminating bacteria and molds. To Sabouraud media, Vitamins (Thiamine, Inositol and Riboflavin 50mg./litre) were added to facilitate the primary isolation. The plate cultures were incubated at 30°C for 2—3 weeks. The cultures were examined weekly interval for evidence of growth and transplants were made for pure culture study.

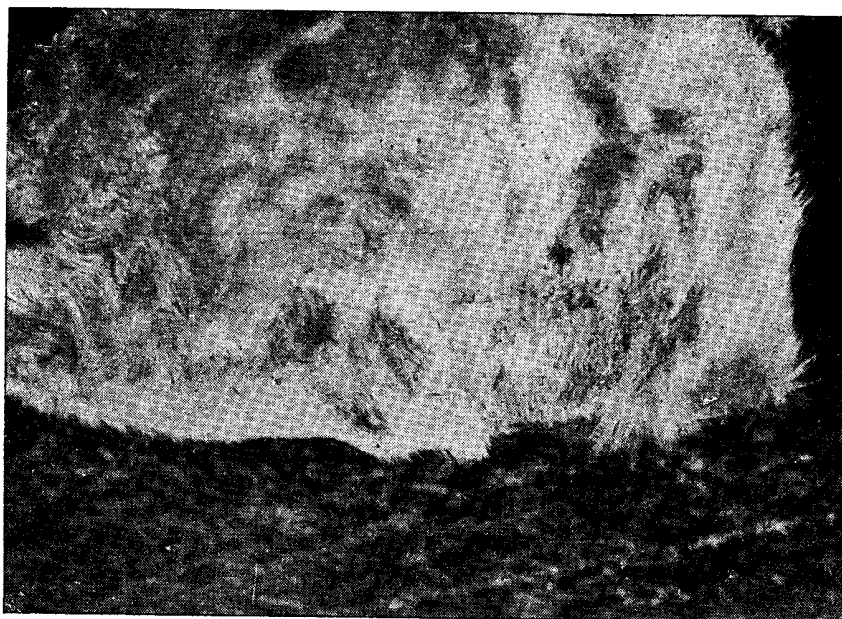


Photo 1 : A cow showing ringworm  
(loss of hairs and crusts formation)

#### **Microscopical Examination of Culture Mounts :**

Cultures were examined microscopally by removing a small part of colony by means of a sterile slightly bent wire on a slide. The material was fragmented into very small parts by means of 2 dissecting needles and a drop of lactophenol-cotton blue was added. A cover glass was placed and the preparation was heated gently on a low flame to drive out air bubbles and produce greater penetration of the stain.

## RESULTS

### **Direct Microscopical Examination ;**

Only 38 samples out of 55 gave positive result. The scales presented fungal spores arranged in chains (arthospores) and the hairs showed ectothrix hair invasion i.e. fungal spores arranged outside hair shaft. The spores were of large type ranging from 7—10 u in diameter.

### **Cultural Examination :**

In 24 out of the 55 samples, cultures of dermatophytes were obtained. All cultures showed the same characteristics on Sabouraud, which denotes that we deal with one organism. The colony was small, slow growing, disc shaped, at first waxy in appearance then developed white powdery surface. (Photo 2).

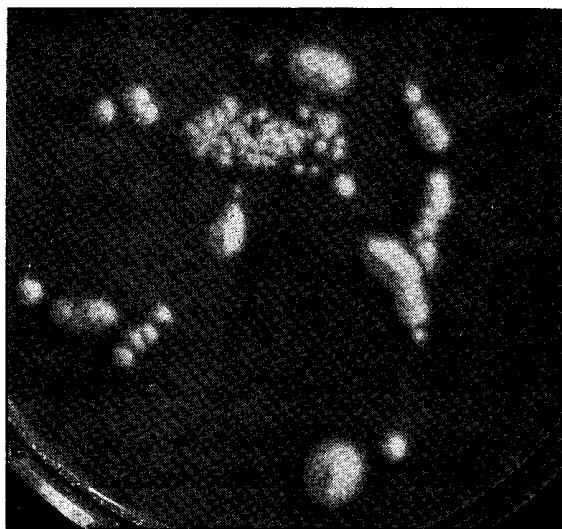

Photo 2 : *T. verrucosum*, 12 days old culture on Sabouraud agar.

Microscopically, thin irregular mycelium with numerous chlamyospores were seen. The dermatophyte was therefore identified as *Trichophyton verrucosum*.

It is interesting to note that *T. verrucosum* grew in the presence of vitamins added as well as in its absence, though, addition of thiamine & inositol resulted in rapid growth and the colony attained a bigger diameter up to 2 cms in 2 weeks.

Table 1  
Results of microscopic and cultural  
examination of 55 cases of cattle ringworm.

Cultural + Microscopic +	Cultural — Microscopic +	Cultural — Microscopic —	Total
24	14	17	55

### DISCUSSION

It is generally known that *Trichophyton verrucosum* is the predominant cause of cattle ringworm (Ozegovic and Grin, 1957 and Klokke 1961).

Nowadays the problem of animal mycosis became very important due to : (El-Fiki and Rieth 1958).

- a) The presence of dermatomycosis in animals is a constant source of infection for persons who come in contact with those animal or who live in rural areas especially farmers ...
- b) The knowledge of the extent of dermatomycosis in animals, as well as the species of pathogenic fungi, is important in epidemiological studies concerning the problem of mycotic epidemics in animals beside the improving methods for the treatment and control of this disease.

Ashton in 1932, summarised the result of an inquiry made among 384 general practitioners in rural areas throughout England and Wales and found that 296 had seen cases of cattle ringworm, and only 132 had not. Sylvest in Denmark in 1949 reported a rapid increase of ringworm infection from 1000 cases to over 4000 within 4 years period. In a survey of animal mycosis described by Anisworth and Austwick (1955), 41 cases of 71 were positive which had clinical symptoms of ringworm with an incidence of 57.8%.

In the present work and as shown in table 1, only 24 animals out of 55 having a clinical symptoms of ringworm, it was possible to isolate and identify *T. verrucosum*; however, in another 14 cases

it was positive only microscopically but cultures could not be obtained. The failure in isolation of the fungus in the microscopical positive cases may be due to the rapid growth of the contaminants in spite of the incorporation of antibiotics into the media or the fungus that present in the hairs and scales has been died. Therefore, only 38 cases could be confirmed by laboratory diagnostic method (69%) and in the remaining 17 cases, it was impossible to detect the organism either microscopically or culturally that it may be due to other causation having ringworm-like lesions as in seborrhea, eczema or vitamin deficiency.

It has found that the obtained results (69%) in this study was in agreement with that recorded by Ainsworth & Austwick (1955) that constituted 57.8% with a comparatively slight increase. Accordingly, *T. verrucosum* occupied the first place between the causative dermatophytes followed by *T. metagrophytes*, *T. violaceum* and *M. canis*; Rook, 1956 and Ozegovic & Grin, 1957).

From the epidemiological point of view, the incidence of ringworm in cattle were said to be influenced by certain factors as age, season, nutrition & hygienic condition (Rook, 1956; Hajsig, 1957; and Hajsig & Asaj 1962) & Mention should be paid to the transference of infection either directly or indirectly from infected animals to man (Blank & Craig, 1954, Coudert 1955 & Faninger 1962) as human ringworm acquired from cattle was distressing to patients & even sometimes leaving diffiguring scars.

General speaking, the state of nutrition, the care & management, the sanitary uncrowded dwellings with the application of the general hygienic measures materially minimize the incidence of infection both in man & animals & to obtain rapid spontaneous cure.

## REFERENCES

- Ainsworth, G.C. and Austwick, P.K.C. (1955) A survey of animal Mycoses in Britain : General aspects. *Vet. Rec.*, **67**, 88.
- Ashton, G. (1932) Cattle ringworm in man. *Lancet*, **1**, 97.
- Blank, F. (1953) Ringworm of cattle due to *T. discoides* and its transmission to man. *Canad. J. Comp. Med.* **17**, 277.
- Blank, F. and Craig, G.E. (1954) Family epidemics of ringworms contracted from cattle. *Canad. M.A.J.* **71**, 234-235.

- Coudert, J. (1955) Large-spored tinea of the scalp in a child, caused by *Trichophyton album*. *Ann. Parasit. hum. Comp.* **30**, 144-149.
- El-Fiki, A.Y. and Rieth, H. (1958) A short survey of dermatomycoses in animals. *Vet. Med. J., Fac. Vet. Med., Cairo University*, **5**, 359-367.
- English, M.P. (1961) Fungus infections of the skin in Bristol and the West Country. *Med. J.S.W.* **76**, 112-120.
- Ernst (1820) Cited by Ashton, G. (1932) Cattle ringworm in man. *Lancet*, **1**, 97.
- Even-Paz, Z. and Raubitschek, F. (1960) Epidemics of tinea capitis due to *T. verrucosum* contracted from cattle or sheep. *Dermatologica, Basel*, **120**, 74-82.
- Faninger, A (1962) Uber die beruflich bedingte Trichophytie. *Berfusdermatosen*, **10**, 27-33.
- Ford, E.J.H. (1956) Ringworm in cattle. An account of an outbreak. *Vet. Rec.* **68**, 803.
- Hagan, W.A. (1957) The infectious diseases of domestic animals, 3rd Ed. Comstock. Publ. Associates. Ithaca, N.Y.
- Hajsig, M. (1957) *T. verrucosum* in cattle in the region of the P.R. Croatia. *Vet. Arh. (Zagreb)* **27**, 315-322.
- Hajsig, M. and Zukovic, M. (1961) Isolation of *T. verrucosum* from the sucking and biting lice of cattle and investigation of the effect of delousing upon the course of trichophytosis.
- Hajsig, M. and Asaj, A. (1962) Investigation on the effect of the stabling of cattle upon the occurrence of ringworm. *Vet. Archiv.* **32**, 26-29.
- Jillson, O.F. and Buckley, W.R. (1952) Fungus disease in man acquired from cattle and horses due to *T. faviforme* New England J. Med. **246**, 996-999.
- Klokke, A.H. (1961) Short report of a systematic investigations into animal mycoses in cattle and man. *T.N.O. Nieuws*, 577-578.
- La Touche, C. J. (1952) Some observations on ringworm in calves due to *T. discoides*. *Vet. Rec.* **64**, 841.
- Main, P.T. (1959) Ringworm contracted from cattle : A two year's survey in general practice. *Practitioner* **182**, 347-354.
- Ozegovic, L. and Grin, I. E. (1957) : Dermatomycosis in domestic animals in our country with special attention to their spread in Bosnja and Herzegovina *Veterinaria, Sarajevo* **6**, 2-3.
- Rook, A. (1956) Animal ringworm. *Trichophyton discoides* and *mentagrophytes* in the cambridge area. *Brit. J. Derm.* **68**, 11-15.

Sartory, A., Sartory, R. and Kocher, F. (1943) A Common dermatophytosis of calves caused by a sp. of the genus *Trichophytosis*. C.R. Acad. Sci. Paris, cc **XVI**, 578-579.

Saunders, W. (1954) Inflammatory ringworm due to *T. faviforme*. Report of three cases in one family. *Arch. Derm.* **69**, 365-366.

Sylvest, B. (1949) *Acta Derm. Vener. Stock*, 29 225 cited by Rook, A.J. and Frain-Bell, W.(1954) cattle ringworm. *Brit. Med. J.*, **2**, 1198.