

From the Faculty of Veterinary Medicine, Cairo University, El-Giza, Egypt

Laboratory acquired infection with *Keratinomyces ajelloi*

M. REFAI and A. H. ALI

A technician who attends the animal house at the "Chemical Industries Development" CID, has developed small, greyish-white, fine scaly lesions on both hands (Foto 1).

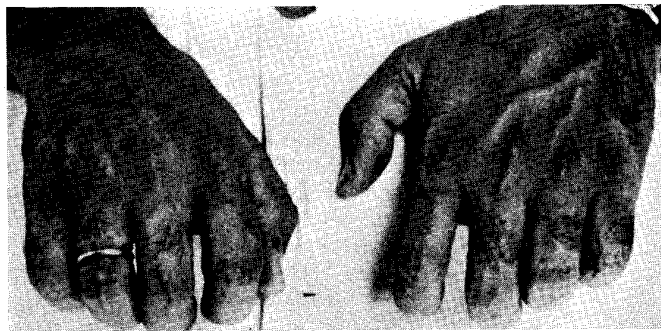


Foto 1: Fine scaly lesions due to *K. ajelloi*

Microscopical examination of the scales revealed the presence of fungal hyphae. This observation encouraged us to make culture. The scales were inoculated on Sabouraud's dextrose agar and incubated at room temperature. Rapidly growing light brown colonies were obtained within one week (Foto 2).

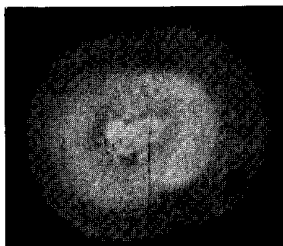


Foto 2: 1 week old culture of *K. ajelloi*

Microscopical examination of the colonies revealed the presence of only sterile hyphae. The culture was considered as a contaminant and no further trials were done for proper identification. At the same time progressing self-healing of the lesions was noticed. Fortunately, however, the plates were not discarded. As it is our custom to have a look at the plates or tubes before discarding them, we noticed dark-red pigmentation on the reverse of the colonies. The surface of the culture became powdery denoting sporulation

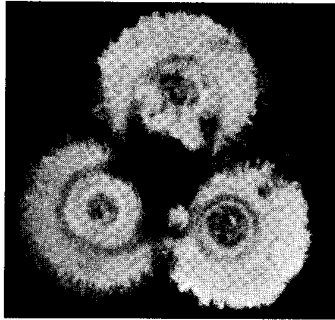


Foto 3: 3 week old culture of *K. ajelloi*

(Foto 3). Microscopical examination of culture mounts revealed numerous macroconidia typical of *Keratinomyces ajelloi*.

It is an interesting finding; as this is the first time to record *Keratinomyces ajelloi* in Egypt and to report the infection in man.

Although this fungus was found in soil in most parts of the world, REFAI and RIETH (1964) and REFAI (1967) failed to isolate it from the soil in Egypt. Samples from the walls and floors of the CID laboratory were free from *K. ajelloi*, however soil samples from animal house yielded only *Trichophyton mentagrophytes*. Our suspicion was then directed to the laboratory animals although the 250 mice found at that time in the house were apparently healthy and presented no lesions or loss of hairs.

Hairs from 5 different parts of the body of 250 mice were cultured. Surprisingly *Keratinomyces ajelloi* was observed in 7 samples from 2 mice. The other samples yielded mostly *Scopulariopsis*.

In the literature there are many reports of laboratory-acquired infections. RIETH et al. (1960) described infection of a technical assistant and a laboratory worker with *Trichophyton mentagrophytes* during injecting mice with the fungus. KAFFKA and RIETH (1958) reported *T. mentagrophytes* infection in a technical assistant who handled an infected rabbit. DOLAN and co-workers (1958) reported 3 dermatophytic infections with *T. mentagrophytes* that were properly transmitted from laboratory animals.

In our case, it seems that infection was transmitted to the technician from mice.

References

1. DOLAN, M. M.; KLIGMAN, A. M.; KOBYLINSKI, P. G. and MOTSAVAGE, M. A. (1958): Ringworm epizootics in laboratory mice and rats: Experimental and accidental transmission of infection. *J. Invest. Derm.* 30, 23—25.
2. HANEL, E. and KRUSE, R. (1967): Laboratory-acquired mycoses. Dept. Army. Fort Detrick, Frederick, Maryland.
3. KAFFKA, A. and RIETH, H. (1958): Laboratoriumstiere als Ursache einer Berufsdermatomykose und Maßnahmen zur Verhütung weiterer Pilzinfektionen. *Zbl. Bakt. I. Orig.* 171, 319—321.
4. REFAI, M. and RIETH, H. (1964): Das Vorkommen von Dermatophyten in ägyptischem Erdboden. *Zbl. Vet.-Med.* 11, 200—205.
5. REFAI, M. (1967): Dermatophytes in soil in Egypt. Under publication.
6. RIETH, H. and EL-FIKI, A. Y. (1959): Dermatomykose beim Pferd durch *K. ajelloi*. *Bull. Pharm. Res. Inst. Osaka* 21, 1.
7. RIETH, H., SCHIRREN, C., EL-FIKI, A. Y. and ITO, K. (1960): Beziehungen zwischen humanen und animalen Dermatomykosen. III. Direkte und indirekte Übertragung von Mäuse-*Trichophytie* auf Menschen. *Bull. Pharm. Res. Inst. Osaka* 25, 15—18.

Address for reprints: Dr. M. REFAI, Faculty of Veterinary Medicine, Cairo University, El-Giza, Egypt, U. A. R.