

From the Faculty of Veterinary Medicine, Cairo University, El-Giza, Egypt

Incidence of epizootic lymphangitis in Egypt with reference to its geographical distribution

MOHAMED REFAI and AHMED LOOT

The epizootic lymphangitis, known also as African farcy or pseudo-glanders, is a fungus disease of equines caused by diphasic fungus identified by RIVOLTA (1873) as *Cryptococcus farciminosum*. VUILLEMIN (1901) named it *Saccharomyces farciminosum*. In 1934, the fungus was classified by CIFERRI and REDAELLI in the genus *Histoplasma*, as *H. farciminosum*.

The disease involves the skin and associated lymphatics and the lesions are mostly noted upon the inner parts of the limbs, the withers, the back, breast, sides, metatarsal and metacarpal regions of the limbs, with the appearance of distinct cording of the adjoining lymphatics, which are at first hard and then soften and ulcerate (See foto 1, 2, 3). Lesions may also occur in mucous membranes, lungs and internal organs (MARCATO, 1947, ARTIOLI, 1948 and SINGH, 1966).

In the twentieth century, 3 major outbreaks of epizootic lymphangitis were noted (AINSWORTH and AUSTRICK, 1959). The first epidemic was reported in England and Ireland after the South African war. The second occurred in Europe during the first world war, and the third one in Italy, Burma and India during the second world war. However, slaughter policy was successful in eradicating the disease in England (PALLIN, 1904), and since that time no cases were recorded in that country. In Canada the last incidence of the disease was in 1923, and in Denmark and Czechoslovakia no record since 1946.


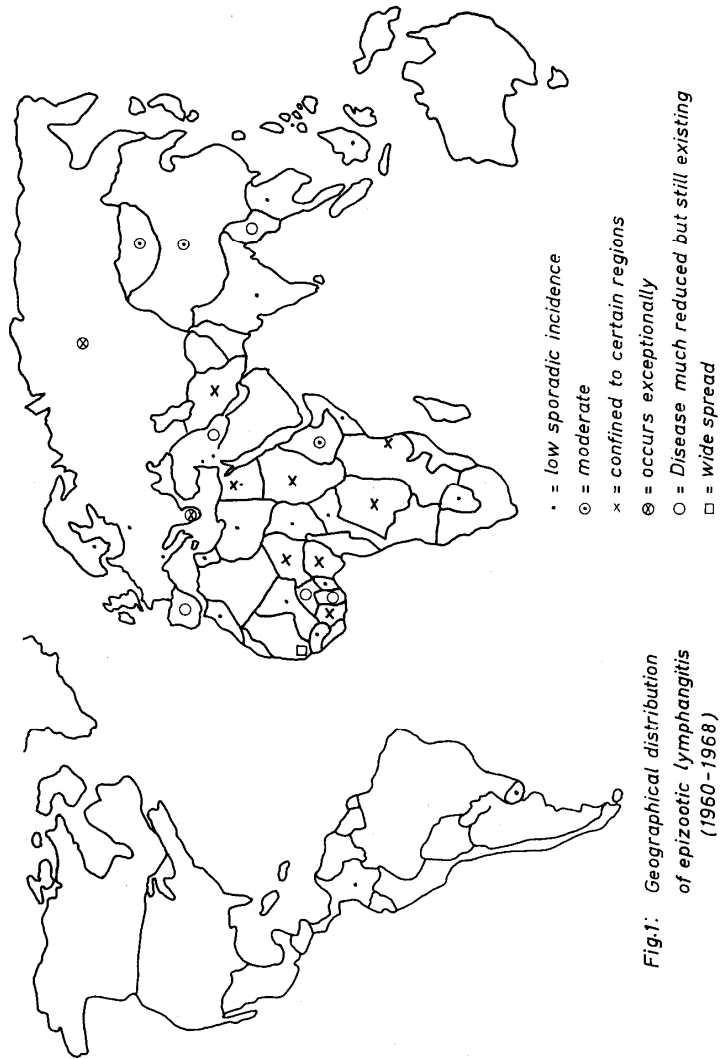
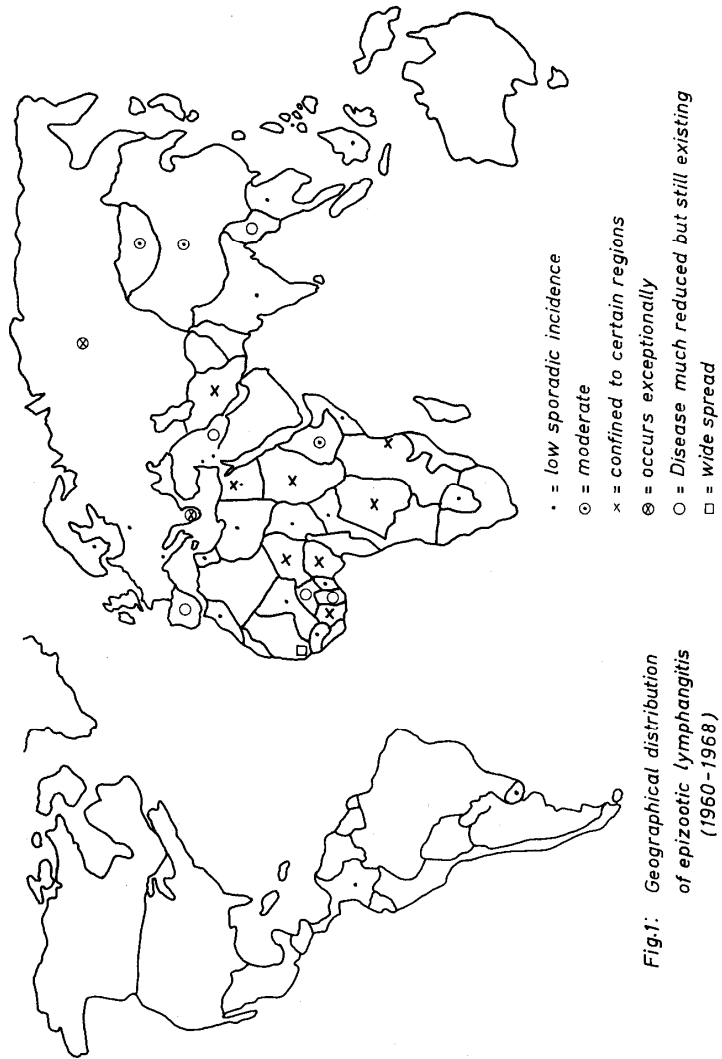


Foto 1: Epizootic lymphangitis in a horse, lesions on the hind limbs, abdomen, chest and neck





The present situation of epizootic lymphangitis all over the world as surveyed in the Animal Health Year Book, FAO-WHO-OIE (1960—1967) is displayed as follows (fig. 1):

The disease is endemic in Colombia and Uruguay; no evidence of its presence in Canada, U. S. A. and other countries of the American Continent. In Europe, epizootic lymphangitis occurs sporadically in Spain, Italy and Greece. In Poland, the disease was recently diagnosed in 27 horses (WOLOS, 1968). In Sweden, JOHANNSEN and OLSSON (1966) reported it in a mare, in U. S. S. R. the disease occurs exceptionally. In China and Mongolia the incidence is moderate. Low sporadic incidence is recorded annually in Lebanon, Jordan, Iran, India, Thailand, Indonesia and Philippines. The disease is much reduced but still existing in Iraq and Burma. In Australia, New Zealand and Venezuela epizootic lymphangitis was never recorded up to the year 1967.

In Africa, the disease is widely distributed. It has low sporadic incidence in Morocco, Tunisia, Libya, U. A. R., Chad, Mali, Somalia, Botswana, Guinea, Togo, Dahomey and Central African Republic. It is confined to certain regions in U. A. R., Tanzania, Congo, Niger, Sudan, Ivory Coast and Nigeria. In Ghana, the disease is much reduced but still existing, whereas in Senegal it is widely spread.

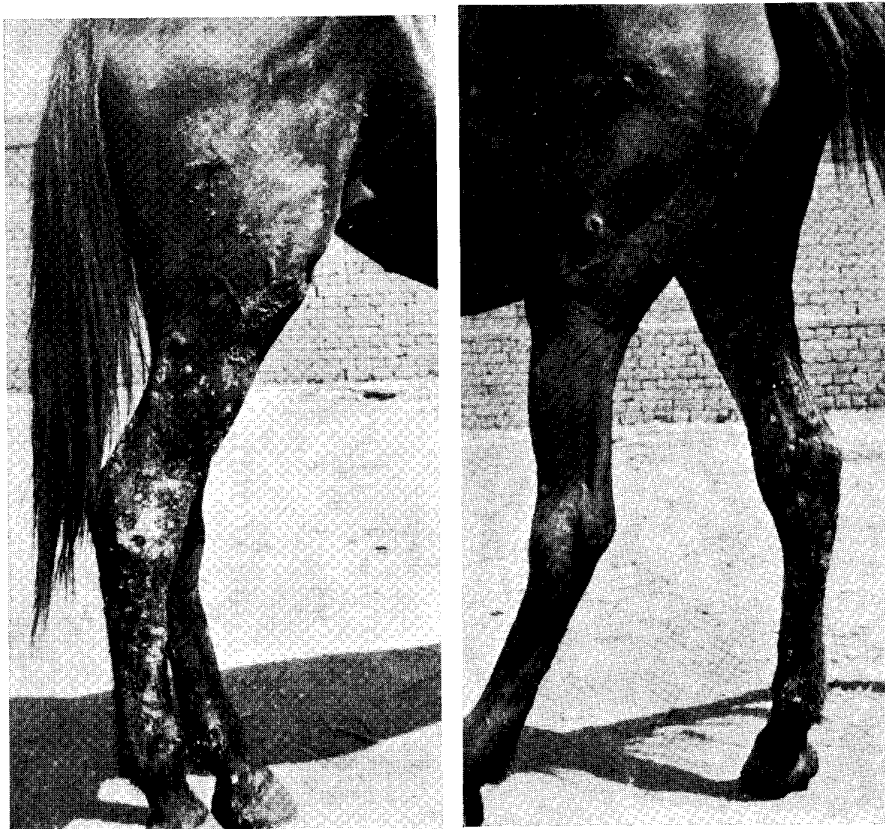


Foto 2 and 3: Nodules and ulcers on the outer surface of the hind limb (left foto) and on the inner side (right foto)

In U. A. R., the first record of the disease is not known. From the available annual reports of the Veterinary Department, Ministry of Agriculture, we found that, only one case was reported in 1949 and another case in 1955. In 1957, 5 cases were noted and gradually there was an increase in incidence reaching a maximum in 1965 with a total of 222 cases and then the disease incidence declined gradually (fig. 2). Compulsory notification and compensation for the diseased animals led to the increased reporting of cases in the last years. The owner of a diseased animal is compensated with about 20 L. E. for his animal. In 1965, about 7132, 5 L. E. were delivered to the owners as financial compensations for 201 animals.

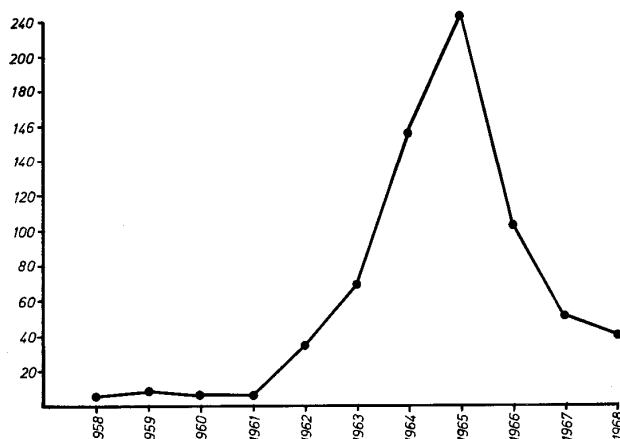


Fig. 2: Yearly incidence of epizootic lymphangitis in Egypt

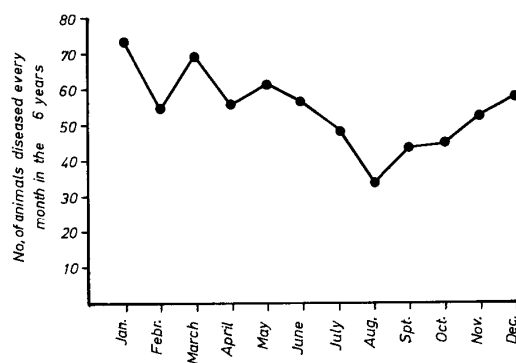


Fig. 3: Monthly incidence of epizootic lymphangitis (1963—1968)

Epizootic lymphangitis is endemic in Lower Egypt except in Ismailia and Suez (table 1). In the contrary, Upper Egypt is free except Giza, Fayoum and Beniswef provinces, where the disease is occasionally met with. In the last 10 years, about 724 cases were reported. The disease was prevalent in horses (89,6%) — see table 2 — and rare in mules (6,5%) and donkeys (3,9%). Males contracted the disease more commonly than in females (61,6%).

Table 3: Monthly incidence of epizootic lymphangitis in Egypt from 1963 to July 1969

month	1963	1964	1965	1966	1967	1968	1969	total
January	4	10	33	19	3	4	6	79
February	2	9	23	11	4	5	3	57
March	5	20	26	9	6	3	7	76
April	11	13	15	7	7	2	4	59
May	—	24	14	11	9	3	3	64
June	11	9	17	8	5	6	1	57
July	2	8	23	6	5	4	2	50
August	4	8	12	5	2	2	—	33
September	4	16	15	5	1	2	—	43
October	9	9	15	5	4	2	—	44
November	10	13	17	7	3	2	—	52
December	10	17	12	11	1	6	—	57
Total	72	156	222	104	50	41	26	671

March and May. In the last 10 years about 724 cases were recorded, of which 604 cases were horses, 41 mules and 26 donkeys. 61.6 % of the diseased animals were males. The average age of affected animals was 10—15 years. The incidence of the disease began to increase in 1963 and reached its maximum rise in the year 1965, where 222 cases were reported; then declined gradually. Epizootic lymphangitis is a notifiable disease. All diseased animals are compulsory condemned and the owners of such animals are financially compensated; about 20 L. E. pro animal.

References

- AINSWORTH, G. C. and AUSTWICK, P. K. C.: Fungal diseases of animals. Commonwealth Agricultural Bureaux, Farnham, Royal Bucks England (1959).
- AJELLO, L.: Comparative morphology and immunology of members of the genus *Histoplasma*. *Mykosen* 11, 507—514 (1968).
- Animal Health Yearbook, FAO, WHO, OIE (1960—1967).
- Annual Reports of Veterinary Departments, Ministry of Agriculture, U. A. R. (1949—1969).
- ARTIOLI, D.: Contributo alla conoscenza delle localizzazioni interne del farcino criptococcico. *Alti. Soc. Ital. Sci. Vet.* 2, 405—414 (1948).
- CIFERRI, R. and REDAELLI, P.: Sulla posizione sistematiche dell'agente patogeno del farcino equino. *Bull. Istit. Sieroterapico Milanese* 10, 1—8 (1934) (cit. AJELLO, 1968).
- JOHANNSEN, A. and OLSSON, L.: *Svensk Vet. Tidn.* 18, 560—563 (1966).
- MARCATO, A.: Le localizzazioni interne del farcino criptococcico. *Nuova vet.* 23, 68—77 (1947).
- PALLIN, W. A.: A treatise on epizootic lymphangitis, 2nd edit., London. Univ. Press of Liverpool. (1904) (cit. AINSWORTH and AUSTWICK, 1959).
- RIVOLTA, S.: Dei parassiti vegetale come introduzione allo studie delle malattie parassitarie e delle alterazioni dell'alimento degli animali domestici. Torino (1873); cit. AJELLO, 1968.
- VUILLEMIN, P.: Les blastomycètes pathogènes. *Rev. gen. sci. pur appl.* 12, 732—751 (1901) (cit. AINSWORTH and AUSTWICK, 1959).
- SINGH, T.: Studies on epizootic lymphangitis. Study of clinical cases and experimental transmission. *Indian J. Vet. Sci.* 36, 45—59 (1966).
- WOLOS, Z. S.: *Medycyna Wet.* 24, 134—140 (1968) cit. *Vet. Bull.* 38, 769 (1968).

Authors' address: Dr. MOHAMED REFAI and AHMED LOOT, Faculty of Veterinary Medicine, El-Giza, Egypt