

From the Faculty of Veterinary Medicine, Cairo University,
El Gizeh, Egypt

Affection of the arrectores pilorum muscles in favus

MOSTAFA AWAD and MOHAMED REHMAN

The arrectores pilorum muscles are smooth, non-striated, involuntary muscles found usually in connection with the hair follicles. They originate by minute multiple fasciculi from the papillary portion of the corium and are inserted just above the plane of the apex of the hair papillae. Elastic threads connect them intimately with the connective tissue bundles of the corium and serve as tendons at either extremity of each muscular fasciculus. By virtue of their oblique direction and mode of attachment, include in the angle surrounded by their muscular fibres, the sebaceous glands connected with hair follicles.

In extensive studies on the histopathology and histochemistry of the scalp tissues in *Trichophyton schoenleini* infection, the authors noticed that the arrectores pilorum muscles share the going on pathology.

In the present work we tend to report the pathological changes in the hair muscles in 30 patients suffering from favus.

Biopsies were surgically excized under local anaesthesia, fixed in 10% formaline and stained with H & E, PAS and combined PAS and Alcian blue stains.

Results and discussion

There was inflammatory cellular infiltrate, "lymphocytes, plasma cells, histiocytes and eosinophils", attached to and surrounding the muscles (Foto 1).

The arrectores pilorum muscles, by their intimate union with the elastic tissue which is evenly and generally distributed throughout the framework of the corium, exert an important function in connection with the regulation of the body temperature. By their contraction the muscles exert a direct compressive action on the skin vessels so that the blood may be driven from the surface in a centripetal direction and its cooling, in a great

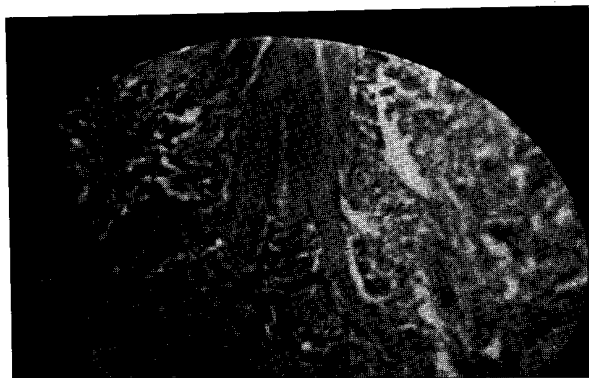


Fig. 1: Arrectores pilorum muscles surrounded by cellular infiltrate which is seen penetrating the muscle fasciculi

degree, is prevented. The reverse of this naturally follows when the muscles expand under the influence of external heat. Their contraction also serves to approximate several of the papillae of the corium including the hair papillae, thus the sebaceous secretion may be extruded.

In the present work, the arrectores pilorum muscles share the going on pathology in the scalp as a result of favus infection. In some sections the muscles were observed to be frayed and broken into small islets invaded and surrounded by heavy cellular infiltration (Foto 2). Reviewing the literature on favus at hand, we failed to find any data reported regarding affection of the arrectores pilorum muscles.

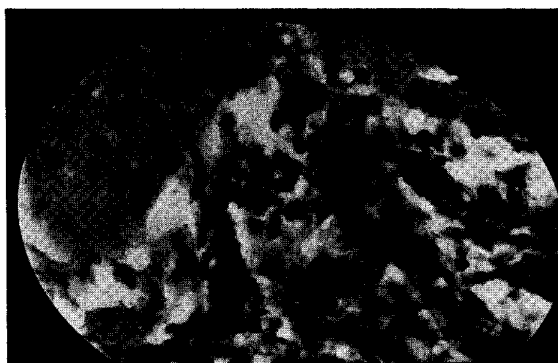


Fig. 2: Completely lysed arrector muscle showing small islets of muscle fragments

The destruction of the muscle could be explained on the assumption that the cellular infiltrate may possibly secrete an enzyme which possesses a lytic action on the muscle fibres as well as on other tissues. The occasional presence of foreign body giant cells around the hair follicles may be a reasonable reaction to the dissolved and broken muscle elements.

The destruction of the arrectores pilorum muscles is an interesting finding since if favus infection becomes a generalized disease, the body hairs will not be acted upon by the arrectores muscles. This in turn will alter the function of the skin as a major organ for regulation of the body temperature, and the gooseflesh skin phenomenon will not be apparent on sudden exposure to cold. Also sebum delivery to the skin surface may be affected.

Zusammenfassung

Die Arrectores pilorum an den Haarpapillen werden bei Favus des behaarten Kopfes von *Trichophyton schoenleinii* befallen. Dabei kommt es zum Zerfall der Muskelfasern in einzelne Fragmente bis zur völligen Auflösung. Dies ergab sich bei der histologischen Untersuchung von Biopsie-Schnitten nach Färbung mit H & E, PAS und PAS + Alcianblau. In der Literatur ließen sich bisher keine Angaben über den Pilzbefall dieser Muskeln finden.

References

1. CONANT, N. F., SMITH, D. T., BAKER, R. D., CALLAWAY, J. L. and MARTIN, D. S., 1962: Manual of clinical mycology. W. B. Saunders Comp. Philadelphia and London.
2. PEERSE, A. G., 1960: Histochemistry theoretical and applied. ed. 2, J. & A. Churchill-London.
3. SMITH, G. H., BLANK, H. and SARKANY, I., 1964: Fungus diseases and their treatment. J. & A. Churchill-London.

Address: Dr. MOHAMED REFAI, Faculty of Veterinary Medicine, Cairo-University, El-Gizeh Egypt