

# Lymphatic Obstruction: A Novel Etiologic Factor in the Formation of Antrochoanal Polyps

Annals of Otolaryngology, Rhinology & Laryngology  
2014, Vol. 123(6) 381–386  
© The Author(s) 2014  
Reprints and permissions:  
sagepub.com/journalsPermissions.nav  
DOI: 10.1177/0003489414522973  
aor.sagepub.com



Hany S. Mostafa, MD<sup>1</sup>, Tamer O. Fawzy, MD<sup>1</sup>,  
Waleed R. Jabri, MD<sup>1</sup>, and Essam Ayad, MD<sup>2</sup>

## Abstract

**Objectives:** Antrochoanal polyps (ACPs) originate from the inner wall of the maxillary sinus and either pass through the natural sinus ostia or cause pressure-induced destruction of the medial sinus wall. Eventually, they extend into the choanae and nasopharynx. Most authors who have studied the microstructure of ACPs, including the component stromal cells and surface epithelium, have not examined the transitional area between the sinus mucosa and the pedicle of the polyp. No explanation has been given for the absence of a cystic intrasinus portion of the polyp, in many cases refuting the therapy (most accepted) that polyps are caused by a mucous gland with a blocked acinus. We noted during endoscopic removal of the ACPs that the antral part of the polyp was cystic in only 5% of patients, and polypoid in 95%. The cystic intrasinus portion of the polyp is a cornerstone of the pathophysiology of ACPs, whether caused by inflammation, cicatrization, or allergy. This finding prompted us to examine the transitional area between the sinus mucosa and the pedicle of the polyp to verify the possibility that lymphatic obstruction—whether primary (areas of higher tissue pressure) or secondary (cicatrization or inflammation)—could be an etiologic factor in the formation of ACPs.

**Methods:** The study material consisted of 25 ACPs and 25 chronic maxillary sinusitis mucosal biopsy specimens (control group). The detection of lymphatic vessels was based on the identification of lymph vessel endothelial hyaluronic acid receptor 1 (LYVE-1) in the endothelial cells of the lymphatic capillaries. This was the first lymph-specific hyaluronic acid receptor to be characterized, and is a uniquely powerful marker for lymph vessels, differentiating them from (blood) capillaries.

**Results:** The density of the lymphatic vessels was marked in 22 of the 25 ACP specimens, ie, 88% of the ACP cases, compared with 16% of the control group.

**Conclusions:** This study resulted in two main findings. The first was the absence of intramaxillary cysts in the ACPs in 23 cases (92%). The second was the markedly high density of lymphatic vessels in the transitional area between the sinus mucosa and the pedicle of the ACPs, in comparison with the density in the control group. These two findings refute the “blocked acinus theory” and indicate that lymphatic obstruction, whether primary or secondary to chronic sinus infection, might play a leading role in the formation and further growth of ACPs.

## Keywords

acinous mucous gland, antrochoanal polyp, endoscopic sinus surgery, functional endoscopic sinus surgery, Killian polyp, lymphatic capillary, LYVE-1, maxillary sinus, maxillary sinusitis mucosal biopsy, nasal polyp

## Introduction

The close relationship between choanal polyps and the maxillary sinus was first reported by Killian<sup>1</sup> in 1906, when he traced polyps from the nasopharynx to the region of the maxillary sinus ostium, but not into the sinus cavity. Kubo<sup>2</sup> maintained that choanal polyps originate from the maxillary sinus mucosa, just inside the ostium. Van Alyea<sup>3</sup> found that choanal polyps in some patients were attached to the lateral aspect of the maxillary sinus with a fibrous or polypoid pedicle. The means by which this pedicle reached the

ostium and its further expansion into a choanal polyp, however, was not explained. Antrochoanal polyps (ACPs) originate from the inner wall of the maxillary sinus and, during

<sup>1</sup>Department of Otolaryngology, Faculty of Medicine, Fayoum University, Al Fayoum, Egypt

<sup>2</sup>Department of Histopathology, Faculty of Medicine, Cairo University, Cairo, Egypt

### Corresponding Author:

Tamer O. Fawzy, MD, Dept of Otolaryngology, Faculty of Medicine, Fayoum University, 197B 26 July Street, 12411 Al Fayoum, Egypt.

their growth, either pass through the natural ostia or cause pressure-induced destruction of the medial sinus wall and formation of accessory ostia.<sup>4</sup> Finally, they extend into the choanae and farther into the nasopharynx. Because of their rare incidence (3% to 6% of all nasal polyps), they have not been extensively studied.<sup>5-7</sup> Antrochoanal polyps have a much higher prevalence in the pediatric population, and Cook et al<sup>8</sup> reported an incidence in adults that was significantly greater (22.3%) than that in the overall literature.<sup>7,9-12</sup>

The ACP is a large, firm, fleshy, mucoid- and smooth-surfaced polyp with a long stalk.<sup>11,13</sup> Histologically, it is an inflammatory polyp covered by a ciliated cylindrical epithelium. The stroma is usually edematous and highly vascular, comprising mainly loose connective tissue infiltrated with plasma cells and a few eosinophils.<sup>10</sup> Although the cause of ACPs is unclear, they present a clinical appearance that is quite uniform. It has been suggested that ACPs are associated with inflammatory or allergic antral disease. However, the relationship of ACPs to allergy has not been clearly defined.<sup>14,15</sup>

Mills,<sup>5</sup> on the other hand, stated that choanal polyps arise from acinous mucous glands that are blocked and ruptured during the healing of bacterial sinusitis, thus being the extension of a mucocele. An "epithelium rupture theory," or "new gland formation theory," has also been proposed, which includes the presence of cysts as the precursors of ACP formation.<sup>16-18</sup>

In 1991, Hosemann et al<sup>19-21</sup> observed postoperative mucosal swelling in the maxillary sinus after extensive middle meatal antrostomy. They speculated that the inflammation represents a secondary lymphatic edema caused by drainage of lymph vessels that is obstructed during major maxillary fenestration. The purpose of our study was to determine whether lymphatic obstruction, either primary or secondary to chronic sinus infection or allergy, plays a leading role in the formation and further growth of ACPs.

A review of the literature showed that most authors have been concerned with the microstructure of the ACP itself in terms of the component stromal cells and surface epithelium. However, no effort has been made to examine the transitional area between the sinus mucosa and the polyp pedicle, nor has there been any explanation for the absence of a cystic intrasinus portion of the polyp; in many cases, reports have refuted the theory (most accepted) of a blocked mucous gland acinus.<sup>22</sup>

Surprisingly, the incidence of ACPs diagnosed in the outpatient clinic of our hospital (Fayoum University) in 2008 and 2009 was 20% of all nasal polyps diagnosed. The antral part of the polyp was cystic in only 5% of patients, and polypoid in 95%. These findings encouraged us to design our study in an attempt to explain this high incidence and verify whether primary lymphatic obstruction is a causative factor of ACPs.

## Materials and Methods

### Patients and Polyps

The study was approved by the ethical committee of the Faculty of Medicine, Fayoum University. All patients underwent a clinical examination consisting of anterior rhinoscopy, oral examination, nasal endoscopy with rigid telescopes, and computed tomography. The study included 25 cases of ACPs and 25 cases of chronic maxillary sinusitis. The specimens of mucosa from patients with chronic maxillary sinusitis ("chronic sinusitis biopsy" or CSB group), approximately 1 cm<sup>2</sup>, were collected during functional endoscopic sinus surgery procedures. All procedures were done at the Department of Otorhinolaryngology, Fayoum University School of Medicine, Al Fayoum, Egypt, during the period 2010 to 2012.

In the group of patients with ACPs, there were 15 men and 10 women. Their ages ranged from 10 to 48 years (mean, 24.85 years.) The CSB group, consisting of 20 men and 5 women from 15 to 67 years of age (mean, 38 years), served as controls, and patients known to be atopic (positive for allergy skin tests and aspirin challenge or showing eosinophilia) were excluded. The main symptom in the ACP group was usually nasal obstruction due to the large nasopharyngeal portion of the polyp. This was unilateral in 17 patients and bilateral in 8 patients. Fourteen patients had recurrent polyps after previous simple avulsion (11 patients) or a Caldwell-Luc procedure (3 patients).

### Polyp Removal and Preparation

The ACPs were strictly unilateral, and in most patients, there was a single polyp. In 3 patients, 2 polyps could be traced coming out of the maxillary sinus, and 6 patients had ipsilateral ethmoid polyps. Endoscopic removal of the ACP by middle meatal antrostomy was typically performed under general anesthesia; the antral part was removed through the maxillary ostium with upward-cutting forceps. Backward-cutting forceps were sometimes needed for widening the maxillary ostium. The pedicle of the polyp was identified and incised, along with the surrounding 1 cm<sup>2</sup> of the sinus mucosa, by means of 30° and 70° endoscopes. The nasal part was easily removed by a transnasal procedure, by a transnasal procedure, or by a combination of the two. A 1-cm<sup>2</sup> control specimen was obtained from the maxillary sinus mucosa of 25 patients with chronic sinusitis who were operated on during this period to relieve their pathologic condition.

### Histopathologic Study

Two 5- $\mu$ m-thick serial sections were cut from each tissue block. One section from each specimen was stained by a routine method with hematoxylin and eosin to confirm the

histopathologic diagnosis. The other section from each block was mounted on positively charged slides for immunohistochemical staining.

The detection of lymphatic vessels was based on identification of lymph vessel endothelial hyaluronic acid receptor-1 (LYVE-1) in the endothelial cells of the lymphatic capillaries; this was the first lymph-specific hyaluronic acid receptor to be characterized and is a uniquely powerful marker for lymph vessels themselves. In contrast, capillaries reveal a significantly lower activity, if any. The area of interest was the transitional area between the sinus mucosa and the pedicle of the polyp in the ACP specimens and the whole specimen in the CSB specimens. The sections were subjected to histochemical visualization of the lymphatic vessels according to the manufacturer's criteria (Abcam Inc, Cambridge, Massachusetts).

For immunoperoxidase staining, the paraffin-embedded sections were rehydrated and antigen retrieved with the Dako 3-in-1 AR buffer citrate (pH 6.0) in a Dako PT Link and then subjected to microwave treatment (700 W; 8 minutes). Slides were peroxidase-blocked in 3% hydrogen peroxide in methanol for 10 minutes. The paraffin embedded sections were then peroxidase-blocked using the Dako Protein Block (containing casein 0.25% in phosphate-buffered saline solution) for 10 minutes and then incubated with primary antibody (1:100 diluted LYVE-1 serum in phosphate-buffered saline solution, 5% human serum, 0.1% azide) for 30 minutes at 25°C, and LYVE-1 was detected with use of a Dako Envision Flex amplification kit for 30 minutes. Antigen was subsequently detected by incubation (30 minutes; 25°C) with an antirabbit immunoglobulin peroxidase conjugate. Colorimetric detection was completed with diaminobenzidine (Envision kit; Dako) for 5 minutes. The slides were counterstained with hematoxylin and eosin (30 seconds) and coverslipped under DePeX.

The number of lymphatic vessels and the extent of their dilatation were estimated individually, and a recording classification was adopted to reflect the density of the lymphatic vessels in each section as follows: markedly positive, if there were more than 3 individual lymph vessels in the low-power field; moderately positive, if there were 2 or 3 individual lymph vessels in the low-power field; or mildly positive, if there was 1 individual lymph vessel in the low-power field.

## Results

The ACPs were strictly unilateral, and most patients had a single polyp. In 3 patients, 2 polyps could be traced coming out of the maxillary sinus. Six patients had associated ipsilateral ethmoid polyps. The size of the ACPs was variable, mostly not exceeding 11 cm in the largest dimension; the largest polyp measured 5x15 cm, together with the pedicle.

In this series of 25 ACPs, the antral part of the polyp was cystic in only 8% of cases (2 polyps) and polypoid in 92%

(23 polyps). The location of the pedicle attachment was determined during surgery. Twelve polyps (48%) originated from the inferolateral wall, 7 (28%) from the anterior wall, and 4 (16%) arose from the lateral and posterior walls; in the 2 cases (8%) in which there were cystic intramaxillary parts, the exact origin could not be determined.

Examination of the histologic biopsy specimens (both ACP and CSB groups) revealed a distinct network of superficial and deep lymphatic vessels. The superficial capillaries were situated near the epithelial basal membrane, arranged in a horizontal orientation that was modified to follow the course of the mucosal gland tubes wherever it came into proximity to them. In the deep lymphatic system, the orientation was less obvious; however, those capillaries were close to the larger blood vessels (arterioles). The two networks were connected by vertical lymphatic vessels that were more prominent in the deeper tissue planes.

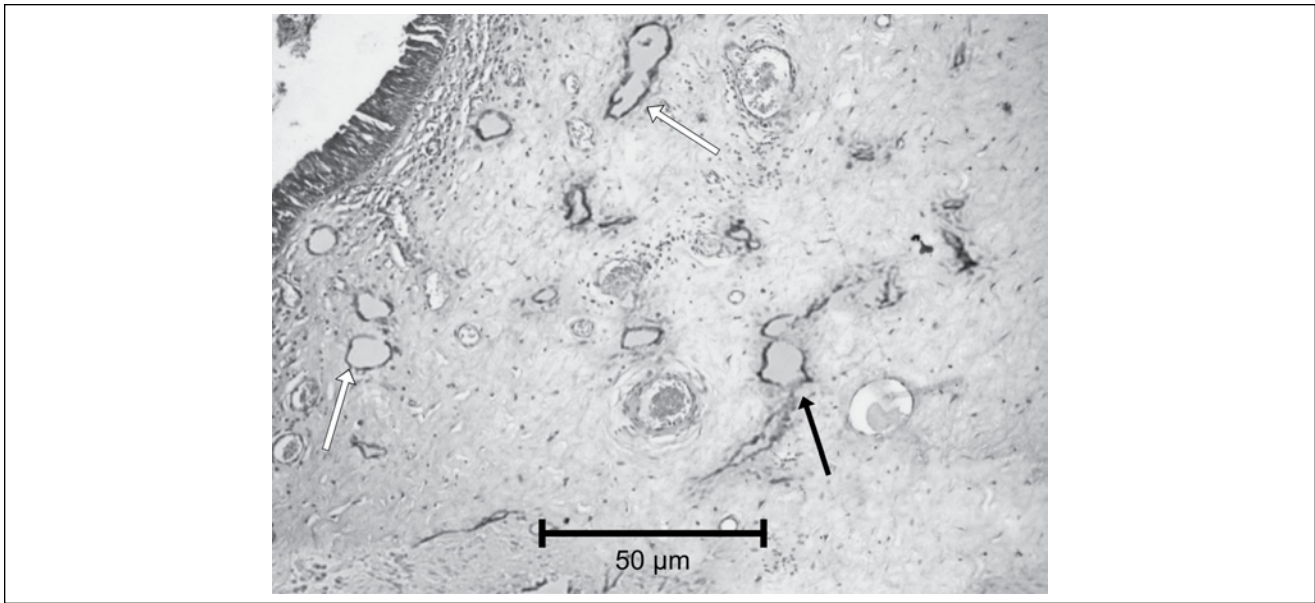
Of the 25 ACP specimens, the density of the lymphatic vessels was marked in 22 (88%) and moderate in 3 (12%). There were 3 times as many superficial lymphatic vessels as deep vessels detected in each examined section. The orientation of both systems was the same as in normal tissue; however, the vertical interconnecting vessels were more conspicuous than in normal tissue.

In our control group (25 CSB specimens), the density of the lymphatic vessels was marked in 4 specimens (16%), moderate in 5 (20%), and mild in 16 (64%), and there were twice as many deep lymphatic vessels as superficial ones. The orientation of both systems was the same as in normal tissue; however, the vertical interconnecting vessels were fewer than in normal tissue (Figures 1-3).

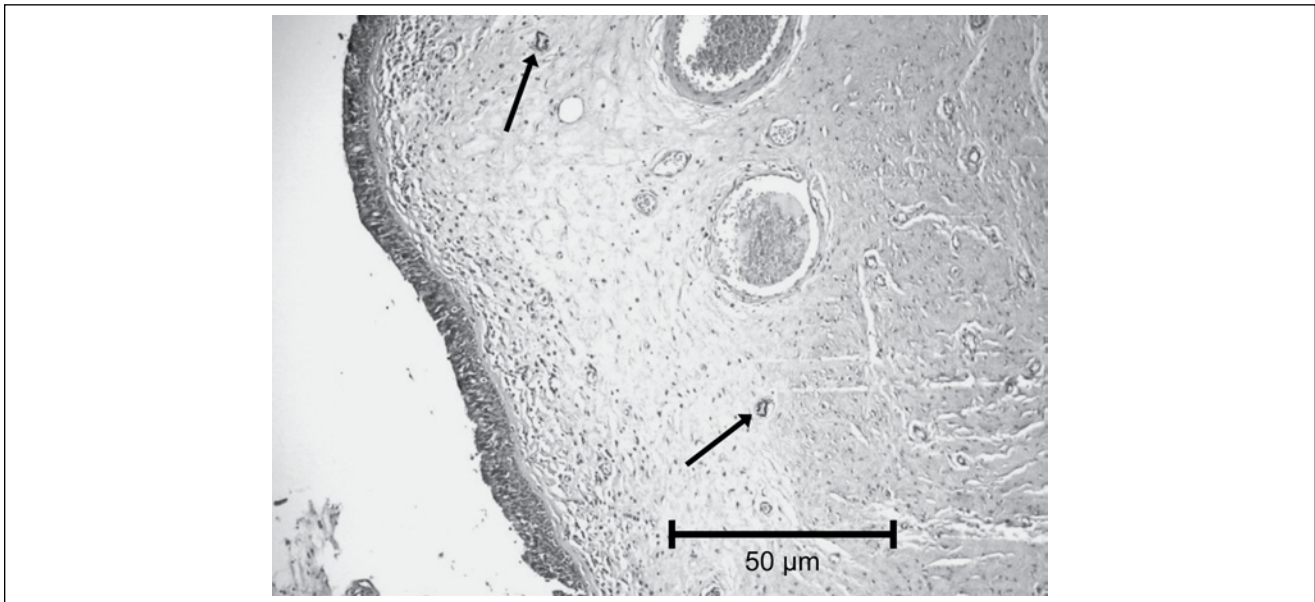
## Discussion

The ongoing debate concerning the pathophysiology of ACP formation and growth has not been satisfactorily elucidated. Through reviewing the literature, we found that ACPs can be associated with chronic inflammation, allergy, dental trauma, or a microvascular disorder, but the pathologic mechanism of their formation and growth is still unclear. There is convincing evidence that most, if not all, ACPs develop from intramural cysts of the maxillary sinus.<sup>23</sup> This peculiar origin is reflected in the presence of cysts in the antral portion of the polyp,<sup>14</sup> representing a sequel of chronic sinusitis that results in acinous mucous glands that are blocked and ruptured during the healing of bacterial sinusitis.<sup>5</sup>

An allergenic background of ACPs has been reported in certain cases.<sup>8,24</sup> Both Cook et al<sup>8</sup> and Heck et al<sup>15</sup> reported allergy in a considerable percentage of their patients with ACPs (23.4% and 69.7%, respectively). They found a statistically significant association of ACPs with allergies. On the other hand, other investigators failed to find even one case of a well-confirmed allergic basis among patients with ACP.<sup>14</sup>



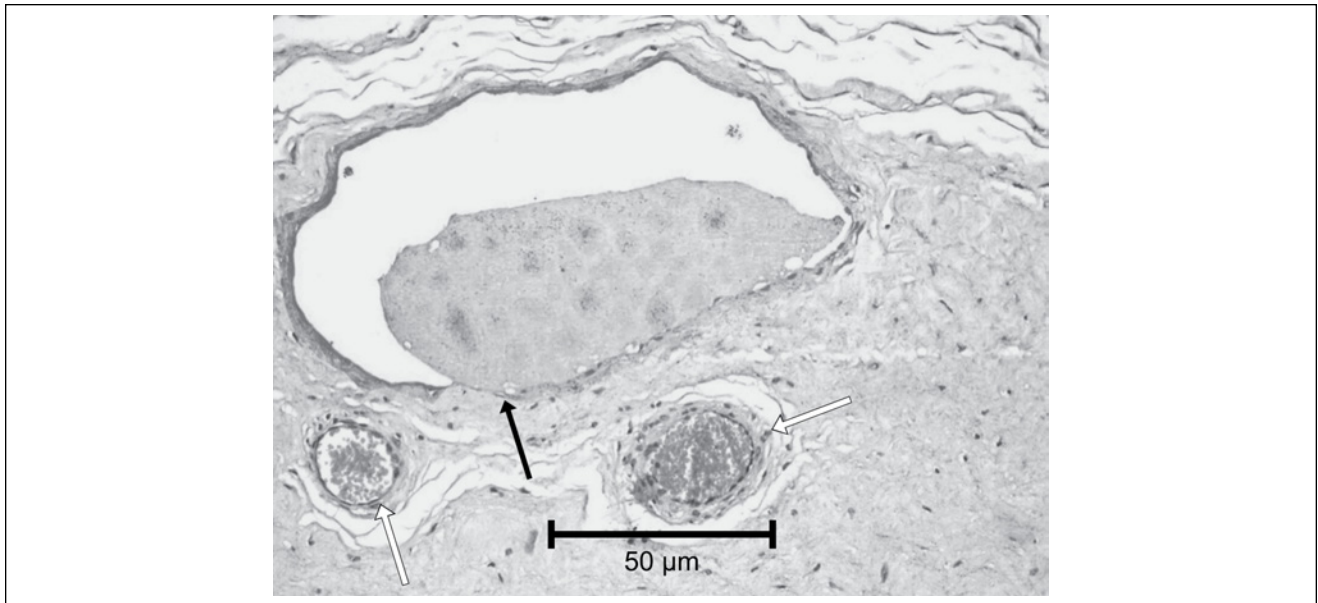
**Figure 1.** Section of antrochoanal polyp stained by LYVE-1 shows both superficial (horizontal orientation) lymphatic vessels exhibiting marked positivity (white arrows) and deep (multiplanar orientation) lymphatic vessels exhibiting marked positivity (black arrow; original  $\times 100$ ).



**Figure 2.** Section of chronic sinusitis mucosa stained by LYVE-1 shows deep lymphatic vessels exhibiting mild positivity (black arrows; original  $\times 100$ ).

Składzień and Litwin<sup>25</sup> demonstrated that polyps of the maxillary sinus secondary to dental extraction (injury-induced polyps), although grossly resembling ACPs, have characteristics different from those of chronic sinusitis- or allergy-associated polyps. Ozcan et al,<sup>26</sup> through transmission electron microscopy, were able to show distinct degeneration and destruction of some of the endothelial cells in

the blood vessels of their ACP cases, supporting a neovascular theory of ACP formation (edema of respiratory epithelium). Hosemann et al<sup>21</sup> demonstrated with histochemical detection of 5'-nucleotidase that both the nasal and maxillary sinus mucosae showed distinct superficial and deep longitudinal lymphatic capillary networks interconnected through vertically arranged lymphatic vessels. We used



**Figure 3.** Section of antrochoanal polyp stained by LYVE-1 shows deep lymphatic vessels exhibiting moderately positive dilated lymphatic vessel (black arrow) with close proximity to blood vessels (white arrows; original  $\times 200$ ).

those findings regarding the histopathologic distribution of the lymphatic system for our model of the normal lymphatic arrangement of the sinonasal mucosa. Our results are consistent with the findings of Hosemann et al,<sup>21</sup> insofar as the distribution of the lymphatic system is distributed into two distinct networks with interconnecting vessels. Our findings on the caliber and orientation of the two individual networks and the interconnecting vessels point to the presence of an area of increased tissue pressure in the ACP.

Kim et al<sup>27</sup> described the distributional and quantitative changes in the lymphatic vessels of normal sinus mucosa, edematous sinus mucosa, and polyps by using immunohistochemistry and Western blotting with D2-40 antibody. Their findings showed lymphatic vessels in the subepithelial layer of both normal and edematous ethmoid sinus mucosae. Some vessels were dilated, whereas others were compressed. The differences in the number, size, length, or density of the lymphatic vessels in the normal and edematous ethmoid sinus mucosae were statistically insignificant. The expression levels of D2-40 antibodies on Western blotting were similar in both samples. They concluded that the absence of lymphangiogenesis in the edematous ethmoid sinus mucosa, which led to accumulation of interstitial fluid in patients with sinusitis, caused mucosal edema and the consequent formation of polyps. On the other hand, our study targeted the transitional zone between the maxillary sinus mucosa and the ACP stalk. We suspected that this area carried answers regarding ACP causation. As control specimens, we used samples of inflammatory sinus mucosa, as opposed to healthy sinus mucosa, as we attempted to challenge the “blocked-acinus” theory in which ACPs are

secondary to chronic inflammation of the maxillary sinus. Kim et al<sup>27</sup> used normal-appearing sinus mucosa as a control. However, they speculated that the possibility of acute or subacute inflammation could not be excluded, and that lymphangiogenesis might occur even in normal sinus mucosa. They concluded that there was no difference in the density of lymphatic vessels between normal and edematous sinuses.<sup>27</sup>

The incidence of ACPs diagnosed in our outpatient clinic (Fayoum University) from 2008 to 2009 was 20% of all nasal polyps. This incidence is high compared with that reported in the literature. Our investigation into the origin of ACPs resulted in two important findings: 1) the pedicled origin of the ACPs (23 cases; 92%) and the absence of an intramaxillary cyst; and 2) lymphatic vessels in ACPs of intrasinus mucosal origin that were of high density and marked enlargement in comparison with those of CSB specimens.

These two findings refute the “blocked acinus” theory and support lymphatic obstruction as the cause of ACPs. We advocate primary lymphatic obstruction as opposed to secondary obstruction because our results, as well as those of Kim et al,<sup>27</sup> showed no increase in the density of lymphatics in the presence of chronic sinusitis. However, there was increased density of the lymphatics in the transitional area between the sinus mucosa and the ACP pedicle.

## Conclusions

We believe that the data gathered through the present study should be considered a step toward a sophisticated and discrete evaluation of the exact cause of ACPs.

### Declaration of Conflicting Interests

The author(s) declared no potential conflicts of interest with respect to the research, authorship, and/or publication of this article.

### Funding

The author(s) received no financial support for the research, authorship, and/or publication of this article.

### References

1. Killian G. The origin of choanal polyp. *Lancet*. 1906;2:81-82.
2. Kubo J. Über die eigentliche Ursprungsstelle und die Radikaloperation der solitären Choanalpolypen. *Arch Laryngol Rhinol*. 1909;21:81.
3. Van Alyea OE. Management of non-malignant growths in the maxillary sinus. *Ann Otol Rhinol Laryngol*. 1956;65:714-722.
4. Składzień J, Litwin JA, Nowogrodzka-Zagórska M, Wierzchowski W. Morphological and clinical characteristics of antrochoanal polyps: comparison with chronic inflammation-associated polyps of the maxillary sinus. *Auris Nasus Larynx*. 2001;28:137-41.
5. Mills CP. Secretory cysts of the maxillary antrum and their relation to the development of antrochoanal polyp. *J Laryngol Otol*. 1959;73:324-34.
6. Loury MC, Hinkley DK, Wong W. Endoscopic transnasal antrochoanal polypectomy: an alternative to the transantral approach. *South Med J*. 1993;86:18-22.
7. Ryan RE Jr, Neel HB III. Antral-choanal polyps. *J Otolaryngol*. 1979;8:344-346.
8. Cook PR, Davis WE, McDonald R, McKinsey JP. Antrochoanal polyposis: a review of 33 cases. *Ear Nose Throat J*. 1993;72:401-402, 404-410.
9. Larsen K, Tos M. The estimated incidence of symptomatic nasal polyps. *Acta Otolaryngol*. 2002;122:179-182.
10. Chen JM, Schloss MD, Azouz ME. Antro-choanal polyp: a 10-year retrospective study in the pediatric population with a review of the literature. *J Otolaryngol*. 1989;18:168-172.
11. Woolley AL, Clary RA, Lusk RP. Antrochoanal polyps in children. *Am J Otolaryngol*. 1996;17:368-373.
12. Orvidas LJ, Beatty CW, Weaver AL. Antrochoanal polyps in children. *Am J Rhinol*. 2001;15:321-325.
13. Başak S, Karaman CZ, Akdilli A, Metin KK. Surgical approaches to antrochoanal polyps in children. *Int J Pediatr Otorhinolaryngol*. 1998;46:197-205.
14. Min Y-G, Chung JW, Shin J-S, Chi JG. Histologic structure of antrochoanal polyps. *Acta Otolaryngol*. 1995;115:543-7.
15. Heck WE, Hallberg OE, Williams HL. Antrochoanal polyp. *AMA Arch Otolaryngol*. 1950;52:538-548.
16. Tos M, Mogensen C. Pathogenesis of nasal polyps. *Rhinology*. 1977;15:87-95.
17. Fang SY, Yang BC. Overexpression of Fas-ligand in human nasal polyps. *Ann Otol Rhinol Laryngol*. 2000;109:267-270.
18. Aktaş D, Yetişer S, Gerek M, Kurnaz A, Can C, Kahramanyol M. Antrochoanal polyps: analysis of 16 cases. *Rhinology*. 1998;36:81-85.
19. Hosemann W, Dunker I, Göde U, Wigand ME. Experimentelle Untersuchungen zur Wundheilung in den Nasennebenhöhlen. III. Endoskopie und Histologie des Operationsgebietes nach einer endonasalen Siebbeinausräumung. *HNO*. 1991;39:111-115.
20. Hosemann W, Wigand ME, Göde U, Länger F, Dunker I. Normal wound healing of the paranasal sinuses: clinical and experimental investigations. *Eur Arch Otorhinolaryngol*. 1991;248:390-394.
21. Hosemann W, Kühnel T, Burchard AK, Werner JA. Histochemical detection of lymphatic drainage pathways in the middle nasal meatus. *Rhinology*. 1998;36:50-54.
22. Kamel R. Endoscopic transnasal surgery in antrochoanal polyp. *Arch Otolaryngol Head Neck Surg*. 1990;116:842-843.
23. Berg O, Carenfelt B, Silfverswärd C, Sobin A. Origin of the choanal polyp. *Arch Otolaryngol Head Neck Surg*. 1988;114:1270-1271.
24. Weisskopf A, Burn HF. Histochemical studies of the pathogenesis of nasal polyps. *Ann Otol Rhinol Laryngol*. 1959;68:509-523.
25. Składzień J, Litwin JA. Allergic nasal polyps examined by scanning electron microscopy. *Riv Ital Otorinolaringol Audiol Foniatr*. 1993;13:183-186.
26. Ozcan C, Zeren H, Talas DU, Küçüköğlü M, Görür K. Antrochoanal polyp: a transmission electron and light microscopic study. *Eur Arch Otorhinolaryngol*. 2005;262:55-60.
27. Kim TH, Lee SH, Lee HM, et al. D2-40 immunohistochemical assessment of lymphangiogenesis in normal and edematous sinus mucosa and nasal polyp. *Laryngoscope*. 2007;117:442-446.