

Bipolar Scissors Tonsillectomy: What Are the Advantages?

Mahmoud Ashraf Ragab, MD, Ahmed Atef, MD, Mohamed Mosleh, MD, Basem Metwally, MSc, and Ahmed F. Abdel Fattah, MD

ABSTRACT

Background: Various methods have been described for tonsillectomy. Convincing evidence in the literature is still lacking regarding the optimal method of performing this surgical procedure.

Aim: To investigate the outcome of bipolar scissors tonsillectomy and compare it to bipolar diathermy forceps tonsillectomy.

Methods: A prospective study of 91 patients was done at Cairo University Hospital. The right tonsils were removed in all patients using the bipolar scissors technique (group A), and the left tonsils were removed with bipolar forceps (group B). Operative time, operative blood loss, and postoperative hemorrhage were the defined parameters used to compare the outcome of both techniques.

Results: The mean operative time for group A was 14.68 ± 6.78 minutes, whereas in group B, it was 14.66 ± 5.53 minutes. This difference was found to be statistically nonsignificant ($p = .987$). In group A, the mean intraoperative blood loss was 27.55 ± 17.89 mL, whereas in group B, the mean blood loss was 29.98 ± 16.9 mL. This difference was not found to be statistically significant ($p = .509$). The overall postoperative bleeding, either primary or secondary, from the first group was 3.3% (three cases), whereas it was 2.2% (two cases) from the second group.

Conclusion: Bipolar scissors tonsillectomy is considered an easy, safe, and effective procedure. Although bipolar diathermy forceps tonsillectomy needs equipment that is less expensive, its outcome is comparable to that of bilateral scissors tonsillectomy.

SOMMAIRE

Contexte: L'amygdalectomie peut s'effectuer selon différentes techniques. Cependant, il y a une insuffisance de données convaincantes dans la documentation médicale en ce qui concerne la meilleure technique d'opération.

Buts: L'étude avait pour buts d'examiner les résultats de l'amygdalectomie réalisée à l'aide de ciseaux bipolaires et de les comparer avec ceux de l'amygdalectomie effectuée à l'aide de pinces diathermiques bipolaires.

Méthodes: Une étude prospective, comptant 91 patients, a été menée à l'hôpital universitaire du Caire. Dans tous les cas, l'amygdale droite a été enlevée à l'aide de ciseaux bipolaires (groupe A) et l'amygdale gauche, à l'aide de pinces bipolaires (groupe B). Les paramètres retenus pour la comparaison des résultats étaient la durée opératoire, les pertes de sang peropératoires et les hémorragies postopératoires.

Résultats: La durée opératoire dans le groupe A s'est établie à 14.68 ± 6.78 minutes tandis que, dans le groupe B, elle était de 14.66 ± 5.53 minutes. L'écart s'est révélé non significatif sur le plan statistique ($p = .987$). Dans le groupe A, les pertes de sang peropératoires se sont élevées à 27.55 ± 17.89 mL et, dans le groupe B, à 29.98 ± 16.9 mL. Encore une fois, l'écart n'était pas significatif ($p = .509$). Enfin, les saignements postopératoires, primaires et secondaires confondus, ont atteint 3.3% (trois cas) dans le premier groupe et 2.2% (deux cas) dans le second.

Conclusion: L'amygdalectomie réalisée à l'aide de ciseaux bipolaires est considérée comme une intervention sûre, facile et efficace. Cependant, l'amygdalectomie effectuée à l'aide de pinces bipolaires diathermiques nécessite du matériel moins coûteux que la première et donne des résultats comparables à ceux de l'amygdalectomie réalisée à l'aide de ciseaux bipolaires.

Key words: bipolar forceps, bipolar scissors, diathermy tonsillectomy, posttonsillectomy hemorrhage

Mahmoud Ashraf Ragab, Ahmed Atef, Mohamed Mosleh, Basem Metwally, and Ahmed F. Abdel Fattah: Department of Otorhinolaryngology, Faculty of Medicine, Cairo University, Cairo, Egypt.

Address reprint requests to: Ahmed Atef, MD, 7 Mahmoud Afifi Street, Almaza, Cairo, Egypt 11341; e-mail: amratef@dr.com.

DOI 10.2310/7070.2011.100217

© 2011 The Canadian Society of Otolaryngology-Head & Neck Surgery

DECKER



Over the years, various techniques have been described for tonsillectomy, including the cold dissection technique—which is currently the most popular method of tonsillectomy—guillotine excision, electrocautery, suction diathermy dissection, cryosurgery, ultrasonic removal, laser, and monopolar and bipolar diathermy dissection.¹ Cold dissection tonsillectomy is considered the gold standard technique; however, bipolar electrodissection tonsillectomy is one of the electrosurgical dissection

methods, and its use for tonsil dissection has been advocated by some authors and hence popularized at many centres.^{2,3}

Bipolar electrosurgery involves energy transfer between proximally placed electrodes. Grasping more or less tissue and altering the distance between electrodes can change the degree of heating or coagulation.^{4,5} It was found that bipolar electrodissection tonsillectomy is a faster technique than cold dissection tonsillectomy, with comparable postoperative bleeding and pain⁶—although much controversy exists in the literature about such values, particularly in the English national audit. These issues make bipolar dissection tonsillectomy a useful technique for the pediatric population. Bipolar electrosurgical scissors are a new instrument that were originally designed for open surgery using a dual function that cuts and coagulates at the same time.⁷ Bipolar scissors tonsillectomy appears to combine the best of cold scissors dissection and electrosurgical techniques, allowing rapid tonsil removal with minimal bleeding and desirable tissue effects.⁸

Bipolar scissors are modified 17 cm Metzenbaum scissors with two normal blades that have been modified to allow bipolar electrocautery without excessive collateral damage. The inner surface of one blade is covered with a ceramic coat. The other blade is coated with a clear, surface-hardening material. The handles and part of the outer surface of the blades are covered with plastic. Some have modified the instrument further to bring the outer plastic coating to within 10 mm of the tip of the scissors. A diathermy machine is used to supply the electrical current.¹ Bipolar scissors, like bipolar forceps, are as effective as monopolar cautery but offer less lateral tissue injury and do not interfere with cardiac pacemakers or joint prostheses. Bipolar scissors and forceps were recently coupled into one automatic unit that is linked to a computer and turns on when touched to tissue. It stops working automatically once coagulation has taken place and before desiccation or fulguration occurs.⁹

Material and Methods

This study was done in a prospective fashion between September 2005 and May 2008. The study included 91 patients who were subjected to tonsillectomy at the Department of Otorhinolaryngology, Kasr Al Aini Hospital, Cairo University. The study design was approved by our local university ethics committee, and strict inclusion criteria were followed, where the indication for tonsillectomy was recurrent attacks of acute follicular tonsillitis (six or more episodes per year or three or more episodes in 2 successive years). All selected patients were above 7 years of age. Patients with obstructive symptoms owing to adenoid hypertrophy, a past history of quinsy, or tonsillar tumours were excluded. The right tonsils were removed in all patients using the bipolar scissors technique (group A), and the left tonsils were removed with bipolar forceps (group B). Operative time, operative blood loss, and postoperative hemorrhage were the defined parameters used to compare the outcome of both techniques.

Group A included patients with tonsils from the right side that were removed using the bipolar scissors technique. Bipolar scissors tonsillectomy was performed using PowerStar Bipolar scissors (Ethicon Ltd., Edinburgh, UK) (Figure 1).

The technique is shown in Figure 2. Patients were orotracheally intubated and placed in the supine position. A Boyle-Davis gag was inserted and supported by Draffin Bi pods (Bolton Surgical, Sheffield, UK). The tonsil was grasped and rolled medially with the tonsillar grasping forceps. Dissection started at the medial edge of the anterior faucial pillar with a slow cutting movement and simultaneous current application. The bulge of the tonsil was then identified, and care was taken to stay close within the capsular plane. Occasional blood vessels seen during the dissection were coagulated between the blades of the bipolar scissors by applying current just before cutting. The dissection was then carried out toward the lower pole

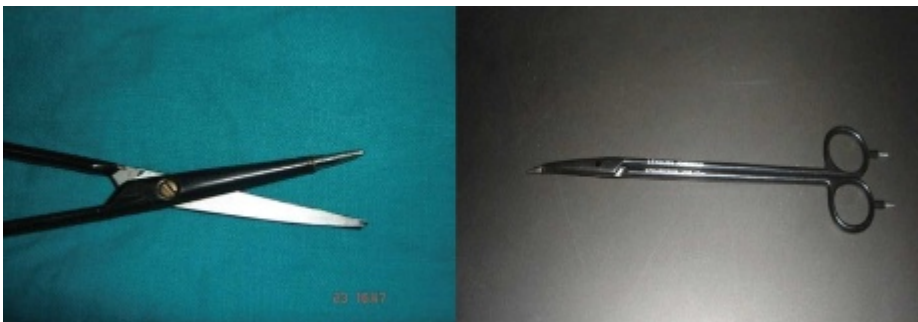

Figure 1. PowerStar bipolar scissors.

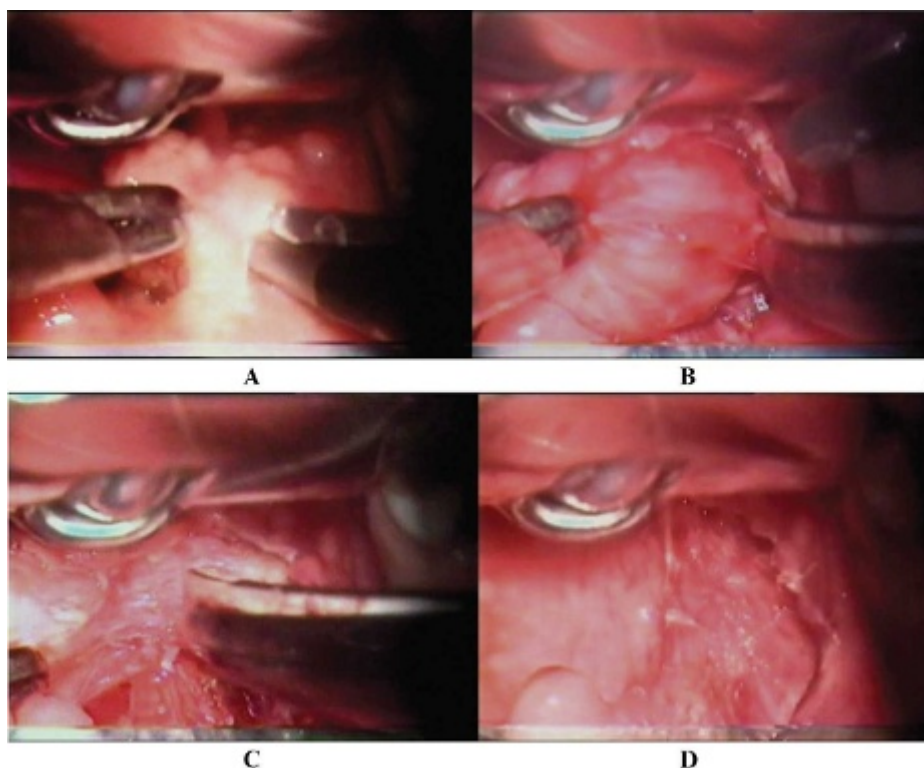


Figure 2. Bipolar scissors tonsillectomy. A, The first incision with the bipolar scissors at the anterior pillar. B, Dissection within the capsular plane. C, Simultaneous cutting and coagulation of the lower pole. D, The tonsillar fossa after removal of the tonsil.

in the same manner. A bloodless field is usually maintained, with slight blanching seen in the tonsillar bed. Occasional bleeding points were cauterized with the tips of the scissors. The whole procedure of dissection was carried out slowly to allow time for coagulation to be completed. The blades of the scissors were successfully cleaned with a wet swab during the procedure.

Group B included patients with tonsils from the left side that were removed using the bipolar forceps technique. The bipolar diathermy machine was set at 30 W, and a pair of straight 20 cm bipolar forceps with a sharp tip were used. The upper pole of the tonsil was grasped with a pair of Luc forceps and then pulled medially. After applying the cautery, blanching occurred and was followed by a palatoglossal incision. The appropriate peritonsillar plane was identified, and the tonsil was dissected to the lower pole. A relatively bloodless field was possible with the use of diathermy on the fibrovascular tissue close to the tonsil. Most of the blood vessels supplying the tonsils were identified and accurately coagulated. By applying tension to the lower pole, the bipolar forceps cut and separate the tonsil from its remaining attachments. Further hemostasis was secured with bipolar diathermy. No ties were needed.

Intraoperative blood loss was assessed for all patients in both groups and measured by assessment of the amount of

blood in milliliters in the suction tray bottle. Blood soaked in swabs and gauzes was not measured as it was trivial and inconsiderable. Operative time was measured in minutes from the first mucosal incision until complete removal of the tonsils. Cases complicated with a primary postoperative hemorrhage were readmitted, and bleeding was secured under general anesthesia. Cases with secondary hemorrhages were managed conservatively.

Sides were compared for intraoperative blood loss, difficulty of the technique evaluated by calculating the operative time, the presence of thermal trauma and mucosal burns, and postoperative hemorrhage.

For comparing categorical data, a chi-square test was performed. A probability value (*p* value) less than .05 was considered statistically significant. All statistical calculations were done using SPSS (SPSS Inc, Chicago, IL) version 15 for Microsoft Windows.

Results

Regarding the overall patient population, there were 41 males and 50 females, ranging in age from 7 to 30 years, with a mean age of 14.48 years.

In group A, the intraoperative blood loss ranged between 10 and 70 mL, with a mean of 27.55 ± 17.89 mL, whereas in group B, the blood loss was a little higher, ranging between 10 and 72 mL, with a mean of $29.98 \pm$

16.9 mL. This difference between operative blood loss in the two groups (sides) was found to be statistically nonsignificant ($p = .509$). The mean operative time in group A was 14.68 ± 6.78 minutes, with a range of 4 to 30 minutes, whereas in group B, it was 14.66 ± 5.53 minutes, with a range of 5 to 29 minutes. This difference between operative time in the two groups (sides) was found to be statistically nonsignificant ($p = .987$).

The overall incidence of posttonsillectomy bleeding, either primary or secondary hemorrhages, was 5.5% (five cases). The overall incidence of the primary hemorrhages was 3.3% (three cases) and for the secondary hemorrhages was 2.2% (two cases). The primary hemorrhage rate for group A was 2.2% (two cases), whereas it was 1.1% (one case) for group B. The secondary hemorrhage for both groups was one case in each group. The overall postoperative bleeding, either primary or secondary, for the bipolar scissors group was 3.3% (three cases), whereas it was 2.2% (two cases) for the bipolar forceps group.

Thermal burns in the oral mucosa and tongue have been observed during use of the bipolar scissors (group A) in 8.8% of patients (eight cases). These burns were superficial and healed spontaneously within 1 week after surgery. In the bipolar diathermy group (group B), burns were detected in 6.6% (six cases). Detection of these burns was reliant on operator observations and his operative notes, although this carries some bias.

Discussion

Methods of performing tonsillectomy vary in attempts to achieve decreased morbidity. Convincing evidence in the literature is still lacking regarding the optimal method of performing this surgical procedure.¹ Among the wide range of tonsillectomy techniques that have evolved and are currently available are blunt dissection, guillotine excision, cryosurgery, ultrasonic removal, laser tonsillectomy, and monopolar and bipolar diathermy tonsillectomy.¹⁰⁻¹²

Electrosurgical instruments and lasers all achieve cutting and simultaneous hemostasis by sealing the blood vessel lumen by virtue of tissue heating, which has great appeal to any surgeon.^{13,14} Surgeons who have tried the bipolar bayonet forceps tonsillectomy technique claimed decreased morbidity and improved tissue effects.¹⁵

More recently, a new technique for tonsillectomy using bipolar electrosurgical scissors was described by Saleh and colleagues and Isaacson and Szeremeta.^{1,8} These scissors allow for simultaneous cutting and electrocoagulation. The use of bipolar scissors has been approached with caution because some authors question their safety and efficacy,¹⁶

but comparing the technique of bipolar scissors tonsillectomy to the standard technique of cold dissection tonsillectomy proved it to be a fast, effective, and safe technique. Raut and colleagues reported a significant reduction in intraoperative blood loss and operative time with bipolar scissors tonsillectomy compared to the classic cold dissection method, without a statistically significant difference for the primary hemorrhage between the two groups.¹⁷

After proving the efficacy and safety of bipolar scissors tonsillectomy by comparing it to the standard cold technique of tonsillectomy, as in the work of Raut and colleagues,¹⁷ the issue should be to investigate whether it is a cost-effective procedure because the cost of the scissors will be added to the cost of the procedure. So it should be compared to the very well-established but much more economical other electrodissection technique: bipolar forceps tonsillectomy.

The only authors who tried such a study were Patel and colleagues.¹⁸ They compared bipolar scissors and forceps tonsillectomies, but their outcome measures were the duration of surgery and the incidence of bleeding only; they did not mention the amount of blood loss during the surgery. Contrary to our results, bipolar scissors tonsillectomy in their work proved to be statistically favourable compared to bipolar forceps tonsillectomy with regard to the duration of surgery and the incidence of bleeding postoperatively. We found no statistical difference between both techniques regarding operative time and the amount of intraoperative blood loss. The incidence of posttonsillectomy bleeding was comparable in both groups. In view of the high-cost machines used in bipolar scissors tonsillectomy, the cost-effective value of this technique should be re-evaluated.

The difference in operative time between both techniques in the work of Patel and colleagues, although statistically significant, was on average 2 minutes,¹⁸ which does not justify the high cost of the procedure. Moreover, the difference in the incidence of posttonsillectomy bleeding (nearly double the values in the bipolar forceps technique) is to be questioned as both techniques use the same electrodissection physical principle. Also, the work of Patel and colleagues was conducted on two groups of patients, and bipolar scissors were used to remove both tonsils in one group of patients and the forceps were used to remove tonsils from the other group of patients.¹⁸ This study design results in some bias, in contrast to our design, which, although nonrandomized, uses both techniques in the same patient to eliminate the effect of patient factors on outcome.

Sood and Strachan raised concerns about the safety of bipolar scissors for tonsillectomy, reporting two significant

tongue burns in their small series, and recommended that care be taken to protect the buccal mucosa and the edge of the tongue from the back edge of the scissors.¹⁶ Patel and colleagues concluded that the modified designs of the bipolar scissors that are insulated more completely cause no such burns, whereas the standard designs used for tonsillectomy were prone to causing inadvertent burn injuries to the base of the tongue.¹⁸ Raut and colleagues reported one case with minor tongue burn adjacent to the lower pole of the tonsil following the bipolar scissors technique.¹⁷ In this study, thermal burns in the oral mucosa and tongue were observed during use of bipolar scissors in 8.8% of cases and bipolar forceps in 6.6%. These burns were superficial and healed spontaneously within 1 week.

Finally, it may be useful to mention that our study design precluded proper comparison of postoperative pain and thermal burns related to the techniques studied, which could be better evaluated through randomized studies on separate candidates, not the same candidate.

Conclusion

The use of bipolar scissors in tonsillectomy is a new, safe, and effective trend that has generated considerable research interest. Although bipolar forceps diathermy tonsillectomy needs much simpler equipment, its outcome is comparable to that of bilateral scissors tonsillectomy. Future studies regarding the cost and cost-benefit of both techniques are mandatory.

Acknowledgement

Financial disclosure of authors and reviewers: None reported.

References

- Saleh HA, Cain AJ, Mountain RE. Bipolar scissor tonsillectomy. *Clin Otolaryngol* 1999;24:9–12, doi:[10.1046/j.1365-2273.1999.00200.x](https://doi.org/10.1046/j.1365-2273.1999.00200.x).
- Pang YT, el-Hakim H, Rothera MP. Bipolar diathermy tonsillectomy. *Clin Otolaryngol* 1994;19:355–7, doi:[10.1111/j.1365-2273.1994.tb01247.x](https://doi.org/10.1111/j.1365-2273.1994.tb01247.x).
- Brodsky L, Pizzuto M, Gendler J, Duffy L. Microbipolar dissection vs. cold knife/suction cautery tonsillectomy in children: preliminary results of a prospective study. *Acta Otolaryngol Suppl* 1996; 523:256–8.
- Voyles RC. Bipolar electrosurgery. *Probl Gen Surg* 2002;19:24–30, doi:[10.1097/00013452-200206000-00005](https://doi.org/10.1097/00013452-200206000-00005).
- Kirazli T, Bilgen C, Midilli R, et al. Bipolar electrodissection tonsillectomy in children. *Eur Arch Otorhinolaryngol* 2005;262: 716–8, doi:[10.1007/s00405-004-0774-4](https://doi.org/10.1007/s00405-004-0774-4).
- Hesham A. Bipolar diathermy versus cold dissection in pediatric tonsillectomy. *Int J Pediatr Otorhinolaryngol* 2009;73:793–5, doi:[10.1016/j.ijporl.2008.09.026](https://doi.org/10.1016/j.ijporl.2008.09.026).
- Winslow CP, Burke A, Bartels S, et al. Bipolar scissors in facial plastic surgery. *Arch Facial Plast Surg* 2000;2:209–12, doi:[10.1001/archfaci.2.3.209](https://doi.org/10.1001/archfaci.2.3.209).
- Isaacson G, Szeremeta W. Pediatric tonsillectomy with bipolar electrosurgical scissors. *Am J Otolaryngol* 1998;19:291–5, doi:[10.1016/S0196-0709\(98\)90000-X](https://doi.org/10.1016/S0196-0709(98)90000-X).
- Stenquist BC, Holt PJ, Motley RJ. Computerized bipolar diathermy with scissors and forceps in cutaneous surgery. *Dermatol Surg* 2002;28:601–2, doi:[10.1046/j.1524-4725.2002.01232.x](https://doi.org/10.1046/j.1524-4725.2002.01232.x).
- McGregor FB, Albert DM, Bhattacharya AK. Post-operative morbidity following paediatric tonsillectomy: a comparison of bipolar diathermy dissection and blunt dissection. *Int J Pediatr Otorhinolaryngol* 1995;31:1–6, doi:[10.1016/0165-5876\(94\)01057-5](https://doi.org/10.1016/0165-5876(94)01057-5).
- McGuire NJ. A method of guillotine tonsillectomy with an historical review. *J Laryngol Otol* 1967;81:187–95.
- Weingraten C. Ultrasonic tonsillectomy: rationale and technique. *Otolaryngol Clin North Am* 1987;20:371–6.
- Blomgren K, Qvarnberg Y, Valtonen H. A prospective study on pros and cons of electrodissection tonsillectomy. *Laryngoscope* 2001;111:478–82, doi:[10.1097/00005537-200103000-00018](https://doi.org/10.1097/00005537-200103000-00018).
- Martinez SA, Akin DP. Laser tonsillectomy and adenoidectomy. *Otolaryngol Clin North Am* 1987;20:371.
- Pang YT. Paediatric tonsillectomy: bipolar electrodissection and dissection/snare compared. *J Laryngol Otol* 1995;109:733–6, doi:[10.1017/S0022215100131172](https://doi.org/10.1017/S0022215100131172).
- Sood S, Strachan DR. Bipolar scissor tonsillectomy [letter]. *Clin Otolaryngol* 1999;24:465.
- Raut VV, Bhat N, Sinnathuray AR. Bipolar scissors versus cold dissection tonsillectomy: a prospective, randomized, multi-unit study. *Laryngoscope* 2001;111:2178–82, doi:[10.1097/00005537-200112000-00020](https://doi.org/10.1097/00005537-200112000-00020).
- Patel N, Kirkland P, Tandon P, et al. Comparison of bipolar scissors and bipolar forceps in tonsillectomy. *Ear Nose Throat J* 2002;81:714–7.

Copyright of Journal of Otolaryngology -- Head & Neck Surgery is the property of Decker Publishing and its content may not be copied or emailed to multiple sites or posted to a listserv without the copyright holder's express written permission. However, users may print, download, or email articles for individual use.