

Functional Endoscopic Dilatation Sinuplasty (FEDS) by Balloon Catheter Balloon Sinuplasty: A Conservative Tool for Sinusitis

Mohammed A. Hegazy, Nabil G. Zeid, Ahmed S. Abd El Rahman, Basim M. Wahba, Mahmoud S. El Fouly

ENT Department, Faculty of Medicine, Cairo University, Egypt

Correspondence to Mahmoud S. El Fouly
Tel: 01009009004
e-mail: melfouly@gmail.com

Received 30 November 2014
Accepted 18 December 2014
PAN Arab Journal of Rhinology
2015, 1:14-22

Paranasal balloon catheter represents a recently developed tool which enables surgeons to dilate the sinus ostia while maximizing tissue preservation. In this study forty patients were divided into two groups: (A) and (B). Patients in group (A) (20 patients) were treated using balloon sinuplasty technique, while patients in group (B) (20 patients) were treated using the standard functional endoscopic sinus surgery. Pre and post-operative findings in each group regarding the symptoms and endoscopic findings were compared. A comparison between the postoperative results of both groups was done as well.

Keywords: Nose, Paranasal Sinuses, Balloon Sinuplasty, FEDS

INTRODUCTION

Chronic Rhinosinusitis (CRS) is one of the most common chronic diseases refractory to treatment and despite improved antibiotic efficacy in the recent years; the prevalence of CRS is increasing [1].

FESS is an effective treatment for chronic sinusitis, recurrent acute sinusitis, or persistent acute sinusitis in patients who fail maximal medical treatment. FESS is a functional procedure for restoration of physiological function to the drainage pathways of paranasal sinuses. It is the most commonly used procedure and it has replaced the old conventional surgeries as it represents a conservative and less tissue destructive procedure than the old techniques. Reports have shown high success rates in both adults and children [2]. Paranasal balloon catheter devices represent a new developed suite of small flexible tools that enable surgeons to endoscopically create an opening in a patient's blocked or significantly narrowed sinus ostia and transition spaces, while maximizing tissue preservation and minimizing iatrogenic mucosal injury [3,4]. A Food and Drug Administration-cleared balloon catheter system has been introduced as a potential minimally invasive, ambulatory strategy for the treatment of CRS [5].

Aim of work: This study tried to evaluate the efficacy of Functional Endoscopic Dilatation Sinuplasty (FEDS) using balloon catheter in the treatment of patients with chronic rhinosinusitis as compared to FESS.

PATIENTS AND METHODS

Forty patients suffering from chronic rhinosinusitis (CRS) that was refractory to ordinary medical treatment were enrolled in this study. Patients were divided into two groups. Group A (20 patients) was operated upon using balloon sinuplasty, while group B (20 patients) underwent the standard functional endoscopic sinus surgery (FESS). Before commencing this study, we obtained the ethical committee approval from ENT Department, Kasr Al Ainy Hospital, Cairo University. This study was carried out in a prospective randomized controlled fashion. Patients were consented to participate in this study.

Inclusion criteria

1. CRS with symptoms of duration longer than 3 months
2. C.T. Evidence of CRS (inflammatory mucosal thickening)
3. Failed previous medical treatment

Exclusion criteria

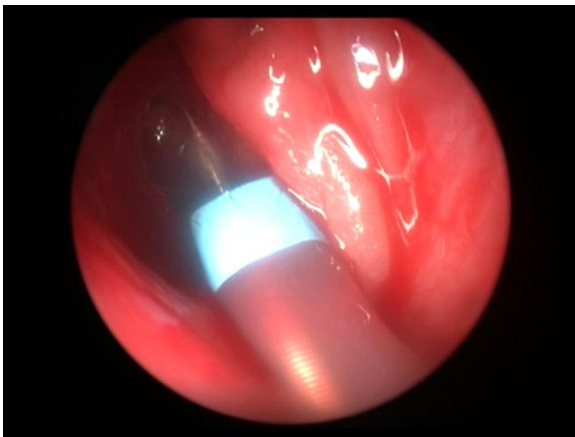
1. Previous surgical treatment for CRS
2. Presence of bronchial asthma and/or Aspirin sensitivity
3. Gross sinonasal polyposis
4. Findings suggestive of allergic fungal sinusitis
5. Pregnant and lactating females

Device Application

In group A: all patients were operated upon under general anesthesia with the standard nasal preparation using cotton pledges soaked in adrenaline (1:200,000) within the nasal cavity. In this group, 33 frontal recesses and 16 maxillary sinuses ostia were dilated using the balloon catheter. Sinuses deemed appropriate for balloon sinuplasty were addressed first. Under endoscopic visualization, a guiding catheter (Acclarent, Inc., Menlo Park, California, USA) was placed in the region of the sinus ostia. A guide wire was introduced through the guiding catheter until it successfully cannulated the sinus. Endoscopic evaluation and/or Luma Sinus Illumination System

(Luma light) (Acclarent, Inc., Menlo Park, California, USA) were done to confirm the stability and right positioning of the guide wire. After successful cannulation, an inflated balloon catheter (Acclarent, Inc., USA) was threaded over the guide wire and through the guiding catheter. The un-inflated balloon was advanced into the position until it straddled the sinus ostium, and then inflated with air to a maximum of 16 atmospheric pressure. The balloon was then immediately deflated and removed. The dilated ostia were examined by nasal endoscopy. Maxillary and frontal sinuses were addressed for balloon dilatation, while ethmoid sinuses, if involved, were treated with standard ESS with the result of hybrid type treatment which was done in 11 cases (Figs. 1-3).

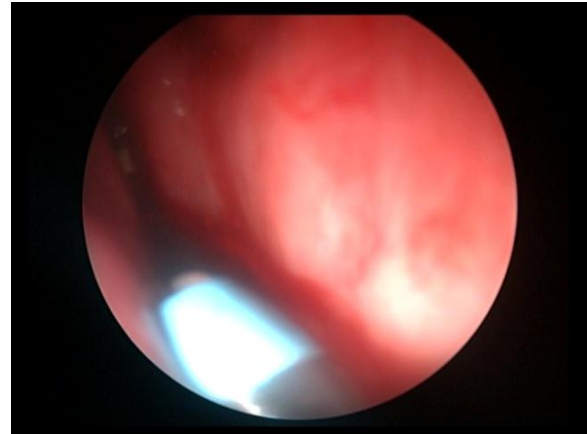
Figure 1



Luma guide wire passing through the guide catheter into the frontal recess

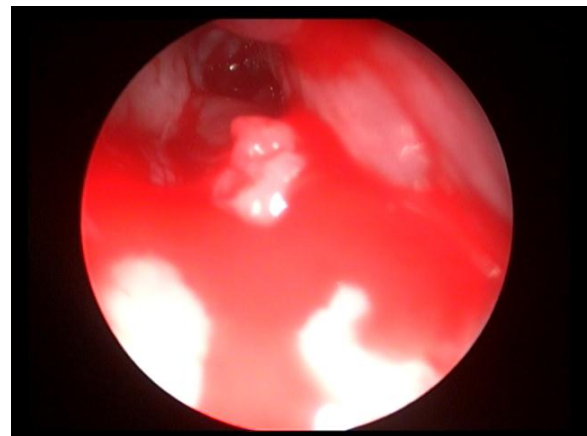
In group B: all patients underwent middle meatal antrostomy using the conventional method of FESS (40 maxillary sinus ostia), while seven patients with frontal sinusitis were treated with frontal recess clearance using the standard instruments for ESS (14 frontal recesses).

Figure 2



The balloon catheter passing through the Luma guide wire into the frontal recess

Figure 3



Frontal recess after dilatation with the balloon catheter

Post-operative care

Endoscopic evaluation was done routinely in the clinic in days 7 and 14 post-operatives, and then on the third month after the surgery, another evaluation was done which was used for statistical assessment. Computed tomography (CT) was done only if symptoms persisted for at least four weeks after the surgery and was not done as a routine post-operative investigation so as not to expose the patients to unnecessary radiation.

Patients were assessed using the following criteria:

A- Symptom assessment

The first outcome measurement was the subjective assessment for the pre-operative and post-operative main symptoms, using standardized symptoms questionnaire; the Lund-Mackay scoring system of symptoms using the visual analogue score (VAS). This scoring system was used to evaluate the severity of the following parameters:

- Nasal obstruction.
- Nasal discharge.
- Headache.
- Facial pain.
- Sense of smell (Olfactory disturbance).
- Total Points

The patient indicated symptom severity on a scale from 1 to 10. A score of zero was given when a symptom was not present, while numbers up to 10 were given when symptoms were present, with 10 indicating the greatest severity [6].

B- Endoscopic assessment

The second outcome measurement used was the objective endoscopic assessment; which was done in both pre and post-operative periods. The endoscopic appearances were quantified on 0-2 point basis (0 = not present, 1 = not marked, and 2 = marked). The parameters used were:

- Inflammatory mucosal edema at ostiomeatal complex (OMC)
- Polyp at the OMC region
- Muco-pus in the middle meatus
- Scarring or adhesions
- Crusting

Thus the maximum score was 20

C- Radiological assessment

The third outcome measurement for evaluation was by coronal CT scanning which was done routinely in the pre-operative period and after the surgery if symptoms persisted. The CT findings were assessed using Lund and Mackay scoring system for each of the sinuses (maxillary, anterior ethmoids, posterior ethmoids, sphenoid, and frontal) of 0-2, where 0 = no abnormality, 1 = partial opacification, 2 = total opacification, and 0 or 2 for the OMC. Thus the maximum score was 24 and each side was considered separately [6].

D) Occurrence of complications

Statistical analysis

Statistical analysis was carried out using SPSS for Windows program (version 15). Descriptive statistics were carried out for all variables including obtaining mean and standard deviation. The independent samples student (t) test, Pearson Chi Square test, Wilcoxon matched pairs signed rank sum test, and Mann-Whitney test were used for statistical analysis for all the parametric variables. A P value of 0.05 or less was considered significant, and a P value of 0.01 or less was considered highly significant.

RESULTS

Demographic data

In group (A) there were 12 males (60%) and 8 females (40%) ranging between 18 and 77 years with a mean age of 46.1±17.18 years. While in group (B), there were 14 males (70%) and 6 females (30%) ranging between 26 and 44 years with a mean age of 33.15 ±6.722 years (Table 1) shows descriptive statistics of age distribution.

Table 1 Descriptive statistics of age distribution

Group	N	Minimum	Maximum	Mean	SD*
Group A	20	18	77	46.10	17.180
Group B	20	26	44	33.15	6.722
Total	40	18	77	39.63	14.450

* SD = standard deviation

Thirty three frontal recesses and 16 maxillary sinuses ostia were dilated using the balloon catheter.

Effect on Symptoms

1- Pre-operative

According to the Lund-Mackay scoring system of symptoms, nasal obstruction scores of the 20 patients

ranged from 0-7 with a mean of 4.75±1.832; nasal discharge ranged from 0-6 with a mean of 2.85±2.3; headache ranged from 0-6 with a mean of 3.35±2.412; facial pain ranged from 0-6 with a mean of 3.1±2.198; smell ranged from 0-4 with a mean of 0.2±0.894, and overall total symptoms score ranged from 3-21 with a mean of 14.25± 5.476 (Table 2).

Table 2 Descriptive statistics of the pre-operative symptoms (VAS) for all patients of group (A) (20 patients)

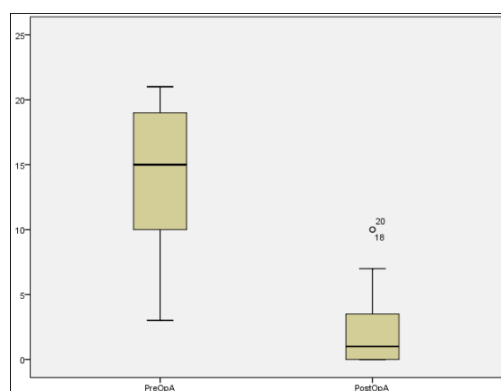
Pre-operative Symptoms Group (A)	n	Minimum	Maximum	Mean	SD*
Obstruction	20	0	7	4.75	1.832
Discharge	20	0	6	2.85	2.300
Headache	20	0	6	3.35	2.412
Facial Pain	20	0	6	3.10	2.198
Smell Affection	20	0	4	0.20	0.894
Overall Total Score	20	3	21	14.25	5.476

* SD = standard deviation

2- Post-operative

The VAS, nasal obstruction scores of the 20 patients ranged from 0-5 with a mean of 0.7 ± 1.525 with improvement that was statistically highly significant ($p < 0.001$); nasal discharge ranged from 0-3 with an improved mean score of 0.4 ± 0.94 , which was also statistically highly significant with a p value of < 0.001 ; headache ranged from 0-5 with a mean of 0.75 ± 1.372 showing highly significant improvement ($p < 0.001$); facial pain ranged from 0-4 with a mean of 0.55 ± 1.099 showing improvement which was highly statistically significant ($p < 0.001$); smell was totally improved in patients who previously suffered from hyposmia, however this was not statistically significant ($p = 0.33$). Lastly, the overall total symptoms score ranged from 0-10 with a mean of 2.45 ± 3.252 which was statistically highly significant ($p < 0.001$) (Fig. 4).

Figure 4



Comparison between the pre and post-operative overall total symptoms scores in group (A)

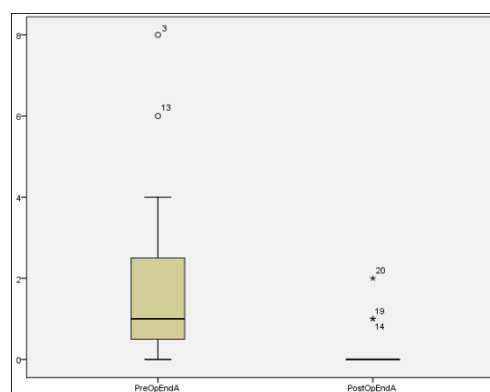
Effect on Endoscopic Findings

Mucosal edema was noted in 13 patients (65%), nasal polyps in the middle meatus were detected in 4 patients (20%), and mucopus was seen in 8 patients (40%). Two

patients (10%) had pre-operative scarring or adhesions, and one patient (5%) had pre-operative crustation.

After treatment with balloon sinuplasty, mucosal edema and scarring were completely improved in all twenty patients with a p value of 0.001 (highly significant) and 0.180 (insignificant) respectively. Nasal polyps were present in only one patient (5%), and one patient showed crustation (5%). These last two parameters showed insignificant statistical difference with p values of 0.83 and 1.00 respectively. Mucopus was present in 2 patients (10%) with a statistical significant improvement (P value= 0.033) (Fig. 5). According to the Lund-Mackay scoring system, the pre-operative overall total endoscopy scores ranged from 0-8 with a mean of 1.85 ± 2.110 , while the post-operative overall total endoscopy scores ranged from 0-2 with a mean score of 0.2 ± 0.523 , and thus there was a statistically highly significant difference between the pre and post-operative endoscopy scores (p value = 0.001) (Fig. 5).

Figure 5



Comparison between the pre and post-operative overall total endoscopy scores in group (A)

Out of the 33 frontal recesses treated with the balloon sinuplasty, 3 months follow up showed 32 patent frontal recesses with a patency rate of 96.9%. Only one patient required revision surgery. While for the sixteen maxillary sinuses ostia dilated with the balloon, 3 months follow up revealed a patency rate of 100%.

Effect on CT findings

The pre-operative radiological findings showed maxillary sinus opacification in 16 patients (80%) and

anterior ethmoid air cells opacification in 14 patients (70%). The posterior ethmoid air cells were opaque in half of the patients (50%), sphenoid sinus was opaque in 8 patients (40%), and frontal sinus was opacified in 14 patients (70%). The OMC was opaque in 13 patients (65%). These results are shown in (Table 3). Computed tomography was done only for one patient who required revision surgery as symptoms persisted for more than 12 weeks after the surgery.

Table 3 Descriptive statistics for the pre-operative CT findings for both groups (A) and (B)

Sinus Opacification	Pre-operative Group (A)		Pre-operative Group (B)	
	Present	Absent	Present	Absent
Maxillary	16 (80%)	4 (20%)	18 (90%)	2 (10%)
Anterior ethmoids	14 (70%)	6 (30%)	20 (100%)	0 (70%)
Posterior ethmoids	10 (50%)	10 (50%)	10 (50%)	10 (50%)
Sphenoid	8 (40%)	12 (60%)	4 (20%)	16 (80%)
Frontal	14 (70%)	6 (30%)	9 (45%)	11 (55%)
OMC	13 (65%)	7 (35%)	16 (80%)	4 (20%)

Group (B)

Twenty patients were treated by FESS. Forty maxillary sinuses ostia were dilated and clearance of 14 frontal recesses was done using the conventional endoscopic sinus surgery.

Effect on symptoms

1- Pre-operative

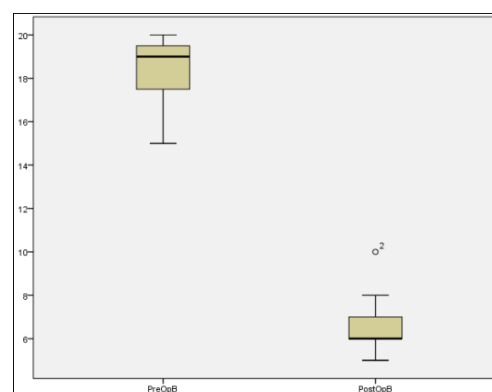
The VAS score; nasal obstruction, discharge and headache scores of the 20 patients were 5 in all cases. Facial pain ranged from 0-5 with a mean of 3.40 ± 1.536 and smell was not affected in any of the patients. Overall total symptoms score ranged from 15-20 with a mean of 18.40 ± 1.536 .

2- Post-operative

The VAS score, nasal obstruction scores of the 20 patients ranged from 0-2 with a mean of 1.05 ± 0.394 , nasal discharge ranged from 2-4 with an improved mean score of 3.05 ± 0.394 , headache ranged from 1-3 with a mean of 1.65 ± 0.671 , facial pain ranged from 0-2 with a mean of 0.75 ± 0.716 , smell was not affected post-operatively in any of patients. Lastly, the overall total symptoms score ranged from 5-10 with a mean of 6.5 ± 1.192 . The improvement in all symptomatic

parameters was highly statistically significant with a P value of < 0.001 (Fig. 6).

Figure 6



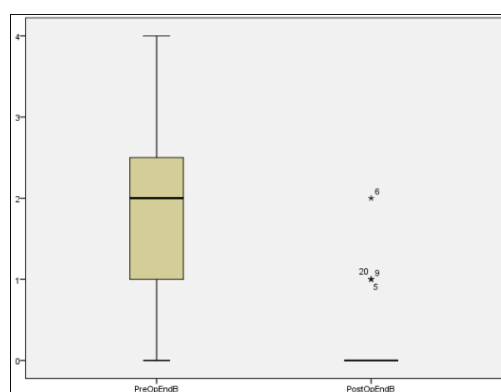
Comparison between the pre and post-operative overall total symptoms scores in group (B)

Effect on Endoscopic Findings

Mucosal edema was noted in 19 patients (95%), nasal polyps in the middle meatus were detected in 8 patients (40%), while mucopus was seen in 7 patients (35%). No

patients showed pre-operative scarring, adhesions or crustation (Table 3). After FESS none of the patients had mucosal edema indicating a highly significant improvement with a p value < 0.001. Nasal polyps were still present in 2 patients (10%) with a significant statistical improvement (p value=0.014). Mucopus was present in 2 patients (10%), which was a significant difference from the pre-operative findings (p value=0.025). One patient (5%) had post-operative scarring and adhesions. No crustations were found in any of the patients. The latter two parameters did not show any statistical difference from the pre-operative findings. According to the Lund-Mackay scoring system the pre-operative overall total endoscopy scores ranged from 0-4 with a mean of 1.9±0.968, while the post-operative overall total endoscopy scores ranged from 0-2 with a mean score of 0.25±0.550. This improvement was considered to be statistically highly significant p value < 0.001 (Fig. 7).

Figure 7



Comparison between the pre and post-operative overall total endoscopy score in group (B)

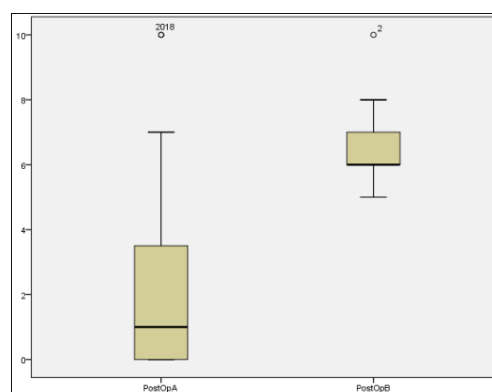
Effect on CT findings

The pre-operative radiological findings showed maxillary sinus opacification in 18 patients (90%), and anterior ethmoid sinus opacification in all patients (100%). The posterior ethmoid sinus was opaque in 10 patients (50%), sphenoid sinus was opaque in 4 patients (20%), and frontal sinus was opacified in 9 patients (45%). The OMC was opaque in 14 patients (70%). No post-operative CT was required as none of the patients were indicated for such an investigation (Table 3).

In comparing the results between group A and group B, FEDS showed better improvement in nasal discharge and overall total symptoms scores, that were statistically highly significant (P < 0.001). Headache showed a statistical significant improvement with FEDS (P=0.012). However, patients did not show a statistically significant difference in improvement regarding nasal obstruction and facial pain with p values of 0.327 and 0.500 respectively (Fig. 8). Improvement in the endoscopy scores among patients treated with FEDS

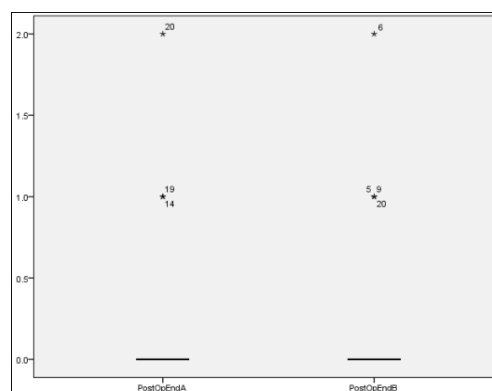
was statistically insignificant regarding all endoscopic parameters compared to those treated with FESS (Fig. 9).

Figure 8



Comparison between the post-operative overall total symptoms scores in both groups (A) and (B)

Figure 9



Comparison between the post-operative overall total endoscopy scores in both groups (A) and (B)

DISCUSSION

Since its approval by US Food and Drug Administration (FDA) in 2005, a number of studies have been published that attest to its feasibility, safety, and potential clinical efficacy to treat chronic rhinosinusitis [3,7,8]. The first large-scale investigation; the CLEAR study, was a multicenter study that aimed to confirm balloon sinuplasty safety, to evaluate ostial patency, and to assess post-operative symptomatology. Maxillary, frontal, and sphenoid sinuses were dilated in 115 patients using the balloon catheter. Overall, 50% of the patients underwent a Hybrid technique. Endoscopic sinus ostial patency rates at 24 weeks were 91% for maxillary sinus, 82% for frontal sinus, and 60% for sphenoid sinus. A statistically significant decrease in SNOT-20 scores was noted with using the balloon. The procedure appeared to be safe with no reported cases of cerebrospinal fluid (CSF) leak, orbital injury, or bleeding

requiring nasal packing [9]. A subsequent 1-year follow-up study showed ostial patency rates of 93% for maxillary sinus, 92% for frontal sinus, and 86% for sphenoid sinus [7].

In agreement with the results of these two previous studies, the present study, with using the VAS score as a parameter for symptoms assessment, revealed that patients treated with balloon sinuplasty showed a highly significant improvement of the total symptoms score three months following treatment (p value < 0.001). The mean pre-treatment overall score was 14.25 ± 5.476 and improved to 2.45 ± 3.252 . More emphasis on each of the symptoms evaluated showed post-treatment significant improvement of nasal obstruction, headache, discharge and facial pain. Although, the mean symptom score of smell affection improved from 0.2 ± 0.894 to 0 after treatment, yet it did not reach statistical significance.

The CLEAR study serves as an example of a typical single-armed, uncontrolled, observational study, however, the lack of a comparison group significantly limits interpretation of the results or any efficacy claims relative to the FESS paradigm [10].

Conversely, Friedman and Wilson (2009) in their study compared balloon technique versus FESS. In both groups, SNOT-20 scores improved significantly compared to baseline (2.8 to 0.78 for balloon and 2.7 to 1.29 for FESS). Patients in the balloon group reported higher satisfaction rates [11]. In comparing these results with ours, the overall symptoms score using the VAS showed a statistically highly significant improvement with P value < 0.001 for both groups (14.25 to 2.45 for balloon and 18.40 to 6.50 for FESS). We further compared the postoperative results between the two groups in which FESS showed better improvement in nasal discharge and overall symptoms score, that was statistically highly significant ($p < 0.001$). Headache showed a statistical significant improvement with FESS ($p = 0.012$). However patients did not show a statistically significant difference in improvement regarding nasal obstruction and facial pain with p values of 0.327 and 0.500 respectively.

One of the largest study to date was a retrospective study done by Levine and his colleagues at 27 different centers. This study analyzed data from 3,276 sinuses from 1,036 patients. Sinus symptoms were improved in 95.2%, unchanged in 3.8%, and worse in 1.0% of patients. There were no major adverse events associated with use of balloon catheters. Two cases of CSF leaks (0.3%) and six cases of minor bleeding requiring packing and/or cautery were reported in cases undergoing concomitant ethmoidectomy. Revision surgery was required in 25 patients (2.4%) [12]. In our study, no complications were reported apart from minor bleeding in some patients who required nasal packing to control. However, this can be explained due to the difference in the sample size between the two studies.

Catalano and Payne (2009) reported on 20 patients with chronic frontal sinusitis treated with balloon catheter dilatation of the frontal sinus outflow tract. Their results showed that the success rates for Samter's triad, CRS with polyposis, and CRS without polyposis were 36.4%, 40%, and 61.5%, respectively [13]. These success rates are much lower than has been previously reported for ostial patency for primary and revision endoscopic frontal sinusotomy at 82.3% and 86.6%, respectively. [14,15] On the other hand, Vaughan in his review stated that FESS for frontal disease can induce complications related to the skull base, anterior ethmoid artery, olfactory mucosa and peri-orbital tissue. In his practice, most patients require revision. Mucosal removal, edema, infection, incomplete surgery and scar tissue formation may, independently or in various combinations, lead to failure [16]. In another study with Rehl, Vaughan reviewed a series of patients in which FRED was attempted on 95 recesses; 91% were accessible. At 6 months follow up, there was a patency rate of 99%. One recess was closed and required a revision procedure [17]. These results match with those of our study; among the twenty patients treated with balloon sinuplasty, 33 frontal recesses were approached and 3 months follow up showed a patency rate of 96.9%. Only one patient required revision surgery. While for the 16 maxillary sinuses ostia dilated with the balloon, 3 months follow up revealed a patency rate of 100%. After treatment with balloon sinuplasty, mucosal edema was completely improved in all twenty patients with a p value of 0.001 (highly significant). Nasal polyps, scarring/adhesion, or crustation findings post-operatively did not show any statistical significance, while mucopus showed a statistical significant improvement (p value = 0.033).

One of the complaints of the balloon dilating catheter is the cost associated with the procedure. Most instrumentation commonly used in ESS is not disposable. There is an array of instrumentation required to use this technique that is not reusable between patients; a standard bilateral case for six sinuses (two sphenoid, frontal, and maxillary sinuses) typically uses three introducing cannulas, one guidewire, and one balloon. This costs approximately \$1200. Despite these up-front costs, there are potential savings also associated with this technique. First, there may be an overall reduction of operating room time, which decreases charges from the operating facility as well as from the anesthesia team. There is also a reduction in the number of debridements commonly performed in the postoperative period as there is less mucosal disruption [18]. Friedman et al. (2008) reported that charges for FESS exceeded those for balloon dilatation. The difference in charges was attributed to shorter operating room and recovery room times and reduced need for general anesthesia by one third in the balloon group. In the present study, the cost for balloon sinuplasty was estimated by \$1500 (9000 Egyptian Pounds) [19]. The fact of being disposal with a relatively high cost makes it less cost-efficient if compared to the

standard autoclavable ESS instruments. However; being less invasive with a shorter operative time and the possibility to use it as an office-based procedure, makes it attractive as a new modality of treatment for CRS.

Although some claim that diseased bone must be removed to effectively clear infection. Some outcome data could challenge the postulate that all diseased bone must be removed in order to clear disease; Kuhn et al (2008) reported a one-year patency rate of 91.6% with balloon dilatation. In the same context [7], Weiss et al reported a two-year durability of clinically significant symptom improvement (SNOT-20 reduced from 2.17 to 0.87) [8]. Similar to these results, we found that at 3 months follow up, objective assessment using the endoscope showed that mucosal edema was completely improved in all twenty patients treated with the balloon catheter with a p value of 0.001 (highly significant). Mucopus was present in 2 patients (10%) with a statistical significant improvement (p value= 0.033). Nasal polyps, scarring/adhesion, despite of their improvement, they failed to show any statistical significance with P values of 0.083 and 0.180 respectively.

Wiess et al. (2008) in their study; following up patients who underwent balloon sinuplasty, stated that 2 year post-operative mean Lund-Mackay CT scores decreased from 9.66 pre-operatively to 2.69 post-operatively which was highly statistically significant ($p < 0.001$) [8]. In the current study, CT scanning was not done as a routine post-operative investigation and left only for patients who had persistent symptoms for at least 4 weeks after the operation. Only one patient had persistent symptoms after balloon dilatation and was subjected to CT.

As a device, the balloon dilating catheter allows the surgeon to accomplish tasks that other instruments cannot. First, frontal sinusotomy can be performed without ethmoidectomy. Second, maxillary antrostomy can be performed without removal of the uncinate process. Although the function of the uncinate process has been debated, there may be some unrecognized benefit to this mat-like structure that protects the middle meatus by acting as a physical barrier to airborne antigens/pathogens while diverting airflow away from the middle meatus/osteomeatal complex. Perhaps the absence of the uncinate process could help explain why the microbial flora is so different in chronic rhinosinusitis patients who have been operated upon and those who have not. Third, a trans-nasal sphenoid sinusotomy can be performed without removal of any portion of the superior turbinate and risk of hyposmia or skull base fracture. Next, it can be used to relieve a frontal sinus that is obstructed by a type III frontal cell that has pneumatized high and lateral into the frontal sinus. It can reach this difficult anatomic configuration with a trans-nasal approach rather than via a trephine or osteoplastic flap. It can also be used in the office with no sedation or anesthesia to treat frontal ostium

stenosis [18]. However, in this study out of the twenty cases treated with balloon sinuplasty, 11 patients (55%) required ethmoidectomy in addition (hybrid technique); as to reach to the ostia of the maxillary and frontal sinuses in these patients with the balloon, uncinctomy and/or ethmoidectomy including removal of the cells surrounding the frontal sinus ostium (uncapping the egg) were performed.

CONCLUSION

Balloon sinuplasty is a new tool in rhinology which can be used for treatment of patients who have CRS recalcitrant to medical treatment. It can be used alone or in combination with FESS (hybrid technique). In view of previous results, it could be concluded that: Balloon Sinuplasty proved to be safe and effective and shows improvement of symptoms and signs in patients with mild CRS with similar results to those of the conventional FESS. Concerning the cost-benefit ratio; being disposal with a relative higher cost than FESS hinders the publicity of the procedure, however, it is superior to FESS in being less invasive, having a relative shorter operative time, and that it can be done under local anesthesia as an office-based procedure.

Further comparative multicenter studies with a larger sample size are recommended to assess its effect over a long period of time and to address the appropriate indications and guidelines for such a new technique.

REFERENCES

1. Benninger MS, Ferguson BJ, Hadley JA et al. Adult chronic rhinosinusitis: definitions, diagnosis, epidemiology, and pathophysiology. *Otolaryngol Head Neck Surg.* 2003;129:s2-32.
2. Lazar RH, Younis RT, Long TE et al. Revision functional endonasal sinus surgery. *Ear Nose Throat J.* 1992;71:131-3.
3. Bolger WE, Vaughan WC. Catheter based dilation of the sinus ostia: initial safety and feasibility analysis in a cadaver model. *Am J Rhinol.* 2006;20:290-4.
4. Brown C, Bolger WE. Safety and feasibility of balloon catheter dilation of paranasal sinus ostia: a preliminary investigation. *Ann OtolRhinolLaryngol.* 2006;115:293-9.
5. Friedman M, Schalch P, Lin HC et al. Functional endoscopic dilation of the sinuses: patient satisfaction, postoperative pain and cost. *Am J Rhinol.* 2008;22:204-9.
6. Lund VJ, Mackay IS. Staging in rhinosinusitis. *Rhinology.* 1993;107:183-4.
7. Kuhn FA, Church CA, Goldberg AN et al. Balloon catheter sinusotomy: One-year follow-up—Outcomes and role in functional endoscopic sinus surgery. *Otolaryngol Head Neck Surg.* 2008;139:S27-S37.

8. Weiss RL, Church CA, Kuhn FA et al. Long-term outcome analysis of balloon catheter sinusotomy: two-year follow up. *Otolaryngol Head Neck Surg.* 2008;139:38-46.
9. Bolger WE, Brown CL, Church CA et al. Safety and outcomes of balloon catheter sinusotomy: a multicenter 24-week analysis in 115 patients. *Otolaryngol Head Neck Surg.* 2007;137:10-20.
10. Friedman M, Wilson M. How I Do It: Illumination Guided Balloon Sinuplasty. *Laryngoscope.* 2009;119: 1399-1402.
11. Levine HL, Sertich AP, Hoisington DR, Weiss RL, Pritikin J. Multicenter registry of balloon catheter sinusotomy outcomes for 1,036 patients. *Annals of Otolaryngology, Rhinology and Laryngology.* 2008;117:263-70.
12. Batra PS, Ryan MW, Sindwani R. Balloon catheter technology in rhinology: reviewing the evidence. *Laryngoscope.* 2011;121:226-32.
13. Catalano PJ, Payne SC. Balloon dilation of the frontal recess in patients with chronic frontal sinusitis and advanced sinus disease: an initial report. *Ann OtolRhinolLaryngol.* 2009;118:107-12.
14. Chandra RK, Palmer JN, Tangsujarittham T et al. Factors associated with failure of frontal sinusotomy in the early follow-up period. *Otolaryngol Head Neck Surg.* 2004;131:514-8.
15. Chiu AG, Vaughan WC. Revision endoscopic frontal sinus surgery with surgical navigation. *Otolaryngol Head Neck Surg.* 2004;130:312-8.
16. Vaughan WC. Review of balloon sinuplasty. *Curr Opin Otolaryngol Head Neck Surg.* 2008;16:2-9. Presented at the Triologic Society Annual Meeting, 2007.
17. Melroy CT. The balloon dilating catheter as an instrument in sinus surgery. *Otolaryngol Head Neck Surg.* 2008;139:S23-6.
18. Friedman M, Schalch P, Ninos J. Functional endoscopic dilation of the sinuses: safety, feasibility, patient satisfaction and cost. Presented at the ARS Annual Meeting, 2006.