

Evaluation of implant stability and marginal bone loss in immediate implant using “nano bone” versus “autogenous bone” for the treatment of patients with unrestorable single tooth: a randomized controlled trial

► **S. A. N. ADAM¹, A. E. ELARAB², A. R. A. RAHMAN³, D. F. ABEL RAHIM⁴**

¹Oral medicine and Periodontology department, South Valley University, Qena, Egypt

^{2,3}Oral medicine and Periodontology department, Faculty of Dentistry, Cairo University, Egypt

⁴Oral and Maxillofacial Radiology department, Faculty of Dentistry, Cairo University, Egypt

TO CITE THIS ARTICLE

Adam SAN, Elarab AE, Rahman ARA, Abel Rahim DF. Evaluation of implant stability and marginal bone loss in immediate implant using “nano bone” versus “autogenous bone” for the treatment of patients with unrestorable single tooth: a randomized controlled trial. *J Osseointegr* 2019;12(1):8-17.

DOI 10.23805 /JO.2019.12.01.21

ABSTRACT

Aim A randomized controlled trial was conducted to evaluate the advantages of using nano-hydroxyapatite (nHA) bone graft compared to the “gold standard” autogenous bone graft in the jumping gap with immediate implants.

Materials and methods Immediate implant placement was performed for the treatment of patients with an unrestorable single tooth. All eligible patients, in total 18, were randomly selected and divided in two groups, controls (AG) and study group (NB), in equal proportions (9 for each group). Six months later implants were surgically exposed and the measurements of the secondary outcomes were taken.

Results Implant stability outcomes showed no significant differences in the groups. Marginal bone level of both groups at baseline and after six months showed a significant difference, as bone loss occurred more in NB group than AG group.

Conclusion Within the limits of the present study the placement of NB graft in the jumping gap contributed in decreasing and reduced the morbidity of the donor site compared to autogenous bone (AB) group. Trial had been registered in both The Pan African Clinical Trials Registry (PACTR) PACTR201512001348246 and clinical trial.gov NCT02613663.

KEYWORDS: Autogenous bone; Immediate implant stability; Marginal bone loss; nano bone

INTRODUCTION

Tooth loss is occurring mainly due to dental disease as untreated caries, endodontic treatment failure, trauma, root fracture or periodontal diseases. Tooth extraction considered traumatic procedure sometimes result in immediate destruction of alveolar bone and soft tissue structure. Loss of alveolar bone after extraction occurs over six to twelve months (1). This called bone remodeling begins and continues for several months, most of the changes occur in the first three months (2).

Histologically, socket healing after tooth extraction starts by blood clot formation, proceeds by fill with woven bone and then mature trabecular bone after 6 months (3). This healing/repair is not complete due to physiological resorption of the external contours of the bony ridge over the first month after tooth extraction (4,5).

The post-extracted socket has a 50% reduction in both bucco-lingual dimension (2), and further loss of vertical dimension during the first year (6). In 2012 Tan et al., (7) concluded that vertical and horizontal dimensions were reduced around 11–22% and 29–63%, respectively, due to alveolar resorption after 6 months following tooth extraction. This atrophy is more intense in the buccal surface (about 0.8 mm) during the first 3 months (2).

After teeth loss, the most challenging and important target of treatment is the protection of bone and soft tissues. Atraumatic extraction techniques using instruments as periostomes can reduce the damage and bone resorption (8). Even if the residual buccal bone is still present at the time of extraction, the final outcome of bone remodeling phase is difficult to predict due to great individual variability which complicate the aesthetic outcome (9). Dental implants consider as an alternative for bridges and dentures to restore functional and aesthetic deficit occur due to missing teeth (10). Immediate implants placed in freshly extracted sockets are an alternative treatment for traditional dental implants aiming to reduce physiological resorption of alveolar ridge (11).

Immediate implant replacement has several benefits as:

fast and simple reclamation procedures through decreasing the number of dental appointments, shortening length of treatment time, lesser surgical intervention (12), and ideal axial orientation of the implant. In several situations it is not even necessary to elevate a flap. Immediate implant promotes the preservation of the bone and soft tissue contour, also offers mechanical support to the papillae and midfacial gingival tissues allowing for maximum preservation better than waiting for socket healing. As it decreases the amount of bone loss, which normally happens during the remodeling phase, in addition it accelerates the treatment of edentulism (2). However despite all the advantages immediate dental implantation has many disadvantages such as the unpredictable aesthetic outcome (9) like midfacial recession especially in incisors with high lip line which compromise the overall aesthetic results.

Several studies like (13,14) reported that about 20% of patients suffered from limited aesthetic outcomes with their final restorations due to buccal soft tissue recession with follow-up time 3 years. While in (2011) Kan et al., (15) revealed that the aesthetic satisfaction rate by patients was (9.9 of 10) at the first year recall, only 11% of the patients complained of disappointing restorations due to presence of facial gingival recession after a longer period of follow-up (mean 4 years, range: 2–8.2 years). Anterior maxillary aesthetic zone consider a challenging area during treatment because of esthetic concern and unfavorable bone topography (16). Interproximal bone levels plays a significant role such as it influence the socket healing, because this bone along with the facial bones make up the walls of a socket, and provide support to the interproximal papilla following immediate implant placement which depend on the level of interproximal bone (17,18).

Soft tissue recessions in immediate implantation could occur due to Multiple factors. In fact patients treated by flapless immediate implant placement with an intact facial bone and thick gingival biotype, with an immediate crown restoration, may exhibit an inferior risk of the occurrence of midfacial recession (<10%) (19). Other factors like absence of periapical pathologies, infected socket or periodontal diseases reduce the risk of failure, peri-implant marginal bone loss and mid-facial recession (20,21,22,23).

Initial implant stability is achieved by intimate contact between pristine socket bone and implant surfaces. Dental roots have wide non circle shape, while the implant has regular circular shape; in type 1 immediate dental implantation there is incongruity of size and shape between post-extraction sockets and implants presents challenge to primary implant stability and always there is residual bony defects around implants this space between bone and implant is called peri-implant gap (13,24). Primary stability is only achieved by securing the implant in the apical bone (3–4 mm), where cancellous bone leads to spontaneous bone fill occurs in the

peri-implant marginal gap after 3–4 months (4,25).

In type 1 immediate dental implant intra- and extra-alveolar modeling and remodeling occur, which lead to the inevitable bone vertical and horizontal reduction conspicuously in facial alveolar bony walls. These biological changes imply higher risk of marginal mucosal recession after immediate implant placement, which could result in non-aesthetic restorations in areas of aesthetic priority (26).

To overcome the problem of residual peri-implant jumping gap, grafting materials has been proposed to fill the implant-to bone space (27). Bone grafts act as a space maintainer to reduce the alveolar bone loss and promote osteogenesis (28). Several systematic reviews (12,29) tested this theory and revealed inconclusive evidence, but short-term trials proved that the aesthetic outcome has been enhanced with using resorbable bone augmentation (9,30,31,32).

Source of bone graft can be autograft from the same person, allograft from other individuals, xenograft that comes from another species, or synthetic alloplast material (33). Autograft bone is considered the gold standard as it provides scaffolding for osteoconduction, osteoinduction, and pluripotent progenitor cells for osteogenesis (34). Unfortunately, this is not fully taken in practice because of the death of most of the cells (35). About 80% of the bone is consisting of dense cortical bone, with 20 % highly porous and vascular cancellous bone. However, this cancellous bone is responsible for 88% of the amount of the normal bone turnover. The donor site can be mentonian region, retromolar area, maxillary tuberosity, chin, iliac crest, rib, cranium, tibia, and fibula (36). Cancellous bone is load distributor as predominantly susceptible to compressive forces and has minimal weight-bearing function.

However, there are several disadvantages of autogenous bone graft technique, like serious complications that occur in the donor site as donor area morbidity, infection, edema, hematoma, vascular or nerve lesions (37) limited availability (38), high cost, more intra-operative blood loss, temporary disruption of the bone structure in the donor-site, also, this technique take more surgical time and provides limited amount for large reconstructions (34,35).

Synthetic NanoBone grafting material (Artoss,Rostock, Germany) "nanocrystalline hydroxylapatite (nHA) used as synthetic alternatives to bone grafting materials overcomes both the avoidable and unavoidable problems of autograft. It is a new product that has been available commercially since 2005. Consists of a slow resorbing nanocrystal 74% unsintered hydroxyapatite embedded in a 24% microporous Silica dioxide (SiO₂) gel matrix with interconnecting pores on the nanoscale (39,40). It has many advantages as safer, faster bone formation, complete bone graft remodeling, and high performance through nanostructure (41).

According to Gotz et al., (42) The NanoBone's HA com-

ponent is responsible for osteoconductivity, while the silica gel component is assumed to stimulate connective tissue formation, osteoblast proliferation, matrix mineralization and calcification, so it combining osteoconductive and osteoinductive properties.

Tooth loss can affect deeply patient's psycho-social and daily activities, also associated with functional and esthetic problems (43). Implant stability is a fundamental criteria and important factors in achieving implant success and osseointegration (44). The connection between the implant and surrounding socket bone is generated by many mechanical factors include implant design, bone augmentation, treatment protocol, surgical procedure, along with local and systemic factors (45).

There are several methods used to measure marginal bone level changes postoperatively, with a wide range of reliability. The conventional and digital periapical x-ray techniques using paralleling cone technique have proven to be the accurate and the most practical method for the linear measurement of alveolar bone height with less radiation exposure in comparison to 3D imaging (46,47,48).

MATERIALS AND METHODS

The study was approved by the ethical committee of Faculty of Oral and Dental Medicine, Cairo University. Eighteen patients (10 females, 8 males) participated in this randomized clinical trial as a parallel study, unicenter, double blinded. All patient signed informed consent form. Eligible patients were randomly selected to both control or study group in equal proportions between active control group immediate implant with Autograft and study group immediate implant with NanoBone® (Artoss GmbH). Patients were recruited based on eligible criteria include 1) individuals with ≥ 18 years of age, 2) hopeless tooth in maxillary aesthetic area due to endodontic problems, trauma or prosthetic issues, 3) intact four-wall sockets of the teeth, 4) good oral hygiene condition and jumping gap ≥ 2 mm. exclusion criteria were 1) history of systemic diseases that would contraindicate surgical treatment (49). 2) acute infection in surgical sites (49). 3) long term non-steroidal anti-inflammatory drug therapy. 4) periodontal disease with bone loss. 5) known allergy to any of the materials used in the study. 6) molar extraction sites. 7) patients with severely atrophic ridges requiring a staged grafting procedure (49).

Sample size was calculated using G*Power program (University of Düsseldorf, Düsseldorf, Germany), sample size was 18 (9 for each group). Patient from the outpatient clinic of the oral medicine and periodontology department – Cairo University. Screening of patients was done until the target population was achieved. Allocation "sequence generation" had been done by using software program: www.random.com to divide patient randomly. An opaque sealed envelopes used to allocate

each patient into one clinical and radiographic assessors were blinded they didn't involve in sequence generation or allocation concealment or performance of surgery.

Presurgical treatment:

Patients were checked for the integrity of the socket. Severe caries, periapical lesions and periodontal disease were treated prior to implant placement in the same quadrant. Primary impression was taken for the patients to make a study cast.

Intraoperative procedures for both groups

The patient was advised to rinse with 0.2% chlorhexidine mouth wash for 1 minute. Atraumatic tooth extraction was done by periosteal. Care was taken to avoid fracture of socket wall. Extraction sockets were carefully cleaned of any remains of granulation tissue, evaluated for the integrity of the labial bone and when possible, minimally invasive crestal flap was used to visualize the crestal bone margin on the labial aspect. Drills were used to prepare the socket for the implant. The axis of the implant was aligned with the incisal edges of the adjacent teeth or be slightly palatal to this landmark. The implant head was placed at a minimum of 2 mm apical to the interproximal and crestal bone.

Intraoperative procedures for the study group

The gap between the facial aspect of the implant and the buccal wall was measured and then filled with NanoBone® (NB). Primary closure was intended but wounds in all cases were left partially open because complete soft tissue coverage was not easy to achieve. The flap was scored and sutured in place without tension using 3-0 vicryl suture (Figure 1).

Intraoperative procedures for the control group

Harvesting of the autogenous bone (AB) was done from the chin. Vestibular incision method was used as an access to the donor site. A wide full-thickness incision was made. Care was taken not to involve the mental nerve bundles. The incision was then directed apico-lingually toward the bone, the full thickness flap was reflected until the lower border of the mandible. Bone harvesting was done using trephine bur (2015 Hu-Friedy Mfg. Co., LLC). Rule of 5's was followed, trephine bur was held perpendicular on the cortical plate. The cuts were "5mm" away from teeth roots, inferior border of the mandible and away from the mental foramina. The bone block was milled to granules using bone mill then it was mixed with saline or blood which was immediately placed in the gap between the implant and the socket on the labial aspect, once the gap was filled with bone cross figure suture technique was used to secure the bone graft in position. Closure of the soft tissues in the donor site was immediately done to minimize exposure of the osseous tissue to contamination from the oral environment (Figure 2).

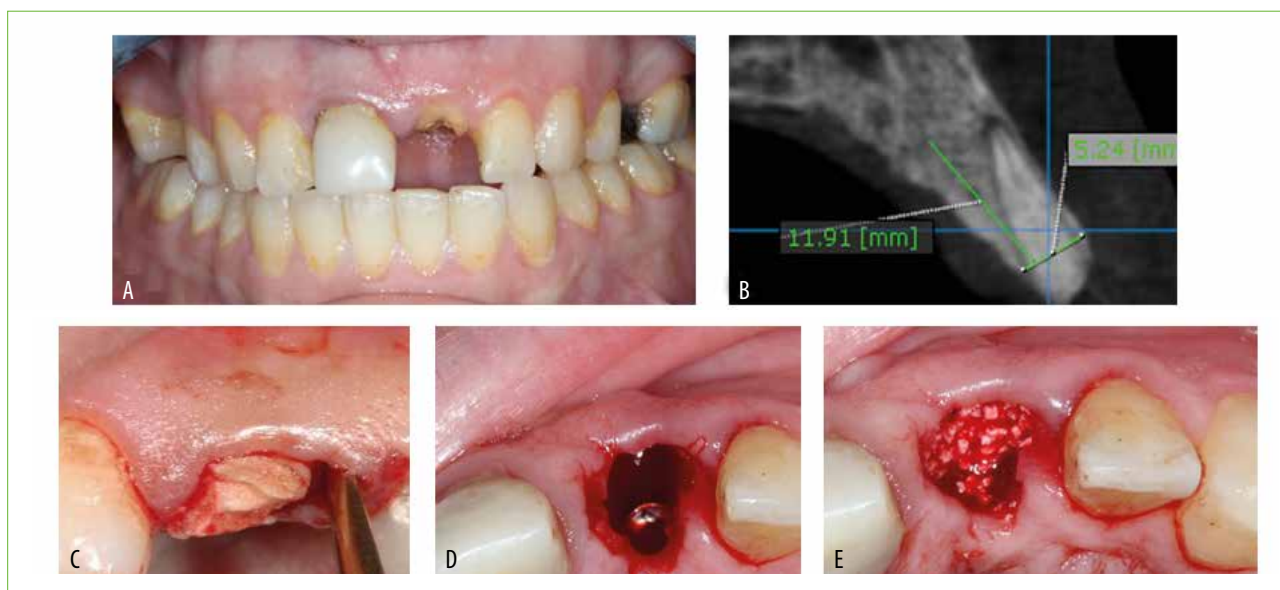


FIG. 1 NanoBone grafted jumping gap. Non-restorable upper left 1st central (frontal view) (A), sagittal cut of CBCT showing no dehiscence or fenestration (B), Periosteum was used for atraumatic extraction, (D): Implant placed sub-crestal (C), NB filled the jumping gap (E).

Postoperative procedure

Six months later implants were exposed surgically and the healing abutments were placed allowing the soft tissue to heal completely. During that the measurements of the outcomes were taken.

- Outcome assessment:
- Radiographic assessment:

Preoperative radiographs

CBCT (Planmeca Promax 3D Mid machine, Helsinki, Finland) scan was obtained for the upper and lower (chin area) arch to every included patient for measuring the available bone width, vertical and bucco-lingual dimensions, determine if there were any apical lesions, check the integrity of the socket wall, determine the diameter

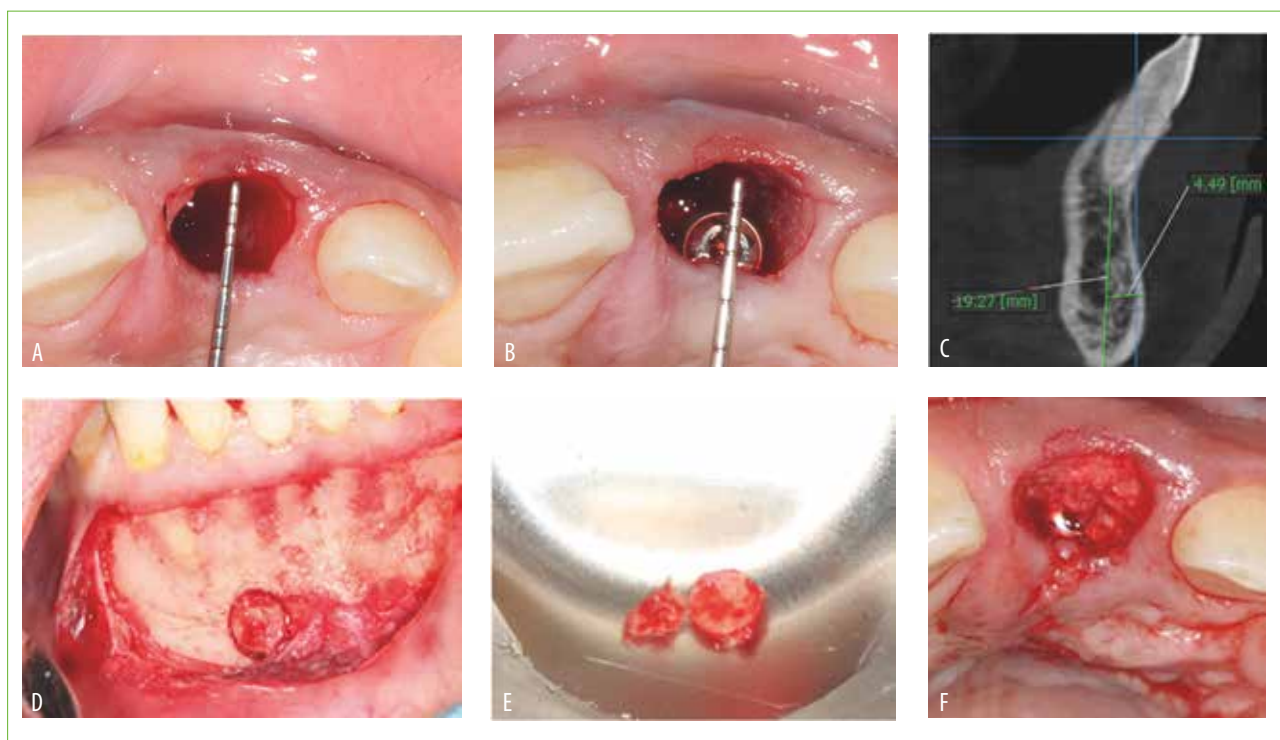


FIG. 2 Autograft in the jumping gap. Atraumatic tooth extraction, labio-palatal and mesio-distal clinical measurement (A), implant installed (jumping gap 2mm) (B), CBCT using rule 5 for chin graft harvesting (C), harvesting of autograft bone block with Trephine bur (D), Milled bone graft (D) placed in the jumping gap (F).

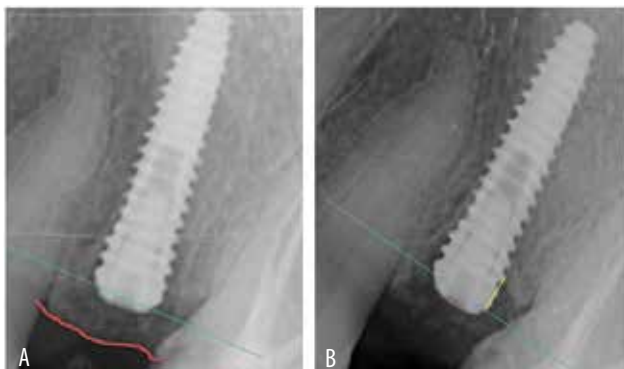


FIG. 3 Digital radiograph scan: baseline digital periapical x-ray (A), 6 month digital periapical x-ray (B).

and length of fixture that will be used and to identify, recognize the anatomical structure and to determine the exact position and dimension of the chin graft (50).

Postoperative radiograph

For the digital radiograph scan; an individualized bite block was prefabricated by using acrylic resin material which was built on the study cast. A film holder with bite block was used at follow-up to ensure image reproducibility.

During the first week after surgery using MINRAY® x-ray machine (Soredex, Tuusula, Finland) with fixed parameter (tube voltage 70 kVp and tube current 7 mA at 0.08 second) digital images were obtained with size 2 photostimulable plate (PSP) (Soredex, Tuusula, Finland) using the Digora Optime imaging system by strict standardized imaging technique.

To evaluate marginal bone level changes, mesial and distal marginal bone levels were measured. The implant shoulder was used as the reference point. The distance from the reference point to the bone level was recorded mesially and distally (51,52).

Follow-up

After 6 month implants were surgically exposed. The relative radiographic marginal bone level change was evaluated by using the same bite block for each patient, same software linear measurement tool and x-ray machine parameters (see figure 3).

The relative radiographic marginal bone levels were assessed by the Digora software (Soredex, Tuusula, Finland) on the standardized digital periapical radiographs with calibration each time. The measurements were recorded to compare between pre and post-operatively and compared between the two groups.

Implant stability measurement:

Implant stability was assessed by using Osstell ISQ (Osstell AB Gamlestadvägen 3B - SE 415 02 Göteborg - Sweden) (53). The SmartPeg transducers were used on each implant and four measurements were completed

(buccally, palatally, mesially and distally) by blinded clinical assessor experienced with knowl-edge of the Osstell ISQ system for Resonance Frequency Analysis (RFA) assessment.

SmartPeg was directly attached to the implant with the interposition of no prosthesis, no soft tissue interposition, no contact between any part of the SmartPeg and teeth, and Placement of the Osstell ISQ's probe was approximately 2 mm from the SmartPeg in a 90° angle relative to the implant's major axis. RFA measurements were taken on total subjects and were statistically analyzed and compared between the two groups.

Statistical analysis

Statistical analysis was performed with SPSS 20® (Statistical Package for Social Science, IBM, USA), Graph Pad Prism® (Graph Pad Technologies, USA) and Microsoft Excel 2016 (Microsoft Co-operation, USA). Data presented as means and standard deviation (SD) values. One-way analysis of variance (ANOVA) followed student's t test performed to compare between both groups regarding marginal bone loss and implant stability.

The significant level was set at $P \leq 0.05$.

RESULTS

Fifty subjects were screened for participating in this clinical trial from 2016 to 2018 using CONSORT flowchart. Eighteen healthy individuals were recruited in the study, their age ranged from 18-60. The patients were randomly allocated into two groups based on the type of bone augmentation in the jumping gap. All implant sites healed uneventfully and no complications were reported at the re-entry procedure.

Testing of normality:

Values were obtained along this study for both groups as means and standard deviations. By using Kolmogorov-Smirnov/Shapiro-Wilk tests for normality, a p-value of 0.05 rejects the null hypothesis that the data are from a normally distributed population.

Marginal bone level evaluation

1. Group I (Nano Bone) Follow-up

At baseline revealed a value of (1.422 ± 0.448) at the mesial side and (1.49 ± 0.365) at the distal side. While after six months, mesial surface was (0.711 ± 0.077) and distal surface was (0.7911 ± 0.079) , all listed in table (1). Using Student's t test, there was significant decrease in marginal bone level values after six months at the mesial and distal sides as P -value < 0.05 .

2. Group II (Autogenous Bone)

At baseline revealed a value of (0.9744 ± 0.0599) at the mesial side and (0.877 ± 0.0682) at the distal side. While after six months, mesial surface was (0.527 ± 0.0613) and distal surface was (0.321 ± 0.0597) , all listed in

		M ± SD		P-value
		Group I	Group II	
Baseline	Mesial	1.422 ± 0.448	0.9744 ± 0.0599	0.009**
	Distal	1.49 ± 0.365	0.877 ± 0.0682	0.0001**
After Six Months	Mesial	0.711 ± 0.077	0.527 ± 0.0613	0.0001**
	Distal	0.7911 ± 0.079	0.321 ± 0.0597	0.0001**
<i>M: Mean, SD: Standard Deviation, P: Probability level</i>				
<i>**significant difference</i>				

TABLE 1 Comparison of Marginal Bone Level between Both Groups:â

		M ± SD		P-value
		Group I	Group II	
Buccal		62.78 ± 7.69	67.78 ± 12.26	0.316*
Mesial		62.11 ± 6.03	60.44 ± 10.33	0.682*
Distal		62.11 ± 6.03	60.44 ± 10.33	0.682*
Palatal		62.78 ± 7.69	64.78 ± 10.73	0.656*
Average		62.44 ± 6.86	63.36 ± 10.91	0.8331*
<i>M: Mean, SD: Standard Deviation, P: Probability level</i>				
<i>*insignificant difference</i>				

TABLE 2 ISQ measurements for group I and group II.

table (1). There was insignificant decrease in marginal bone level values at the mesial and distal sides after six months follow up as P-value > 0.05.

3. Comparison of Marginal Bone Level between both groups

For group I and group II at baseline mean ± SD of mesial surfaces were (1.422 ± 0.448 and 0.9744 ± 0.0599) and distal surfaces were (1.49 ± 0.365 and 0.877 ± 0.0682) respectively. While after six months, mesial surfaces were (0.711 ± 0.077 and 0.527 ± 0.0613) and distal surfaces were (0.7911 ± 0.079 and 0.321 ± 0.0597), all listed in table (1) and showed in (Figure 4). There was a significant difference between both groups for mesial and distal surfaces as P-value < 0.05, listed in table (1).

Implant stability evaluation through isq measurements using osstell device:

mean ± SD for buccal surface was (62.78 ± 7.69 and 67.78 ± 12.26), mesial surface was (62.11 ± 6.03 and 60.44 ± 10.33), distal surface was (62.11 ± 6.03 and 60.44 ± 10.33) and palatal surface was (62.78 ± 7.69 and 64.78 ± 10.73) respectively, all listed in table (2). There was an insignificant difference between both groups for all surfaces as P-value > 0.05, listed in table (2).

DISCUSSION

Bone remodeling naturally following tooth extraction, occurs as catabolic changes begin with bundle bone resorption that lines the extraction socket, which is a tooth-dependent structure. At the palatal bone plate, bundle bone represents about 0.2 to 0.3 mm width, whereas at the buccal bone plates, it is frequently ≥2 mm (2), almost consisting of the entire width of the buccal bone in the coronal part of the tooth socket (54). Factors that affect the degree of vertical and horizontal bone alterations after tooth extraction include lacking of both mechanical stimulus and vascular blood supply due to loss of periodontal ligament. With reduced vascular supply, the bundle bone becomes non-functional through and ultimately undergoes complete resorption (55).

Placement of post-extracted dental implants minimize the rate of bone loss, even though it failed to stop the bone remodeling that occurs naturally (56). Using resorbable bone substitutes has shown to change these modeling events and partially counteract the marginal ridge contraction (57,58,59,60). In other studies very limited benefits obtained after immediate implantation with simultaneous bone grafting (61,62,63).

In the test group, the NB graft was placed till the level of

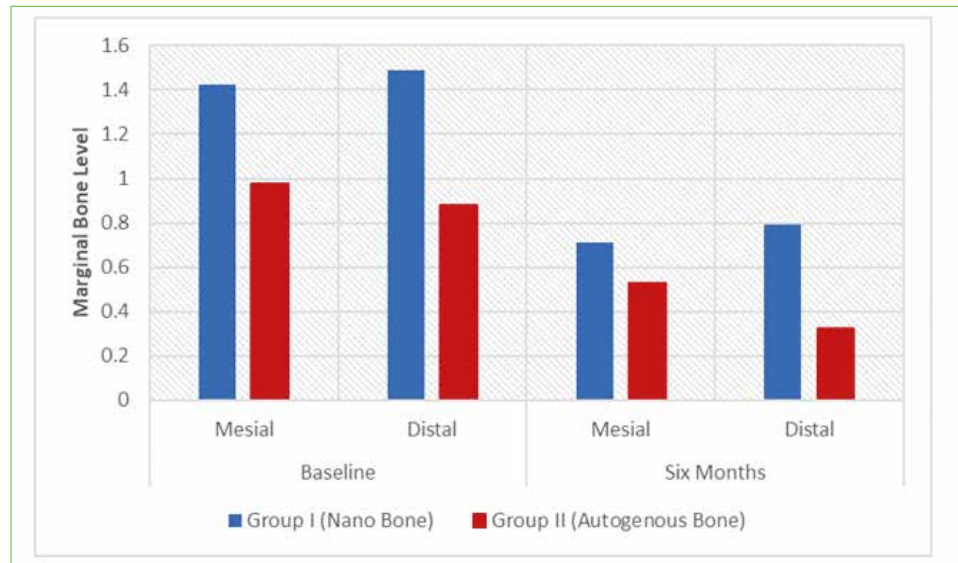


FIG. 4 Bar chart of marginal bone height for both groups.

the peri-implant mucosa as recommended by Araujo et al. (57), and Chu et al. (64) to improve the level of marginal bone to implant contact and prevent soft tissue recession. In the control group, the mandibular symphysis area is a favorable donor site (50); offers a large amount of cortico-cancellous autograft, easy to access and can be harvested in the dental clinic (65).

Cornelini et al. (66), and De Angelis et al. (30) reported that marginal bone loss around dental implants might represent a threat to implant aesthetic and longevity. Marginal bone loss that occurs after implantation may be influenced by multifactor such as infection or occlusal overloading the implants (67), surgical trauma, peri-implantitis, biologic width, implant crest module and surgical approach (68).

Implant stability is the main factor for the immediate placement success which used as guide for the best time for implant loading (69). Resonance frequency analysis (RFA) is non-invasive, clinically reliable method with reproducibility used to assess implant stability and osseointegration (44,70).

At the end of this randomized clinical trial (RCT) the evaluation of the implant stability assessment in the study; there was statistical insignificant difference in ISQ measurements after 6 months between the "NanoBone" group and "Autogenous bone" group. This demonstrated the possibility of achieving osseointegration and stability of dental implants either grafted with NanoBone or Autogenous bone graft.

These results are in agreement with Vanden Bogaerde et al. (71), Villa and Rangert (72) and Crespi et al. (73). They studied immediate implants placement with early loading and Autogenous bone graft in anterior/posterior mandible/ maxilla arch; the measurement of ISQ was 60-63 after 6 months revealing the preservation of high implant stability.

Another prospective controlled studies (64,74,75) using

immediate implants with Autogenous graft in anterior aesthetic area, reported implant stability (ISQ) with mean value of $64.5 \pm 6.3.9$ at 6 months and no significance difference with the comparator "delayed implant" group.

Also Antunes et al. (76) who studied immediate implants installed in dogs mandible with Autogenous bone grafts versus hydroxyapatite/tricalcium phosphate (HA/TP) revealed no significant difference between groups " 56.66 ± 8.10 " " 58.27 ± 6.03 " respectively, after 2 month follow-up.

In a randomized Case-Series Vanden Bogaerde and Sennerby (77) placed 22 immediate implants with immediate function in 11 patients, 13 of the implants were augmented with Autogenous graft and only one implant was augmented with NanoBone which failed after six weeks showing a constant decline in stability. RFA values were measured in autogenous bone grafted implants in a bucco-palatal direction and have shown a progressive stability increase.

Regarding to radiographic assessment of the marginal bone level (MBL) using digital x-ray showed that there was statistical significant reduction in MBL in mesial and distal surfaces in the NB group. Moreover, in the AB group there was a significant reduction in MBL for both mesial and distal surfaces compared with 6 month MBL. Baseline radiographs assessment showed peri-implant bone level was more coronal to implant shoulder as x-rays were taken during first week after sub-crestal implant placement and bone grafts packing. Bone graft particles had confounded the radiograph assessor for scoring the actual marginal bone level at baseline. Ideally x-rays should be taken at implant placement before bone augmented (30). Meanwhile six months readings showed peri-implant bone loss; many investigators supported this finding. Regarding the use of an immediate implant plus AB graft in a randomized case series; Vanden Bo-

gaerde and Sennerby (77) reported the outcomes on marginal bone changes. There were no significant differences between immediate implant placements with Autogenous bone compared with immediate implantation without any grafting control group. Most of the marginal bone was lost during the first three months ($0.6 \pm 0.4\text{mm}$).

In RCTs as Chen et al. (78) and Sanz et al. (60) reported crestal bone height changes at 6 months follow-up; the mean vertical height change showed a loss of 1.12 mm. Another RCT by Hazzaa et al. (32) reported a mean change in vertical height with a loss of 2.57 ± 0.23 mm after 6 months of immediate implants placement augmented with autogenous bone/melatonin composite graft. While in a prospective trial by Noelken et al. (79) measuring MBL in immediate implants with autograft in aesthetic anterior zone revealed that at 5 years follow-up the mean and SD was (0.15 ± 0.59 , -0.05 ± 0.54 , 0.04 ± 0.65) 1st year, 3rd year and 5th year respectively. The tenable explanation of marginal bone loss in this study and the other supported studies could be related to the phenomenon of normal bone remodeling and replacement of the bone grafts by new bone formation in the jumping gap (30).

CONCLUSION

Within the limitations of this study. It may be concluded that:

- Although the placement of nanobone (NB) graft in the jumping gap did not counteract the bone loss after tooth extraction and immediate implant installation, it contributed in reduced the morbidity of the donor site compared to autogenous bone (AB) group.
- Both treatment approaches were associated with implant stability with insignificant difference.

Recommendations

- More randomized clinical trials are needed to compare both treatment approaches with longer follow up.
- Further studies should be conducted to compare the nanobone with immediate implants measuring other clinical primary outcomes such as bone density and quality of life.
- Further studies are recommended for comparing implant installation with different measurements of jumping gap and different types of bone graft.
- The soft tissue dimensional changes after immediate implant placement should be evaluated in further studies.

Acknowledgments

I would like to express my sincere gratitude to Prof. Azza Ezz Elarab to whom I had the privilege of doing this work under her supervision. Assist. Prof. Dr. Ahmed Reda I wish to thank him for his continuous effort. To Dr. Dena Fahem for her guidance, encouragement, and explicit

work in radiographic and implant stability assessment.

Funding

Self-funded. No conflict of interest. Role of authors:

- Samar Ahmed Nouby Adam: (Principle Investigator) Researcher;
- Prof. Azza Ezz Elarab: The senior supervisor;
- Assist.prof. Ahmed Reda: Assistant supervisor;
- Dr. Dina F. Abel Rahim: Assistant supervisor.

REFERENCES

1. Johnson K. A study of the dimensional changes occurring in the maxilla following tooth extraction. *Aust Dent J* 1969; 14(4): 241-4.
2. Schropp L, Wenzel A, Kostopoulos L, Karring T. Bone healing and soft tissue contour changes following single-tooth extraction: a clinical and radiographic 12-month prospective study. *Int J Periodontics Restorative Dent* 2003; 23(4): 313-23.
3. Cardaropoli G, Araujo M, Lindhe J. Dynamics of bone tissue formation in tooth extraction sites. An experimental study in dogs. *J Clin Periodontol* 2003; 30(9): 809-18.
4. Araujo MG, Lindhe J. Dimensional ridge alterations following tooth extraction. An experimental study in the dog. *J Clin Periodontol* 2005; 32(2): 212-8.
5. Brkovic BM, Prasad HS, Rohrer MD, Konandreas G, Agrogiannis G, Antunovic D, Sandor GK. Beta-tricalcium phosphate/type I collagen cones with or without a barrier membrane in human extraction socket healing: clinical, histologic, histomorphometric, and immunohistochemical evaluation. *Clin Oral Investig* 2012; 16(2): 581-90.
6. lasella JM, Greenwell H, Miller RL, Hill M, Drisko C, Bohra AA, Scheetz JP. Ridge preservation with freeze-dried bone allograft and a collagen membrane compared to extraction alone for implant site development: a clinical and histologic study in humans. *J Periodontol* 2003; 74(7): 990-9.
7. Tan WL, Wong TL, Wong MC, Lang NP. A systematic review of post-extraction alveolar hard and soft tissue dimensional changes in humans', *Clin Oral Implants Res* 2012; 23 Suppl 5: 1-21.
8. Caplanis N, Lozada JL, Kan JY. Extraction defect assessment, classification, and management. *J Calif Dent Assoc* 2005;33(11): 853-63.
9. Zuffetti F, Esposito M, Capelli M, Galli F, Testori T, Del Fabbro M. Socket grafting with or without buccal augmentation with anorganic bovine bone at immediate post-extractive implants: 6-month after loading results from a multicenter randomised controlled clinical trial. *Eur J Oral Implantol* 2013; 6(3): 239-50.
10. Pjetursson BE, Lang NP. Prosthetic treatment planning on the basis of scientific evidence. *J Oral Rehabil* 2008; 35 Suppl 1: 72-9.
11. Hammerle CH, Chen ST, Wilson TG Jr. Consensus statements and recommended clinical procedures regarding the placement of implants in extraction sockets. *Int J Oral Maxillofac Implants* 2004; 19 Suppl:26-8.
12. Esposito M, Grusovin MG, Polyzos IP, Felice P, Worthington HV. Interventions for replacing missing teeth: dental implants in fresh extraction sockets (immediate, immediate-delayed and delayed implants). *Cochrane Database Syst Rev* 2010; 9: Cd005968.
13. Botticelli D, Renzi A, Lindhe J, Berglundh T. Implants in fresh extraction sockets: a prospective 5-year follow-up clinical study. *Clin Oral Implants Res* 2008; 19(12): 1226-32.
14. Bianchi AE, Sanfilippo F. Single-tooth replacement by immediate implant and connective tissue graft: a 1-9-year clinical evaluation. *Clin Oral Implants Res* 2004; 15(3): 269-77.
15. Kan JY, Rungcharassaeng K, Lozada JL, Zimmerman G. Facial gingival tissue stability following immediate placement and provisionalization of maxillary anterior single implants: a 2- to 8-year follow-up. *Int J Oral Maxillofac Implants* 2011; 26(1): 179-87.

16. Gotfredsen K. A 10-year prospective study of single tooth implants placed in the anterior maxilla. *Clin Implant Dent Relat Res* 2012; 14(1): 80-7.
17. El Chaar E, Oshman S, Fallah Abe, P. Single-Rooted Extraction Sockets: Classification and Treatment Protocol. *Compend Contin Educ Dent* 2016; 37(8): 537-541;quiz542.
18. Kan JY, Rungcharassaeng K, Umezu K, Kois JC. Dimensions of peri-implant mucosa: an evaluation of maxillary anterior single implants in humans. *J Periodontol* 2003b; 74(4): 557-62.
19. Cosyn J, Hooghe N, De Bruyn H. A systematic review on the frequency of advanced recession following single immediate implant treatment. *J Clin Periodontol* 2012; 39(6): 582-9.
20. Takeshita F, Iyama S, Ayukawa Y, Suetsugu T, Oishi M. Abscess formation around a hydroxyapatite-coated implant placed into the extraction socket with autogenous bone graft. A histological study using light microscopy, image processing, and confocal laser scanning microscopy. *J Periodontol* 1997; 68(3):299-305.
21. De Boever AL, Quirynen M, Coucke W, Theuniers G, De Boever JA. Clinical and radiographic study of implant treatment outcome in periodontally susceptible and non-susceptible patients: a prospective long-term study. *Clin Oral Implants Res* 2009; 20(12): 1341-50.
22. Nowzari H. Esthetic implant dentistry. *Compend Contin Educ Dent* 2001; 22(8): 643-50, 652-4; quiz 655.
23. Ramanauskaitė A, Baseviciene N, Wang HL, Tozum TF. Effect of history of periodontitis on implant success: meta-analysis and systematic review. *Implant Dent* 2014; 23(6): 687-96.
24. Botticelli D, Berglundh T, Buser D, Lindhe J. The jumping distance revisited: An experimental study in the dog. *Clin Oral Implants Res* 2003; 14(1): 35-42.
25. Covani U, Bortolaia C, Barone A, Sbordone L. Bucco-lingual crestal bone changes after immediate and delayed implant placement. *J Periodontol* 2004; 75(12): 1605-12.
26. De Rouck T, Collys K, Cosyn J. Single-tooth replacement in the anterior maxilla by means of immediate implantation and provisionalization: a review. *Int J Oral Maxillofac Implants* 2008; 23(5): 897-904.
27. Rosenquist B, Ahmed M. The immediate replacement of teeth by dental implants using homologous bone membranes to seal the sockets: clinical and radiographic findings. *Clin Oral Implants Res* 2000; 11(6): 572-82.
28. Nemcovsky CE, Moses O, Artzi Z, Gelernter I. Clinical coverage of dehiscence defects in immediate implant procedures: three surgical modalities to achieve primary soft tissue closure. *Int J Oral Maxillofac Implants* 2000; 15(6): 843-52.
29. Esposito M, Grusovin MG, Coulthard P, Worthington HV. The efficacy of various bone augmentation procedures for dental implants: a Cochrane systematic review of randomized controlled clinical trials. *Int J Oral Maxillofac Implants* 2006; 21(5): 696-710.
30. De Angelis N, Felice P, Pellegrino G, Camurati A, Gambino P, Esposito M. Guided bone regeneration with and without a bone substitute at single post-extractive implants: 1-year post-loading results from a pragmatic multicentre randomised controlled trial. *Eur J Oral Implantol* 2011; 4(4): 313-25.
31. Rodrigo D, Martin C, Sanz M. Biological complications and peri-implant clinical and radiographic changes at immediately placed dental implants. A prospective 5-year cohort study. *Clin Oral Implants Res* 2012; 23(10): 1224-31.
32. Hazzaa HHA, El-Kilani NS, Elsayed SA, Abd El Massieh PM. Evaluation of immediate implants augmented with autogenous bone/melatonin composite graft in the esthetic zone: a randomized controlled trial. *J Prosthodont* 2019 Feb;28(2):e637-e642.
33. Kim YK, Lee JY, Kim SG, Lim SC. Guided bone regeneration using demineralized allogenic bone matrix with calcium sulfate: case series. *J Adv Prosthodont* 2013b; 5(2): 167-71.
34. Erbe EM, Marx JG, Clineff TD, Bellincampi LD. Potential of an ultraporous beta-tricalcium phosphate synthetic cancellous bone void filler and bone marrow aspirate composite graft. *Eur Spine J* 2001; 10 Suppl 2: S141-6.
35. Dimitriou R, Mataliotakis GI, Angoules AG, Kanakaris NK, Giannoudis PV. Complications following autologous bone graft harvesting from the iliac crest and using the RIA: a systematic review. *Injury* 2011; 42 Suppl 2:S3-15.
36. Coradazzi LF, Garcia IR Jr., Manfrin TM. Evaluation of autogenous bone grafts, particulate or collected during osteotomy with implant burs: histologic and histomorphometric analysis in rabbits. *Int J Oral Maxillofac Implants* 2007; 22(2): 201-7.
37. Sandhu HS, Grewal HS, Parvataneni H. Bone grafting for spinal fusion. *Orthop Clin North Am* 1999; 30(4): 685-98.
38. Summers BN, Eisenstein SM. Donor site pain from the ilium. A complication of lumbar spine fusion. *J Bone Joint Surg Br* 1989; 71(4):677-80.
39. Gerber TT, Henkel K-O, Bienengraeber V. Development and In Vivo Test of Sol-Gel Derived Bone Grafting Materials. *J Sol-Gel Science and Technology* 2003; 26(1-3): 1173-1178.
40. Troedhan A, Schlichting I, Kurrek A, Wainwright M. Primary implant stability in augmented sinuslift-sites after completed bone regeneration: a randomized controlled clinical study comparing four subantrally inserted biomaterials. *Sci Rep* 2014; 4: 5877.
41. Bienengraeber V, Gerber T, Henkel KO, Bayerlein T, Proff P, Gedrange T. The clinical application of a new synthetic bone grafting material in oral and maxillofacial surgery. *Folia Morphol (Warsz)* 2006; 65(1):84-8.
42. Gotz W, Gerber T, Michel B, Lossdorfer S, Henkel K.O, Heinemann F. Immunohistochemical characterization of nanocrystalline hydroxyapatite silica gel (NanoBone(r)) osteogenesis: a study on biopsies from human jaws. *Clin Oral Implants Res* 2008; 19(10): 1016-26.
43. Pjetursson BE, Karoussis I, Burgin W, Bragger U, Lang NP. Patients' satisfaction following implant therapy. A 10-year prospective cohort study. *Clin Oral Implants Res* 2005; 16(2): 185-93.
44. Sadeghi R, Rokn AR, Miremadi A. Comparison of Implant Stability Using Resonance Frequency Analysis: Osteotome Versus Conventional Drilling. *J Dent (Tehran)* 2015; 12(9): 647-54.
45. Heinemann F, Hasan I, Bourauec L, Biffar R, Mundt T. Bone stability around dental implants: Treatment related factors. *Ann Anat* 2015; 199: 3-8.
46. Fahd A, Abd-El Ghaffar Y, El-Shenawy H, Khalifa M, Dahaba M. Bone Changes in dental implant combined with laser therapy: a split mouth study. <http://www.sciencepub.net/researcher>. 2017; (7)(9): 68-74.
47. Naser AZ, Etemadi S, Rismanchian M, Sheikh M, Tavakoli M. Comparison of conventional and standardized bone densitometry around implants in periapical radiographs during a three months period. *Dent Res J (Isfahan)* 2011; 8(1): 33-8.
48. Wakoh M, Harada T, Otonari T, Otonari-Yamamoto M, Ohkubo M, Kousuge Y, Kobayashi N, Mizuta S, Kitagawa H., Sano T. Reliability of linear distance measurement for dental implant length with standardized periapical radiographs. *Bull Tokyo Dent Coll* 2006; 47(3): 105-15.
49. Wood MR, Vermilyea SG. A review of selected dental literature on evidence-based treatment planning for dental implants: report of the Committee on Research in Fixed Prosthodontics of the Academy of Fixed Prosthodontics. *J Prosthet Dent* 2004;92(5):447-62.
50. Deeb G, Antonos L, Tack S, Carrico C, Laskin D, Deeb JG. Is cone-beam computed tomography always necessary for dental implant placement? *J Oral Maxillofac Surg* 2017; 75(2): 285-289.
51. Kan JY, Rungcharassaeng K, Lozada J. Immediate placement and provisionalization of maxillary anterior single implants: 1-year prospective study. *Int J Oral Maxillofac Implants* 2003a; 18(1): 31-9.
52. Berberi AN, Noujeim ZN, Kanj WH, Mearawi RJ, Salameh ZA. Immediate placement and loading of maxillary single-tooth implants: a 3-year prospective study of marginal bone level. *J Contemp Dent Pract* 2014; 15(2): 202-8.
53. Herrero-Climent M, Albertini M, Rios-Santos JV, Lazaro-Calvo P, Fernandez-Palacin A, Bullon P. Resonance frequency analysis-reliability in third generation instruments: Osstell mentor(R), *Med Oral Patol Oral Cir Bucal* 2012; 17(5): e801-6.
54. Chappuis V, Enge, O, Reyes M, Shahim K, Nolte LP, Buser D. Ridge alterations post-extraction in the esthetic zone: a 3D analysis with CBCT. *J Dent Res* 2013; 92(12 Suppl): 195s-201s.
55. Araujo MG, Silva CO, Misawa M, Sukekava F. Alveolar socket healing: what

- can we learn?'. *Periodontol* 2000 2015; 68(1): 122-34.
56. Chappuis V, Araujo MG, Buser D. Clinical relevance of dimensional bone and soft tissue alterations post-extraction in esthetic sites. *Periodontol* 2000 2017; 73(1): 73-83.
 57. Araujo MG, Linder E, Lindhe J. Bio-Oss collagen in the buccal gap at immediate implants: a 6-month study in the dog. *Clin Oral Implants Res* 2011;22(1): 1-8.
 58. Caneva M, Botticelli D, Pantani F, Baffone GM, Rangel IG Jr, Lang NP. Deproteinized bovine bone mineral in marginal defects at implants installed immediately into extraction sockets: an experimental study in dogs. *Clin Oral Implants Res* 2012; 23(1):106-12.
 59. Greenstein G, Cavallaro J. Managing the buccal gap and plate of bone: immediate dental implant placement. *Dent Today* 2013;32(3):70, 72-7; quiz 78-9.
 60. Sanz M, Lindhe J, Alcaraz J, Sanz-Sanchez I, Cecchinato D. The effect of placing a bone replacement graft in the gap at immediately placed implants: a randomized clinical trial'. *Clin Oral Implants Res* 2017; 28(8): 902-910.
 61. Favero, G., Botticelli, D., Garcia, B., Mainetti, T. and Lang, N. P. (2013) 'Alveolar bony crest preservation at implants installed immediately after tooth extraction: an experimental study in the dog', *Clin Oral Implants Res*, 24(1), pp. 7-12.
 62. Lee CT, Chiu TS, Chuang SK, Tarnow D, Stoupe J. Alterations of the bone dimension following immediate implant placement into extraction socket: systematic review and meta-analysis. *J Clin Periodontol* 2014; 41(9): 914-26.
 63. Spinato S, Agnini A, Chiesi M, Agnini AM, Wang HL Comparison between graft and no-graft in an immediate placed and immediate nonfunctional loaded implant. *Implant Dent* 2012; 21(2): 97-103.
 64. Chu SJ, Salama MA, Salama H, Garber DA, Saito H, Sarnachiaro GO, Tarnow DP. The dual-zone therapeutic concept of managing immediate implant placement and provisional restoration in anterior extraction sockets. *Compend Contin Educ Dent* 2012;33(7): 524-32, 534.
 65. Hunt DR, Jovanovic SA. Autogenous bone harvesting: a chin graft technique for particulate and monocortical bone blocks. *Int J Periodontics Restorative Dent* 1999;19(2): 165-73.
 66. Cornellini R, Cangini F, Martuscelli G, Wennstrom J. Deproteinized bovine bone and biodegradable barrier membranes to support healing following immediate placement of transmucosal implants: a short-term controlled clinical trial. *Int J Periodontics Restorative Dent* 2004; 24(6): 555-63.
 67. Qian J, Wennerberg A, Albrektsson T. Reasons for marginal bone loss around oral implants. *Clin Implant Dent Relat Res* 2012;14(6): 792-807.
 68. Sakka S, Baroudi K, Nassani MZ. Factors associated with early and late failure of dental implants. *J Investig Clin Dent* 2012; 3(4): 258-61.
 69. Quesada-Garcia MP, Prados-Sanchez E, Olmedo-Gaya MV, Munoz-Soto E, Gonzalez-Rodriguez MP, Valllecillo-Capilla M. Measurement of dental implant stability by resonance frequency analysis: a review of the literature. *Med Oral Patol Oral Cir Bucal* 2009; 14(10): e538-46.
 70. Buyukguclu G, Ozkurt-Kayahan Z, Kazazoglu E. Reliability of the Osstell Implant Stability Quotient and Penguin Resonance Frequency Analysis to evaluate implant stability. *Implant Dent* 2018 Aug;27(4):429-433.
 71. Vanden Bogaerde L, Rangert B, Wendelhag I. Immediate/early function of Branemark System TiUnite implants in fresh extraction sockets in maxillae and posterior mandibles: an 18-month prospective clinical study. *Clin Implant Dent Relat Res* 2005; 7 Suppl 1: S121-30.
 72. Villa R, Rangert B. Early loading of interforaminal implants immediately installed after extraction of teeth presenting endodontic and periodontal lesions. *Clin Implant Dent Relat Res* 2005; 7 Suppl 1: S28-35.
 73. Crespi R, Cappare P, Gherlone E, Romanos GE. Immediate occlusal loading of implants placed in fresh sockets after tooth extraction. *Int J Oral Maxillofac Implants* 2007; 22(6): 955-62.
 74. Lindeboom JA, Tjiook Y, Kroon FH. 'Immediate placement of implants in periapical infected sites: a prospective randomized study in 50 patients. *Oral Surg Oral Med Oral Pathol Oral Radiol Endod* 2006; 101(6): 705-10.
 75. Ganeles J, Norkin FJ, Zfaz S. Single-tooth implant restorations in fresh extraction sockets of the maxillary esthetic zone: two-year results of a prospective cohort study., *Int J Periodontics Restorative Dent* 2017; 37(2): e154-e162.
 76. Antunes AA, Oliveira Neto P, de Santis E, Caneva M, Botticelli D, Salata LA. Comparisons between Bio-Oss[®] and Straumann[®] Bone Ceramic in immediate and staged implant placement in dogs mandible bone defects. *Clin Oral Implants Res* 2013;24(2): 135-42.
 77. Vanden Bogaerde L, Sennerby L. A randomized case-series study comparing the stability of implant with two different surfaces placed in fresh extraction sockets and immediately loaded. *Int J Dent* 2016: 8424931.
 78. Chen ST, Darby IB, Reynolds EC. A prospective clinical study of non-submerged immediate implants: clinical outcomes and esthetic results. *Clin Oral Implants Res* 2007;18(5): 552-62.
 79. Noelken R, Moergel M, Kunkel M, Wagner W. Immediate and flapless implant insertion and provisionalization using autogenous bone grafts in the esthetic zone: 5-year results. *Clin Oral Implants Res* 2018; 29(3): 320-327.