Journal of Equine Veterinary Science 93 (2020) 103217

Contents lists available at ScienceDirect

Journal of Equine Veterinary Science

journal homepage: www.j-evs.com

Case Report

Congenital Osteoma of the Frontal Bone in an Arabian Filly

Ashraf M. Abu-Seida*, Ashraf A. Shamaa

Department of Surgery, Anesthesiology and Radiology, Faculty of Veterinary Medicine, Cairo University, Giza, Egypt

ARTICLE INFO

Article history:
Received 11 June 2020
Received in revised form
29 July 2020
Accepted 3 August 2020
Available online 7 August 2020

Keywords:
Bone tumor
Craniofacial tumor
Equine
Frontal bone
Osteoma

ABSTRACT

Congenital frontal osteoma has not been previously described in horses. This report records—for the first time—a congenital osteoma of the frontal bone in a 4-month-old Arabian filly. The filly had a frontal hard mass that was present at birth and then showed a slow and continuous growth. This mass appeared as a solitary, painless, oval dense tumor of compact bone, about 2 cm in diameter and 3 cm in length. The tumor was asymptomatic, and the skin over the mass was normal. Radiography revealed a well-defined oval, radio-dense mass projecting from the surface of the right frontal bone with no local invasion. The tumor had a broad-based attachment to frontal bone with normal frontal sinus. The mass caused disfigurement; therefore, it was removed at the owner's request. The mass was diagnosed histopathologically as osteoma. The surgical excision of the osteoma was successful without any complications, and the filly adapted remarkably well after surgery. No recurrence was reported 20 months after the surgery. In conclusion, osteoma should be listed during the differential diagnosis of the congenital craniofacial masses in horses. Early diagnosis of the frontal osteoma guarantees a successful surgical treatment and consequently prevents the future complications.

© 2020 Elsevier Inc. All rights reserved.

1. Introduction

Osteoma is a rare benign bone neoplasm in most animal species, whereas it is more often recorded in equine and bovine [1]. Most of the recorded osteomas in equine have been found in the paranasal sinuses and nasal cavity [1–7]. Craniofacial osteomas are usually asymptomatic; however, the large-sized osteomas may cause mass effect-type signs depending on their location [2,5,6]. Clinical signs associated with the craniofacial osteomas depend mainly on the size and location of the tumor including respiratory dyspnea, facial distortion, torticollis, nasal discharge, headshaking, epistaxis, and exophthalmia [1–7]. In addition, osteomas have been recorded at the thoracic spinous processes of a horse causing pain, atrophy of the thoracolumbar muscles, and symmetrical prominence of the tuber sacrale [8].

No age, sex, or breed predilections of osteoma have been recorded in horses probably due to the limited availability of reports describing osteomas in horses [8]. But most of the recorded osteomas have been found in adult male horses (3–15 years old) [5–8].

Diagnosis and extent of osteomas are based on clinical examination, radiography, ultrasonography, excisional biopsy, histopathology, and computed tomography [2–4,8].

This case report describes a novel congenital frontal osteoma in a 4-month-old Arabian filly that has not been previously recorded.

2. Case Presentation

A 4-month-old Arabian filly with a congenital right frontal mass was admitted to the surgery clinic at Faculty of Veterinary Medicine, Cairo University, Egypt. The filly had a 4-month history of a frontal mass that showed slow growth. At birth, the tumor appeared as a small hard swelling (0.5 × 0.5 cm^2) with intact normal skin.

On presentation, the filly appeared bright, alert, and responsive. All clinical values were within normal limits. The heart and respiratory rates of the filly were 70 beats/min and 30 breaths/min, respectively. Body temperature of the filly was 38°C. The mucous

Animal welfare/ethical statement: All international and institutional guidelines for animal use and care were followed up. Both authors approved the writing and submission of this article. This article is not published elsewhere before in any form.

Conflict of interest statement: The authors declare that they have no known competing financial interests or personal relationships that could have appeared to influence the work reported in this article.

* Corresponding author at: Ashraf M. Abu-Seida, Department of Surgery, Anesthesiology & Radiology, Faculty of Veterinary Medicine, Cairo University, Giza - Giza Square, Egypt 12211.

E-mail addresses: ashrafseida@cu.edu.eg, ashrafseida@yahoo.com (A.M. Abu-Seida).

https://doi.org/10.1016/j.jevs.2020.103217
0737-0806/© 2020 Elsevier Inc. All rights reserved.



Fig. 1. A photograph of a 4-month-old Arabian filly showing a right well-defined oval frontal osteoma.

membrane was pink and moist, and the capillary refill time was less than 2 s. The body weight of the filly was 80 kg.

On palpation of the frontal mass, a solitary, 2 × 3 cm^2 oval, painless, well-defined dense mass of compact bone was found. The mass was projecting from the surface of the right frontal bone and the skin over the mass was intact without any discoloration or alopecia (Fig. 1).

Lateral radiography revealed a well-defined, oval radio-dense, osseous mass that was not locally invasive. The mass showed a broad-based attachment to the right frontal bone with normal frontal sinus (Fig. 2).

Based on the case history, clinical examination, and radiography, the mass was diagnosed as a congenital osseous mass. The mass caused disfigurement; therefore, it was excised at the owner's request.

Surgical removal of the osteoma was carried out in the standing position under sedation and local infiltration analgesia. The filly was sedated with an intramuscular injection of Xylazine HCl 2%

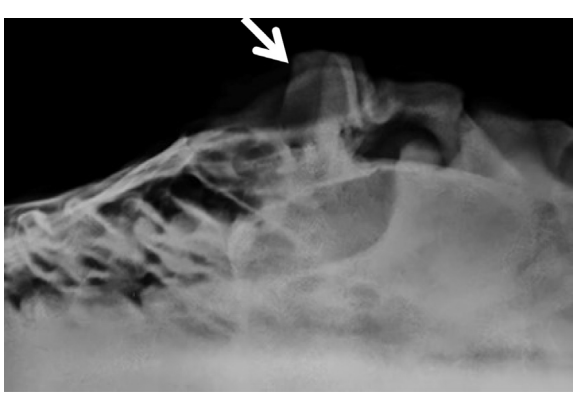

Fig. 2. Lateral radiograph of the skull demonstrating a well-defined radio-dense osseous mass (arrow) over the frontal bone.

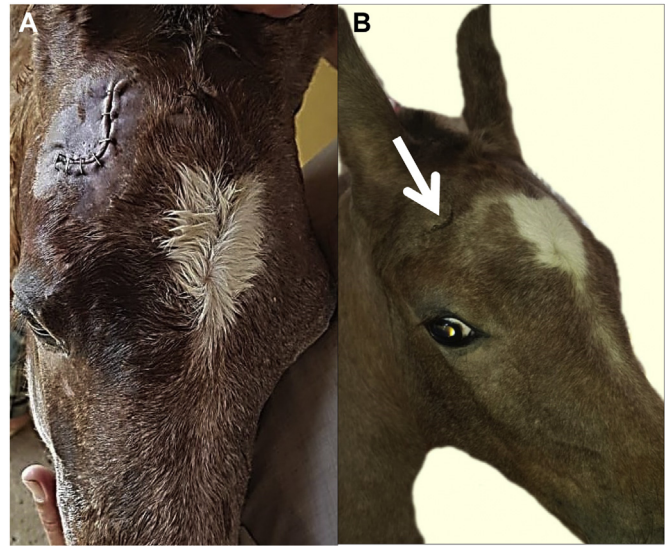

Fig. 3. (A) A photograph of a 4-month-old Arabian filly after surgical resection of the right frontal osteoma showing the skin sutures. (B) A photograph of the same animal after 20 months of surgery showing scar tissue at the surgical site with no recurrence.

(Xylaject, ADWIA, Egypt) at a dose of 1 mg/kg. The area around the frontal mass was clipped and aseptically prepared using Povidone iodine 10% solution (Povidone, Panax Pharma, PharmaCare, Egypt). The skin along the site of intended incision around the base of the mass was infiltrated with 5 mL of Lidocaine HCl 2% solution (Lidocaine, Hospira Co, Lake Forest, IL). A semicircular skin incision was carried out around the base of the osseous mass. Then the skin over the mass was bluntly dissected to make a skin flap. The osseous mass was resected from the frontal bone by oscillating saw (FMM 350 Q MultiMaster Oscillating tool, Fein, Germany). Careful observation of the position and orientation of the saw was considered, to avoid opening of the frontal sinus. The sawed area was smoothed by a carbide rasp (FMM 350 Q MultiMaster Oscillating tool, Fein, Germany). Intraoperative radiography was undertaken to confirm the complete excision of the osseous mass. The surgical area was washed with 100 mL compound sodium lactate solution [8], then the excess of the skin flap was cut. The skin was closed by a sterile disposable skin stapler (United Company for Biological Industries, Egypt) (Fig. 3A). The timing of surgery was 20 min.

The filly was given 1,500 IU of antitetanic serum (Tetanus-antitoxin, Pasteur Lab., Egypt) by subcutaneous injection. Penicillin–streptomycin combination (Penstrep, Pharma Swede, Egypt) was given by IM once daily at a dose of 10,000 IU penicillin/kg, 6.2 mg of streptomycin/kg, and 6.25 mg of dihydrostreptomycin/kg for 5 postoperative days. Phenylbutazone (Phenylbutazone 20% injection, Aspen co, Durban, South Africa) was administered intravenously at a dose of 2.2 mg/kg once daily for 3 successive days for pain control. The skin wound was dressed by Povidone-iodine antiseptic solution 3 times for 10 days. The skin sutures were removed 10 days postoperative by a sterile disposable staple remover (United Company for Biological Industries, Egypt).

The animal was followed up for 20 months and neither recurrence nor complications were recorded (Fig. 3B).

On sectioning, the mass was 2 cm in diameter and 3 cm in length. The osseous tissue within the excised mass had a mixture of trabecular and compact bones. Specimens from the excised osseous mass were collected and fixed in 10% formalin solution for 14 days, then decalcified in 17% EDTA solution for 100 days. The specimens were prepared as usual for histopathology and stained by hematoxylin and eosin for histopathological evaluation.

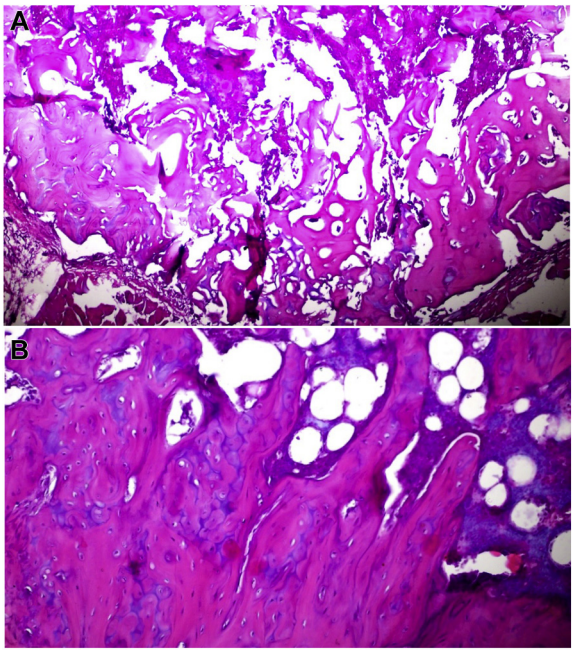

Fig. 4. (A) A photomicrograph of the excised osteoma showing a marked osteogenic activity with new lamellar bone formation (H&E ×100). (B) A photomicrograph of the osteoma section showing compact lamellar bone formation (H&E ×200).

Histopathological evaluation of the tissue excised showed a marked osteogenic activity characterized by high number of active osteoblasts with large nucleus and abundant cytoplasm. Few scattered osteoclasts were observed. Formation of irregular bone trabeculae surrounded by lamellar bone sheets was also seen with the absence of fibrous tissues or Haversian system (Fig. 4). These bony sections had an irregular anastomosis and showed different degrees of mineralization. The signs of neoplastic activity or inflammatory infiltration were absent. Based on these histopathological features, the mass was confirmed as an osteoma.

3. Discussion

An osteoma is a slow-growing benign bone-forming tumor that is consisted of mature bone similar to normal compact and/or trabecular bone but its bone is dense with little marrow [8–10]. The osteoma is often reported in equine and its congenital form has not been recorded in the available veterinary literature [11]. Moreover, most of the osteomas are reported in the paranasal sinuses of horses [1–3]. Therefore, this is the first record describing a case of congenital frontal osteoma in horses.

There are several proposed causes of osteomas in horses, such as infection, trauma, and idiopathic overgrowth of the bone [8]. In the present case, the osteoma was found at birth; hence, it is considered as a congenital disorder. Also, most of the recorded osteomas are developed in adult horses [1–8]. In contrast, the osteoma reported here had a congenital origin. In addition, in contrast to previous studies [1,2,7,8] that found that osteomas are predominantly found in male horses, the gender of the reported foal here is a female.

The filly was well with normal clinical values. This means that the recorded osteoma here had no adverse effects at this young age of the animal but it caused unsightly appearance. This unsightly appearance was the main owner's complaint. Therefore, the owner admitted his filly to the surgery clinic for a cosmetic purpose. In contrast, several complications have been associated with the craniofacial osteomas, depending on their anatomical location, size, and pattern of growth [1–8,12]. This difference could be attributed to the young age of the filly that did not allow the abnormal pressure of osteoma on the surrounding tissues or local invasion of the osteoma into the frontal sinus; therefore, no complications were recorded.

Computed tomography and magnetic resonance imaging are the gold standard diagnostic tools to investigate the skull and paranasal masses [2]. The main limitation of this case report was unavailability of these tools. Therefore, radiography was used during diagnosis and treatment of the osteoma recorded here. Radiography helped us to exclude the local invasion of the osteoma into the surrounding tissues and to plan the surgical removal of the tumor without opening of the frontal sinus. Similar importance of radiography was mentioned in previously recorded osteomas in horses [1,2,8].

Differential diagnosis of the frontal osteoma includes osteosarcoma, ossifying fibroma, fibrous dysplasia, heterotopic ossification, and exostosis [4,10,11]. Case history, clinical signs, radiography, and histopathology are enough to differentiate these tumors.

In this case, surgery was carried out in the standing position and sedation to avoid any potential risk of the general anesthesia at this young age (4 months).

The surgical site was thoroughly washed with 100 mL compound sodium lactate solution to remove any fine bony spicules resulted from sawing of the osteoma. These spicules could delay the wound healing. Similar intraoperative washing was performed in a previous study [8].

Metastases of the osteomas have rarely been reported [7,13–15]. No metastases or recurrence were recorded in the present case during 20 months after the surgery.

Histopathology was essential for a definite diagnosis of the osteoma reported here. We preferred the excisional biopsy to save the time and extra cost and to avoid the potential complications of the other types of biopsies. Histologically, osteomas consisted of a central cancellous bone and a peripheral dense compact bone [8,13]. The proportions of cancellous and compact bones depend on the rate of osteoma's growth [8,13]. In addition, Haversian canal systems can be identified as the osteoma remodels [13], but this was not the case in the reported osteoma here because of its early development.

4. Conclusion

In conclusion, osteoma should be listed during differential diagnosis of the congenital craniofacial masses in the horses. Early diagnosis of the frontal osteoma guarantees successful surgical treatment and consequently prevents the future complications. Surgical resection of osteoma seems to be a successful and radical treatment in our case.

References

[1] Schumacher J, Smith BL, Morgan SJ. Osteoma of paranasal sinuses of a horse. J Am Vet Med Assoc 1988;10:1449–50.
[2] Baptiste KE. Paranasal sinus osteoma in an American Miniature Horse: computed tomographic evaluation and surgical management. Equine Pract 1996;9:14–9.
[3] Scotty NC, Ford M, Williams F, Loiacono C, Johnson PJ, Messer NT, et al. Exophthalmia associated with paranasal sinus osteoma in a Quarter-horse mare. J Vet Diagn Invest 2004;2:155–60.
[4] Puff C, Ohnesorge B, Wagels R, Baum-gartner W. An unusual mucinous osteoma with features of an ossifying fibroma in the nasal cavity of a horse. J Comp Pathol 2006;1:52–5.
[5] Cilliersa I, Williams J, Carstens A, Duncan NM. Three cases of osteoma and an osseous fibroma of the paranasal sinuses of horses in South Africa. J S Afr Vet Assoc 2008;79:185–93.

[6] Scutchfield WL, Schumacher J, Walker M, Crabill M. Removal of an osteoma from the paranasal sinuses of a standing horse. Equine Pract 1994;9:24–8.
[7] Steinman A, Sutton GA, Lichawski D, Johnston DE. Osteoma of paranasal sinuses in a horse with inspiratory dyspnoea. Aust Vet J 2002;3:140–2.
[8] Owen KR, Foote AK, Hinnigan GJ. Surgical resection of an osteoma of two thoracic spinous processes in a horse. Equine Vet Educ 2019;3:28–33.
[9] Goetsch GD. Homoplastic osteoma of frontal bone of mule. Vet Med 1946;41:142.
[10] Schooley EK, Hendrickson DA. Musculoskeletal system neoplasia. Vet Clin N Am Equine Pract 1998;14:535–42.
[11] Thompson KG, Pool RR. Tumors of bone. In: Meuten DJ, editor. Tumors in domestic animals. USA: Wiley; 2002. Chapter 5.
[12] Ragle CA, de Mira MC, Pearson LK, Coelho JC. Pneumocephalus secondary to removal of an osteoma from the paranasal sinuses of a horse. J Am Vet Med Assoc 2009;235:184–8.
[13] Head W, Dixon PM. Equine nasal and paranasal sinus tumours. Part 1: review of the literature and tumour classification. Vet J 1999;157:261–79.
[14] Robbins SC, Arighi M, Ottewell G. The use of megavoltage radiation to treat juvenile mandibular ossifying fibroma in a horse. Can Vet J 1996;11:683–4.
[15] McGlinchey L, Cole R, Caldwell FJ. Reoccurrence of a paranasal osteoma following surgical removal in a 6-month-old Warmblood filly. Equine Vet Educ 2019. https://doi.org/10.1111/eve.13055. In press.