

Case report

UDK 636.8:618.2

<https://doi.org/10.46784/e-avm.v16i2.329>

ECTOPIC PRIMARY ABDOMINAL PREGNANCY IN A PERSIAN CAT

Ashraf M. Abu-Seida^{1*}

¹ Department of Surgery, Anesthesiology and Radiology, Faculty
of Veterinary Medicine, Cairo University, Giza, Egypt

Abstract

Ectopic pregnancies are common in human medicine, while they are rarely recorded in animals. This report describes a case of 2.5-year-old ectopic primary abdominal pregnancy in a 7-year-old Persian cat. The cat was admitted to the surgery clinic for routine ovariohysterectomy with no characteristic clinical symptoms. During surgery, ovaries, uterus and ligaments were normal, like in a non-pregnant cat. Four intra-abdominal fetuses of different developmental stages were found and carefully removed. Three fetuses were found free in the abdomen inside their gestational sacs. The fourth fetus was covered with omentum and had no gestational sac. The gestational sacs had different sizes (2-8 cm in diameter). Two of the fetuses were fully-haired with normal position of limbs. No complications were recorded during the surgery and 10 months post-operative. This case report adds to the database of ectopic pregnancies in cats and further illustrates their incidental nature.

Key words: Abdominal pregnancy, cat, ectopic pregnancy, fetuses, ovariohysterectomy.

^{1*} Corresponding Author: ashrafseida@cu.edu.eg

VANMATERIČNI PRIMARNI ABDOMINALNI GRAVIDITET KOD PERSIJSKE MAČKE

Ashraf M. Abu-Seida¹

¹Departman za hirurgiju, anesteziologiju i radiologiju, Fakultet veterinarske Medicine, Univerzitet Kairo, Giza, Egipat

Kratak sadržaj

Vanmaterične trudnoće su česte u humanoj medicini, dok se retko beleže kod životinja. Ovaj izveštaj opisuje slučaj 2,5-godišnjeg vanmateričnog primarnog abdominalnog graviditeta kod 7-godišnje persijske mačke. Mačka je primljena na Kliniku za hirurgiju radi rutinske ovariohisterektomije bez karakterističnih kliničkih simptoma. Tokom operacije jajnici, maternica i ligamenti bili su normalni, kao kod mačke koja nije gravidna. Pronađena su i pažljivo izvađena četiri intraabdominalna fetusa različitih razvojnih stadijuma. Tri fetusa pronadena su slobodna u abdomenu unutar svojih gestacijskih vrećica. Četvrti fetus bio je prekriven omentumom i nije imao gestacijsku vreću. Gestacijske vreće bile su različite veličine (2-8 cm u promeru). Dva fetusa su bila sa potpuno formiranim dlačnim pokrivačem s normalnim položajem udova. Tokom operacije i 10 meseci nakon operacije nisu zabeležene komplikacije. Ovaj prikaz slučaja predstavlja dodatni podatak za bazu podataka o vanmateričnom graviditetu kod mačaka i dodatno ilustruje njihovu slučajnu prirodu.

Cljučne reči: Abdominalni graviditet, mačka, vanmaterični graviditet, fetusi, ovariohisterektomija

INTRODUCTION

Ectopic pregnancy refers to a pregnancy occurring outside of the cavity of the uterus. While this disorder is common in humans, it is rarely recorded in animals (Vidiastuti et al., 2022). Ectopic pregnancies are classified according to the site of implantation and they can be abdominal and tubal pregnancies. The etiology and pathogenesis of ectopic pregnancy are not always clearly defined (Chong, 2017; Zheng et al., 2018; Jiasan et al., 2019).

Abdominal pregnancies are also subdivided into primary and secondary

forms. The primary form occurs when fertilized oocytes are released into the abdomen and implanted on the abdomen (Osenko and Tarello, 2014; Zheng et al., 2018; Vidiastuti et al., 2022). Secondary form occurs when a pregnant uterus is ruptured due to trauma or wounds and the fetuses are released into the abdominal cavity where they continue their development (Tirgari, 1986; Findik et al., 1998; Ivanova et al., 2019). Differentiation between primary and secondary extra-uterine pregnancies is controversial due to the presence of an intact (Dzięcioł et al., 2012), altered (Kumru et al., 2007) or partially missing reproductive system (Johnston et al., 1983). Consequently, the absence of signs of uterine rupture is one of the most important inclusion criteria for the diagnosis of primary extra-uterine pregnancies in cats (Osenko and Tarello, 2014).

Diagnosis of ectopic pregnancy is based mainly using X-ray (Johnston et al., 1983; Osenko and Tarello, 2014; Mirsepehr et al., 2015), ultrasound (Findik et al., 1998; Mirsepehr et al., 2015; Vidiastuti et al., 2022) and exploratory laparotomy (Bodle, 1979; Tirgari, 1986). Nevertheless, several cases of ectopic pregnancies were recorded in cats as an accidental finding during routine clinical examination or radiography (Mirsepehr et al., 2015; Chong, 2017; Ivanova et al., 2019). Moreover, the histological examination of the ectopic fetuses did not definitively prove their extra-uterine development (Rosset et al., 2011).

Death of the abdominal fetuses is a typical outcome of recorded ectopic pregnancies in cats due to insufficient nutrition resulting from a lack of adequate blood supply inside the abdomen (Mirsepehr et al., 2015; Chong, 2017; Zheng et al., 2018). Therefore, laparotomy, removal of the ectopic fetuses and ovariohysterectomy are usually performed for treatment and prevention of recurrence of ectopic pregnancies in cats (Mirsepehr et al., 2015; Chong, 2017; Zheng et al., 2018; Ivanova et al., 2019). Nevertheless, spontaneous resolution of early ectopic pregnancies may occur, suggesting that many diagnosed cases in early stages require no treatment at all (Mirsepehr et al., 2015; Chong, 2017).

Ectopic pregnancy in cats has been recorded in the veterinary literature. However, it is quite uncommon, as shown in Table 1. Therefore, this case report adds to the available database of ectopic pregnancies in cats and further explains their accidental nature.

Table 1. Types of ectopic pregnancies recorded in different breeds of cats and characters of the ectopic fetuses

Age/Breed	Type of ectopic pregnancy	Characters of the fetuses	Reference
A 3-year-old Persian cat	Primary abdominal pregnancy	One mummified fetus, 7.25 x 4.74 cm	Vidiastuti et al. (2022)
Two European shorthair cats	Secondary abdominal pregnancies	Three fetuses, 3 cm in diameter Two, 6 x 3.5 cm and 5 x 4.5 cm	Ivanova et al. (2019)
A British shorthair	Tubal pregnancy	One fetus, not identified	Jiasan et al. (2019)
Unidentified cat	Primary abdominal pregnancy	One calcified fetus, 4 cm in diameter	Zheng et al. (2018)
A British shorthair cat	Tubal pregnancy	One immature fetus, unidentified size	
A domestic, short-haired cat	Secondary abdominal pregnancy	Two fetuses, 10 cm from crown to rump	Chong (2017)
A domestic short-haired cat	Secondary abdominal pregnancy	Three fetuses, fully developed	Mirsepehr et al. (2015)
A domestic short haired spayed cat	Primary abdominal pregnancy	Three calcified fetuses, 4-5 cm in size	Osenko and Tarello (2014)
A domestic shorthair	Secondary abdominal pregnancies	Two fetuses, different stages of development	Dzięcioł et al. (2012)
Unidentified cat		One outside the uterus and one inside, 30-35 days pregnancy	
A 1.5-year-old domestic short-haired cat	Secondary abdominal pregnancies	One mummified fetus, 7 cm in length	Rosset et al. (2011)
A 2-year-old crossbreed free-roaming cat	Secondary abdominal pregnancies	One dead fetus at 55 days' gestation	Kumru et al. (2007)
Angora cat	Secondary abdominal pregnancy	One fetus, 6 x 2.5 cm	Findik et al. (1998)
A 2.5- year-old short-haired cat	Secondary abdominal pregnancy	One encapsulated fetus, 7 x 4 x 4 cm and one embedded in the omentum, 7.5 x 3 cm	Tirgari (1986)

Age/Breed	Type of ectopic pregnancy	Characters of the fetuses	Reference
A 2.5- year-old domestic short-haired cat	Secondary abdominal pregnancy	Two necrotic fetuses, 7 x 4 cm	Johnston et al. (1983)
Unidentified cat	Primary abdominal pregnancy	Three mummified fetuses, 2,3 and 6 cm in diameter	Bodle (1979)

CASE PRESENTATION

This study was approved by the ethical committee at Faculty of Veterinary Medicine, Cairo University, Egypt. The cat was treated in accordance with guidelines established by the international and institutional Animal Care and Use Committees.

A seven-year-old Persian cat was brought to the veterinary clinic for routine ovariohysterectomy. The owner adopted the cat when it was 2.5 years old from the street. The cat showed normal sings of regular estrous cycles. Detailed history of previous pregnancies could not be obtained. During the preoperative examination, two large intra-abdominal hard masses were palpated in the middle abdomen and no other abnormalities were detected. The masses were freely mobile inside the abdominal cavity.

The cat was given general anesthetic for ovariohysterectomy and exploratory laparotomy. During surgery, three freely movable encapsulated intra-abdominal masses were found and easily removed. A fourth mass covered with omentum was also removed by careful blunt dissection. The ovaries, uterus and ligaments had normal appearance without any abnormalities. Ovariohysterectomy was carried out according to a standard procedure. Prior to closing, the abdominal cavity was thoroughly examined and washed with sterile warm normal saline solution. The cat was monitored for 10 months after surgery. A successful recovery without any complications was reported.

The dimensions of the removed masses were 8 x 5 x 4 cm, 6 x 5 x 3cm, 4 x 2 x 2 cm and 1.5 x 1 x 0.5 cm as shown in Figure 1. Three of these masses were covered with calcified sacs while the fourth mass was covered with omentum and had no sac. After opening the sacs of the three masses and removal of the omental tissue from the fourth mass, four mummified and calcified fetuses were found. Two fetuses were well-developed, fully haired and had normal positions of limbs (Figure 2). One of the well-developed fetuses had a normal body, while the second one had open abdomen without viscera as shown in Figure 2.

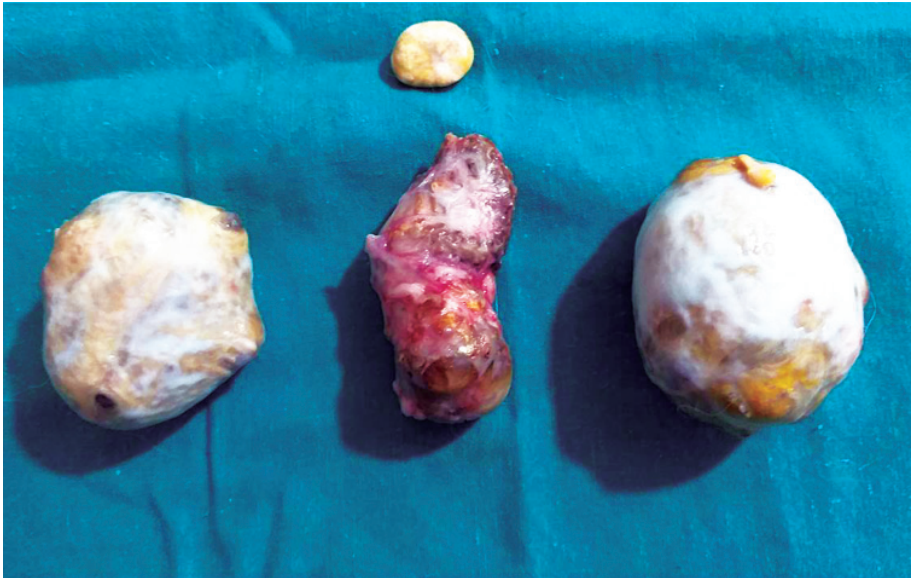


Figure 1. Four masses of different sizes were removed from the abdominal cavity of the cat. Note that three of them were encapsulated by gestational sacs and one embedded in the omentum.

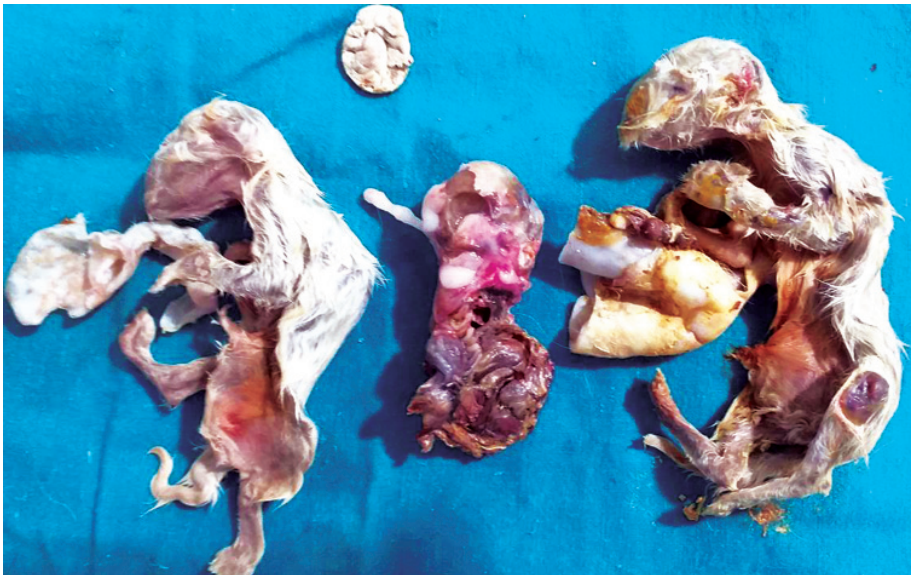

Figure 2. Four ectopic fetuses at different stages of development were identified after opening the gestational sacs and removal of the omentum.

DISCUSSION

While ectopic pregnancy is a common pathology in humans, it is still rarely recorded in veterinary literature. No detailed epidemiological studies on ectopic pregnancy have been conducted on animals, particularly cats. Cats are less likely to have ectopic pregnancy due to a difference in their endotheliochorial placentation (Zheng et al., 2018). This report describes a rare case of long-standing (> 2.5 years) ectopic primary abdominal pregnancy in a Persian cat.

Diagnosis of this case depended on the case history and findings of the clinical examination as well as laparotomy. In addition, abdominal ectopic pregnancy is truly primary when placentation presents onto a peritoneal or omental surface (Zheng et al., 2018; Vidiastuti et al., 2022), as in the current case. The differences between this case and other recorded ectopic pregnancy cases in cats are the number (N = 4) and different developmental stages of the ectopic fetuses as shown in Table 1.

Regarding the cat breed, domestic short-haired cats were the most commonly affected breed with ectopic pregnancies as shown in Table 1. However, the reported cat in this case study is a Persian cat. Similarly, a Persian cat with ectopic pregnancy was recently diagnosed by Vidiastuti et al. (2022).

Similar to the current cat, cats with ectopic pregnancy generally exhibit no clear clinical signs due to the aseptic condition of the ectopic fetuses which can remain within the animal's body for months or even years without complications (> 2.5 years). This is in agreement with the previously reported results by other authors (Dzięcioł et al., 2012; Zheng et al., 2018). Nevertheless, some cats with ectopic pregnancies, particularly secondary abdominal ectopic pregnancies, show various clinical signs such as loss of appetite, fever, vomiting, vaginal bleeding and peritonitis (Rosset et al., 2011; Dzięcioł et al., 2012; Mirsepehr et al., 2015). In other cases, particularly in primary abdominal ectopic pregnancies, cats have no clinical signs and they are detected during abdominal radiography or routine spaying as in the current case. Similar findings have been recorded before (Osenko and Tarello, 2014; Ivanova et al., 2019; Vidiastuti et al., 2022). Therefore, ectopic pregnancy may be detected as an incidental finding during clinical examination prior to ovariohysterectomy, like in the present case. The lack of associated clinical signs appears to demonstrate that such pregnancy is compatible with a normal healthy life in cats. Similar finding was confirmed by other authors (Chong, 2017; Zheng et al., 2018; Ivanova et al., 2019).

In the present case, only two of the four fetuses were palpable prior to the surgery. This could be attributed to the small size of the other two fetuses. This

finding is similar to the findings of other recorded cases of ectopic pregnancies in cats (Dzięcioł et al., 2012; Osenko and Tarello, 2014; Zheng et al., 2018; Ivanova et al., 2019). Therefore, radiography and ultrasonography examinations are useful tools for diagnosis of this problem in cats (Osenko and Tarello, 2014; Zheng et al., 2018). The main limitation in the present case report is the lack of radiography and ultrasonography examinations due to their unavailability at the time of examination.

During surgery, the uterus, ovaries and ligaments were normal in the present case. Therefore, it was diagnosed as primary abdominal pregnancy. Similar findings were recorded by other authors (Zheng et al., 2018; Ivanova et al., 2019). Unlike in these findings, ectopic abdominal fetuses secondary to trauma were observed in cats with multiple uterine abnormalities (Johnston et al., 1983; Dzięcioł et al., 2012; Chong, 2017). Moreover, Zheng et al. (2018) and Jiasan et al. (2019) diagnosed tubal ectopic pregnancy in the fallopian tubes of cats, and Osenko and Tarello (2014) recorded a case of ectopic pregnancy in a spayed cat at necropsy.

In the current case, laparotomy, removal of the ectopic fetuses and ovariohysterectomy were performed for treatment and prevention of recurrence of ectopic pregnancy. The surgeries were simple and without any early or late complications. This can be explained by the lack of attachment of the fetuses to any of the internal organs. These findings are in accordance with the findings of other authors (Mirsepehr et al., 2015; Chong, 2017; Zheng et al., 2018; Ivanova et al., 2019).

The number of extra-uterine fetuses ranged between one and three as shown in Table 1. The cat had four extra-uterine fetuses. According to the available literature, this is the largest number of extra-uterine fetuses recorded in cats to this day. In addition, the removed fetuses here were grown to different stages of development. The difference in developmental stages of the removed fetuses can be explained by the difference in the time of death of each fetus. Therefore, there was a variation in the size of the removed ectopic fetuses. Development of abdominal fetuses to advanced stages without an elaborated placentation has been recorded previously in cats (Mirsepehr et al., 2015).

According to Knospe (2002), the removed ectopic fetuses died between three and eight weeks of gestation. At 60 days of gestation, pigmentation can occur on the skin, hair, and nails, the brain and bones ossification also are present at this time. Signs of fetal mummification and calcification were observed in all ectopic fetuses. This is the common end of all recorded cases of ectopic pregnancies in cats due to malnutrition of the ectopic fetuses (Mirsepehr et al., 2015).

CONCLUSION

This is an interesting rare case of long-lasting ectopic primary abdominal pregnancy in a Persian cat. Four extra-uterine fetuses at different stages of development were present inside the abdomen for more than 2.5 years without any clinical signs or complications.

Competing interest

The author declares no conflicts of interest affecting the work reported in this paper. This research received no external funding.

REFERENCES

1. Bodle T.J. 1979. Ectopic pregnancy in a cat. *New Zealand Veterinary Journal*, 27, 279. doi:10.1080/00480169.1979.34673.
2. Chong A. 2017. A case of feline ectopic abdominal fetuses secondary to trauma. *The Canadian Veterinary Journal*, 58, 4, 400-402.
3. Dzięcioł M., Nizański W., Ochota M., Błasiak K., Kozdrowski R., Stanczyk E., Twardon J. 2012. Two separate cases of extrauterine pregnancy in queens. *Electronic Journal of Polish Agricultural Universities. Series Veterinary Medicine*, 15: 2.
4. Findik M., Vural O., Beşal T.Y., Gülbahar M. 1998. Secondary ectopic pregnancy in an Angora cat: A case report. *Ankara Üniversitesi Veteriner Fakültesi Dergisi*, 45, 239-241. doi:10.1501/Vetfak_0000000600.
5. Ivanova M., Ivanova C., Marinkov T., Georgiev P. 2019. Two cases of ectopic abdominal pregnancy in queens. *Tradition and Modernity in Veterinary Medicine*, 4, 2, 21-25. doi:10.5281/zenodo.3066338.svg.
6. Jiasan Z., Tingting Z., Zheng W., Jiaren Z. 2019. Pathological analysis of feline fallopian tubal ectopic pregnancy. *Acta Veterinaria et Zootechnica Sinica*, 50, 9, 1936-1939. doi: 10.11843/j.issn.0366-6964.2019.09.023.
7. Johnston S.D., Harish G., Stevens J.B., Scheffler H.G. 1983. Ectopic pregnancy with uterine horn encapsulation in a cat. *Journal of the American Veterinary Medical Association*, 183, 9, 1001-1002.
8. Knospe C. 2002. Periods and stages of the prenatal development of the domestic cat. *Anatomia, Histologia, Embryologia*, 31, 1, 37-51. doi: 10.1046/j.1439-0264.2002.00360.x.
9. Kumru H., Seyrek-Intas K., Tuna B., Celimli N., Seyrek-Intas D. 2007. Severe abdominal dog bite wounds in a pregnant cat. *Journal of Feline Medicine and Surgery*, 9, 6, 499-502. doi: 10.1016/j.jfms.2007.03.011.

10. Mirsepehr P., Asheghian I., Hajinasrollah M., Javadi S.R., Bashiri A.R., Esmailinejad M.R., Taghipour H., Mojtahedzade S.M. 2015. Accidental finding of ectopic pregnancy in a cat with presence of three fetuses without gestational sac that were attached to the abdominal wall and mesentery (A case report). *International Journal of Advanced Biological and Biomedical Research*, 3, 3, 217-221.
11. Osenko A., Tarello W. 2014. A 7-year-old extrauterine pregnancy in a cat. *Case Reports in Veterinary Medicine*, Article ID: 145064. doi:10.1155/2014/145064.
12. Rosset E., Galet C., Buff S. 2011. A case report of an ectopic fetus in a cat. *Journal of Feline Medicine and Surgery*, 13, 610-613. doi:10.1016/j.jfms.2011.04.003.
13. Targari M. 1986. Secondary ectopic pregnancy in a cat: a case report. *Journal of Small Animal Practice*, 27, 6, 383-385. doi:10.1111/j.1748-5827.1986.tb02152.x.
14. Vidiastuti D., Fauzi A., Noviatry A. 2022. Feline extrauterine pregnancy (EUP) in Persian cat with fetal mummification: a case study. *Journal of Experimental Biology and Agricultural Sciences*, 10, 3, 633-637. doi:10.18006/2022.10(3).633.637.
15. Zheng J.S., Wang Z., Zhang J.R., Qiu S., Wei R.Y., Nie J., Zhu T.T. 2018. Ectopic pregnancy in two cats. *Acta Scientiae Veterinariae*, 46, 5. doi:10.22456/1679-9216.85155.

Received: 25.06.2023.

Accepted: 01.10.2023.