

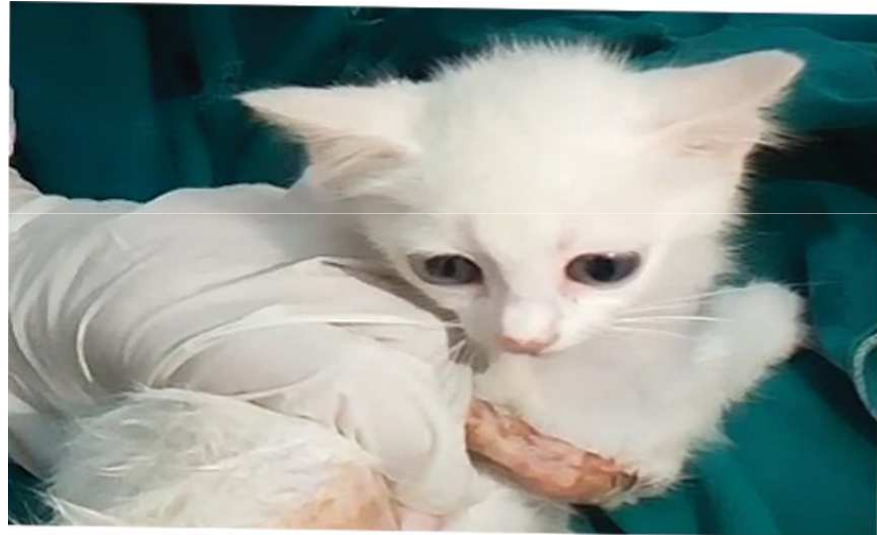

Rectal prolapse



Patient identification

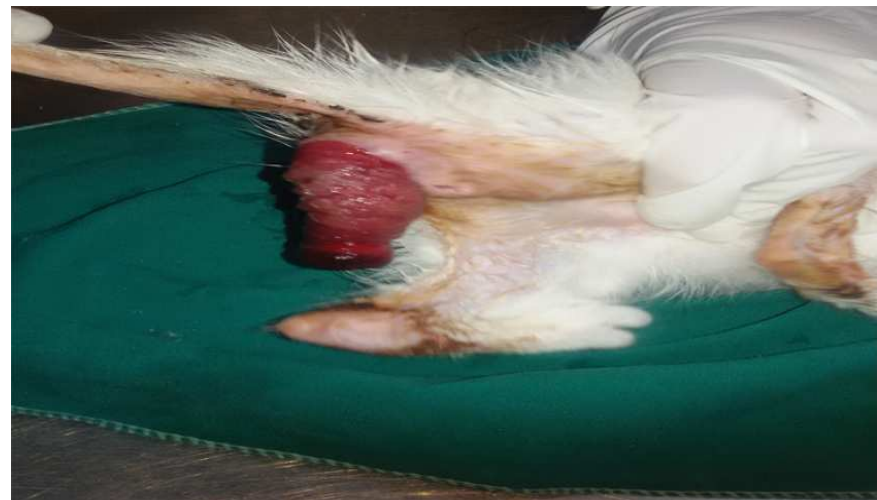
- Breed: Persian
- Age: 2 month
- Sex: Female
- Feed: Chicken liver
- cheese



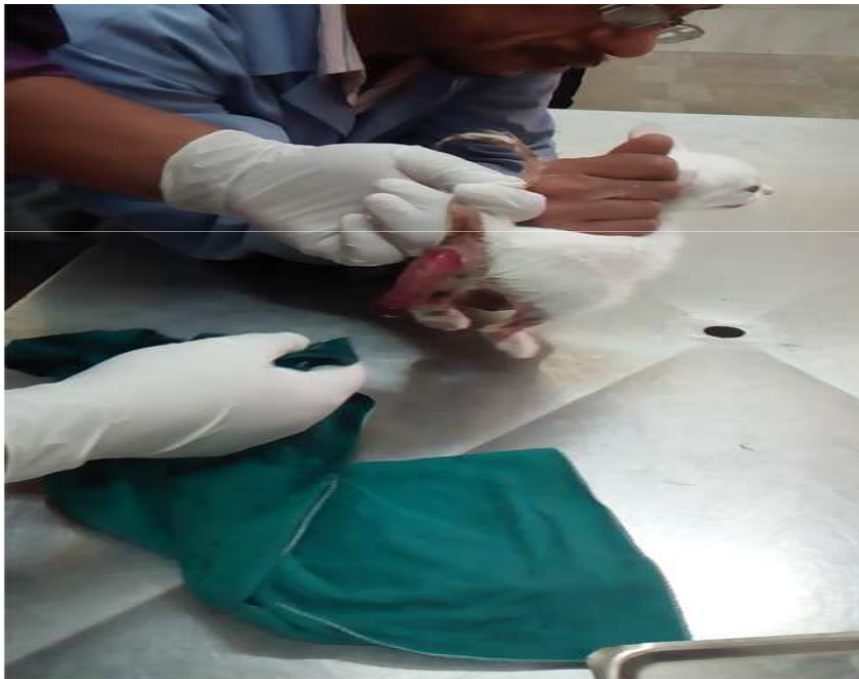Case history

- Protruded swelling (Redness & Hottness) from anal opening.
- Episode constipation and straining.
- Previously treated by kenacomb.

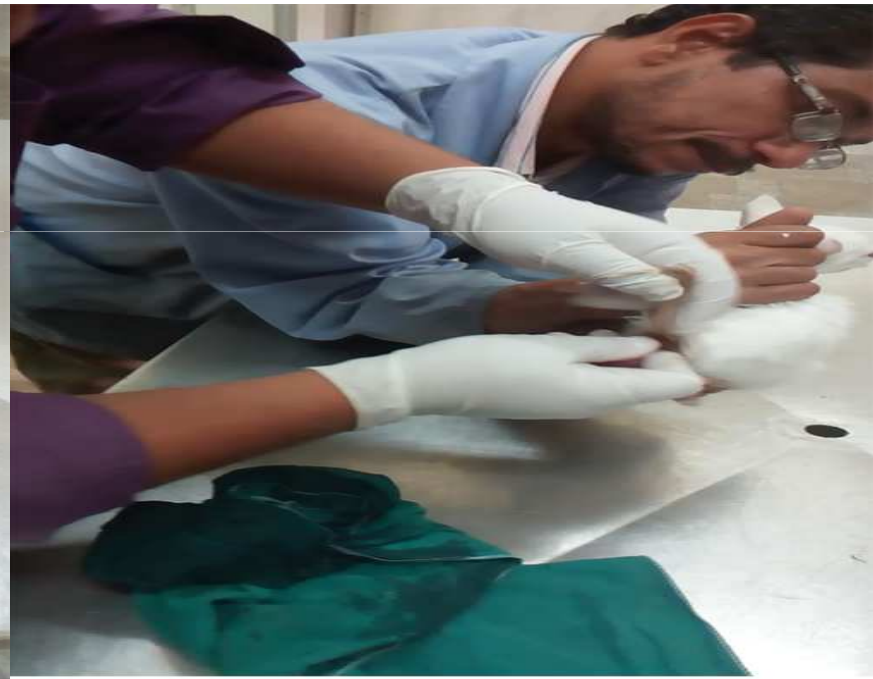- - it strains while passing stool.
- - presence of worms



Surgical treatment

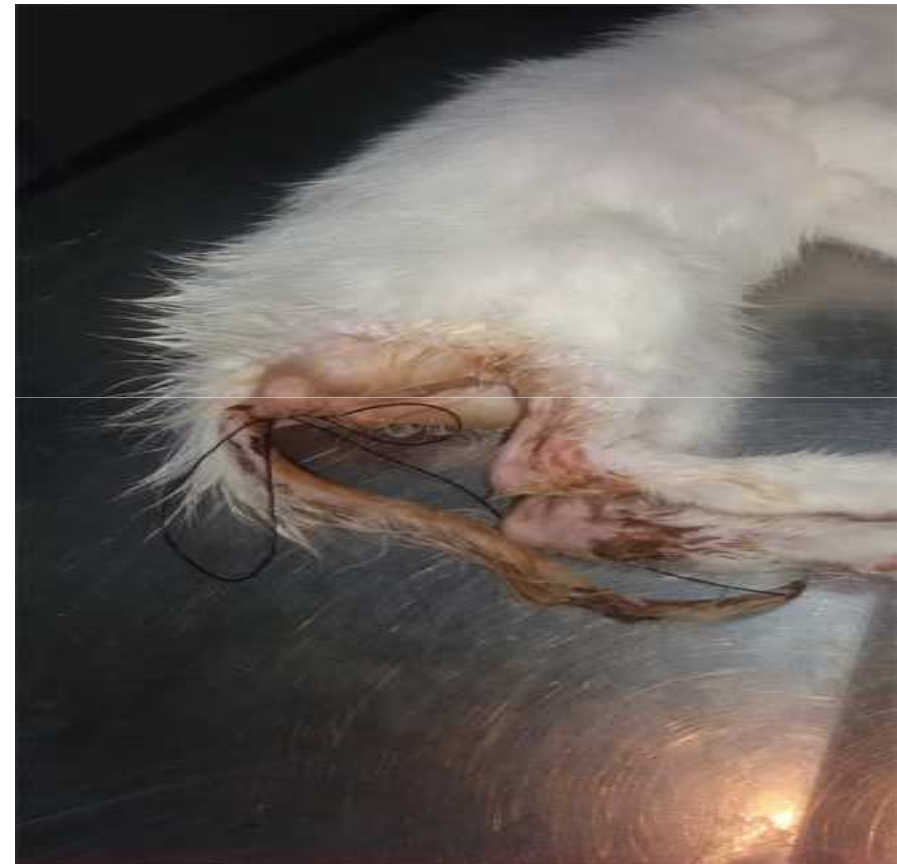
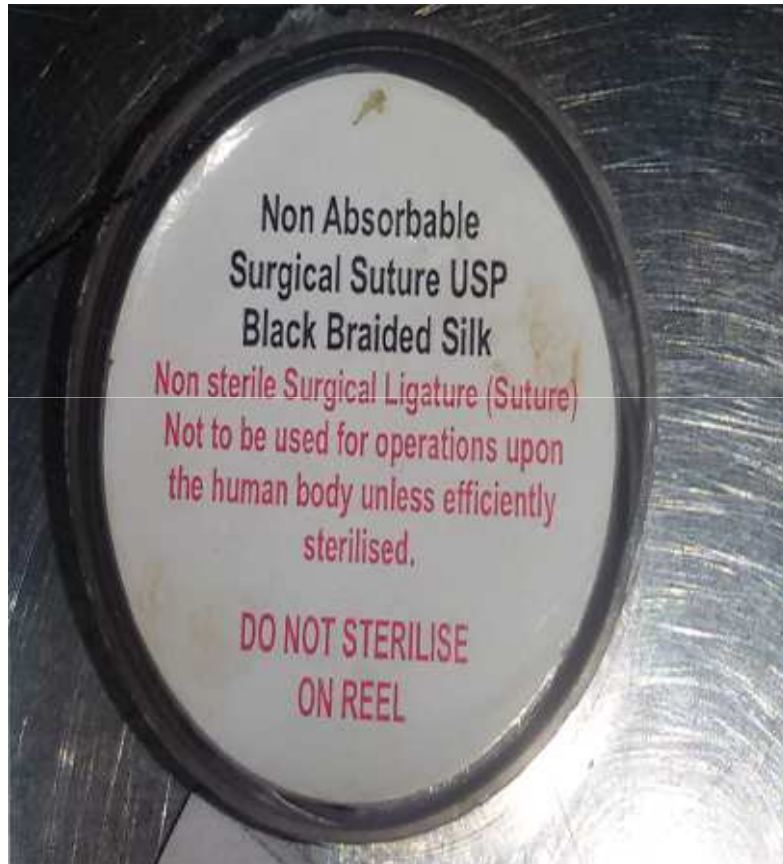
**1- Hot fomentation.
2- Anaesthesia by
ketamine**



**reduction of
prolapsed tissue
into anal opening**

Surgical treatment



Stitch by purse string suture
Stitch left loose

Therapeutic treatment

- Owner was advised to loose the suture twice daily to allow defecation.
- Suture should be kept for 1 week

- **Becozyme syrup**
2ml orally daily for 1 week
- **Flovermal syrup**
1ml orally daily for 3 day and repeat after 14 day again