

Cystic calculi

Case data :

spp : cat

breed : persian

sex : female

name : kitty

age : 1.5 year

owner name : dr. Inas shaltot

Feed : open source of dry food (“friskus” then changed to “mera cat urinary”)

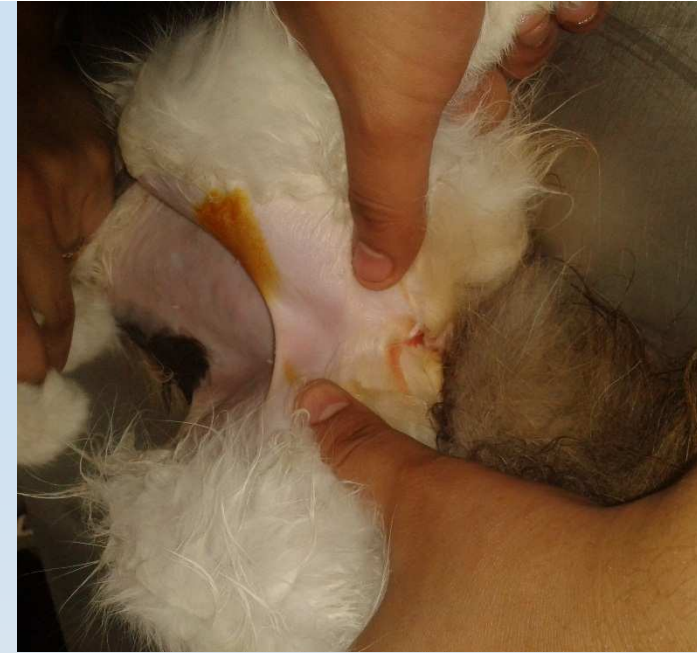+ variable meals (egg , chicken , sardine fish “the most”

N.B: the sardine contain large amount of protein and salt



Owner Complain : slight bleeding from vulva then fresh blood “bloody urine” since 2 months

Previous medication : course of antibiotics (ceftriaxone injection + ciprofloxacin tablets) , vit. K “inj. then tab.” , drugs of urolithiasis (fowatinex , proximol) but no positive results



- The owner`s first visit to the clinic of the faculty was Since 15 days ... sonar has made and dr.Faisal advised ttt with vit. K but also no results so it was necessary to make surgery

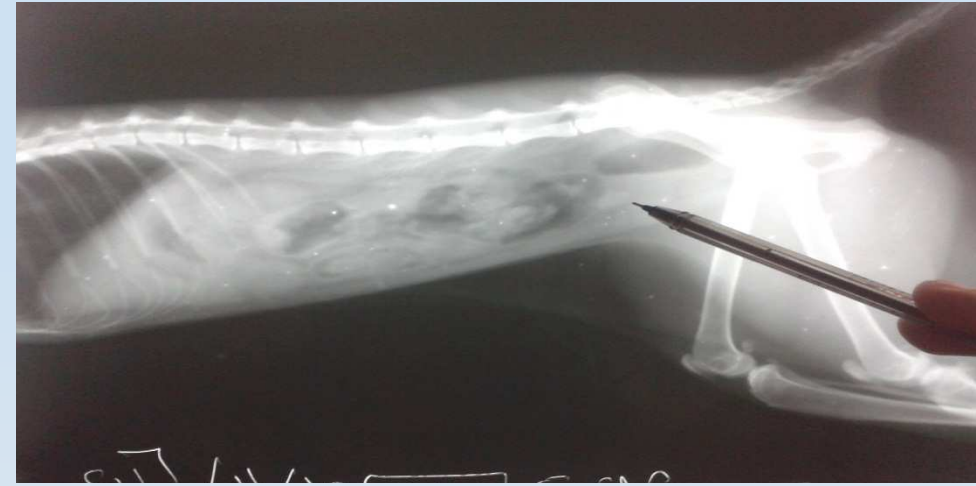I.B : the owner has 5 cats eating the same food , one of them is 13 years old not affected but this case affected and this is evidence on variability

I.B : the owner visited external clinic and the doctor diagnosed it as infection but the owner was not satisfied because she noticed that it is fresh blood "hematuria" which means the cause is obstructive

At the day of surgery 15/11/2016 ...

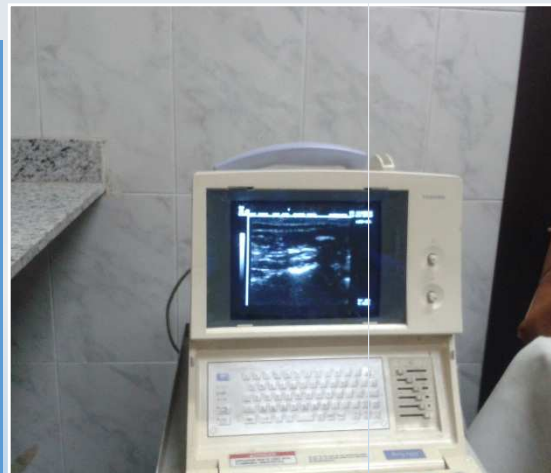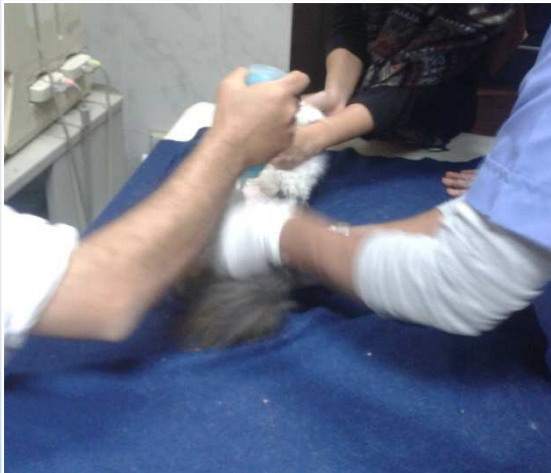X_ray :

by lateromedial position revealed radiolucent substance "stone" but was not very clear



Ultrasound :

reveal presence of white shadow of the calculi



The operation “Cystotomy”

7 hours fasting before time of surgery

Anesthesia :

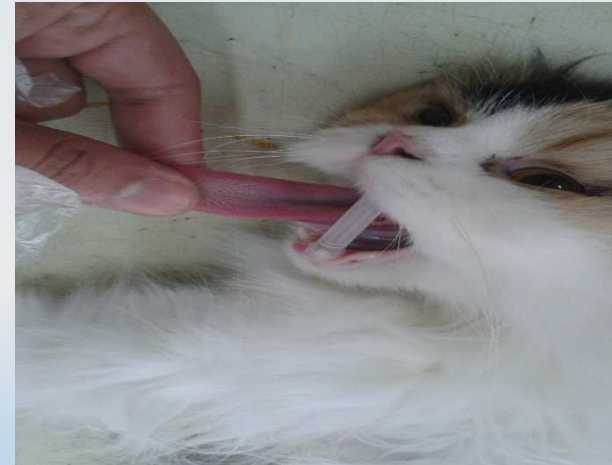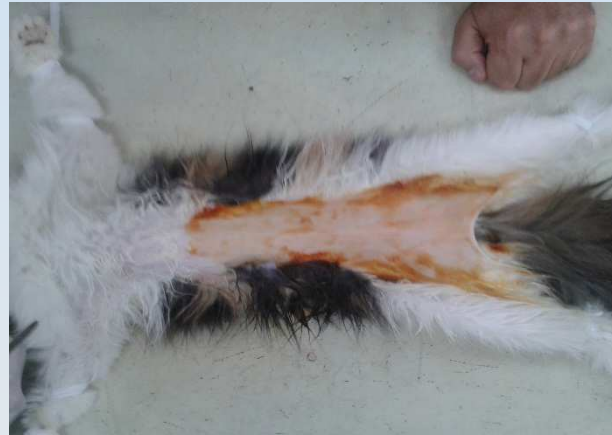Propofol sulphate “0.5 mg/kg bwt” → 0.2 cm

”شرطية“ , I/M

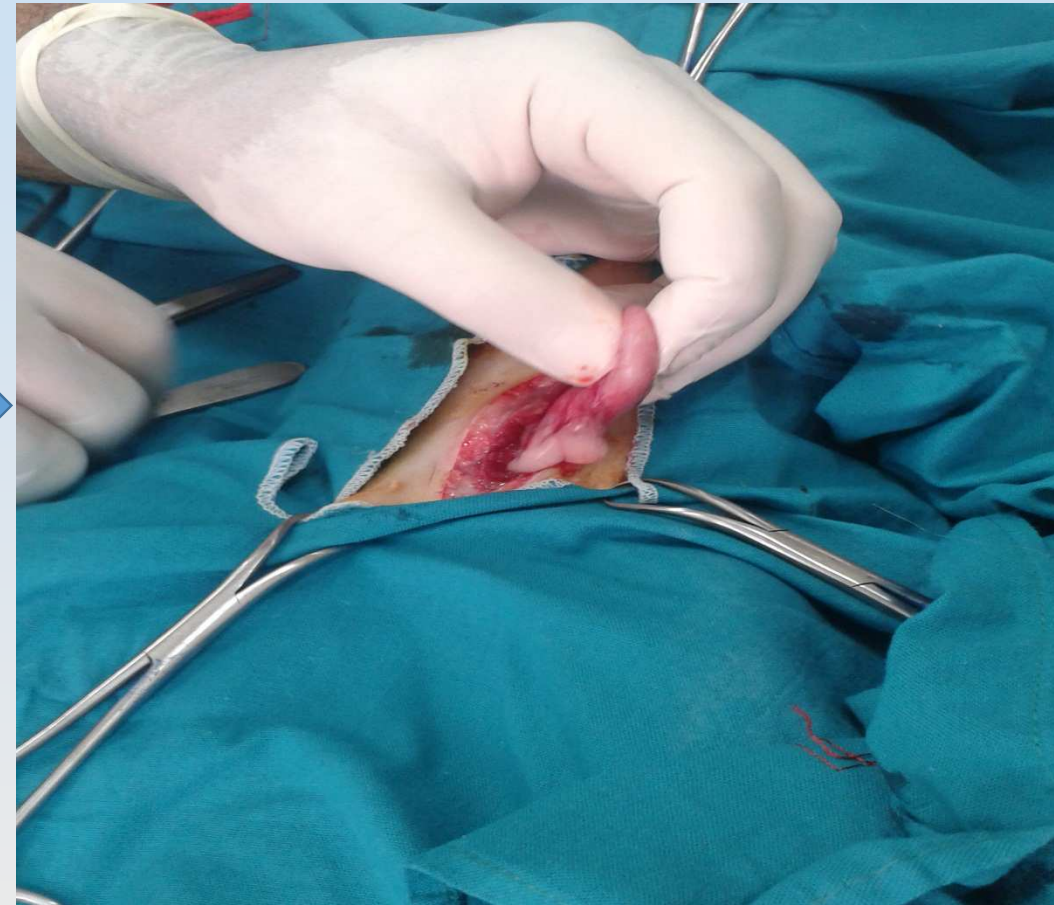
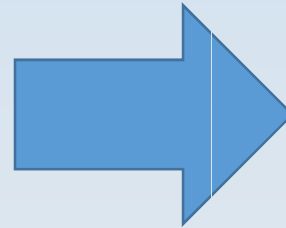
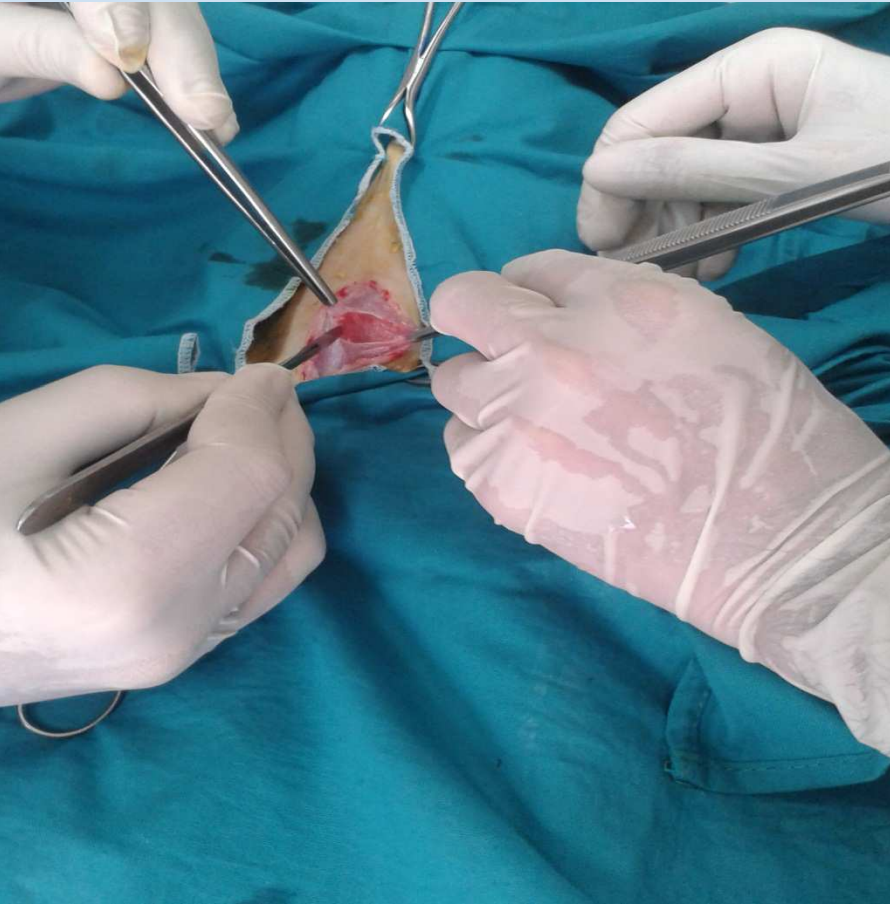
Alfaxalone “1mg/kg bwt” → 0.2 cm “شرطية“ , I/M

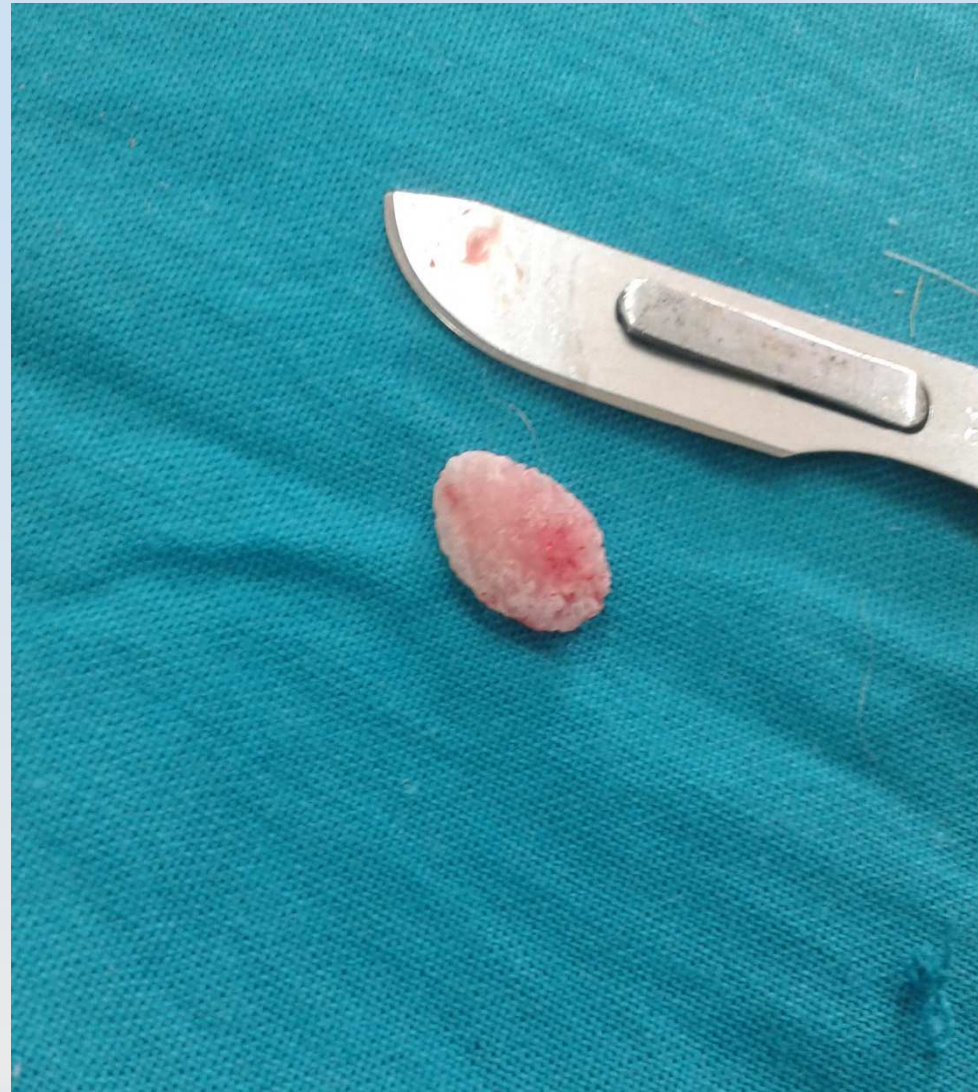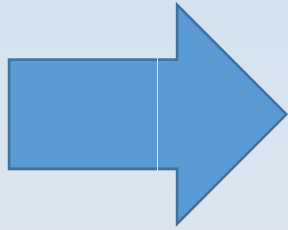
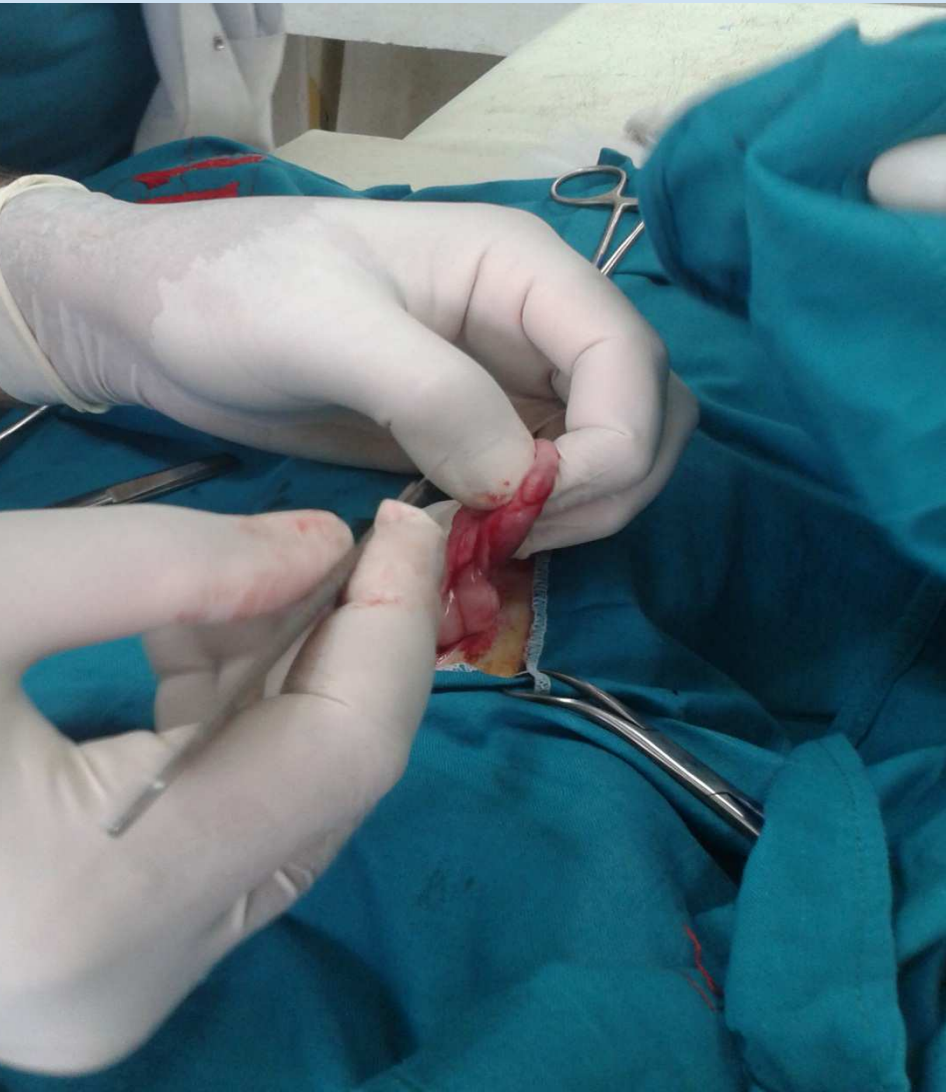Atropine “10-20 mg/kg bwt” → 0.5 cm , I/M

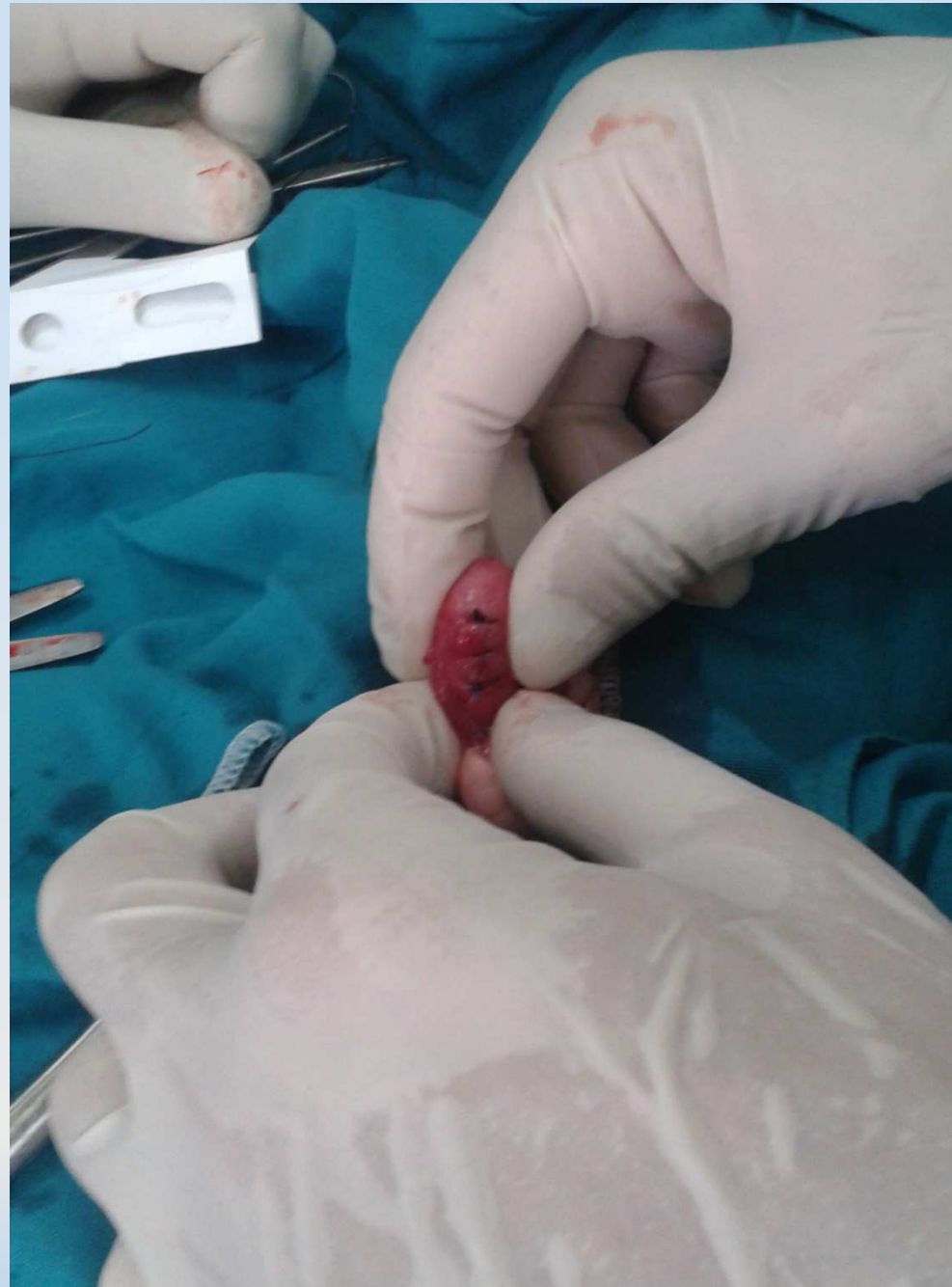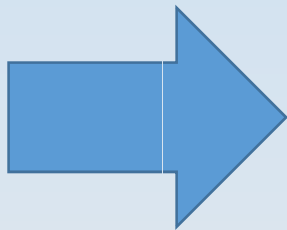
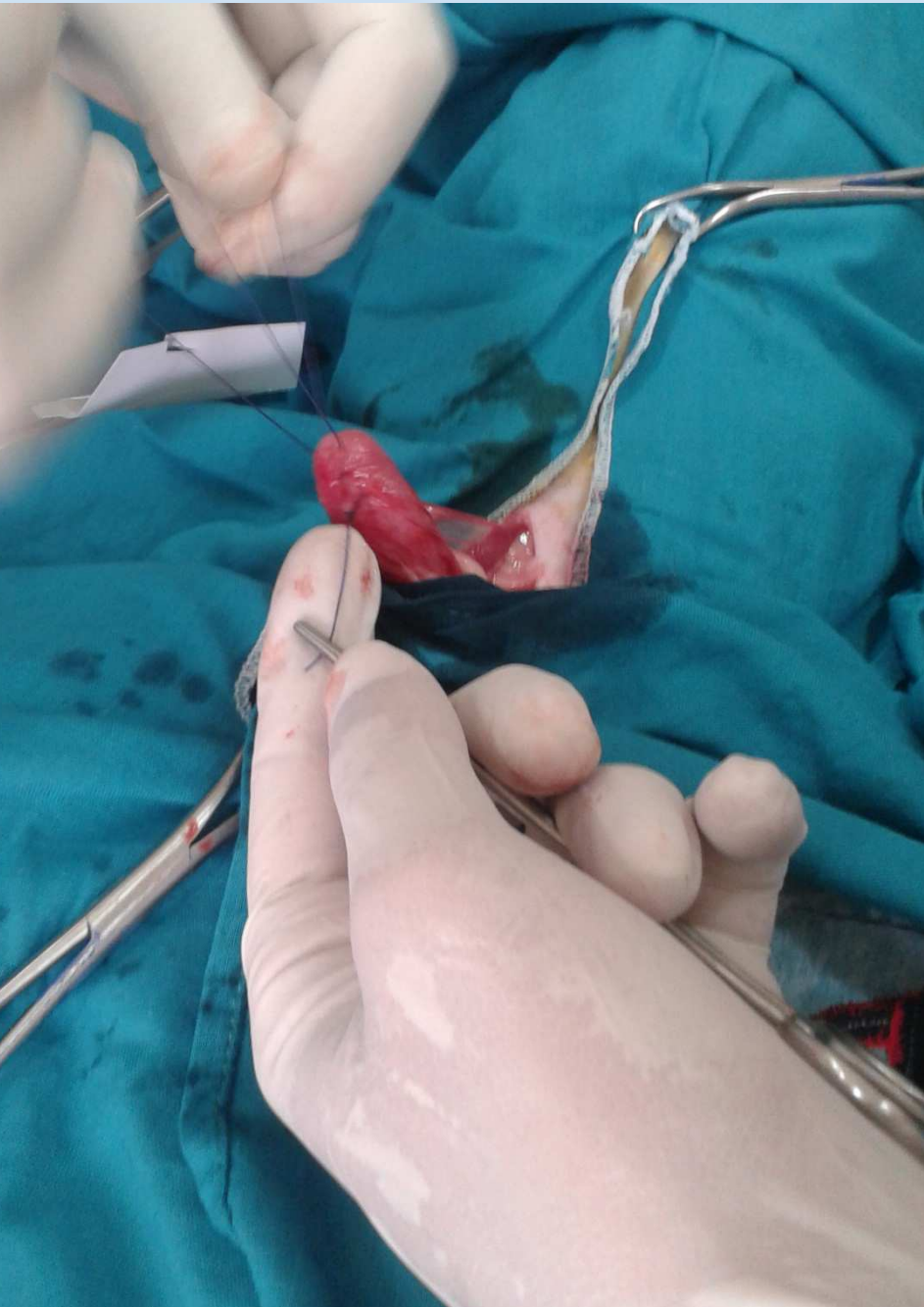Light vomiting after anesthesia as side effects of Alfaxalone

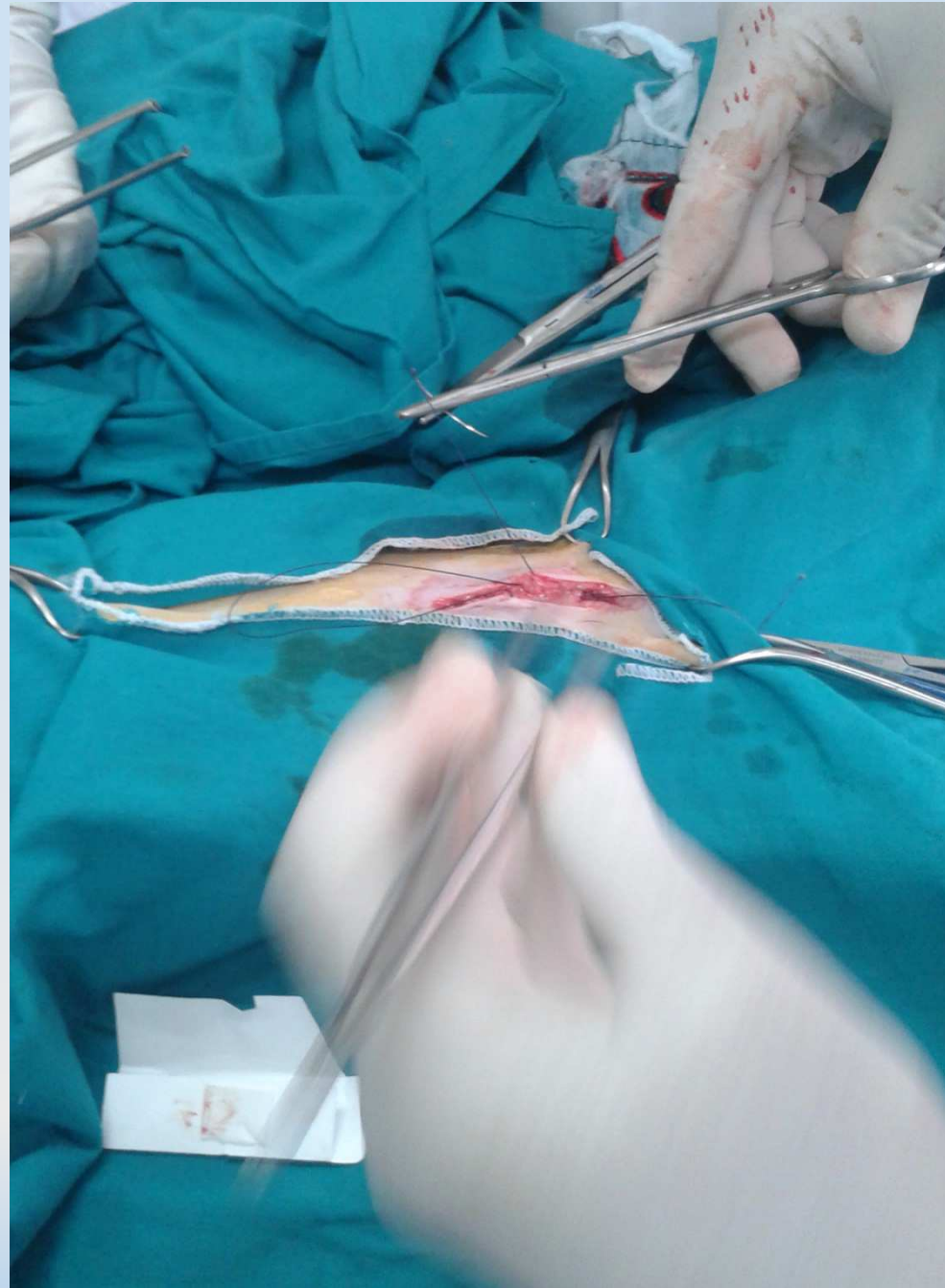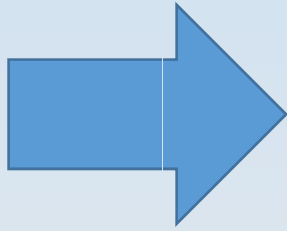
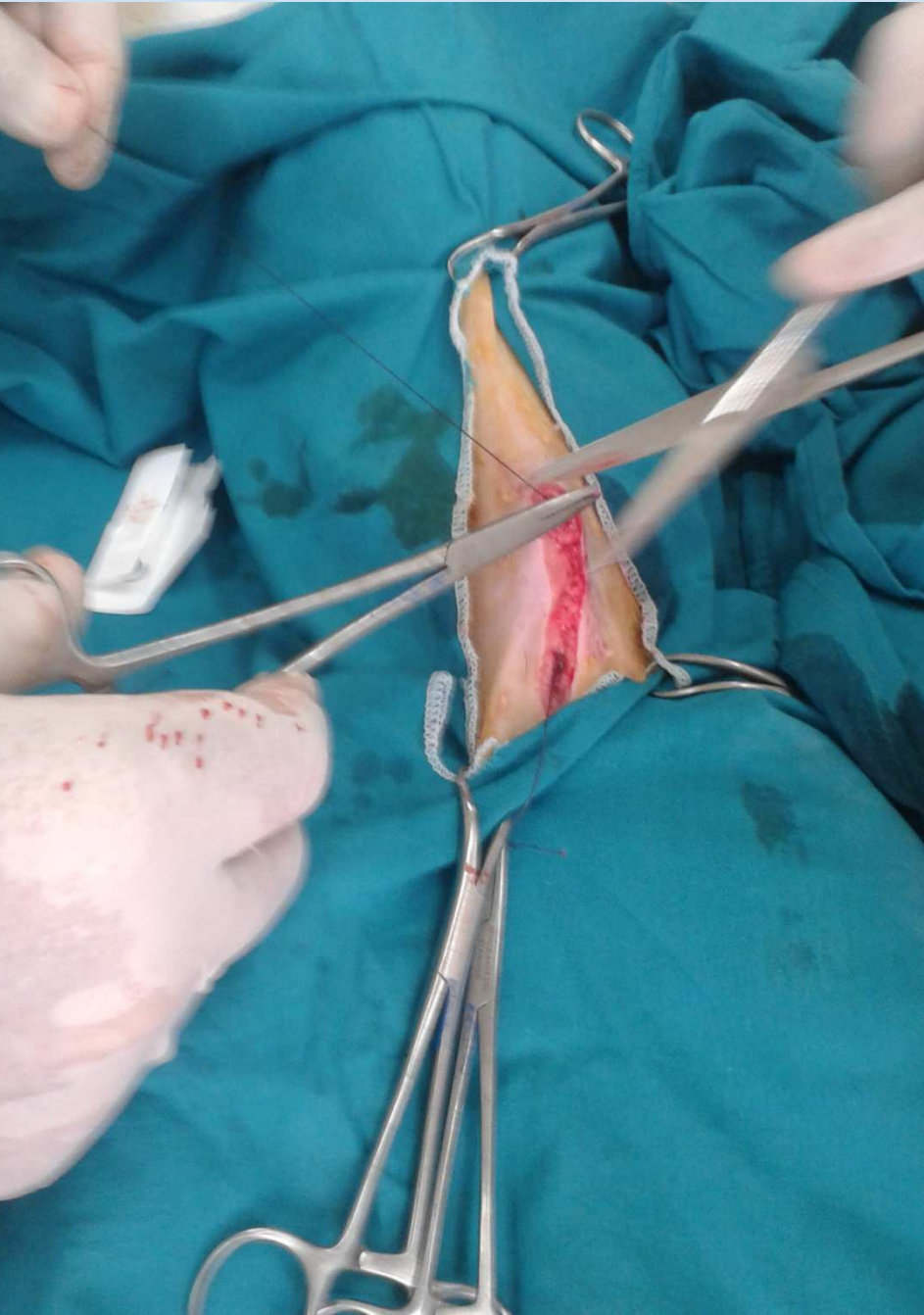


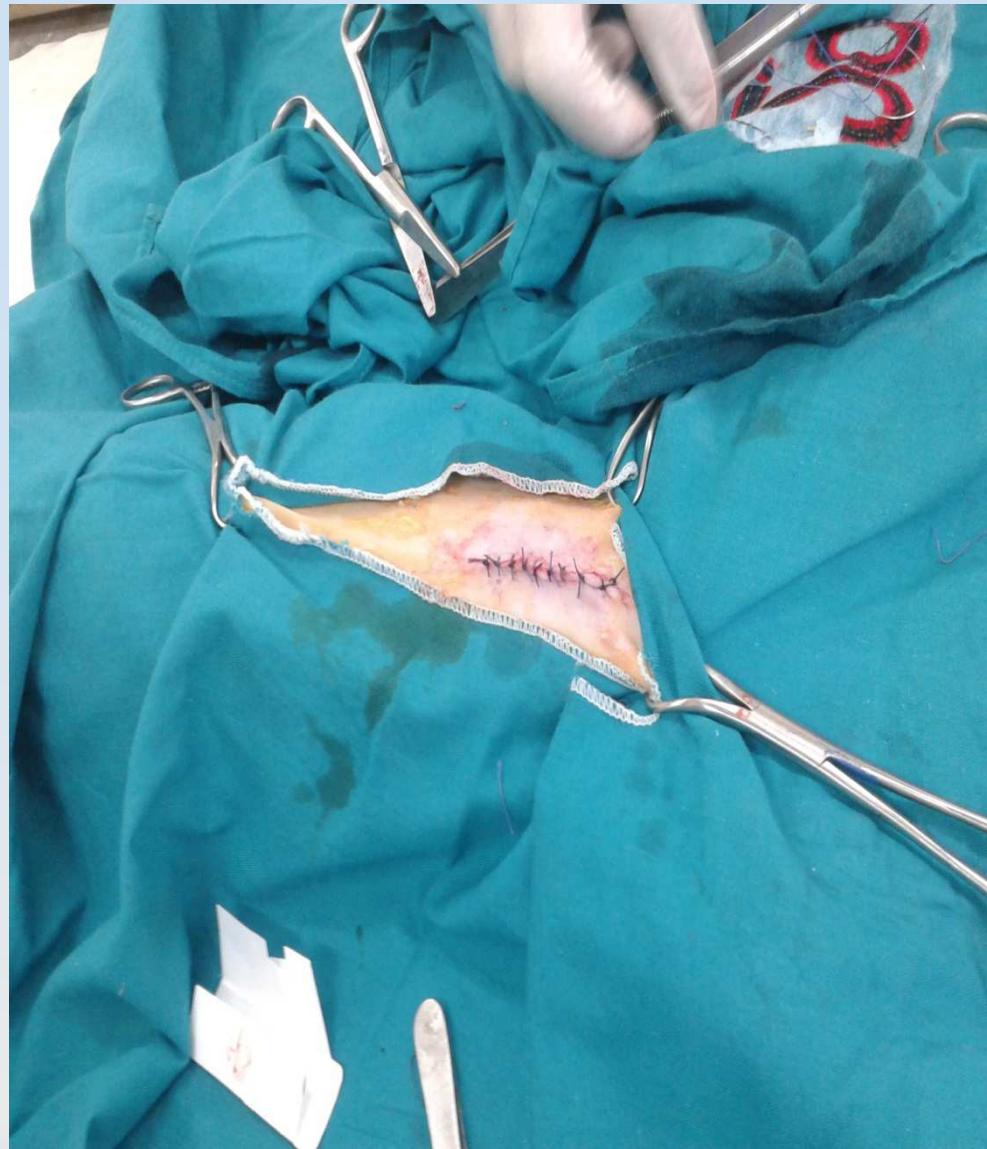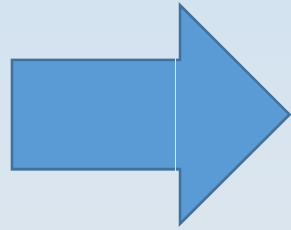
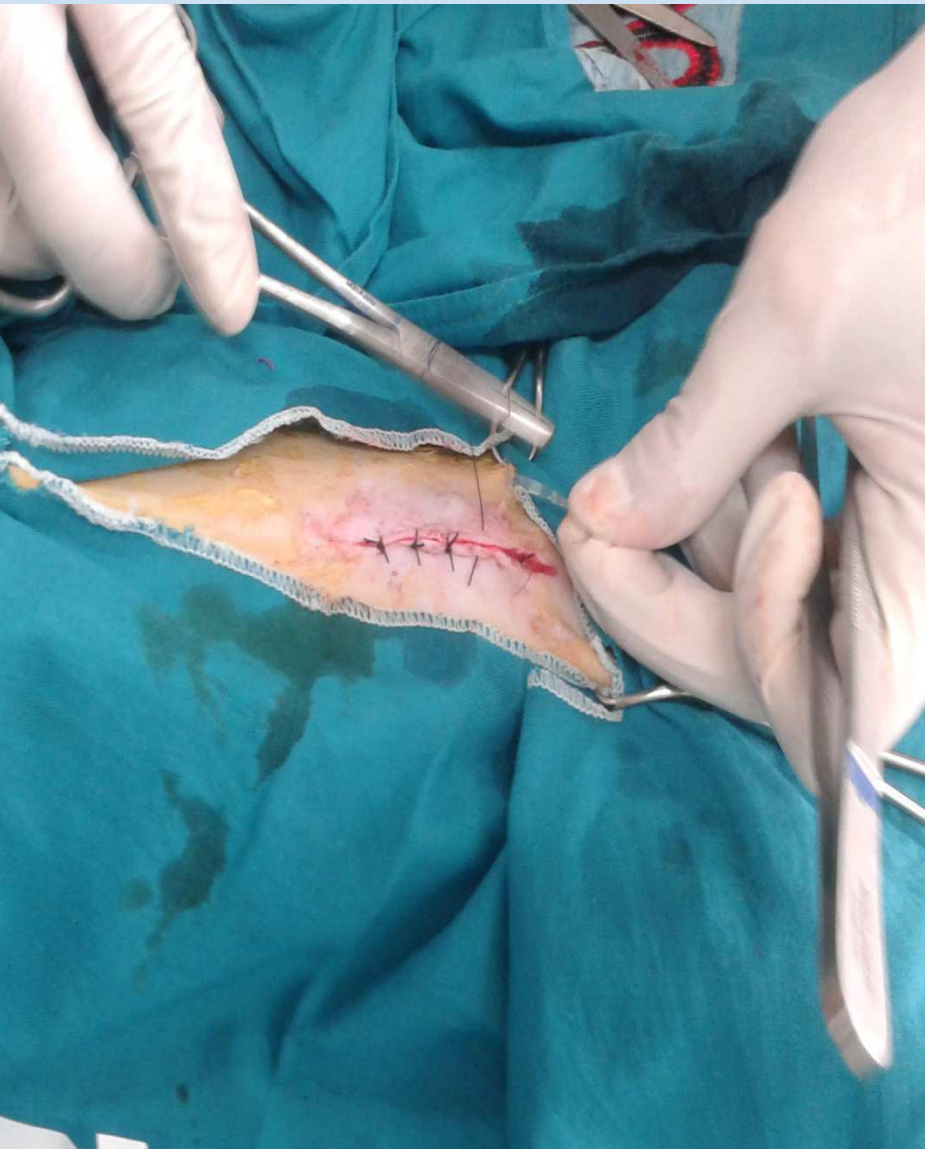
The operation described as photos











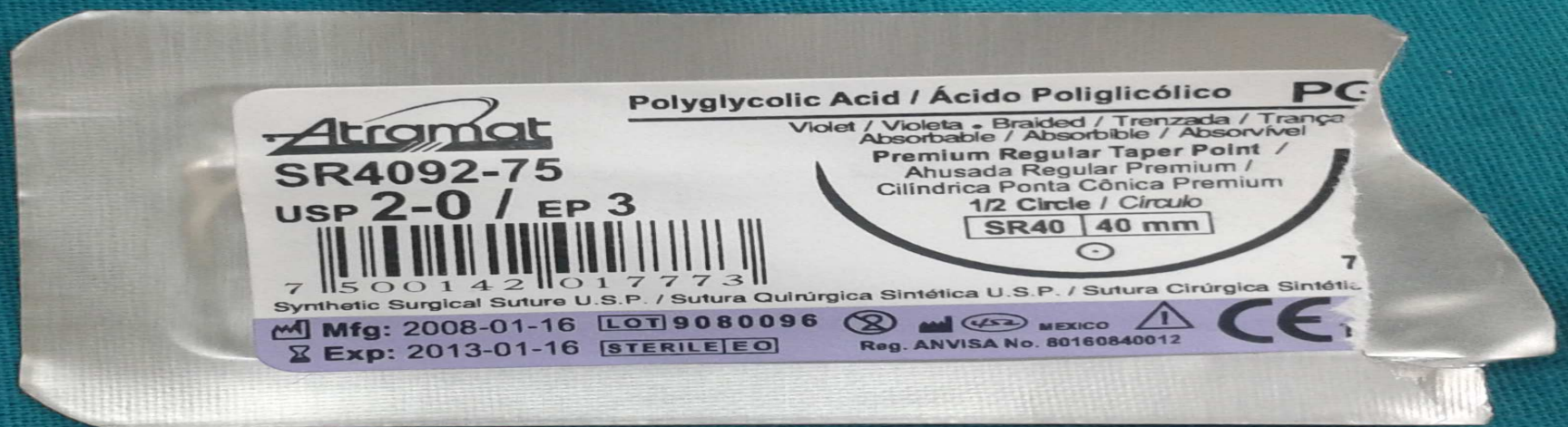
Suture :

ladder → by Lambert's pattern with

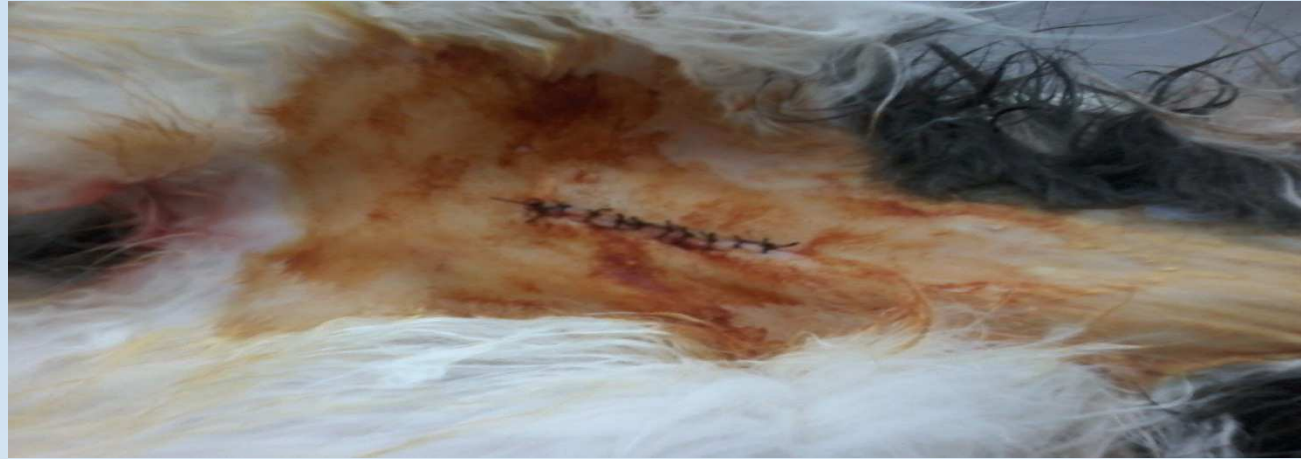absorbable material "polyglycolic acid"

peritoneum e` muscle → simple continuous

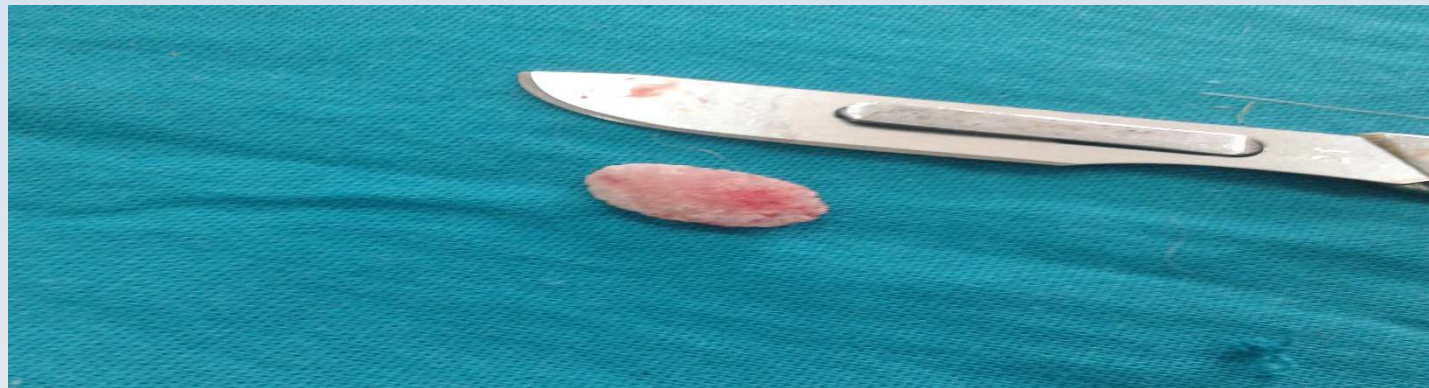
skin → simple interrupted



Wound after operation →



the stone →



After analysis of the stone , it was of calcium oxalate type

Post operative amphlet →

B : don't give pain killer after
surgery in order to the animal
feeling pain and tired so does
not play nor scratch at the
wound and keep calm

