

ORIGINAL ARTICLE

Magnetic resonance sialography of the parotid glands in chronic hepatitis C virus patients with and without vasculitis

Amira A. SHAHIN,¹ Hanan HUSSEIN,¹ Wafaa GABER,¹ Tamer ELBAZ² and Lamia A. Salah El Din³

Departments of ¹Rheumatology and Rehabilitation, ²Endemic Hepatogastroenterology, and Radiology³ Faculty of Medicine, Cairo University, Cairo, Egypt

Abstract

Aim: Hepatitis C virus (HCV) is sialotropic. The pathogenesis of sicca manifestations in patients with chronic HCV infection is not fully understood. We aimed to detect changes in magnetic resonance sialography (MRS) of HCV patients with and without vasculitis.

Method: We studied 32 HCV patients (19 female, mean age 48.8 ± 10.3 years) and 20 age- and gender-matched healthy controls. Half of the patients had vasculitis. Demographic, clinical and serological data were prospectively evaluated. In patients with vasculitis, the disease activity was assessed by the Birmingham Vasculitis Activity Score (BVAS). MRS was performed on all patients and controls.

Results: Abnormal MRS was found in 25% of patients, (6/16 and 2/16 in patients with and without vasculitis, respectively). Among patients with vasculitis, those with abnormal MRS had longer disease duration, higher leukocytic and lymphocytic counts and more frequent cryoglobulinemia ($P < 0.01$, $P < 0.001$, $P < 0.001$ and $P < 0.008$, respectively), while BVAS scores were not significantly different.

Conclusion: Among HCV patients with vasculitis, longer disease duration and cryoglobulinemia were associated with abnormal findings on MRS. To confirm our results, we propose larger-scale, multicentre studies with longer evaluation periods.

Key words: cryoglobulinemia, HCV-related sicca, HCV-related vasculitis, magnetic resonance sialography.

INTRODUCTION

The association between sialadenitis and hepatitis C virus (HCV) infection was first postulated in 1992.¹ The reported occurrence of HCV-related sicca syndrome ranges from 4% to 57% of chronic HCV patients.^{2–5}

HCV is sialotropic. Mice transgenic for HCV envelope genes develop sialadenitis resembling Sjögren's syndrome.⁶ In addition, salivary gland lymphoma is associated with HCV infection.⁷ A hypothesis was postulated that HCV is a relevant local trigger for chronic inflammation and B cell proliferation in the

salivary gland mucosa-associated lymphoid tissue micro-environment.^{7,8}

Magnetic resonance imaging (MRI) has been widely used for demonstrating parenchymal lesions in the salivary glands. It was preferred by some authors as an imaging modality in patients suspected of having Sjögren's syndrome.⁹

Lomas *et al.*¹⁰ described a method of MR sialography (MRS) using a heavily T2-weighted rapid acquisition with relaxation enhancement (RARE) projection technique for imaging the major salivary gland ducts. This technique can be performed in a short time. MRS shows stenosis and dilatations. The presence of the normal peripheral ducts and acini indicates, at least partially, that the gland has not been completely destroyed. Absence of the peripheral ducts and acini indicates that

Correspondence: Professor Amira A. Shahin, 453 Alharam St. Alharam, Giza, Egypt.
Email: amirashahin@hotmail.com

the acini have been destroyed and compressed. The cystic changes seen on MR sialogram represents dilated intra-glandular ducts.¹¹ The mechanism by which HCV results in sicca syndrome is not well established. It is likely that HCV-related sicca syndrome is the product of a host immune-mediated mechanism, rather than direct viral effect.¹²

We aimed in this study to assess the MRS findings in chronic HCV patients with and without vasculitis, and to study the relation of these findings to the epidemiological, clinical and laboratory features of the disease.

MATERIALS AND METHODS

The study population was composed of 32 patients with definite HCV infection (19 women, 26–68 years old with mean age 48.8 ± 10.3 years) and 20 healthy control subjects (eight women, 26–63 years old with mean age 47.9 ± 8.7 years). The healthy controls had no history of disease or of medical treatment that would affect the salivary glands. All patients with HCV had sicca manifestation. Of the 32 patients with HCV, 16 had been chosen to have HCV-related vasculitis, and 16 patients were without any other extra-hepatic manifestations other than sicca. Patients were classified as HCV-related vasculitis using the preliminary classification criteria for cryoglobulinemic vasculitis proposed by de Vita *et al.*¹³, which are also useful for classifying cryoglobulinemic vasculitis in patients with negative cryoglobulins by initial laboratory testing.

Informed consent was obtained from patients and controls for all investigations and patient anonymity has been preserved. The protocol for the research project was approved by a suitably constituted Ethics Committee of the institution within which the work was undertaken and it conformed to the provisions of the World Medical Association's Declaration of Helsinki.

Demographic data, age, age at onset and duration of HCV infection were recorded. The duration of the illness was estimated from the date of blood transfusion or initial exposure to other parenteral sources. In patients with no identifiable source of infection, the disease duration was calculated from the date of diagnosis of HCV infection.

The disease manifestations recorded for every patient were as follows: the presence of rheumatologic manifestations (arthralgia, arthritis, myalgia), skin manifestations (Raynaud's phenomenon, purpura, distal ulcer, gangrene), neurological manifestations, including peripheral and/or central nervous system manifestations (impaired cognitive function and/or abnormal

findings on MRI of the brain), cardiac, pulmonary, renal, gastrointestinal (peptic ulcers, mesenteric microaneurysms), hepatic, ear, nose and throat (ENT) or ophthalmologic involvement. Relevant laboratory tests were performed; complete blood count by automated coulter method, liver function tests (aspartate aminotransferase [AST], alanine aminotransferase [ALT] by kinetic method, serum albumin by bromocresol green [BCG] method, bilirubin by Diazo method and prothrombin time and concentration). All patients were evaluated for complement 3 and 4 levels by the immunonephelometric method, rheumatoid factor (RF) by qualitative determination using latex suspension kits (Cromatest, Barcelona, Spain), anti-Sjögren's syndrome B (anti-SS-B/anti-La by indirect solid phase enzyme-linked immunosorbent assay (ELISA) for the quantitative measurement of immunoglobulin G (IgG) class autoantibodies against SS-A (Ro, 52 and 60 kDa) and SS-B (La) in human serum or plasma, antinuclear antibodies (ANA) by indirect immunofluorescence technique using indirect fluorescence antibody kit (ANAFast, Diasorin, Stillwater, MN, USA), anti-double-stranded DNA (anti-ds-DNA) using an ELISA kit (Diasorin) and antineutrophil cytoplasmic antibodies (ANCA) using indirect immunofluorescence assay on ethanol-fixed neutrophils. Cryoglobulins were isolated by centrifugation of refrigerated patient serum in Wintrobe's tubes. Positive cryoglobulinemia was considered in patients who had a measurable cryocrit level $> 1\%$. The purified cryoglobulins were further analyzed and characterized by immunofixation electrophoresis. HCV infection was confirmed by detection of serum HCV-RNA by polymerase chain reaction.

Exclusion criteria included: (i) HBV patients by performing hepatitis B surface antigen (HbsAg) and hepatitis B core antibody (HbcAb) tests using the ELISA technique; (ii) human immunodeficiency virus by performing anti-human immunodeficiency virus (HIV-I and -II) antibody testing by ELISA technique; (iii) coexistence of diabetes, autoimmune, lymphoproliferative or other infectious diseases (except HCV infection); (iv) presence of any other cause of vasculitis; (v) any subject with other associated liver pathologies, such as as bilharziasis; (vi) past head and neck radiation treatment; (vii) use of anticholinergic drugs (since a time shorter than fourfold of the half-life of the drug); (viii) local parotid gland pathology; and (ix) previous treatment with antiviral therapy (in the form of interferon [IFN]- α).

For the patients with associated vasculitis, the Birmingham Vasculitis Activity Score (BVAS, 2003),¹⁴ an

updated version of the BVAS,¹⁵ was used for scoring disease activity. This score is a clinical index of the degree of vasculitis activity in nine separate organ systems, namely the systemic, cutaneous, mucous membranes/eyes, ENT, chest, cardiovascular, abdominal, renal and nervous systems. The maximum score for persistent abnormalities is 33 and for new/worse symptoms and signs, it is 63.

MRS

MRS was performed on a 1.5-T imager with a neck phased-array coil. Initially, a single-shot RARE image was obtained in the axial plane. Imaging parameters for the single-shot RARE sequence were as follows: echo space 11.5 msec, T_{Reff} 1200, section thickness 30–40 mm, field of view (FOV) 200 mm, matrix 256, number of acquisitions one, and acquisition time 6 sec. By using this axial RARE image as a localizer, we determined the oblique sagittal image plane necessary to cover the whole course of the parotid gland duct, since the duct has a small C-shaped curve anteriorly as it bends around the masseter muscle. MRS source images were then obtained with a 2-D fast FSE sequence using the following parameters: 9500/259/4 (TR/T_{Reff}/excitations), number of echoes for each excitation 27, section thickness 2 mm with no intersection gap, number of sections acquired 18, FOV 170 mm, matrix 290 3 512, and acquisition time 6 min 45 sec. A fat-saturation pulse was used in this sequence. All images generated were analyzed on the basis of maximum intensity projection (MIP) reconstruction. To enhance the visualization of the ductal structures, we stimulated salivation by intra-oral application of lemon juice.

MRs staging

The MR sialographic stages were determined according to the criteria of X-ray sialography proposed by Rubin and Holt.¹⁶

Stage 0: normal.

Stage 1: punctuate; this is the earliest stage, in which diffuse, spherical areas of high signal intensity, 1 mm or less in diameter and uniform in size, are distributed evenly throughout the gland.

Stage 2: globular; in this stage of the disease, the spherical areas of high signal intensity increase to 1–2 mm in diameter.

Stage 3: cavitory; with further disease progression, the areas of high signal intensity coalesce and enlarge further, up to 1 cm in diameter, becoming irregular in size and distribution and decreasing in number.

Stage 4: destructive; this represents the end stage of the disease, in which there is a marked dilatation of the main duct with an irregular diameter.

MR sialographic staging of the cases was performed by the reviewer who was blinded to the clinical parameters, to the results of the imaging tests and to the final diagnosis with 15 years experience in gastrointestinal tract imaging.

Statistical methods

Statistical analysis was performed by SPSS (version 11: SPSS Inc., Chicago, IL, USA) for Windows. The means and standard deviation (SD) were computed for the continuous variables; the difference between the means was tested by standard *t*. For comparison of percentages chi-squared (χ^2) was used. Differences were considered to be significant when *P*-value was < 0.05.

RESULTS

The difference between the mean age of all patients (48.1 ± 8.1 years) and the mean age of the controls (48.1 ± 8.8 years) was non-significant with *P* = 0.987. The patients were 13 males and 19 females, and the controls were eight males and 12 females (*P* = 1.000).

Twenty-four patients with HCV (75%) had normal glands (stage 0). Eight patients (25%) had abnormal findings, while all the controls had normal glands (stage 0). This difference was statistically significant (*P* = 0.017). In three patients (9.45%) the glands had a punctuate appearance (stage 1) (Fig. 1). Three patients

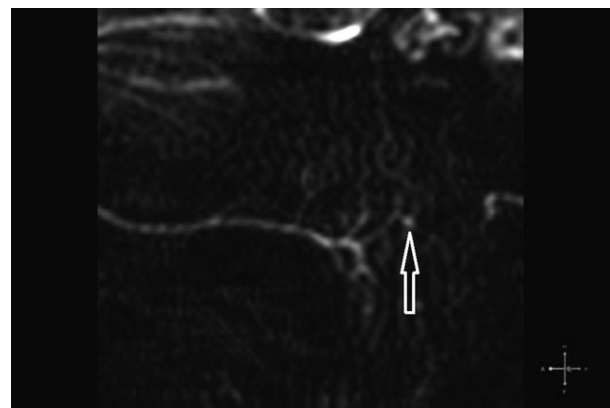


Figure 1 Oblique sagittal-coronal magnetic resonance sialogram after stimulation of salivation with a lemon juice shows few punctuate lesions (arrow) at parotid duct branches (stage 1).

(9.45%) had a globular appearance (stage 2) (Fig. 2) and two patients (6.35%) had a destructive appearance (stage 4) (Fig. 3).

HCV was attributed to blood transfusion in two patients and to a previous operation in nine patients. In group A, vasculitis was the presenting symptoms of HCV in 14/16 patients (87.5%), while the remaining had other HCV manifestations. ANA was detected in five patients and it was speckled in all of them. Anti-Ro, anti-La and anti-ds-DNA antibodies were not detected in any of our patients. Cryoglobulins were detected in six patients (37.5%). All of them had associated vasculitis (group A). Cryoglobulin characterization showed

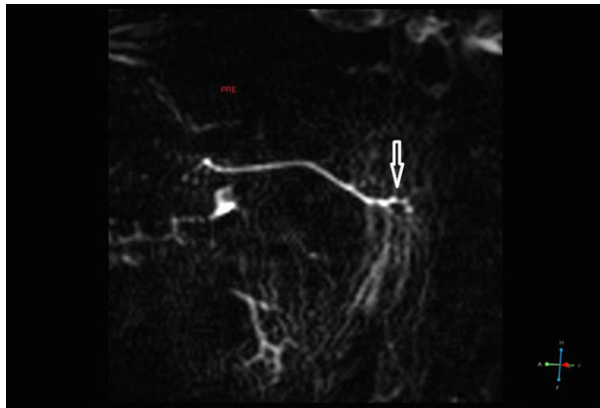


Figure 2 Oblique sagittal-coronal magnetic resonance sialogram after stimulation of salivation with a lemon juice shows few globular lesions (arrow) at main duct and branches (stage 2).

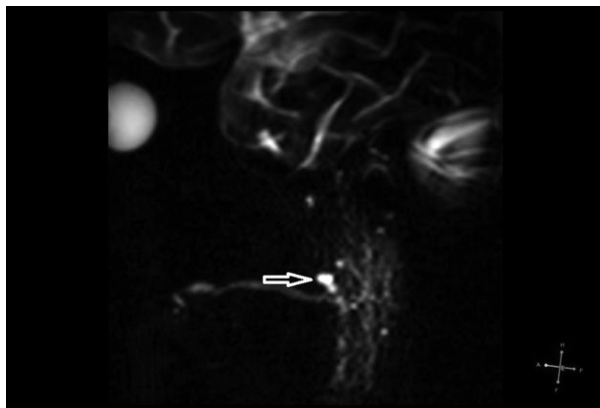


Figure 3 Oblique sagittal-coronal magnetic resonance sialogram after stimulation by a lemon juice shows the irregularities of the main parotid duct and its branches. Multiple globular as well as one cavitory destructive lesion (arrow) are noted (stage 4).

that four patients were type III and two patients were type II. Eight patients in group A had a history of receiving steroids in low doses (5–10 mg/day) and four patients received azathioprine (50–100 mg/day) for months during their illness time. One patient received cyclophosphamide of 6-monthly pulses 1 g/pulse during her illness time. She had stage 2 on MRS. The comparisons between demographic, clinical and laboratory data in group A and group B is shown in Table 1.

Four patients (25%) in group A had fever and fatigue. Eleven patients (68.8%) had purpura, two (12.5%) had digital gangrene, 10 (62.5%) had arthralgia, eight (50%) had arthritis, two (12.5%) had fibromyalgia, two (12.5%) had Raynaud's phenomenon, seven (43.8%) had peripheral neuropathy and three (18.8%) had mononeuritis multiplex. Nerve conduction velocity studies of the patients with peripheral neuritis revealed that seven had axonal lesions and three had axonal-demyelinating lesions. Two patients (12.5%) had depression and three (18.8%) had cognitive impairment. One patient had brain vasculitis and two patients had brain infarcts as diagnosed by MRI. Cardiac involvement was diagnosed in three patients (18.8%); all of them had valvular lesions and diastolic dysfunction, while pericardial effusion was detected only in one of them. Three patients (18.8%) had interstitial pulmonary fibrosis and two (12.5%) had nephritis.

By comparing the MRS findings of the patients with HCV-associated vasculitis (group A) and HCV patients without vasculitis (group B), six patients from group A showed abnormal findings compared to two in group B ($P = 0.22$). The details of the MR results in group A and group B are shown in Table 2.

We subdivided group A into another two subgroups according to the findings from MRS: group I, patients with abnormal findings on MRS, and group II, patients with normal findings. The comparisons between group I and II concerning demographic, laboratory data and BVAS score is shown in Table 3.

DISCUSSION

We studied the MRS of 32 HCV patients and 20 normal subjects. Abnormal MRS findings were detected in eight HCV patients (25%). The previous reported occurrence of HCV-related sicca syndrome ranges from 4% to 57%. This wide range may be related to differences in diagnostic criteria.^{1–5} The lower number of patients with positive data in this study compared to other studies may be related to the different modality we used. MRS was considered by Tonami *et al.*⁹ as being less sensitive,

Table 1 The comparison between demographic, clinical and laboratory data of group A and group B

	HCV patients <i>n</i> = 32	Group A <i>n</i> = 16	Group B <i>n</i> = 16	<i>P</i>
Age (years)	48.1 ± 8.1	48.7 ± 6.8	47.7 ± 9.2	0.725
Age of onset (years)	44.8 ± 7.9	44.9 ± 7.2	44.9 ± 9.2	1.000
Duration (years)	3.3 ± 2.1	3.8 ± 2.1	2.7 ± 1.9	0.149
Virologic load (copies/mL)	778 781 ± 618 555	315 062 ± 324 786	1 275 333 ± 473 495	<0.001*
Leuceocytes/mL	6148 ± 2792	8375 ± 2353	4200 ± 1309	<0.001*
Lymphocytes/mL	4406 ± 4885	3678 ± 1193	2149 ± 1248	0.001*
Platelets/mL	240 344 ± 89 278	228 375 ± 84 933	251 000 ± 97 834	0.492
RF <i>n</i> (%)	11 (34.4)	10 (62.5)	1 (6.3)	0.002*
ANA <i>n</i> (%)	5 (15.6)	5 (31.3)	0	0.043*
Cryoglobulins <i>n</i> (%)	6 (18.8)	6 (37.5)	0	0.018*
Consumed C3 <i>n</i> (%)	6 (18.8)	6 (37.5)	0	0.018*
Consumed C4 <i>n</i> (%)	7 (21.9)	7 (43.8)	0	0.007*

**P* < 0.05, *n*, number; RF, rheumatoid factor; ANA, antinuclear antibody; C, complement.

Table 2 MRS findings in group A and group B

	All patients <i>n</i> = 32	Group A <i>n</i> = 16	Group B <i>n</i> = 16	<i>P</i>
Abnormal MRS <i>n</i> (%)	8 (25)	6 (37.5)	2 (12.5)	0.220
Stage 1 <i>n</i> (%)	3 (9.4)	1 (6.3)	2 (12.5)	1.000
Stage 2 <i>n</i> (%)	3 (9.4)	3 (18.8)	0	0.226
Stage 3 <i>n</i> (%)	0	0	0	–
Stage 4 <i>n</i> (%)	2 (6.3)	2 (12.5)	0	0.484

MRS, magnetic resonance sialography.

Table 3 comparison between demographic data and clinical presentation of group I and group II

	Group I <i>n</i> = 6	Group II <i>n</i> = 10	<i>P</i>
Age (years)	47.5 ± 5.8	49.4 ± 7.6	0.605
Age at onset (years)	42 ± 5.5	46.7 ± 7.8	0.219
Duration (years)	5.7 ± 1.5	2.7 ± 1.9	0.010*
Virologic load (copies/mL)	172 000 ± 165 523	400 900 ± 372 572	0.181
Leuceocytes/mL	10 500 ± 1900	6700 ± 1600	< 0.001*
Lymphocytes/mL	4858 ± 731	2971 ± 769	< 0.001*
Platelets/mL	231 667 ± 91 900	226 400 ± 94 300	0.909
RF <i>n</i> (%)	4 (66.7)	6 (60)	1.000
ANA <i>n</i> (%)	3 (50)	2 (20)	0.299
Cryoglobulins <i>n</i> (%)	5 (83.3)	1 (10)	0.008
Consumed C3 <i>n</i> (%)	3 (50)	3 (30)	0.607
Consumed C4 <i>n</i> (%)	3 (50)	4 (40)	1.000
BVAS score	4.8 ± 1.9	10.9 ± 7.5	0.077

**P* < 0.05. ANA, antinuclear antibody; BVAS, Birmingham Vasculitis Activity Score; C, complement; RF, rheumatoid factor.

although a more specific tool when compared to sialography.

All HCV patients were seronegative for SS-A/SS-B antibodies, which was similar to previously reported results.¹⁷ The pathology of sicca complex in HCV-

associated sicca is different from the pathology of SS. In SS, the presence of focal lymphomonocytic infiltrates in the target organs, particularly in the salivary and lacrimal glands, had been considered the hallmark of disease. The focus consists of an agglomerate of

inflammatory cells, mainly lymphocytes, which are located around the acinar and ductal structures of the glands.^{18,19} The great importance of T cells in the immunopathology of progressive SS is strongly confirmed by the common observation that focal lymphocytic infiltrates are mainly constituted of T cells with a large predominance of CD4+ T cells (CD4/CD8 ratio ranging from 3 : 1 to 5 : 1).²⁰ The pathogenesis of various HCV-associated disorders is quite complex and still not completely understood.

In HCV associated sicca, the lymphotropic virus causing lymphocytic infiltrates was found to be located in the pericapillary area rather than around the glandular ducts. In addition, a lack of damage (or mild damage) of the glandular tissue has also been reported. However, sicca symptoms seem to be less frequent and milder in HCV-infected patients.²¹ The lymphocytic subpopulations present in glandular infiltrates appear to be different, sometimes being represented by a predominance of CD8+ T lymphocytes, at least in some areas.^{19,22} Histologic examinations of salivary gland biopsies in HCV-infected patients show pericapillary and non-pericanalary lymphocytic infiltration. The glandular canals are typically spared.³

Two groups of patients were selected to be involved in the current study, group A had HCV-associated vasculitis and group B had chronic HCV infection without any other extrahepatic manifestation other than sicca. On comparing the MRS findings of the two groups, six patients from group A showed abnormal MRS findings compared to two patients in group B. The glandular destruction in the form of stage 2 and stage 4 was found more in group A than in group B, which had only stage 1. Leukocytosis and subsequently lymphocytosis were detected significantly more in group A than in group B, which is an evident finding in cases of vasculitis. This elevation in the number of leucocytes and the number of lymphocytes in group A may be involved in the pathogenesis of sicca as it is mainly through lymphocytic infiltration of the salivary glands.³

Patients with HCV-associated vasculitis and MRS positive findings had a longer disease duration ($P < 0.01$), while the activity of the disease measured by BVAS was not related to MRS-positive findings, which may relate these changes more to the chronicity of the disease than to the activity.

Cryoglobulins were detected in 18.8% in all HCV patients involved in this study, which is slightly lower than the published data in previous results that ranged between 19–54%.²³ This may be related to the different study designs. Patients in this study were not randomly

chosen. All of those patients with cryoglobulinemia had vasculitis (group A) and constituted 37.5% of this group. Cryoglobulins were detected more in patients with positive MRS findings ($P < 0.01$).

Patients with mixed cryoglobulinemia were reported to develop a mild sicca syndrome in the absence of typical histopathological and/or serological alterations.²⁴ In individual cases the differential diagnosis between SS and mixed cryoglobulinemia may be very difficult, mainly in patients with overt sicca syndrome, cryoglobulinemia and HCV infection. On the other hand, the detection of mixed cryoglobulins in the serum of a minority of SS cases seems to identify a particular clinical subset characterized by worse prognosis.²⁵ Ferri *et al.*²⁶ suggested classifying these patients as overlapping mixed cryoglobulinemia/primary SS.

The mechanism by which HCV results in sicca syndrome is not well established. The virus has not been shown to directly infect salivary gland tissue²⁷ and it is likely that HCV-related sicca syndrome is the product of host immune-mediated mechanisms rather than direct viral effect.¹² The increased number of patients with abnormal MRS in the group of HCV-associated vasculitis and cryoglobulinemia supports this speculation.

CONCLUSION

The abnormal MRS findings were detected in 37.5% of HCV patients with associated vasculitis (group A) compared to 12.5% of HCV only (group B). The glandular destruction in the form of stage 2 and stage 4 was found more in group A than in group B which had only stage 1. Patients with HCV-associated vasculitis and MRS-positive findings had longer disease duration, while the activity of the disease measured by BVAS was not related to MRS-positive findings, which may relate this manifestation more to the chronicity of the disease than to the activity. Cryoglobulins were detected significantly more in patients with positive MRS findings. However, its implication in the pathogenesis of these diseases deserves future research.

REFERENCES

- 1 Haddad J, Deny P, Munz-Gotheil C *et al.* (1992) Lymphocytic sialadenitis of Sjögren's syndrome associated with chronic hepatitis C virus liver disease. *Lancet* 339, 321–3.
- 2 Cacoub P, Renou C, Rosenthal E *et al.* (2000) Extrahepatic manifestations associated with hepatitis C virus infection: a prospective multicenter study of 321 patients. *Medicine* 79 (1), 47–56.

- 3 Jacobson M, Cacoub P, Dal Maso L, Harrison SA, Younossi ZM (2010) Manifestations of chronic hepatitis C virus infection beyond the liver. *Clin Gastroenterol Hepatol* 8, 1017–29.
- 4 Zarebska-Michaluk DA, Lebensztejn DM, Kryczka WM, Skiba E (2010) Extrahepatic manifestations associated with chronic hepatitis C infections in Poland. *Adv Med Sci* 55 (1), 67–73.
- 5 Nawito Z, Amr Amin A, Abu El-Fadl S, Abu El Einen K (2011) Sicca complex among Egyptian patients with chronic hepatitis C virus infection. *Clin Rheumatol* 30, 1299–304.
- 6 Arrieta JJ, Rodriguez-Inigo E, Ortiz-Movilla N *et al.* (2001) In situ detection of hepatitis C virus RNA in salivary glands. *Am J Pathol* 158, 259–64.
- 7 De Vita S, Damato R, Marchi G, Sacco S, Ferraccioli G (2002) True primary Sjögren's syndrome in a subset of patients with hepatitis C infection: a model linking chronic infection to chronic sialadenitis. *Isr Med Assoc J* 4, 1101–5.
- 8 De Vita S, De Marchi G, Sacco S, Gremese E, Fabris M, Ferraccioli GF (2001) Preliminary classification of nonmalignant B cell proliferation in Sjögren's syndrome: perspectives on pathobiology and treatment based on an integrated clinico-pathologic and molecular approach. *Blood Cells Mol Dis* 27, 757–66.
- 9 Tonami H, Higashi K, Matoba M, Yokota H, Yamamoto I, Sugai S (2001) A comparative study between MR sialography and salivary gland scintigraphy in the diagnosis of Sjögren syndrome. *J Comput Assist Tomogr* 25, 262–8.
- 10 Lomas DJ, Carroll NR, Johnson G *et al.* (1996) MR sialography. *Radiology* 200, 129–33.
- 11 Tonami H, Ogawa Y, Matoba M *et al.* (1998) MR sialography in patients with Sjögren's Syndrome. *AJNR Am J Neuroradiol* 19, 1199–203.
- 12 Ramos-Casals M, Loustaud-Ratti V, De Vita S *et al.* (2005) Sjögren's syndrome associated with hepatitis C virus: a multicenter analysis of 137 cases. *Medicine* 84 (2), 81–9.
- 13 De Vita S, Soldano F, Isola M *et al.* (2011) Preliminary classification criteria for the cryoglobulinaemic vasculitis. *Ann Rheum Dis* 70(7): 1183–90.
- 14 Flossmann O, Bacon P, de Groot K *et al.* (2007) Development of comprehensive disease assessment in systemic vasculitis. *Ann Rheum Dis* 66, 283–92.
- 15 Luqumani RA, Exley AR, Kitas GD, Bacon PA (1997) Disease assessment and management of the vasculitides. *Ballieres Clin Rheumatol* 11, 423–46.
- 16 Rubin P, Holt JF (1957) Secretory sialography in diseases of the major salivary glands. *Am J Roentgenol Radium Ther Nucl Med* 77, 575–98.
- 17 Jorgensen C, Legouffe MC, Perney P *et al.* (1996) Sicca syndrome associated with hepatitis C virus infection. *Arthritis Rheum* 39, 1166–71.
- 18 Daniels TE (1984) Labial salivary gland biopsy in Sjögren's syndrome. Assessment as a diagnostic criterion in 362 suspected cases. *Arthritis Rheum* 27, 147–56.
- 19 Vitali C (2011) Immunopathologic differences of Sjögren's syndrome versus sicca syndrome in HCV and HIV infection. *Arthritis Res Ther* 13, 233.
- 20 Katsifis GE, Moutsopoulos NM, Wahl SM (2007) T lymphocytes in Sjögren's syndrome: contributors to and regulators of pathophysiology. *Clin Rev Allergy Immunol* 32, 252–64.
- 21 Carrozzo M (2008) Oral diseases associated with hepatitis C virus infection. Part 1: sialadenitis and salivary glands lymphoma. *Oral Dis* 14, 123–30.
- 22 Freni MA, Artuso D, Gerken G *et al.* (1995) Focal lymphocytic aggregates in chronic hepatitis C: occurrence, immunohistochemical characterization and relation to markers of autoimmunity. *Hepatology* 22, 389–94.
- 23 Himoto T, Masaki T (2012) Extrahepatic manifestations and autoantibodies in patients with hepatitis C virus infection. *Clin Dev Immunol* 2012, 871401.
- 24 Ferri C (2008) Mixed cryoglobulinemia. *Orphanet J Rare Dis* 16, 3–25.
- 25 Ioannidis JPA, Vassiliou VA, Moutsopoulos HM (2002) Long term risk of mortality and lymphoproliferative disease and predictive classification of primary Sjögren's syndrome. *Arthritis Rheum* 46, 741–7.
- 26 Ferri C, Sebastiani M, Antonelli A, Colaci M, Manfredi A, Giuggioli D (2012) Current treatment of hepatitis C-associated rheumatic diseases. *Arthritis Res Ther* 14, 215.
- 27 Toussirot E, Le Huède G, Mougin C, Balblanc JC, Bettinger D, Wendling D (2002) Presence of hepatitis C virus RNA in the salivary glands of patients with Sjögren's syndrome and hepatitis C virus infection. *J Rheumatol* 29, 2382–5.