

N-ACYTEL CYSTEINE AMELIORATES METHOTREXATE INDUCED HEPATIC TOXICITY AND GENOTOXICITY IN MALE ALBINO RATS

Hala Said^{*}, Amany Salah^{*}, Alaa Shehab^{*}, Ahmed Elshatory^{*}, Omayma Elkholy^{**},
Gorge Nazih^{**} and Walaa Awad^{***}

^{*}Forensic Medicine and Clinical Toxicology department, ^{**}Biochemistry department, Faculty of Medicine, Cairo University and ^{***}Egyptian Fellowship of Clinical Pharmacy.

ABSTRACT

Background: Methotrexate (MTX) is widely used as a cytotoxic chemotherapeutic agent for malignancies as well as in the treatment of various inflammatory diseases. MTX treatment has been associated with hepatic toxicity and genotoxicity. The current study was conducted to assess the potential protective role of N-acetylcysteine in attenuation of methotrexate-induced hepatic damage and genotoxicity in MTX intoxicated male albino rats.

Methods: Forty, apparently healthy adult male albino rats weighed 150±10 gm were randomly divided into four groups; [group 1: negative control group, group 2: positive control (NAC treated) group, group 3: MTX treated group, group 4: MTX/NAC treated group]. The rats were treated once daily for 12 weeks by I.V injection of Methotrexate in a dose of 2 mg/kg ($1/7$ LD₅₀) and N-acetylcysteine in a dose of 80 mg/kg ($1/14$ LD₅₀) in the tail veins of rats. Blood samples were obtained at the end of the 4th, 8th and 12th weeks and were prepared for ALT levels and BAX gene expression value examination. At the end of the study, liver samples were obtained for histopathological examination.

Results: A significant constant increase in ALT levels and BAX gene expression value of the MTX-treated group (group 3) was observed throughout the study. Supplementation of NAC concomitantly with MTX in group 4 reduced significantly ALT levels and BAX gene expression value when compared to the non-supplemented group 3 that treated with MTX at the 4th, 8th and 12th weeks (P< 0.000). The previous chemical results were confirmed by the histopathological studies of the liver that revealed the presence of dilatation and congestion of the central veins, hepatic sinusoids, hepatic arteries, portal veins with increased number of Kupffer cells and pyknosis of the hepatic nuclei in group 3: MTX treated group. On the other hand, the liver sections showed the normal hepatic architectures with addition of NAC with MTX in group 4.

Conclusion: The present study showed that NAC has a good protective effect against the hepatic damage and genotoxicity induced by MTX in male albino rats.

INTRODUCTION

Methotrexate was used as part of combination chemotherapy regimens to treat many kinds of cancers. Moreover, it has been used as a treatment for some autoimmune diseases, including Crohn's disease, psoriasis, psoriatic

arthritis, rheumatoid arthritis, ankylosing spondylitis, and scleroderma (Klareskog et al., 2004).

The mechanism of liver injury with methotrexate is believed to be through inhibition of RNA and DNA synthesis in the liver and producing cellular

arrest. Methotrexate is well known to cause elevations in serum aminotransferase levels, with high dose intravenous methotrexate, serum ALT levels can rise to 10 to 20 times the upper limit of normal (ULN) within 12 to 48 hours, on the other hand, with progress of time levels then fall rapidly to normal with only rare instances of jaundice or symptoms of liver injury. With long term use of low-to-moderate dose methotrexate therapy, elevations in serum ALT or AST values occur in 15 to 50% of patients. Approximately 5% of patients have elevations greater than twice normal and these abnormalities resolve rapidly with discontinuation or dose modification. Furthermore, long term therapy has been linked to development of fatty liver disease, fibrosis and cirrhosis (**Reuben, 2007**).

Long term therapy with methotrexate has been associated with development of fatty liver, hepatic fibrosis and, in rare instances, portal hypertension, symptomatic cirrhosis and cytogenetic damage. (**Chabner et al., 2011**).

N-acetyl-cysteine (NAC) is the acetylated form of L-cysteine. It has an impressive list of protective effects including: antioxidant activity, decrease of the biologically effective dose of carcinogens, anti-inflammatory activity, immunological effects, inhibition of progression to malignancy and metastasis, cytogenetic protective effects and protection from the adverse effects of chemopreventive and chemotherapeutic agents. (**Sklar and Subramaniam, 2004**).

A small pilot study of chronic hepatitis C gave a promise that the addition of NAC to conventional therapy with interferon- α might make

the treatment more effective, but a larger multicentre trial in Spain and Italy came to the opposite conclusion (**Selzner et al., 2003**).

METHODS

Chemicals used:

1. **Methotrexate:** It is manufactured by PfizerAustralia Pty Ltd. It was given intravenously in tail veins of rats in a daily dose of 2 mg/kg ($1/7$ LD₅₀).
2. **N-acetylcysteine:** It is manufactured by American International Chemical, Inc. It was given intravenously in tail veins of rats in a daily dose of 80 mg/kg ($1/14$ LD₅₀).

Animals used & Experimental

Design:

Forty, apparently healthy, adult male albino rats (150 \pm 10 gm body weight) were obtained from Animal house of Faculty of Medicine-Cairo University. They were housed in hygienic metal cages and kept in a clean well ventilated room. They were fed on standard laboratory diet and allowed free access to water. Rats were left for two weeks before commencement of the study to be acclimatized to lab conditions. All rats were weighed weekly in order to adjust the dose of drugs according to body weight. All doses were given once daily for 12 weeks. Blood samples were obtained at the end of the 4th, 8th and 12th weeks and were prepared for ALT levels and BAX gene expression values examination. By the end of the study; animals' samples were obtained for liver histopathological examination.

Animals were randomly classified into 4 groups:

Group1 (negative control): 10 rats were injected I.V. with 1ml distilled water once daily for 12

weeks.

Group 2 (positive control): 10 rats were supplemented with N-acetylcysteine in dose of 80 mg/kg body weight ($1/14$ LD₅₀) by intravenous route daily for 12 weeks.

Group 3: 10 rats were supplemented with methotrexate in dose of 2 mg/kg body weight ($1/7$ LD₅₀) by intravenous route daily for 12 weeks.

Group 4: 10 rats were supplemented with methotrexate in dose of 2 mg/kg body weight ($1/7$ LD₅₀) and N-acetylcysteine in dose of 80 mg/kg body weight ($1/14$ LD₅₀) by intravenous route daily for 12 weeks.

Biochemical Studies:

Blood samples were obtained at the end of the 4th, 8th and 12th weeks from the retro-orbital plexus using the capillary pipette method of **Halpern and Pacaud, (1951)**, centrifuged at 1800 r.p.m. and stored in -20 °C.

An alanine transaminase (ALT) activity is determined according to the method of (**Reitman and Frankel, 1957**).

DNA damage is determined by studying the Bax gene expression using the **Abcam's Human Baxin vitro ELISA (Enzyme-Linked Immunosorbent Assay) kit.**

Histopathological study:

Liver samples, obtained at the end of the experiment (the 12th week), were fixed in 10% formalin and processed for paraffin blocks. Sections of 4-5 microns were cut and stained by hematoxylin & eosin according to **Bancroft & Stevens, (1977)** and examined by light microscope. The sections were viewed and photographed on an Olympus light

microscope with attached photograph machine.

STATISTICAL ANALYSIS:

Data obtained from the biochemical analysis are represented in tables as Mean \pm Standard deviation (mean \pm SD). The One-Way ANOVA test was used for statistical analysis of data. The analysis was done using the SPSS-PC computer software package version 10 **Abacus Concepts (1989)**.

RESULTS

No difference was observed between the negative and positive control groups concerning the ALT levels.

At the end of the fourth week, the ALT level of the Methotrexate-treated group (group 3) increased about 3.46 times than that of the negative control group ($P < 0.000$). With the use of the N-acetylcysteine (group 4), the ALT level decreased significantly about 11.88% as compared to that of the Methotrexate-treated group, but still 3 times higher than that of the negative control group ($P < 0.000$). At the end of the eighth week, the ALT level of the Methotrexate-treated group (group 3) increased about 3.68 times than that of the negative control group ($P < 0.000$). With the use of the N-acetylcysteine-treated group (group 4), the ALT level decreased significantly about 23.3% as compared to that of the Methotrexate-treated group, but still 2.82 times higher than that of the negative control group ($P < 0.000$). At the end of the twelve weeks, the ALT level of the Methotrexate-treated group increased about 3.76 times than that of the negative control group ($P < 0.000$). With the use of the N-acetylcysteine (group 4), the ALT level decreased significantly by 34.7% as compared to

that of the Methotrexate-treated group (group 5) , but still it was about 2.45 times higher than that of the negative control group ($P < 0.000$).

A significant constant increase of the ALT level of the Methotrexate-treated group (group 3) was observed throughout the study. The level increased about 5% at the end of 8th week and became about 10.4% more at the end of 12th week as compared to its similarity of the 4th week. In the N-acetylcysteine-treated group (group 4), the ALT level decreased about 8.6% at the end of 8th week and became about 18% less at the end of 12th week as compared to its similarity of the 4th week-treated group (**Table 1**).

No difference was observed between the negative and positive control groups concerning the BAX levels.

At the end of the fourth week, the BAX level of the Methotrexate-treated group (group 3) increased about 6.5 times than that of the negative control group ($P < 0.000$). In the N-acetylcysteine-treated group (group 4), the BAX level decreased significantly about 23.1% as compared to that of the Methotrexate-treated group, but still it was about 5 times higher than that of the negative control group ($P < 0.000$). At the end of the eighth week, the BAX level of the Methotrexate-treated group (group 3) increased about 9.16 times than that of the negative control group ($P < 0.000$). With the use of the N-acetylcysteine (group 4), the BAX level decreased significantly about 45.45% as compared to that of the Methotrexate-treated group, but still 5 times higher than that of the negative control group ($P < 0.000$). At the end of

twelve weeks, the BAX level of the Methotrexate-treated group (group 3) was about 9.57 times higher than that of the negative control group ($P < 0.000$). With the use of the N-acetylcysteine (group 4) , the BAX level decreased significantly about 62.6% as compared to that of the Methotrexate-treated group, but it was 3.57 times higher than that of the negative control group ($P < 0.000$). A significant constant increase in the level of BAX of the Methotrexate-treated group (group 3) was observed throughout the study. The level increased about 20.8% at the end of 8th week and became about 48.3% more at the end of 12th week as compared to its similarity of the 4th week.

In the N- acetylcysteine-treated group (group 4), the BAX decreased about 14.2% at the end of 8th week and became about 28.5% less at the end of 12th week as compared to its similarity of the 4th week-treated group (**Table 2**). The histological sections of the liver of the negative control group (Figure 1) and positive control group (**Figure 2**) were normal.

The histological sections of the liver of the Methotrexate-treated rats (group 3) showed the presence of dilatation and congestion of the central veins, hepatic sinusoids, hepatic arteries and portal veins. The increased number of Kupffer cells and pyknosis of the hepatic nuclei was characteristic features of this group (**Figures 3&4**). The liver sections of N-acetylcysteine-Methotrexate treated group (group 4) showed dilated and congested hepatic sinusoids with better histopathological appearance than group 3 (**Figure 5**).

Table (1): Shows ANOVA one-way statistical analysis of the ALT levels (IU/L) in all studied groups throughout the experimental period in rats

Groups	ALT levels (IU/L)(mean±SD)		
	4 th week	8 th week	12 th week
Group 1	26.07±5.6* cd	25.77±6.82* cd	26.54±8.32* cd
Group 2	27.03±5.64* cd	26.33±5.57* cd	26.75±7.77* cd
Group 3	90.40±15.39* abd	94.95±15.86* abd	99.85±16.64* abd
Group 4	79.66±9.70* abc	72.77±12.31* abc	65.17±11.96* abc

*= statistical significant difference at $p \leq 0.05$

a = significant difference versus group 1 **b** = significant difference versus group 2

c = significant difference versus group 3 **d** = significant difference versus group 4

Group 1= Negative control.

Group 2= Rats received doses equal to $1/14$ of LD₅₀ of N-acetylcysteine.

Group 3= Rats received doses equal to $1/7$ of LD₅₀ of methotrexate.

Group 4= Rats received doses equal to $1/7$ of LD₅₀ of methotrexate & $1/14$ of LD₅₀ of N-acetylcysteine.

Table (2): Shows ANOVA one-way statistical analysis of the BAX Gene expression values in all studied groups throughout the experimental period in rats.

Groups	BAX gene (mean±SD)		
	4 th week	8 th week	12 th week
Group 1	0.14±.01* cd	0.12±.01* cd	0.14±.01* cd
Group 2	0.13±.01* cd	0.13±.01* cd	0.13±.01* cd
Group 3	0.91±.27* abd	1.10±.29* abd	1.34±.34* abd
Group 4	0.70±.16* abc	0.60±.16* abc	0.50±.16* abc

*= statistical significant difference at $p \leq 0.05$

a = significant difference versus group 1 **b** = significant difference versus group 2

c = significant difference versus group 3 **d** = significant difference versus group 4

Group 1= Negative control.

Group 2= Rats received doses equal to $1/14$ of LD₅₀ of N-acetylcysteine.

Group 3= Rats received doses equal to $1/7$ of LD₅₀ of methotrexate.

Group 4= Rats received doses equal to $1/7$ of LD₅₀ of methotrexate & $1/14$ of LD₅₀ of N-acetylcysteine.

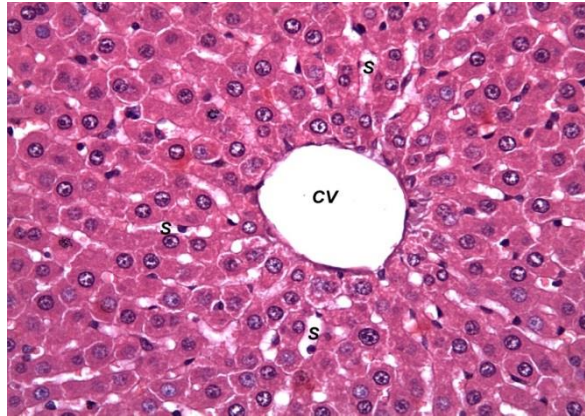


Figure (1): Photomicrograph of a cross section in the liver of a rat of the negative control group (group 1) showing normal hepatic sinusoid (S) near the central vein (CV) (H&E x 400).

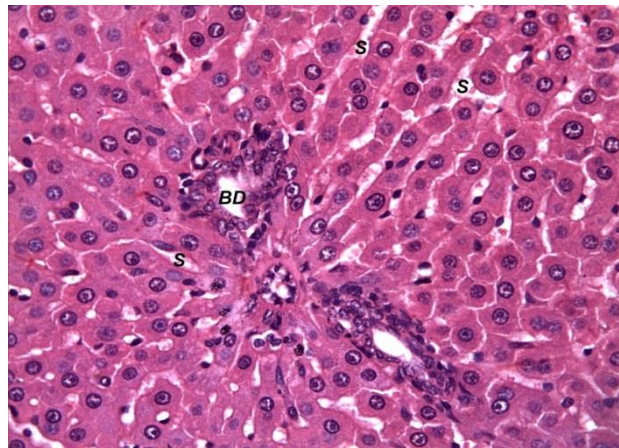


Figure (2): Photomicrograph of a cross section in the liver of a rat of the positive control group (group 2) showing normal hepatic sinusoid (S) near the bile duct (BD) (H&E x 400).

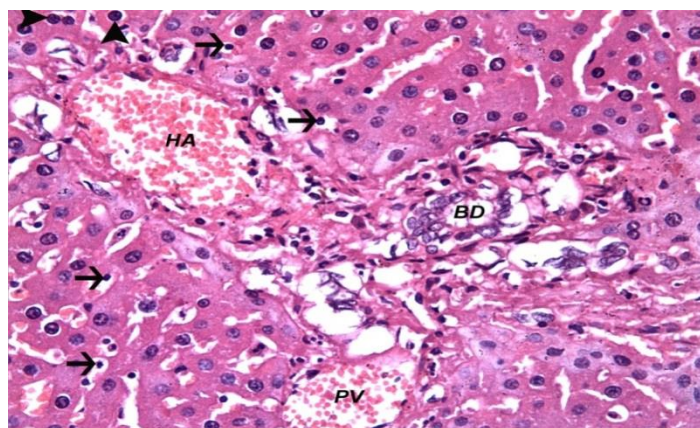


Figure (3): Photomicrograph of a cross section in the liver of a rat of the Methotrexate-treated group (group 3) showing a dilated congested hepatic artery and portal vein (PV). Pyknosis of hepatic nuclei (arrowheads) with increased number of Kupffer cells (arrows) are seen. Not bile duct (BD) (H&E x 400).

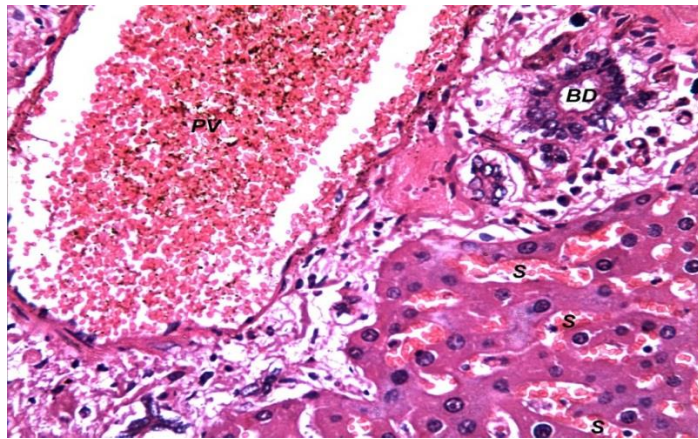


Figure (4): Photomicrograph of a cross section in the liver of a rat of the Methotrexate-treated group (group 3) showing a hugely dilated congested portal vein (PV) and dilated congested sinusoids (S) near the bile duct (BD) (H&E x 400).

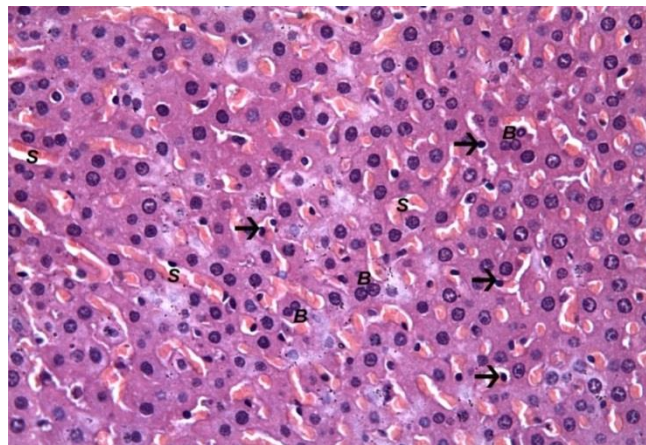


Figure (5): Photomicrograph of a cross section in the liver of a rat of the N-acetylcysteine- Methotrexate treated group (group 4) showing dilated and congested hepatic sinusoids (S). Note Kupffer cells (arrows) and binucleated hepatic cells (B) (H&E x 400).

DISCUSSION

The purpose of this study was to test the protective effect of N-acetyl cysteine on Methotrexate induced hepatic toxicity in albino rats.

In the current study, the ALT levels of the methotrexate-treated group (group 3) increased about 3.46, 3.68 and 3.76 times than that of the negative control group at the end of the 4th, 8th and 12th weeks of the study respectively ($P < 0.000$). **Aithal, 2011** reported that

with high dose intravenous MTX; serum ALT levels can rise to 10 to 20 times the upper limit of normal within 12 to 48 hours.

Similar results were recorded by **Aithal, 2011** who reported that with long term MTX therapy, elevations in serum ALT values occurred in 15 to 50% of patient. In addition, **Van Ede et al., 2001** concluded that methotrexate (MTX) can induce elevation of serum transaminases.

The previous biochemical findings that reflect deteriorated liver functions were confirmed by the corresponding hepatic cellular changes. The most characteristic feature of the examined hepatic sections of rats treated with MTX (group 3) in the current study was the presence of massive dilatation and congestion of central veins, hepatic sinusoids, portal veins and hepatic arteries.

The use of the N-acetylcysteine in addition to MTX in group 4 resulted in significantly decreased ALT levels at the end of the 4th, 8th and 12th weeks by 11.88%, 23.3% and 34.7% respectively as compared to that of the methotrexate-treated group ($P < 0.000$). Meanwhile, the liver sections of N-acetylcysteine-MTX treated rats (group 4) showed the normal hepatic architectures with nearly normal hepatic sinusoids and normal central veins. **Cetinkaya et al., 2006** stated that N-acetylcysteine (NAC) is a well-established cytoprotective drug that has proven efficacy against drug (acetaminophen overdose)-induced hepatotoxicity (**Cetinkaya et al., 2006**).

BAX is a member of the Bcl-2 gene family. BCL2 family members form hetero- or homodimers and act as markers of apoptosis which indicates DNA damage (**Rekha and Selvakumar, 2014**).

In the current study, the BAX gene expression value was used as a marker for genotoxic damage. In the methotrexate-treated rats (group 3), the BAX gene expression values showed a significant progressive increase in its values throughout the study in relation to the negative control group ($P < 0.000$). These results go hand in hand with those of **Criswell et al., 2003** who

reported that MTX could induce increased frequencies of micronuclei and chromosomal aberrations in both rats and humans. **Keshava et al., 1998** reported that MTX could induce a significant increase in percent of micronucleated and binucleated cells and percent of aberrant cells in V79 cells of Chinese hamster lung fibroblast cells which have been widely used in studies of DNA damage and DNA repair.

In the present study, with the addition of NAC to MTX in group 4, the Bax gene expression values significantly decreased 23.1 %, 45.45% and 62.6 % at the 4th, 8th and 12th weeks respectively as compared to that of the methotrexate-treated rats (group 3), but it was still about 5.92, 5 and 3.57 times higher than that of the negative control group at the end of the 4th, 8th and 12th weeks respectively. These results were similar to those recorded by **Reliene et al., 2004** who concluded that the antioxidant NAC counteracted the oxidative DNA damage-induced by MTX.

Farombi, 2006 reported that N-acetylcysteine has been shown to be an antigenotoxic agent, exhibiting protective effects against DNA oxidative damage by its antioxidant properties. **Balansky and Flora 2004** reported that NAC may decrease cytogenetical damage produced by exposure to cigarette smoke and mutagenic agents as urethane and 2-acetylaminofluorene in rodents, suggesting chemopreventive effects.

In conclusion, the current study showed that NAC has a good protective effect against the hepatic damage and genotoxicity induced by MTX in rats. So it may be useful to use NAC as an adjunctive supplementation to alleviate

the hepatic damage and genotoxicity induced by MTX in rats.

In the view of the present study, we recommend to conduct the same study on human beings in order to investigate the feasibility and suitability of the results of the present study on human beings.

REFERENCES

- Abacus Concepts (1989):** Super ANOVA. Abacus Concepts Inc, Berkeley, CA.
- Aithal, G. P. (2011):** Hepatotoxicity related to antirheumatic drugs. *Nat Rev Rheumatol*, 7(3): 139-50.
- Balansky RM, and De Flora S. (2004):** Interactions between N-acetylcysteine and sodium selenite in modulating the clastogenicity of urethane and 2-acetylaminofluorene in mice. *Int J Cancer*; 108:158–61.
- Bancroft, J.D. and Stevens, A. (1977):** Theory and practice of histological techniques Churchill Livingstone, New York, USA.
- Cetinkaya A, Bulbuloglu E, Kurutas EB, and Kantarceken B. (2006):** N-acetylcysteine ameliorates methotrexate-induced oxidative liver damage in rats. *Med Sci Monit.*; 12:BR274–BR278.
- Chabner BA, Bertino J, Cleary J, Ortiz T, Lane A, Supko JG, Ryan DP. In, Brunton LL, Chabner B, and Knollman B, eds (2011):** Antimetabolites, Folic acid analogs and Cytotoxic agents. In: Goodman & Gilman's the pharmacological basis of therapeutics. Laurence L. Brunton. New York McGraw-Hill Companies, Inc 11th Ed. pp. 1690-4.
- Criswell K.A., Krishna G., Zielinski D., Urda G.A., Juneau P., Bulera S. and Bleavins, M.R. (2003):** Validation of a flow cytometric acridine orange micronuclei methodology in rate. *Mutat. Res.*, 528, 1–18.
- Farombi EO (2006):** Genotoxicity of chloroquine in rat liver cells: protective role of free radical scavengers. *Cell Biol Toxicol*; 22:159–67.
- Halpern, B.N, and Pacaud, A. (1951):** C.R.Soc.Biol., Paris.
- Keshava, C., Keshava, N., Whong, W.Z., Nath, J. and Ong, T.M. (1998):** Inhibition of methotrexate-induced chromosomal damage by folic acid in V79 cells. *Mutat. Res.*, 397, 221–228.
- Klareskog L, van der Heijde D, de Jager JP, Gough A, Kalden J, Malaise M, Martin Mola E, Pavelka K, Sany J, Settas L, Wajdula J, Pedersen R, Fatenejad S, and Sanda M (2004):** Therapeutic effect of the combination of etanercept and methotrexate compared with each treatment alone in patients with rheumatoid arthritis: double-blind randomised controlled trial. *Lancet* 363: 675–81.
- Reitman, Sand Frankel, S. (1957):** Glutamic – pyruvate transaminase assay by colorimetric method. *Am. J. Clin. Path* 28: 56.
- Rekha, K. R. and Selvakumar, G. P. (2014):** Gene expression regulation of Bcl2, Bax and cytochrome-C by geraniol on chronic MPTP/probenecid induced C57BL/6 mice model of Parkinson's disease. *Chem Biol*

-
- Interact, 217: 57-66.
- Reliene, R., Fischer, E., and Schiestl, R. H. (2004):** Effect of N-acetyl cysteine on oxidative DNA damage and the frequency of DNA deletions in atm-deficient mice. *Cancer Res*, 64(15): 5148-53.
- Reuben A (2007):** Methotrexate controversies. In: Kaplowitz N, DeLeve LD, eds. *Drug-induced liver disease*. 2nd ed. New York: Informa Healthcare USA, pp. 683-705.
- Selzner N, Rudiger H, Graf R, and Clavien PA (2003):** Protective strategies against ischemic injury of the liver. *Gastroenterology*; **125:917–36**.
- Sklar GE, and Subramaniam M (2004):** Acetylcysteine treatment for non-acetaminophen-induced acute liver failure. *Ann Pharmacotherapy*.; 38:498–500.
- van Ede, A. E., Laan, R. F., Rood, M. J., et al (2001):** Effect of folic or folinic acid supplementation on the toxicity and efficacy of methotrexate in rheumatoid arthritis: a forty-eight week, multicenter, randomized, double-blind, placebo-controlled study. *Arthritis Rheum*, 44(7): 1515-24.

التأثير الوقائي لل ن اسيتايل سيستايين على التسمم الكبدي والتسمم الجيني المحدث بواسطة الميثوتريكسيت في ذكور الفئران البيضاء

هالة سعيد* ، أماني صلاح* ، علاء شهاب* ، أحمد الشطوري* ، أميمة الخولى** ، جورج نزيه** ، ولاء عوض***

*قسم الطب الشرعي والسموم الإكلينيكية و**قسم الكيمياء الحيوية -كلية الطب جامعة القاهرة،
***الزمالة المصرية -الصيدلة الإكلينيكية

الملخص العربي

يستخدم عقار الميثوتريكسيت على نطاق واسع في علاج الأورام الخبيثة وكثير من الأمراض الالتهابية وارتبط العلاج بالميثوتريكسيت بالتسمم الكبدي والتسمم الجيني.

وتهدف هذه الدراسة الى دراسة الأثر الوقائي لعقار ن اسيتايل سيستايين على التسمم الكبدي والتسمم الجيني المحدث بواسطة الميثوتريكسيت في ذكور الفئران البيضاء المسومة بعقار الميثوتريكسيت.

واجريت الدراسة على أربعين من ذكور الفئران البيضاء البالغة التي تزن حوالي 150 جرام تم الحصول عليها من بيت الحيوان كلية الطب جامعة القاهرة. وقد قسمت الفئران عشوائيا الى أربعة مجموعات المجموعة الأولى: المجموعة الضابطة السلبية وشملت عشرة فئران المجموعة الثانية: مجموعة ضابطة ايجابية وشملت عشرة فئران والمجموعة الثالثة : مجموعة الميثوتريكسيت وشملت عشرة فئران المجموعة الرابعة : مجموعة ن اسيتايل سيستايين مع الميثوتريكسيت وشملت عشرة فئران وتمت إعاشتهم في أقفاص معدنية في حجرة نظيفة جيدة التهوية وتغذيتهم على الغذاء المعمل المناسب والسماح لهم بالحصول على الماء وتركوا لمدة اسبوعين قبل البدء في الدراسة حتى يتأقلموا على ظروف المعمل وتم وزن جميع الفئران اسبوعيا وذلك لتعديل جرعات العقارات المستخدمة على حسب الوزن. وقد اخذت عينات الدم من الفئران في نهاية الاسبوع الرابع والثامن والثاني عشر لتقييم وظائف الكبد والسمية الجينية وعند نهاية الدراسة تم تشريح الفئران للحصول على عينات نسيجية كبدية لإجراء الدراسات النسيجية الباثولوجية.

في هذه الدراسة لوحظت زيادة مطردة في مستويات إنزيم الانين ترانسفيريز في المجموعة الثالثة التي حقنت بالميثوتريكسيت مقارنة بالمجموعة الضابطة السلبية عند الاسبوع الرابع والثامن والثاني عشر من الدراسة. وعند اضافة ن اسيتايل سيستايين مع الميثوتريكسيت في المجموعة الرابعة لوحظ انخفاض ملحوظ في قيمة إنزيم الانين ترانسفيريز مقارنة بالمجموعة الثالثة.

بالنسبة لقيمة التعبير عن الباكس جين لوحظت زيادة ثابتة في قيمة التعبير عن الباكس جين في مجموعة الميثوتريكسيت المجموعة الثالثة مقارنة بالمجموعة الضابطة السلبية عند الاسبوع الرابع والثامن والثاني عشر من الدراسة. وعند اضافة ن اسيتايل سيستايين مع الميثوتريكسيت في المجموعة الرابعة لوحظ انخفاض ذو دلالة احصائية في قيمة التعبير عن الباكس جين مقارنة بالمجموعة الثالثة؛ مجموعة الميثوتريكسيت.

ولقد تم تأكيد هذه التغيرات الكيميائية الخاصة بإنزيم الانين ترانسفيريز عن طريق الدراسات النسيجية للكبد حيث اظهرت اتساع واحتقان الاوردة الكبدية المركزية والشرايين الكبدية والاوردة الكبدية البابية وزيادة في عدد خلايا كابفر وتغلظ في نويات الخلايا الكبدية في مجموعة الفئران التي حقنت بالميثوتريكسيت. وعلى العكس من ذلك اوضحت الدراسات النسيجية الكبدية عند اضافة ن اسيتايل سيستايين الى الميثوتريكسيت في المجموعة الرابعة تحسن في شكل النسيج الكبدي مقارنة بالمجموعة الثالثة.

وخلصت الدراسة الى ان تعاطى ن اسيتايل سيستايين بالتزامن مع الميثوتريكسيت قد ادى الى تحسن ملحوظ في وظائف الكبد وانخفاض في معدل التعبير عن جين باكس وأدى كذلك الى تحسن في التغيرات الهستولوجية في الكبد وتوصى الدراسة بتعاطي ن اسيتايل سيستايين في المرضى الذين يخضعون للعلاج بالميثوتريكسيت لتخفيف سميته الكبدية والجينية.