

The Journal of American Science

ISSN 1545-1003

Volume 6 - Number 10 (Cumulated No. 31), October 1, 2010, ISSN 1545-1003

Marsland Press, Michigan, The United States

First record of a mixed viral infection among cultured common carp in Egypt

M.K. Soliman¹, Safinaz G. Mohamed², Mona S Zaki³ and W.D⁴ Salah

¹ Dept. of Poultry and Fish Diseases, Fac. of Vet. Med. El Bostan, Alexandria Univ. Egypt.

² National Institute of Oceanography and Fisheries, Alexandria Branch, Egypt

³ Head of Dept. of Hydrobiology, Veterinary Research Division, National Research Center, Cairo Egypt.

⁴ Dept. of Microbiology, Fac. of Agriculture, Cairo University, Egypt
Elzahra2002@hotmail.com

Abstract: The commercial production of fish is a rapidly growing industry. Concurrent with this growth, fish culturing is expanding worldwide, especially in Egypt. One of the main factors affecting fish production and efficiency is disease that results from both viral and bacterial infections. In Egypt, spring viremia of carp (SVCV) was recently reported, and it causes severe economic losses among cultured common carp. In the present study, a mixed viral infection was recorded during an outbreak in cultured common carp. Primary isolation was achieved using a common carp ovary cell line. The first isolated virus was identified as SVCV by immunohistochemistry with the aid of a specific monoclonal antibody, as well as by the presence of hecck shapes upon electron microscopic examination. The second virus was identified as *Rhabdovirus carpio* (RHC), which presents in the form of electron-dense particles with a clear halo. Of 60 examined common carp, 20 fish were positive for SVCV, and two displayed mixed infections (SVCV and RHC). Cytopathic effects on the carp's ovaries were assessed, and histopathological examinations were carried out. This mixed viral infection is considered to be the first ever recorded in Egypt. [Journal of American Science 2010;6(10):879-885]. (ISSN: 1545-1003).

Keywords: Spring viremia of carp, Viral infection, Rhabdovirus carpio

1. Introduction

Aquaculture has become a major contributor to total fish production in Egypt. Therefore, the aquaculture sector has expanded dramatically during the past few years. As a result, aquaculture production increased from 139,400 tons in 1998 to 461,535 mt in 2005, representing 58% of the total fish production in Egypt [9].

Tilapias, carps and mullets comprise over 95% of total aquaculture production [9]. Typically, these fish species are cultured semi-intensively in polyculture systems [8]. A number of disease outbreaks have recently been recorded in many fish farms throughout the country. The spring viremia of carp virus (SVCV) and *Rhabdovirus carpio* (RHC) are the most important viral diseases affecting cultured fishes, causing high mortality (30-60%), especially among common carp and silver carp [13]. It has been reported that SVCV and a newly isolated strain of RHC cause high mortality in carp, both in acute and chronic forms, during the spring of the year [13, 17, 1].

However, studies on the effects of viral diseases on wild and farmed fishes have been limited, particularly in tropical and subtropical regions of the world. This is partially due to the higher water temperature and very short life span of fish viruses in

the aquatic environment. The inaccessibility of tissue culture techniques and cell lines for examination of fish viruses and their high cost additionally make such studies more difficult [16]

Thus, viral fish diseases in Egypt have not received sufficient attention. The prevalence of these viruses remains unknown, as does their impact. Very few studies have been conducted on SVCV isolated from carp species in Egypt [17, 1], and it is clear that more work is urgently needed on the identification, isolation, description, symptoms and treatment of the major viral diseases infecting cultured and wild fishes in Egypt.

To determine the source(s) of the lesions and mortality affecting cage-cultured common carp (*Cyprinus carpio* L) during a disease outbreak in a private fish farm in Kafr-El-Shikh governorate in Egypt, we isolated and characterised SVCV and *Rhabdovirus carpio*.

2. Material and Methods

2.1. Fish sampling and examination

Twenty naturally infected common carp with an average body weight of 300±5 g were collected from a private cage fish farm in Kafr El-Shikh governorate, Egypt. The fish were transported alive

in plastic bags containing oxygenated water to the Fish Disease Laboratory, Department of Poultry and Fish Diseases, Faculty of Veterinary Medicine, Alexandria University, Egypt. Immediately after arrival, the fish were subjected to clinical, bacteriological, mycological and parasitological examinations according to [5] and [15].

2.2. Virus isolation

Samples from the fish's liver, kidney, spleen, muscles, intestine, heart, brain and gas bladder were collected, mixed with sterile sand, ground in a sterile mortar and then frozen and thawed three times. Three drops each of 1000 IU/ml mycostatin, 1000 mg/ml penicillin, streptomycin and 500 IU/ml nystatin were added to the supernatant. The supernatant was collected in small flasks, filtered through 0.22- μ m millipore filters and stored at -20°C until use [5, 17].

2.3. Electron microscopic investigation

Samples for electron microscopic examination were prepared from collected organs and fixed in glutaraldehyde as described by [12].

2.4. Immunohistochemical studies

Immunohistochemical studies were carried out on samples preserved in formalin paraffin by using an SVCV monoclonal antibody and anti-mouse IgG, according to [14] and [1].

2.5. Histopathological examination

Specimens from brain, liver, kidney, muscles, intestine and gas bladder were collected from infected fish, fixed in formalin-buffered with 10% saline and used for histopathological examination, according to [7].

2.6. Tissue culture

Cell lines were prepared from the ovary of a mature common carp according to the steps described by [10]. The supernatant was added to tissue culture to assess the cytopathic effect (CPE), as reported by [19].

3. Results

3.1. Clinical signs

The clinical signs and post-mortem lesions of naturally infected common carp included skin darkening, tail and fin rot, ulceration, haemorrhage on the abdomen, ascites and redness of the isthmus and head region. Postmortem lesions also included congestion of all internal organs, distended gall bladder, haemorrhagic gas bladder, exophthalmia and swelling of the anal opening (Fig 1, 2, and 3). Moreover, the mortality rate was ~5% in the infected

farm.

3.2. Bacteriological, mycological and parasitological investigation

The results of tests for bacteriological, mycological and parasitological infections were negative in all fish examined.

3.3. Electron microscopic examination

The infected fish samples contained virions of two different shapes: a helek shape (which indicates the occurrence of SVCV) and another type arranged in the form of electron-dense particles with a clear halo (Core), which is indicative of *Rhabdovirus carpio*. Moreover, ultra-structural changes in the liver included vacuolated cytoplasm lacking organelles and undifferentiated cytoplasmic inclusions resembling virus-like particles. The viral particles replaced the cytoplasmic organelles. The euchromatin-like inclusions had electron-dense particles with a clear halo (Core). Aggregates of both viral particles in the cytoplasm could be identified by the presence of envelopes (virions).

The kidneys showed vacuolated nuclei with dark dense bodies of virions attached to the nuclear envelope and vesicles surrounded the virions and virus-like particles. Moreover, brain tissue showed intracytoplasmic inclusion bodies lacking a myelin sheath. Under high magnification, there were different sizes and shapes of virus-like particles consisting of capsid particles with a visible core and homogenous electron-dense empty capsids, which indicated a mixed infection. Large quantities of virus nucleocapsids with viral matrix precursor materials were found. In the brain, tunica granulosa cell nuclei formed intra-cytoplasmic inclusion bodies, and vacuolated cytoplasm was observed. The viral particles replaced the cytoplasmic organelles, whereas the myelin sheath was absent (Figs. 4, 5 and 6). The air bladders of the infected fishes contained intracytoplasmic inclusion bodies with viral nucleocapsids.

3.4. Immunohistochemistry

Immunohistochemical examination with an anti-SVCV monoclonal antibody was used on paraffin-embedded sections of various organs of the common carp. The intensity of infection was recorded according to the degree of positivity as follows: -ve, negative; ++ve, moderate; +++ve, marked; ++++ve, strong and +++++ve, intense.

Among the hepatopancreatic cells in the liver, anti-SVCV detection revealed marked positive signs of infection in all exocrine pancreatic cells. Positive signals were also detected in the kidney, with the

proximal tubular cells exhibiting a large amount of virus precipitate. Moreover, there was marked positivity in the epithelial cells and moderate positivity in the sub-mucosa of the air bladders. The brain showed strong positivity in granulosa cell membranes, and an intense signal was found in the nerve fibres. In muscle tissue, the immunohistochemical detection of SVC antigen revealed marked positive brown granulation in most of the myofibrillar cells and in most of the cloudy swelling muscle fibres (Figs. 7 and 8).

3.5. Cell line formation and CPE due to viral infection

Cultured ovarian cells formed a monolayer sheet by 48 h post-incubation; the cells were spindle-shaped. The number of cells increased rapidly, and a confluent monolayer sheet was formed within 48-72 h (Fig. 9). The CPE occurred within 3-4 days post-infection, wherein cells changed from spindle-shaped to round. They then detached and formed plaque-like structures, leading to the death and detachment of these cells. The degree and severity of CPE increased with increasing concentrations of the virus and decreasing time for the virus to cause CPE, and vice versa (Fig. 10).

3.6. Histopathological changes in infected fishes

The histopathological changes induced through natural infection of common carp by the two isolated viruses (SVCV and RHC) were degeneration and necrosis of hepatic cells, congestion of the liver sinusoids and portal tract, vacuolated cytoplasm and appearance of the nuclei of hepatopancreatic cells in the liver.

In the kidney, degenerative hematopoietic tissue, necrosis and fibrosis were recognised in renal tubules and glomeruli. The brain showed dissolution of neural substance through the loss of stainable substances within the cytoplasm and chromatolysis. The nuclei were shifted to eccentric positions against the margins of the cells. Severely congested blood vessel aggregations were found around distended gas bladders. Moreover, the intestine showed a mild inflammatory reaction and haemorrhaging with oedema of the submucosa. In muscle, basophilic nuclei appeared, myofibrillar striations disappeared, and the tissues showed hyaline degeneration, cloudy swelling of the muscular fibres and pale eosinophilic myofibrils (Figs. 11, 12 and 13).




Fig (1).

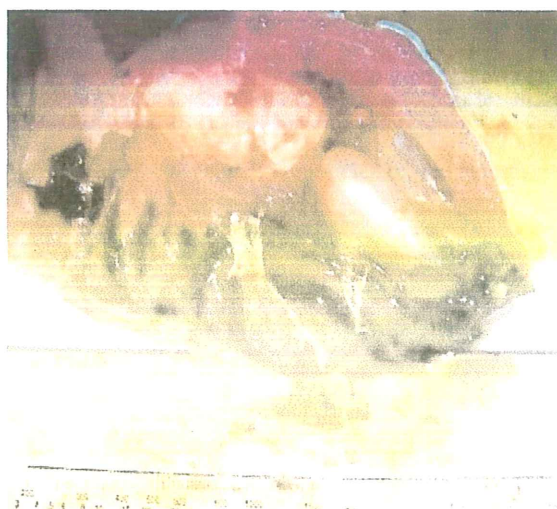

Fig (2).

Fig (1). Naturally infected Common carp showing congestion of head region and eyes.

Fig (2). Naturally infected Common carp showing severe congestion of internal organ.

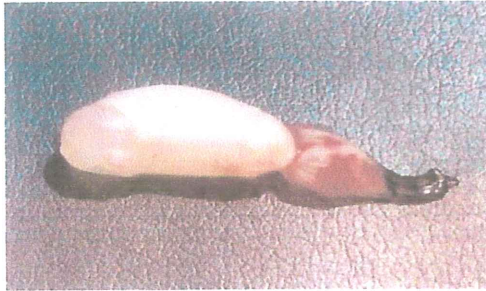

Fig (3).




Fig (4).

Fig (3) Naturally infected Common carp showing hemorrhagic gas bladder surface.

Fig (4). Electron micrograph of Common carp kidneys showing rounded form of Rhabdovirus carpio (L) and helices form of SVCV, indicating mixed-viral infection. (Formalin+ PTAX40,000).



Fig (5).




Fig (6).

Fig (5). Electron micrograph of Common carp liver, with high magnification showing the intracytoplasm inclusion bodies. Most virion are encapsulated electron dense particle with clear core(x). (Formalin+ PTAX40,000).

Fig. (6). Electron micrograph of Common carp brain, with para-crystalline of virus like particles in the cytoplasm. (PTAX 20,000).

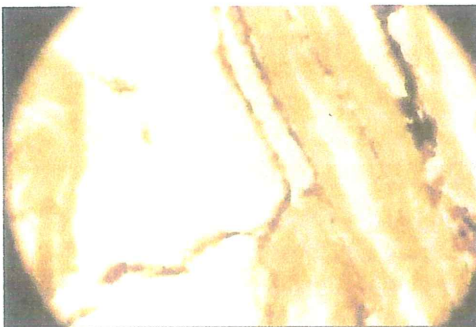

Fig (7).

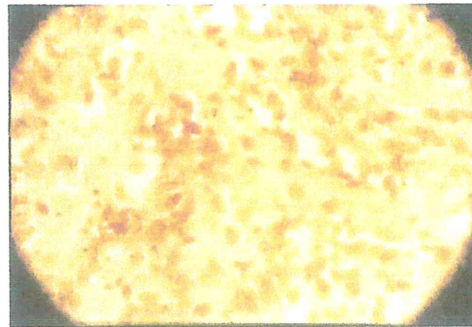


Fig (8).

Fig (7). Paraffin section of air-sacs of Common carp, naturally infected with virus, showing marked positive anti-SVCV in both layer of gas bladder. (DAB X 400).

Fig (8). Paraffin section of Common carp brain, naturally infected with virus, showing strong positive of anti-SVCV in granulosa membrane and nuclei (arrows) as well of blood capillary and nerve connective tissue. (X) (DAB X 400).




Fig (9).

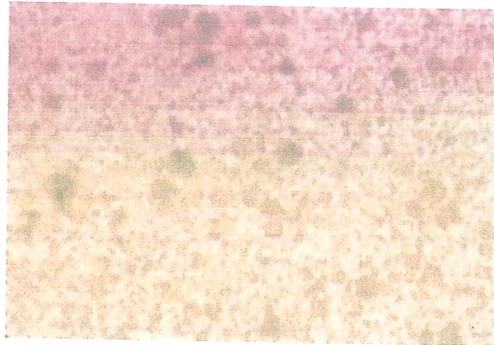


Fig (10).

Fig (9). Normal cell line after 72 hrs post-incubation.

Fig. (10). Severe degree of CPE due to injection of virus (10^{-1}) typified by rounding, detached and dead cells with clear plaque formation.




Fig (11).

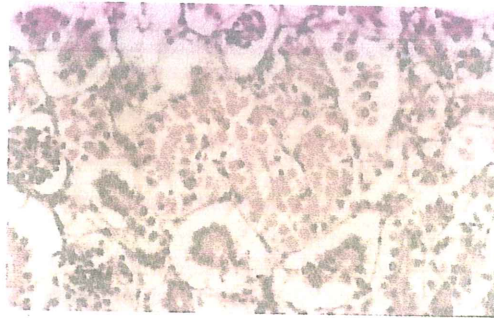


Fig (12).

Fig (11). Gills of naturally infected Common carp showing marked swelling of a primary filament with goblet cells hyperplasia . The neighboring filament was necrotic . H, E. (X 250).

Fig (12). Kidney of naturally infected Common carp showing severe hyaline droplet degeneration of some convoluted tubules with high eosinophilic infiltration.

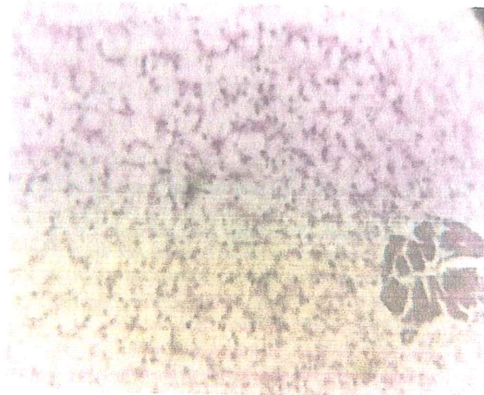


Fig (13)

Fig (13). Hepatopancreas of naturally infected Common carp showing diffuse hydropic degeneration of the hepatocytes. H, E. (X 160).

4. Discussions

This study assessed the clinical signs and post-mortem lesions in common carp during a disease outbreak. We observed respiratory and nervous manifestations, congestion, ulcerated gill covers and abdomens and redness of the tail, fins and mouth. Infected fish exhibited haemorrhagic spots on the eyes, with clear exophthalmia, inflammation of the anal opening, gill paleness and skin darkening. The darkening of the skin may have been due to viral stimulation of spleen melanocytes leading to an increase in melanin pigment secretion, as suggested by [16]. The melanin is deposited under the skin causing the surface of the body to darken.

Post-mortem lesions occurred in the form of redness, haemorrhaging of the gas bladder and congestion of all internal viscera. The nervous manifestations that appeared in the infected fish may have been due to the destructive effect of the viruses on the internal organs, especially the brain, as reported by [17].

Tissue culture inoculation confirmed the presence of the virus by the appearance of cellular vacuolation in ovary cell culture within 3–4 days post-infection by samples from the infected common carp [5].

The electron microscope is an important tool for the identification and diagnosis of SVCV and RHC, as suggested by [3]. For example, [5] used electron microscopy (EM) to show that the virus particles in common carp were extra-cellular bullet-shaped bodies with a diameter of approximately 70 nm. In the present study, EM examination revealed that the liver was characterised by vacuolated cytoplasm and undifferentiated inclusion-like viral particles in the cytoplasm. Therefore, EM examination confirmed the SVCV and RHC infection in these common carp.

The presence in infected tissues of both electron-dense inclusions and a clear halo (core), which may indicate the presence of RHCV, together with the bullet shape of Rhabdoviruses suggests that the outbreak in the present study may have been caused by a mixed viral infection rather than a single viral infection.

The severity of infection and concentration of SVCV in the different tissues of infected fish that we observed in immunohistochemical studies agrees with the results of [6]. They found that brown-labelling granules depended mainly on the level of antigen antibody reaction (SVCV antigen reacts with the SVCV antibodies). They attributed this to the destructive action of the virus.

Respiratory manifestations are attributed to SVCV causing paleness of the gills and destroying gill lamellae [16]. The other PM lesions may be attributable to inhibition of protein and DNA synthesis by the virus, as well as destruction of the cells of the internal organs, as suggested by [4].

The congestion of the internal organs may have also been caused by SVCV and RHCV, which are intra-cellular microorganisms mainly affecting the tunica intima of blood vessels. This leads to oozing of blood outside the blood vessels and causes the haemorrhagic appearance and petechial haemorrhaging. Moreover, the distance between blood vessels cells increases, leading to congestion, ascites, exophthalmia and haemorrhaging in all internal organs, especially the haemobiotic organs [16].

Moreover, [2] and [11] report that the clinical signs of viral infection are external and internal haemorrhaging, peritonitis and ascites. They also state that fish infected with SVCV show degradation of kidney, spleen and liver tissues, leading to haemorrhaging, loss of the water-salt balance and impaired immune responses.

The infected fish in the present study showed histopathological changes in various organs in the form of pyknosis, with hepatic cell atrophy and reduced eosinophilic granules in the cytoplasm. Moreover, there was vacuolar degeneration and red-coloured nuclei, which indicate virus infection. The degeneration of haemobiotic tissues, renal tubule necrosis and congestion of blood vessels in the air sacs may be attributed to the destructive effect of the two viruses, as reported by [18].

5. Conclusion

Our results suggest that the clinical signs and mortality of cultured common carp in an infected farm may be due to a mixed viral infection, as evidenced by both electron microscopic and immunohistochemical examinations. To the best of our knowledge, this is the first record of a mixed viral infection among cultured common carp in Egypt and likely in the entire Middle East.

References

1. Abo-Essa, M.I., 2007. Studies on Spring viremia of carp in cultured fresh water fish. M.V.Sc Thesis, Fac. Of Vet. Med., Alexandria University.
2. Ahne, W., Jorklund, H.V., Essbauer, S., Fijan, N., Kurath, G., Winton, J.R., 2002. Spring viremia of Carp (SVC). *Dis. Aquat. Organ.* 52,

- 261-272.
3. Bekesi, L., Szabo, E., 1979. A Rhabdovirus isolated from carps in Hungary. Experimental infection of Carps and resistance of the virus. *Acta Microbiol Acad. Sci. Hung.* 26, 193 –207.
 4. Bjorklund, H. V., Johansson, T. R., Rinne, A., 1997. Rhabdovirus-induced apoptosis in a fish cell line is inhibited by a human endogenous acid cysteine proteinase inhibitor. *J. Virol.* 71, 5658-5662.
 5. Bucke, D., Finlay, J., 1979. Identification of Spring viraemia in Carp (*Cyprinus carpio* L) in Great Britain. *Vet. Rec.* 27, 69-71.
 6. Clerx, J. P.; Hozink A.S; Marian. C. and Osterhaus, A. D. M. E., 1978. Neutralization and enhancement of infectivity of Non-salmonid Fish Rhabdoviruses by rabbit and Pike immune sera. *J. gen. Virol.* 40: 297 – 308.
 7. Culling, C.F., 1983. Handbook of histopathologic and histochemical staining. 3rd Edn., Butterworth London, pp 235-271
 8. El-Sayed, A.-F.M. 2007. Analysis of feeds and fertilizers for sustainable aquaculture development in Egypt. In M.R. Hasan (ed.) Study and analysis of feeds and fertilizers for sustainable aquaculture development. FAO Fish. Tech. Pap. 497, Rome.
 9. General Authority for Fisheries Resourced Development (GAFRD), 2007. Fisheries Statistics Year Book.
 10. Habashi, Y.Z., 1980. Preparation of monolayer cell culture from the gonads of freshwater fish "Tilapia nilotica" of Egypt. *J. Egypt. Vet. Med. Assoc.* 3, 27-33.
 11. Hoffmann, B., Schutz, H., Mettenleiter, T.C., 2002. Determination of the complete genomic sequence and analysis of the gene products of the virus of Spring viremia of Carp, a fish rhabdovirus. *Virus Res.* 84, 89-100.
 12. Jerome, G., Raphaella, L.G., Choubert, D., Dominique, T., 1995. Flumequine residue depletion in rainbow trout maintained at two water temperatures after oral administration. *J. Vet. Pharmacol. Therap.* 11, 446-450.
 13. Kim, D.H., Oh, H.K., Eou, J.I., Kim, S.K., Oh, M.J., Nam, S.W., Choi, T.J., 2005. Complete nucleotide sequence of the hiram rhabdovirus, a pathogen of marine fish. *Virus Res.* 107, 1-9.
 14. Kiernan, J. A., 2003. Histological and histochemical methods. Theory and practice. 3rd Ed. Butterworth London, Chapter 19: 391 – 418. In *sight RNA. Nature* 16 – 9-2004 Vol.43 i. No. 7006.
 15. Morrison, A.R., 1981. Methods in clinical chemistry. St. Louis, Washington D. C., Toronto. Chapter 10: 114 – 138. *Biochemistry* 1982 Vol.111. No.1251.
 16. Post, G. W., 1987. Textbook of fish health J. F. H. publication, Inc Ltd. 211 West Syvent Neptune City NJ 00753. pp 215-221
 17. Saad, T.T., 2005. Studies on Spring viremia of carp in cultured common and silver carp in Egypt. Ph.D. thesis, Fac. of Vet. Med. Alexandria University.
 18. Way, K., Bark, S.J., Longshaw, C.B., Denham, K.L., Dixon, P.F., Feist, S.W., Gardiner, R., Gubbins, M.J., Le Deuff, R.M., Martin, P.D., Stone, D.M., Taylor, G.R., 2003. Isolation of a rhabdovirus during outbreaks of disease in Cyprinid fish species at fishery sites in England. *Dis. Aquat. Organ.* 57, 43-50.
 19. Zhang, Y., Congleton, J.L., 1994. Detection of infectious haematopoietic necrosis (IHN) virus in rearing units for Steelhead and during IHN epizootics. *J. Aquat. Animal Health* 6, 281-287.

8/12/2010