

ORIGINAL ARTICLE

Ultrasound elastography in the diagnostic evaluation of indeterminate thyroid nodules



Sherif Fathy Abdelrahman ^{a,*}, Fatma Hassan Ali ^b, Mohsen El-Sayed Khalil ^a,
Manal Roshdy El Masry ^c

^a Radiology Department, Faculty of Medicine, Cairo University, Cairo, Egypt

^b National Institute of Liver & Tropical Medicine, Cairo University, Cairo, Egypt

^c Internal Medicine Department, Faculty of Medicine, Cairo University, Cairo, Egypt

Received 4 December 2014; accepted 8 May 2015

Available online 1 June 2015

KEYWORDS

Elastography;
Ultrasound;
Thyroid gland;
Indeterminate;
Thyroid nodules

Abstract *Objective:* To assess the accuracy of US-elastography in the evaluation of indeterminate thyroid nodules, using the cytological/histopathological analysis as the reference.

Patients and methods: Fifty patients with 73 indeterminate thyroid nodules were enrolled in this prospective study. They were examined using US features and elastography scoring according to Rago criteria; then, fine-needle or postoperative biopsy was taken and diagnosis was made.

Results: Fifty patients with 73 indeterminate thyroid nodules were included, 16 nodules were malignant and 57 were benign. On US elastography, all 57 nodules diagnosed as benign had a score of 1–3, while 15 of 16 (93.75%) diagnosed as carcinoma had a score of 4–5, with 93.3% sensitivity, 100% specificity and 97.8% accuracy. Combined US findings with elastography revealed that hypoechoogenicity/score 4–5 was most predictive of malignancy with sensitivity 80%, specificity 100%; and accuracy 93.4%. The strain ratio cutoff value for malignant nodules was determined as 2.3. Five nodules out of sixteen had SR between 2.31 and 4 (sensitivity 96% and specificity 83%).

Conclusion: Thyroid nodules with suspicious US criteria can be evaluated by US elastography that seems to be a useful addition for the assessment of such indeterminate nodules. It may reduce FNAC or select a nodule for aspiration.

© 2015 The Authors. The Egyptian Society of Radiology and Nuclear Medicine. Production and hosting by Elsevier B.V. This is an open access article under the CC BY-NC-ND license (<http://creativecommons.org/licenses/by-nc-nd/4.0/>).

1. Introduction

Nodular thyroid disease is a common finding where the majority of thyroid nodules are benign; however, 15–30% of thyroid nodules are classified as indeterminate or suspicious for

malignancy (1). The recommended treatment of indeterminate lesions remains the surgical excision of the nodule (2).

Ultrasonographic (US) examination is an accurate method for detecting thyroid nodules, but its use in differentiating between benign and malignant thyroid nodules is relatively low (3). Fine-needle aspiration (FNA), has a high sensitivity and specificity in differentiating malignant from benign thyroid lesions (4). The major limitation of FNA cytology is 10–20% are indeterminate (i.e. unable to discriminate between

* Corresponding author.

Peer review under responsibility of Egyptian Society of Radiology and Nuclear Medicine.

benign follicular adenoma and thyroid carcinoma, either follicular thyroid cancer or the follicular variant of a papillary thyroid carcinoma) (5). Presurgical selection by fine-needle aspiration cytology is limited by the finding of indeterminate diagnosis in approximately 10 to 20% of cases (2). A surgical approach is generally recommended in such nodules even if more than 70% of them are benign at histological examination, so excisional biopsy is the best for differentiation (6).

The newly developed real-time ultrasound elastography (USE) has been previously applied to differentiate malignant from benign lesions and to determine tissue stiffness and strain information noninvasively. The principle of USE is to acquire two ultrasonographic images (before and after tissue compression by the probe), and to track tissue displacement by assessing the propagation of the US beam by a dedicated software. The US elastogram was displayed over the B-mode image in a color scale that ranged from red, for components with greatest elastic strain (i.e. softer components), to blue for those with no strain (i.e. harder components) (7).

2. Patients and methods

2.1. Study patients

The study included 50 consecutive patients with indeterminate thyroid nodules (41 women; median age 46.5 yr; range 19–73 yr/9 men; median age 57.5 yr; range 37–78) seen from May 2012 and August 2013. They were selected according to our inclusion criteria.

Inclusion criteria: Suspicious nodules for malignancy were included in the study with ultrasound criteria of being solid or predominantly solid nodules (cystic portion \leq 50%), having hypoechoic pattern, with a predominant vertical development and internal microcalcifications.

Patients with nodules larger than 40 mm, purely cystic without solid components, and shell-calcified nodules that could cause color-coding problems were excluded from the study. Sixteen nodules were malignant and 57 were benign. The final diagnosis was based on the cytology reading in those who did not have surgery and the histopathology reading in those who had surgery.

2.2. Technique of examination

Thyroid US and US elastography were performed using a real-time ultrasound (Toshiba Aplio-XG machine using 10–13-MHz. linear transducer).

The sonographic examinations were performed in three steps. B-mode ultrasound was performed first, then in the second step color Doppler was performed and the third step was real-time sonographic elastography using the same probe during the same examination.

The patient was positioned on his back with the neck is hyper-extended over a pillow and the chin is elevated. The transducer was applied to the neck using adequate amount of gel. Starting the examination with B-mode imaging, during B-mode US, thyroid gland lesions were identified and a region of interest for elastography was identified. A careful evaluation of the following US parameters was performed on all thyroid nodules: echogenicity, presence or absence of the halo sign (a hypoechoic rim surrounding a nodule is comprised of a

pseudocapsule that is caused by fibrous connective tissue), spot microcalcifications (presence of hyperechoic spots less than 2 mm, without acoustic shadowing), and color flow Doppler pattern that was defined as (type I) the absence of blood flow, (type II) perinodular and absent or slight intranodular blood flow, and (type III) marked intranodular and absent or slight perinodular blood flow (8).

Shear wave elastography was performed, the probe was placed on the neck with light pressure and a box was highlighted by the operator that included the nodule to be evaluated, and compression was performed repeatedly in a vertical direction with light pressure and was followed by decompression. The pressure must be applied (and released) with a continuous movement exerted at a right angle to the proximal plane of the lesion, and care should be taken to avoid lateral displacement of the probe. A scale is available on the machine to measure whether adequate compression was used (Figs. 1–3).

In the case of multiple nodules, each nodule is evaluated separately and the strain value ratio (strain index) of thyroid nodule to normal thyroid parenchyma or muscle was calculated.

The US elastogram was displayed over the B-mode image in a color scale that ranges from red, for components with greatest elastic strain (i.e. softest components), to blue for those with no strain (i.e. hardest components).

The elastograms thus obtained were classified according to the scores by Rago et al. (9). Elasticity according to Rago et al. (thereafter, Rago criteria) originated from the elastography scale by Ueno et al. (10) and was applied to thyroid nodules and elastography scores were classified on a scale of 1–5. Nodules with Rago scores of 4 and 5 were classified as suspicious for malignancy (Fig. 4).

Thyroid nodule can be evaluated by the following:

2.2.1. Elasticity scores in thyroid nodules

That can be given based on the following criteria (11):

1. Low stiffness over the entire nodule; the entire nodule is evenly shaded green, as is the surrounding thyroid tissue.
2. Low stiffness over most of the nodule; the nodule is almost completely green but with some blue spots.
 - 3a. Low stiffness at the periphery, and high stiffness in the center of the nodule; the central part of the nodule is blue; the peripheral part is green.
 - 3b. High stiffness over most of the nodule; the nodule is almost completely blue but with some green spots.
4. High stiffness over the entire nodule; the entire nodule is evenly shaded blue.
5. High stiffness over the entire nodule and surrounding tissue; both the nodule and surrounding area are blue.

2.2.2. Strain ratio

Strain represents the amount of deformation; thus, stiff tissue shows less strain than softer tissue. A thyroid lesion may have different levels of stiffness within it, depending on the cellularity and the composition of the nodule. Information from these elastograms helps to assess the relative stiffness of the lesion compared with its surrounding tissues and within itself.

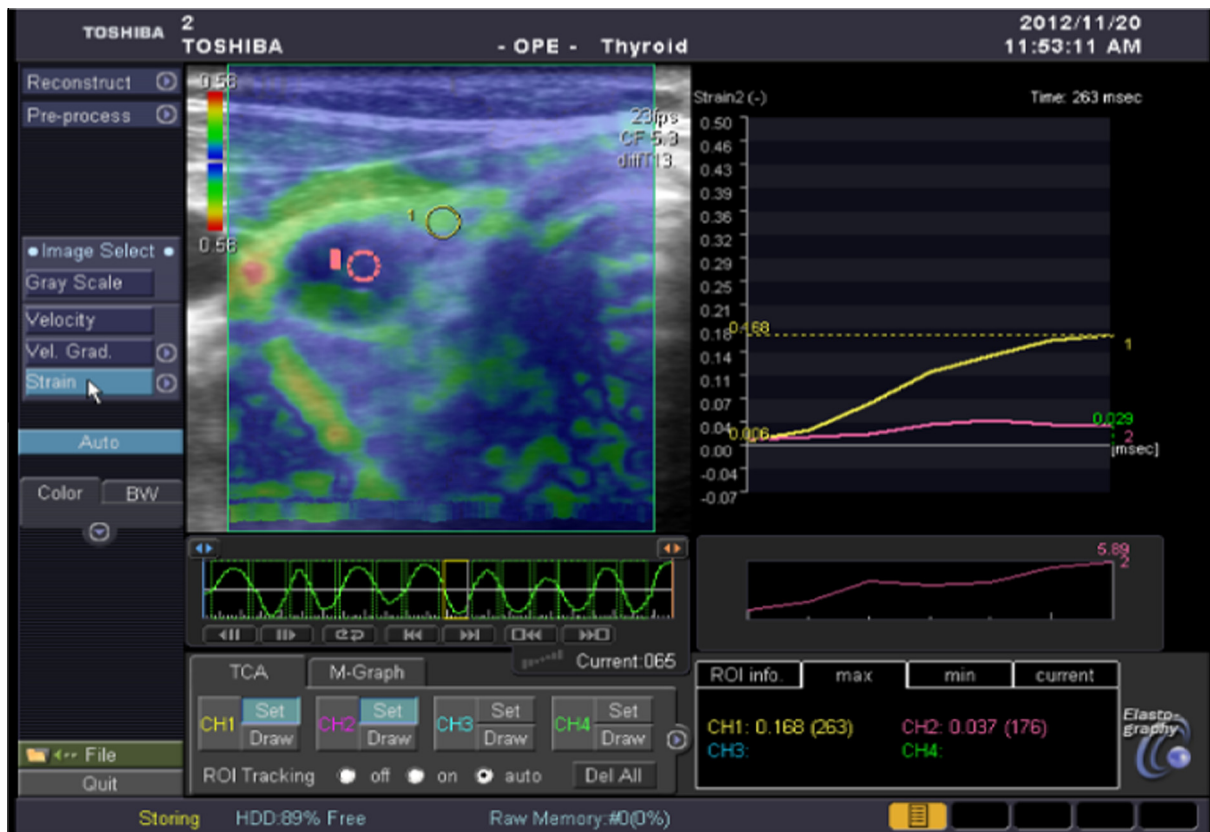


Fig. 1 Showing the automated scale (represented by waves, we select the best downward wave as seen in the yellow box) and color scale that ranges from red (i.e. softest components) to blue (hardest components).

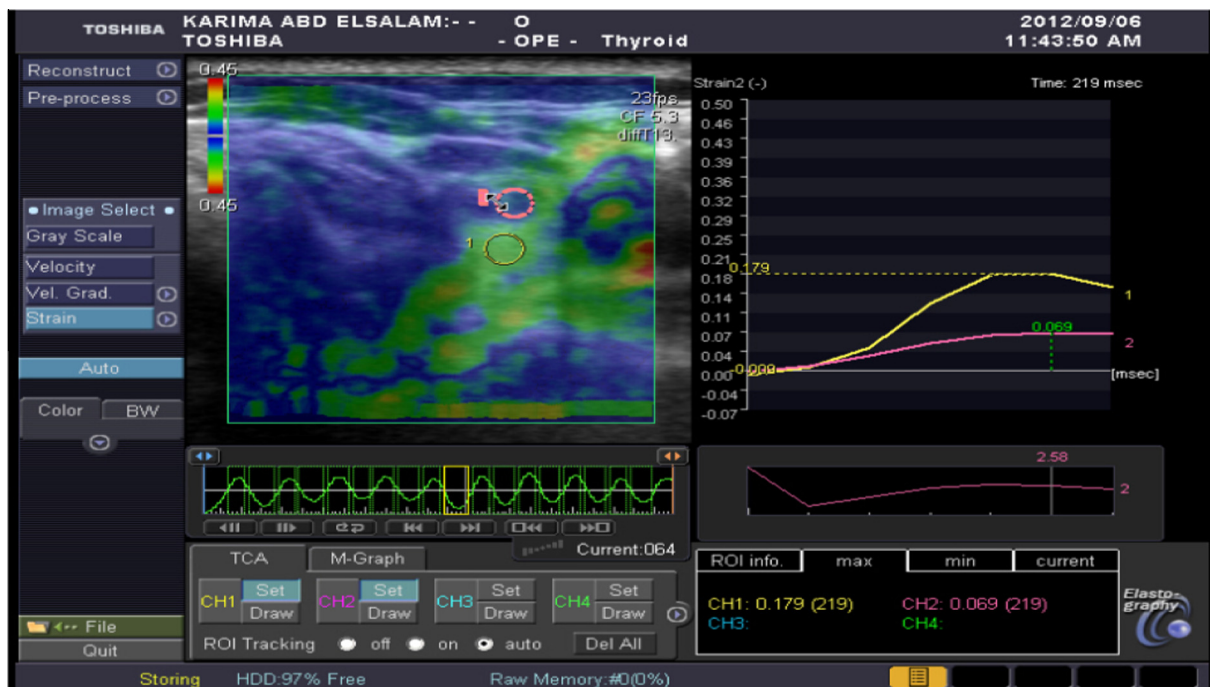


Fig. 2 Showing inadequate compression, the downward waves did not reach the baseline and are not symmetrical.

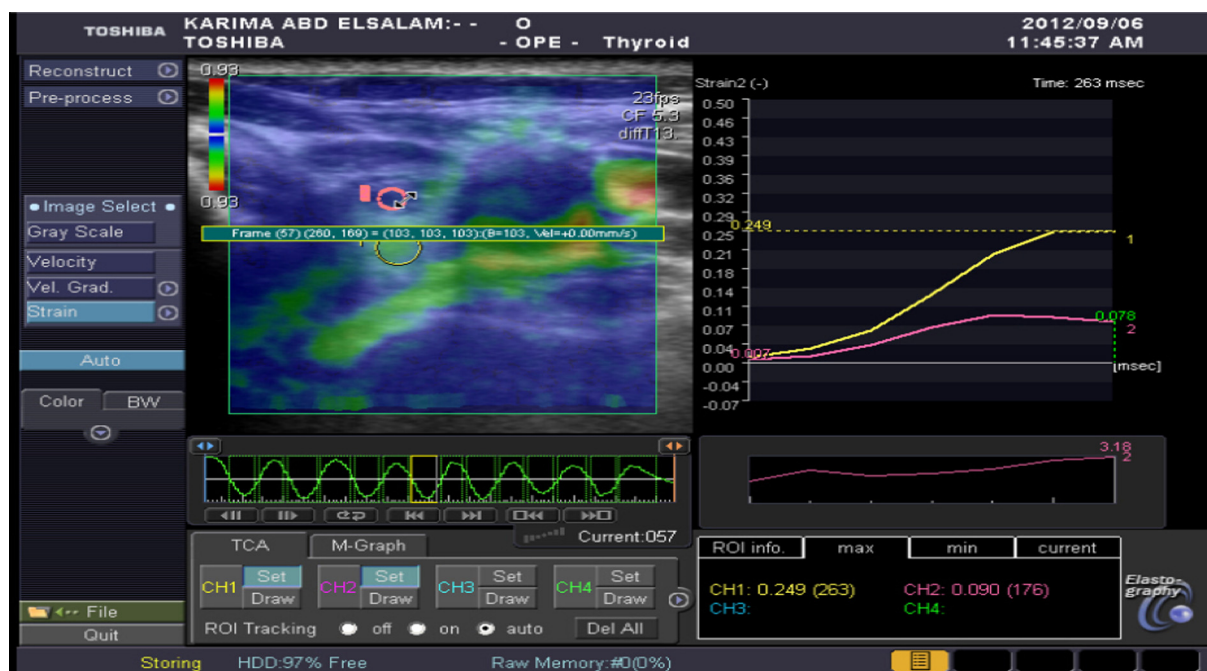


Fig. 3 The same nodule after adequate compression.

- According to Kagoya et al. (12), the strain index of the thyroid nodule and that of the sternomastoid muscle was measured and the nodule to muscle strain ratio was calculated. They found that: $(SR) > 1.5$ correlates with malignancy, $(SR) < 1.5$ correlates with benignity.
- According to Ning et al. (13), 4.2 was chosen as the cutoff point for malignant and benign diseases.

All of the patients underwent fine-needle aspiration biopsy under ultrasound guidance within 5 days of the real-time sonographic elastography evaluation. A 23-gauge needle was used with an attached 5-mL syringe for fine-needle aspiration biopsies. The cytological diagnoses of the thyroid nodules were compared with real-time sonographic elastography imaging features.

3. Results

The study included fifty patients (age range, 21–80 years), including 41 women (age range, 21–80 years) and nine men (age range, 37–78 years), who were enrolled in the study.

Based on histopathological findings, a total of 50 cases with 73 indeterminate nodules, 16 nodules (21.9%) had a final diagnosis of malignancy on histopathology: 13 papillary thyroid carcinomas, including 8 classic variants, four follicular variants, and one tall cell variant; one minimally invasive follicular carcinoma; and two medullary carcinomas. Of 73 nodules, **57 (78.1%) were benign at histopathology**: 50 follicular adenomas, 6 hyperplastic nodules, and one colloid nodule.

Based on Conventional Ultrasound Imaging, 73 indeterminate nodules were identified, and most of the nodules were solid (n_{62}) 84.9% or predominantly solid (n_{11}) 15% with marginal cystic component.

Nodule hypoechoogenicity (sensitivity 81% and specificity 62%; accuracy 67.4), absent halo sign (sensitivity 61% and

specificity 19.3%; accuracy 26.1%), spot microcalcifications (sensitivity 66.7% and specificity 72%; accuracy 69.5%), blurred or speculated margins (sensitivity 84% and specificity 62%; accuracy 68%) and an A/T of 1 cm or greater (sensitivity 80% and specificity 64%; accuracy 67%) were the US patterns most predictive of malignancy.

A hypoechoic pattern was observed in forty-five nodules (43.8%), 32 benign nodules and 13 malignant nodules, 13 nodules (40.6%) did not show the halo sign, 9 nodules (28.1%) had a predominant vertical development and microcalcifications were found in nine of sixteen (56.2%) malignant nodules. Two malignant nodules (2.7%) were isoechoic and one nodule (1.3%) was hyperechoic. Of benign nodules, eight nodules were isoechoic (10.9%) and seventeen nodules were hyperechoic (23.2%) (Table 1).

Regular margins were observed in 60 nodules (82.2%), and irregular margins were seen in 13 nodules (17.8%). The presence of dense macrocalcifications larger than 2 mm was not predictive of malignancy, with a sensitivity of 22% and a specificity of 79.6%. This type of calcification was detected in 15 nodules by the conventional US. Two of the 15 nodules were malignant.

Single US pattern was not predictive of malignancy. The combination of echographic patterns could increase the specificity, but decreased the sensitivity of conventional US in indeterminate nodules. The most predictive combination was the absence of halo sign with the presence of spot microcalcifications (Sensitivity 61%, specificity 95% and accuracy 82.2%) (Table 2).

Based on Color flow Doppler pattern, the pattern of intranodular blood flow taken alone was not predictive of malignancy (sensitivity 6.7% and specificity 96.7%; accuracy 67.4).

Based on US elastography, of the 57 benign nodules, 41 nodules (71.9%) had a score of 1 or 2 (15 nodules had a score of 1, and 26 nodules had a score of 2). Of the sixteen malignant

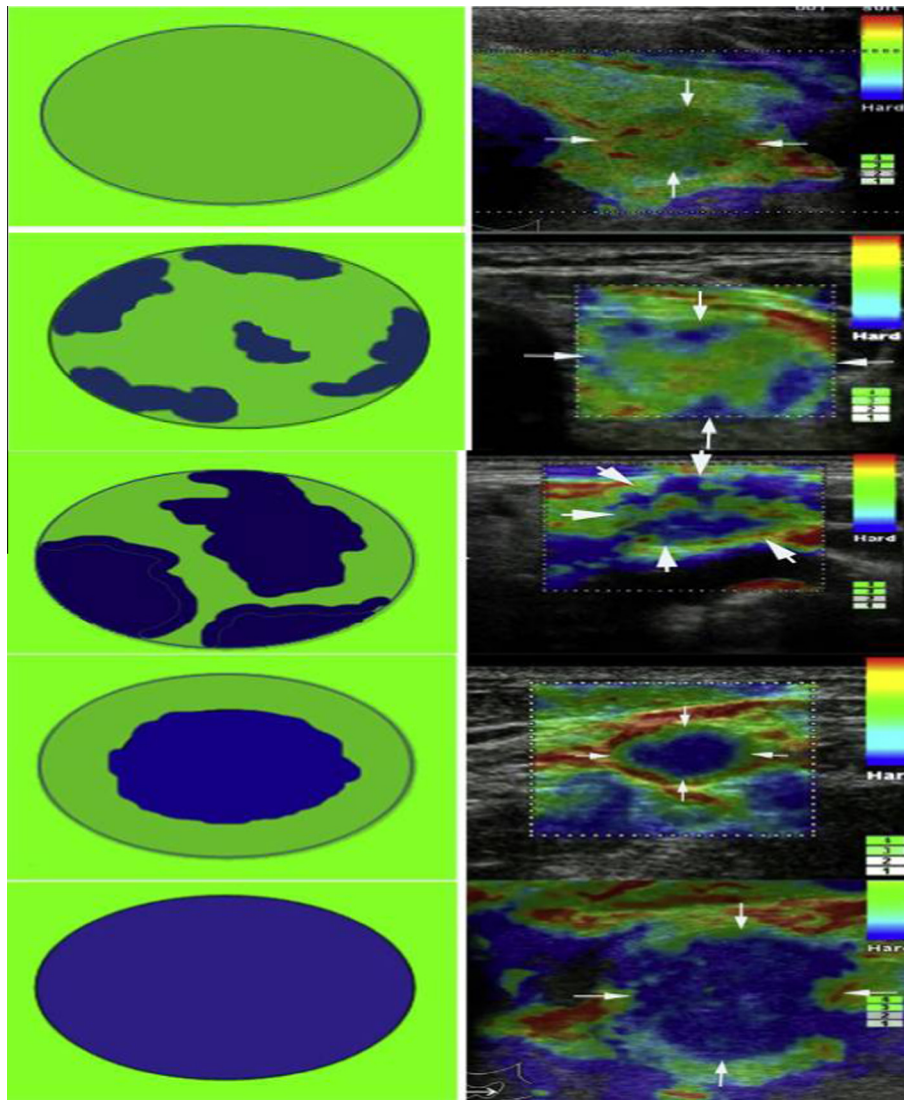


Fig. 4 Elasticity scores of thyroid nodules (10).

Table 1 Sensitivity, specificity and accuracy of US patterns in histopathologically proven thyroid nodules.

		Benign nodules (n = 57)	Malignant nodules (n = 16)	Sensitivity (%)	Specificity (%)	Accuracy																										
Hypoechoogenicity	Present	32	13	81	62	67.4																										
	Absent	25	3				Halo sign	Present	51	3	64	82	53.2	Absent	6	13	Spot-microcalcification	Present	17	9	64	72	68.3	Absent	40	7	Type III-vascularization	Present	10	9	6.4	97
Halo sign	Present	51	3	64	82	53.2																										
	Absent	6	13				Spot-microcalcification	Present	17	9	64	72	68.3	Absent	40	7	Type III-vascularization	Present	10	9	6.4	97	67.4	Absent	47	7						
Spot-microcalcification	Present	17	9	64	72	68.3																										
	Absent	40	7				Type III-vascularization	Present	10	9	6.4	97	67.4	Absent	47	7																
Type III-vascularization	Present	10	9	6.4	97	67.4																										
	Absent	47	7																													

nodules, fifteen (93.7%) had a score of 4 or 5 (eight nodules had a score of 4, and seven nodules had a score of 5). Of the 57 benign nodules, 16 (28.0%) nodules had a score of 3. Only one of the malignant lesions (6.2%) had a color score

of 3, and none of the malignant nodules had a color score of 1 or 2 (Tables 3 and 4).

Sixteen nodules were malignant and 57 were benign. Sensitivity and specificity of the US-elastography for thyroid

Table 2 Sensitivity, specificity and accuracy of combination of US patterns in histopathologically proved thyroid nodules.

	BN(57)	CA(16)	Sensitivity (%)	Specificity (%)	Accuracy
<i>Absent Halo sign/Hypoechoogenicity</i>					
Both present	–	13	60	93.5	78.3
One absent	32	3			
<i>Absent Halo sign/Spot microcalcification</i>					
Both present	–	9	61	93.5	82.6
One absent	17	7			
<i>Hypoechoogenicity/Spot microcalcification</i>					
Both present	–	9	53.3	90.3	78.2
One absent	32	7			
<i>Absent Halo sign/Hypoechoogenicity/Type III vascularization</i>					
Both present	–	9	6.7	100	69.4
One absent	32	7			
<i>Hypoechoogenicity-/Spot microcalcification/Type III vascularization</i>					
Both present	–	9	6.7	100	69.4
One absent	32	7			
<i>Absent Halo sign/Spot microcalcification/Type III vascularization</i>					
Both present	–	9	6.7	100	69.4
One absent	17	7			

cancer diagnosis were 92.3% and 82.1% respectively. The positive and negative predictive values were 54% and 98.2% respectively. The accuracy of the technique was 82.4% when the best cutoff point of 2.31 was used.

Thus, all 57 cases with a final diagnosis of benign nodule (Figs. 5 and 6) had a score of 1–3, while 15 of 16 (93.75%) with a final diagnosis of carcinoma (Fig. 7) had a score of 4–5, with a sensitivity of 93.3%, a specificity of 100% and an accuracy of 97.8%. One of the 16 nodules with the histological diagnosis of follicular variant of papillary thyroid carcinoma had a score of 3 (Fig. 8).

Among benign lesions, the score was 1 in 15 and 2 in 2 of the 6 hyperplastic nodules; it was 1 in 17, 2 and 3 in 40 of the adenomatous nodules, and these data suggest that adenomatous nodules have a higher stiffness with respect to the hyperplastic nodules (Table 3).

Combined US findings with US elastography reveals that hypoechoogenicity/score 4–5 was most predictive of malignancy with sensitivity 80% and specificity 100%; and accuracy 93.4% in addition to the presence of spot microcalcifications/score 4–5 with sensitivity 66.7% and specificity 100%; and accuracy 89.1% and the absent halo sign/score 4–5 with sensitivity 60% and specificity 96.7%; and accuracy 84.7% (Table 4).

Sensitivity of the US-elastography for thyroid cancer diagnosis was 92.3% and 82.1% respectively. The positive and negative predictive values were 54% and 98.2% respectively (Table 5). The accuracy of the technique was 82.4%. Elastasonography was more accurate than US and color Doppler US in characterizing thyroid nodules ($p = 0.002$).

The strain ratio value measured for the histological proven malignant nodules varies between 2.31 and 4. Five nodules out of sixteen had SR between 2.31 and 4 (sensitivity 96% and specificity 83%). The cutoff value for malignant nodules was 2.3, obtained with receiver operating characteristic (ROC) curve analysis.

4. Discussion

Sonographic elastography is based on the combined visualization of tissue elasticity (strain) and the velocity at which the tissue deformation occurs. Some of the major advantages of real time sonographic elastography are its ease of performance, its noninvasiveness, and its suitability of use during routine ultrasound examinations. In addition, this imaging technique facilitates the dynamic visualization of lesions during compression (14).

Ultrasound features predictive of malignant nodules include the presence of irregular margins, marked hypoechoogenicity, microcalcifications, taller-than-wide shape, and intranodular vascularity (15).

According to the current results, nodule hypoechoogenicity (sensitivity 81% and specificity 62%; accuracy 67.4), absent halo sign (sensitivity 61% and specificity 19.3%; accuracy 26.1%), spot microcalcifications (sensitivity 66.7% and specificity 72%; accuracy 69.5%), blurred or speculated margins (sensitivity 84% and specificity 62%; accuracy 68%) and an A/T of 1 cm or greater (sensitivity 80% and specificity 64%; accuracy 67%) were the US patterns most predictive of malignancy in agreement with Rago.

Another recent study by Rania and Khaled (16) revealed that ill-defined margins, spot microcalcifications and AP/T diameter more than 1 cm were the most predictive ultrasound patterns of malignancy.

In the current study, absence of halo sign combined with the presence of spot microcalcifications and absent halo sign/hypoechoogenicity were most predictive of malignancy (sensitivity 60% and specificity 93.5%), in agreement with Rago et al. (5) who stated that combined US features and color Doppler become highly predictive of malignancy only when multiple patterns are simultaneously present in a thyroid nodule.

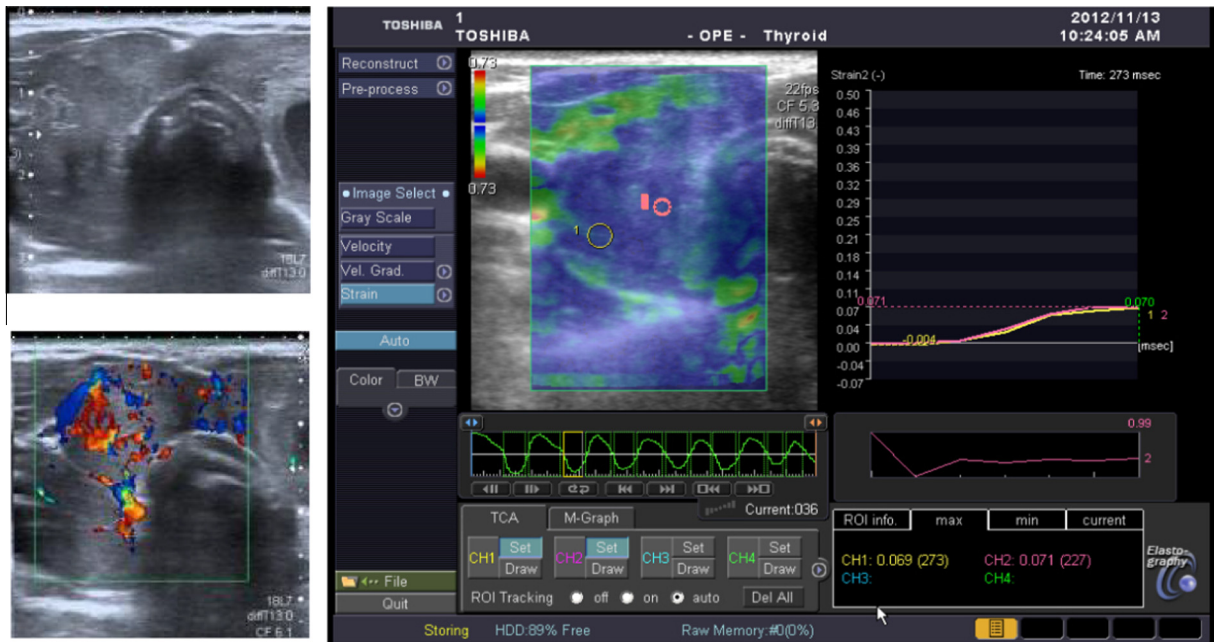


Fig. 5 A 45 year old female with neck swelling. By conventional US, a fairly defined Solid nodule is seen within the right lobe. Color doppler shows central and perinodular vascularity. By elastography: elasticity was absent in most of the examined (almost the whole nodule is displayed in light blue with some regions of light green). Elasticity score: 3, strain ratio: 0.99, cytological findings: hyper plastic nodule.

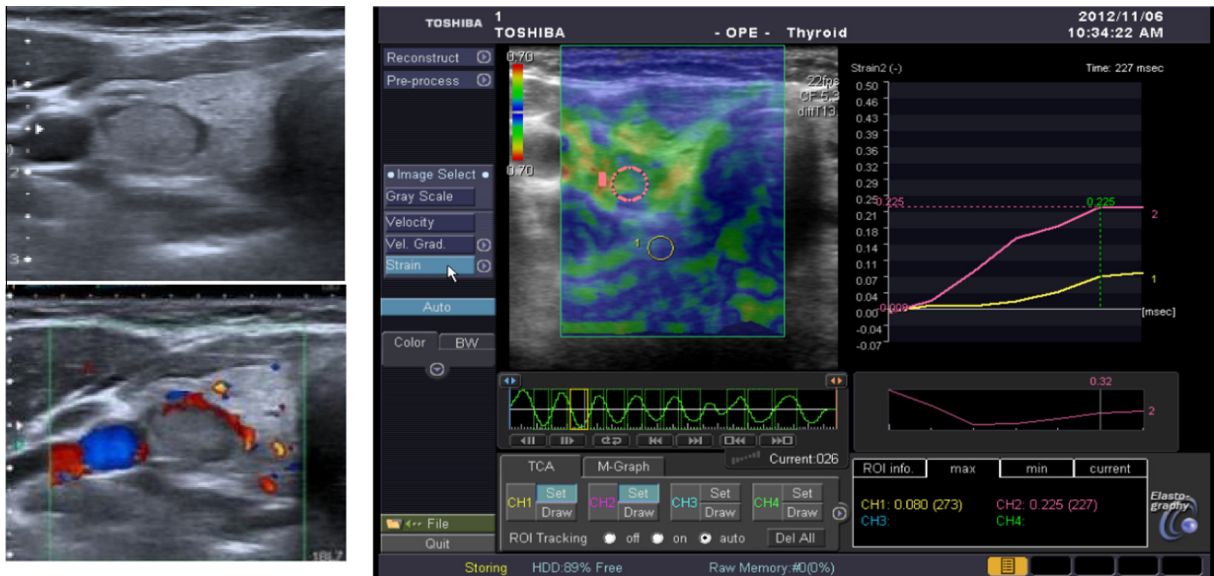


Fig. 6 A 23 year old female with neck pain. By conventional US there is an isoechoic well defined right lobe solid nodule with preserved halo sign seen in the right lobe. Color doppler revealed perinodular vascularity. By elastography: color coding revealed flexibility in most of the nodule (almost the whole nodule is displayed in light green with some peripheral and/or central blue areas). Elasticity score: score 2, strain ratio: 0.32, cytological findings: follicular adenoma.

Conventional US does not provide information regarding hardness of the nodule and this is the role of USE. US elastography was developed to determine tissue stiffness and strain information noninvasively (17).

Strain represents the amount of deformation; thus, stiff tissue shows less strain than softer tissue. A thyroid lesion may have different levels of stiffness within it, depending on the

cellularity and the composition of the nodule. Information from these elastograms helps to assess the relative stiffness of the lesion compared with its surrounding tissues and within itself (3).

Asari et al. (18) reported that the Real-time USE is based upon the principle that the softer parts of tissues deform more rapidly than the harder parts under compression, thereby

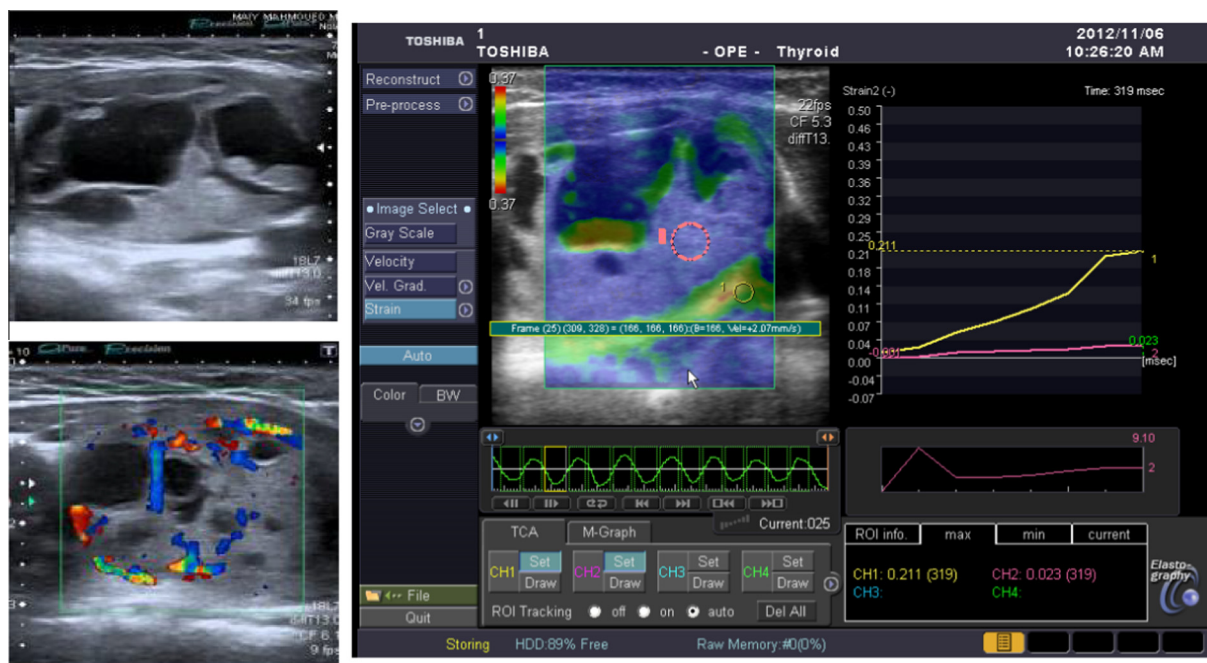


Fig. 7 A 37 year old female, with neck swelling: By conventional US there was a well defined complex lesion with a solid component. Color doppler revealed internal and perinodular vascularity. By elastography: absent elasticity throughout the area examined (the whole nodule is displayed homogeneously in dark blue). Elasticity score 4, strain index: 9.1, cytological findings: minimally invasive follicular carcinoma.

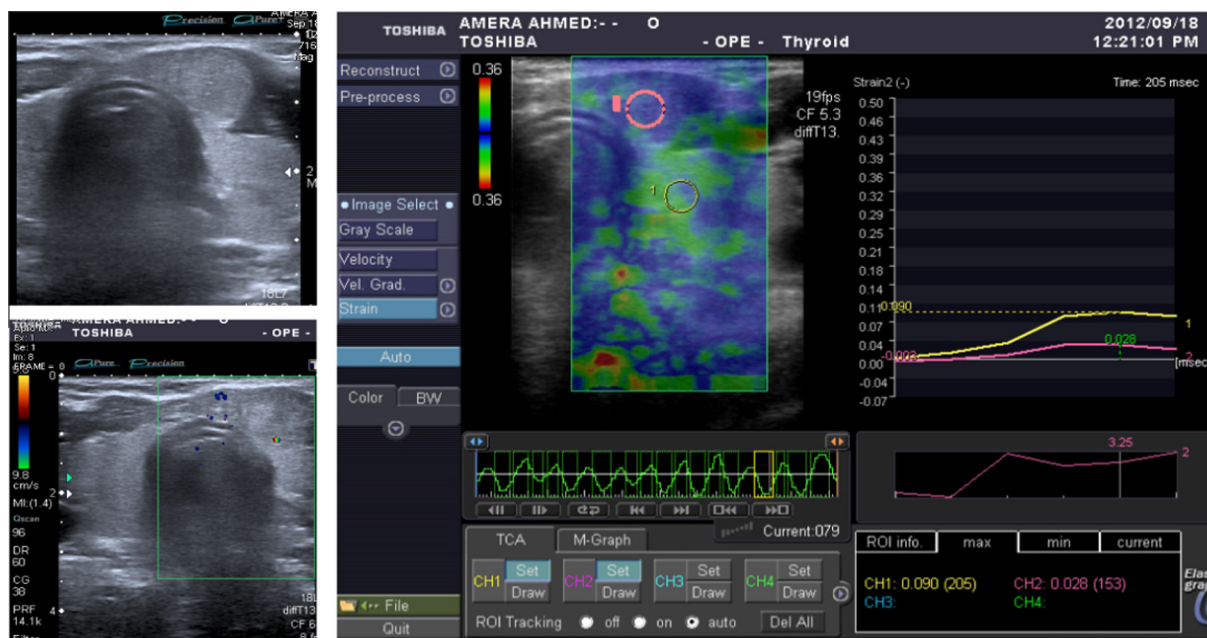


Fig. 8 A 35 year old female with a neck swelling showing a well defined isoechoic solid nodule within the left side of the isthmus. By color doppler faint perinodular vascularity is noted. By elastography: elasticity absent in most of the examined (almost the whole nodule is displayed in light blue with some regions of light green). Elasticity score 3, strain ratio 3.25, cytological findings: follicular variant of papillary thyroid carcinoma.

allowing objective determination of tissue maximum diameter with an indeterminate result on conventional ultrasound. An elasticity score of 4–5 was highly predictive of malignancy, with a sensitivity of 90.63%, a specificity of 89.47% and an accuracy of 90.20%.

In the present study the most US features suggestive of malignancy were, absence of halo sign combined with the presence of spot microcalcifications as well as combined absent halo sign/hypoechoic and all were confirmed by US elastography that revealed a score of 1–3 in all benign cases with

Table 3 Distribution of elasticity scores in group patients.

Elasticity score	BN(57)	CA(16)	Sensitivity	Specificity	Accuracy
Score 1	15	–			
Score 2	26	–			
Score 3	16	1			
Score 4	–	8			
Score 5	–	7			
Score 1–3	57	1			
Score 4–5	–	15	92.3%	82.1%	82.4

only one case scored as score 3 and had these US suspicious features, revealed after that being classic variant of papillary thyroid carcinoma.

We had 16 nodules that were malignant and 57 were benign. Sensitivity and specificity of the US-elastography for thyroid cancer diagnosis were 92.3% and 82.1% respectively with the accuracy of 82.4% in agreement with Rago et al. (5). The positive and negative predictive values were 54% and 98.2% respectively.

All the 57 cases with a final diagnosis of benign nodule had a score of 1–3, while 15 of 16 (93.75%) with a final diagnosis of carcinoma had a score of 4–5, with a sensitivity of 93.3%, a specificity of 100% and an accuracy of 97.8%. One of the 16 nodules with the histological diagnosis of follicular variant of papillary cancer had a score of 3.

Among benign lesions, the score was 1 in 15 and 2 in 2 of the 6 hyperplastic nodules; it was 1 in 17, 2 and 3 in 40 of the adenomatous nodules. Although the number of hyperplastic nodules is too small to allow a reliable statistical evaluation,

these data suggest that adenomatous nodules have a higher stiffness with respect to the hyperplastic nodules.

Combined US findings with US elastography reveals that hypoechogenicity/score 4–5 was most predictive of malignancy with sensitivity 80% and specificity 100%; and accuracy 93.4% in addition to the presence of spot microcalcifications/score 4–5 with sensitivity 66.7% and specificity 100%; and accuracy 89.1% and the absent halo sign/score 4–5 with sensitivity 60% and specificity 96.7%; and accuracy 84.7%.

The strain ratio value measured for the histological proven malignant nodules varies between 2.3 and 4. Five nodules out of sixteen had SR between 2.3 and 4 (sensitivity 96% and specificity 83%). The cutoff value for malignant nodules was 2.3.

Sensitivity of the combination between elasticity scores and strain ratio was 92.3% and specificity 82.1% respectively. The positive and negative predictive values were 55.6% and 98.8% respectively, and the accuracy of the technique was 82.4% (Table 5). Elastasonography was more accurate than US and color Doppler US in characterizing thyroid nodules ($p = 0.002$).

These results revealed that combined techniques were superior to US alone and added more significant value when compared with US elastography alone in agreement with Moon et al. (19). On the other hand, conventional US maintains a pivotal importance to define which nodules are suitable for the US elastographic characterization.

So, thyroid nodules with suspicious criteria can be further evaluated by US elastography that seems to be a useful addition for the assessment of such indeterminate nodules, as it can help to reduce FNAC or at least allow to select nodule (or nodular zone) for aspirations. Further prospective studies are needed to refine US-elastography for improving its diagnostic capability.

Table 4 Combined US findings with elasticity scores and strain ratio.

	BN(57)	MN(16)	Sensitivity (%)	Specificity (%)	Accuracy
<i>Absent halo sign/score 4–5/SI > 2.3</i>					
Both present	–	13	60	96.7	84.7
One absent	–	3			
<i>Present halo sign/score 1–3/SI < 2.3</i>					
Both present	40	1	40	19.3	26.1
One absent	17	–			
<i>Hypoechogenicity/score 4–5/SI > 2.3</i>					
Both present	–	13	80	100	93.4
One absent	32	3			
<i>Absent hypoechogenicity/score 1–3/SI < 2.3</i>					
Both present	25	1	6.7	38.7	28.3
One absent	32	3			
<i>Spot microcalcifications/score 4–5/SI > 2.3</i>					
Both present	–	9	66.7	100	89.1
One absent	17	5			
<i>Absent microcalcifications/score 1–3/SI < 2.3</i>					
Both present	27	–	6.7	29	21.7
One absent	30	5			
<i>Type III vascularization/score 4–5/SI > 2.3</i>					
Both present	–	9	6.7	100	69.7
One absent	2	7			

Table 5 Sensitivity, specificity and accuracy of strain ratio.

Strain ratio	BN(57)	MN(16)	Sensitivity	Specificity	Accuracy
< 2.3	57	–			
> 2.3 up to 4	–	5	92.3%	83%	82.4
> 4	–	11			

Conflict of interest

The authors declare that there are no conflicts of interest.

References

- (1) Vorländer C, Wolff J, Saalabian S, et al. Real-time ultrasound elastography – a noninvasive diagnostic procedure for evaluating dominant thyroid nodules. *Langenbecks Arch Surg* 2010;395:865–71.
- (2) Bahn RS, Castro MR. Approach to the patient with nontoxic multinodular goiter. *J Clin Endocrinol Metab* 2011;96:1202–12.
- (3) Dighe Manjiri, Bae Unmin, Richardson Michael L, et al. Differential diagnosis of thyroid nodules with US elastography using carotid artery pulsation. *Radiology* 2008;248(2):662–9.
- (4) Castro MR, Gharib H. Thyroid fine-needle aspiration biopsy: progress, practice, and pitfalls. *Endocr Pract* 2003;9:128–36.
- (5) Rago T, Scutari M, Santini F, et al. Real-time elastosonography: useful tool for refining the presurgical diagnosis in thyroid nodules with indeterminate or nondiagnostic cytology. *J Clin Endocrinol Metab* 2010;95:5274–80.
- (6) Lewis CM, Chang KP, Pitman M, et al. Thyroid fine-needle aspiration biopsy: variability in reporting. *Thyroid* 2009;19:717–23.
- (7) Rago T, Vitti P, Chiovato L, et al. Role of conventional ultrasonography and color flow-doppler sonography in predicting malignancy in “cold” thyroid nodules. *Eur J Endocrinol* 1998;138:41–6.
- (8) Gharib H, Papini E, Paschke R, et al. AACE/AME/ETA task force on thyroid nodules: American Association of Clinical Endocrinologists, Associazione Medici Endocrinologi, and European Thyroid Association medical guidelines for clinical practice for the diagnosis and management of thyroid nodules. *J Endocrinol Invest* 2010;33:1–50.
- (9) Rago T, Fiore E, Scutari M, et al. Male sex, single nodularity, and young age are associated with the risk of finding a papillary thyroid cancer on fine needle aspiration cytology in a large series of patients with nodular thyroid disease. *Eur J Endocrinol* 2010;162:763–70.
- (10) Ueno E, Ito A. Diagnosis of breast cancer by elasticity imaging. *Eizo Joho Med* 2004;36:2–6.
- (11) Raggiunti B. Ultrasound elastography: can it provide valid information for differentiation of benign and malignant thyroid nodules? *J Ultrasound* 2011;14(3):136–41.
- (12) Kagoya R, Monobe H, Tojima H. Utility of elastography for differential diagnosis of benign and malignant thyroid nodules. *Otolaryngol Head Neck Surg* 2010;143:230–4.
- (13) Ning CP, Jiang SQ, Zhang T, Sun LT, Liu YJ, et al. The value of strain ratio in differential diagnosis of thyroid solid nodules. *Eur J Radiol* 2012;81:286–91 [Pub Med].
- (14) Friedrich-Rust M, Ong MF, Herrmann E, et al. Real-time elastography for noninvasive assessment of liver fibrosis in chronic viral hepatitis. *AJR* 2007;188:758–64.
- (15) Kim JY, Lee CH, Kim SY, et al. Radiologic and pathologic findings of non palpable thyroid carcinoma as detected by ultrasonography in a medical screening center. *J Ultrasound Med* 2008;27:215–23.
- (16) Mohamed Rania E, Abodewan Khaled A. Diagnostic utility of real time ultrasound elastography for prediction of malignancy in solid thyroid nodules. *Egypt J Radiol Nucl Med* 2013;44:33–43.
- (17) Greenleaf JF, Fatemi M, Insana M. Selected methods for imaging elastic properties of biological tissues. *Annu Rev Biomed Eng* 2003;5:57–78.
- (18) Asari R, Niederle BE, Scheuba C, et al. Indeterminate thyroid nodules: a challenge for the surgical strategy. *Surgery* 2010;148:516–25.
- (19) Moon Hee Jung, Sung Ji Min, Kim Eun-Kyung, et al. Benign and malignant thyroid nodules: US differentiation – multicenter retrospective study. *Radiology* 2008;247:762–70.