

Evaluation of annexin A2 and Follistatin as potential biomarkers for hepatocellular carcinoma

Nevine El-Abd¹ · Amal Fawzy² · Tamer Elbaz³ · Sherif Hamdy³

Received: 16 July 2014 / Accepted: 4 September 2014
© International Society of Oncology and BioMarkers (ISOBM) 2015

Abstract Hepatocellular carcinoma (HCC) ranks as the fifth most common malignancy worldwide. Early detection of HCC is difficult due to the lack of reliable markers. We aimed to assess the diagnostic role of annexin A2 (ANXA2) and follistatin as serum markers for HCC patients. This study included 50 patients with confirmed diagnosis of HCC, 30 patients with chronic liver disease, and 20 normal persons. Subjects performed thorough assessment and laboratory investigations. Serum levels of alpha fetoprotein (AFP), annexin A2, and follistatin were measured using ELISA technique. Annexin A2 significantly increased in the sera of HCC patients (median, 69.6 ng/ml) compared to chronic liver disease patients (median, 16.8 ng/ml) and control group (median, 9.5 ng/ml) ($p < 0.001$). Follistatin was higher in sera of HCC patients (median, 24.4 ng/ml) compared to the control group (median, 4.2 ng/ml) ($p = 0.002$) while no such significant difference was achieved between HCC and chronic liver disease patients. At a cutoff level 29.3 ng/ml, area under the receiver-operating characteristic curve for ANXA2 was 0.910 (95 % confidence interval (CI)

0.84–0.97). For follistatin, it was 0.631 (95 % confidence interval 0.52–0.74) at cutoff level 15.7 ng/ml. Combining both annexin A2 and AFP increased the diagnostic efficiency (98 % specificity, LR+41 and 97.6 % PPV). Follistatin combined with AFP provided 92 % specificity while lower sensitivity (50 %) was observed. Serum ANXA2 is a promising biomarker for HCC, certainly when measured with AFP. Follistatin could not differentiate between HCC and chronic liver disease, but its combination with AFP improved the specificity for HCC diagnosis.

Keywords Annexin A2 · Follistatin · AFP · Hepatocellular carcinoma

Introduction

Hepatocellular carcinoma (HCC) is the fifth most common worldwide malignancy [1]. In Egypt, incidence of HCC is currently increasing, even with an observed doubling in the incidence rate in the past 10 years [2, 3].

The diagnostic armamentarium of HCC includes various laboratory and imaging modalities. Detection of serum markers is usually considered the most effective method, being more convenient and inexpensive. However, their diagnostic efficiency is suboptimal.

Annexin A2 (ANXA2) belongs to the annexin family that has been reported to play important carcinogenic roles, including signal transduction, angiogenesis, apoptosis, tumor invasion, and metastasis. It is a 36-kDa calcium-dependent phospholipid-binding protein that is located on the surface of most eukaryotic cells. ANXA2 is involved in several biological processes, including anti-inflammatory effects, Ca^{2+} -dependent exocytosis, immune responses, and phospholipase A2 regulation [4]. Increased expression of ANXA2 is

✉ Tamer Elbaz
tamerbaz@gmail.com; tamerbaz@yahoo.com

Nevine El-Abd
nevineelabd@yahoo.com

Amal Fawzy
amalfawzy69@hotmail.com

Sherif Hamdy
sherifhamdy_74@hotmail.com

¹ Department of Clinical and Chemical Pathology, Cairo University, Cairo, Egypt

² Department of Clinical and Chemical Pathology, National Cancer Institute, Cairo, Egypt

³ Department of Endemic Hepatogastroenterology, Cairo University, Cairo, Egypt

documented in cancers of different sites such as the breast, liver, prostate, and pancreas [5–8]. Moreover, ANXA2 has been reported to play an integral role in cancer cell migration, invasion, and adhesion processes which are crucial for the development of cancer metastasis [9]. A previous study used the complementary DNA (cDNA) microarray technique and demonstrated that ANXA2 gene was upregulated in tissue samples from HCC lesions [10]. The human follistatin (FST) gene is another potential serological marker for the diagnosis of HCC. It is comprised of six exons on chromosome 5q11.2 and gives rise to two main transcripts: transcript variant FST344 and FST317 [11]. It is a secreted monomeric protein that is over-expressed in rat and human liver tumors and contributes to hepatocarcinogenesis through the inhibition of activins [12]. Activins are cytokines that belong to the transforming growth factor- β (TGF- β) family [13]. Therefore, the activin/follistatin system is thought to primarily act as a local growth regulating system controlling proliferation, differentiation, and apoptosis of many cell types in an autocrine and paracrine manner [14, 15]. Follistatin mRNA was markedly over-expressed in HCC cell line microarray studies, raising the possibility to have an efficient role in HCC diagnosis [16].

In our study, we aimed to evaluate the potential role of annexin A2 and follistatin as diagnostic serological markers for detection of HCC. In addition, we will correlate them with another well-documented HCC marker (alpha fetoprotein) for a possibly higher diagnostic accuracy through improved sensitivity and/or specificity.

Patients and methods

Patients

This is a case-control study that was conducted over a period of consecutive 6 months from April 2013 to September 2013.

Serum samples from 80 patients with different spectrum of liver disease and from 20 apparently healthy persons were analyzed. Subjects were classified into two groups: group (I) included 50 patients with HCC, (mean age 59.9 years \pm 8.8 SD, they were 35 males and 15 females). HCC was diagnosed in respect to AASLD guidelines [17]. The diagnosis of focal lesions was originally detected by ultrasonography. We used multidetector CT scan to confirm the presence of hypervascular lesions in the arterial phase that washed out in the portal venous or delayed phases. If lesions showed atypical findings, confirmatory dynamic contrast-enhanced MRI was the following step. No patients needed to be biopsied. Blood samples were collected prior to initiation of any HCC treatment. Group (II) included 30 cirrhotic patients (mean age 46.7 years \pm 14.1 SD; they were 21 males and 9 females). The presence of cirrhosis was diagnosed by ultrasonography that showed evident hepatic changes as well as evidence of portal hypertension. Laboratory

profile including the different parameters of liver biochemical profile potentiated the diagnosis of cirrhosis. All cirrhotic patients underwent regular ultrasonographic screening (every 4–6 months) to exclude the development of any hepatic nodules.

Group III, considered as control group, included 20 apparently healthy volunteering blood donors who attended the blood bank of Kasr El Aini Hospital. All of them had negative histories for chronic liver diseases and performed hepatitis markers that excluded the seropositivity for HBV and HCV (their mean age was 29.4 \pm 4.5 SD; they were 13 males and 7 females). Serum samples were assayed for AFP, ANXA2, and follistatin to establish the normal reference range in Egyptian population as controls.

The study protocol and the suggested informed consent were submitted to the Institutional Review Board (IRB) of National cancer institute and Endemic Hepatogastroenterology Department before the start of enrolling participants. The study was designed in compliance with the ethics principles of the declaration of Helsinki with GCP guidelines.

The studied patients (group I and II) were recruited from those presented to the outpatient clinic of the Endemic Hepatogastroenterology Department of Kasr El Aini Hospital (Cairo University, Egypt) and National cancer institute (Cairo University, Egypt). A written informed consent was obtained from all participants.

Methodology

All patients and controls were subjected to full clinical assessment. Laboratory investigations included aspartate aminotransferase (AST), alanine transaminase (ALT), alkaline phosphatase (ALP), total bilirubin, and serum albumin. All were performed on Beckman CX9 autoanalyser. Prothrombin concentration and INR were done using automated coagulometer (Sysmex CA 1500). Viral markers (HBsAg and anti-HCV antibodies), serum ANXA2, and follistatin were tested using ELISA method [18]. AFP was done using Architect based on the Chemiluminescence Immunoassay (CLIA) technology [19]. Radiological investigations included ultrasonography, computed tomography, and/or magnetic resonance imaging for patients.

Sample collection and storage

Ten milliliters of venous blood were withdrawn; 2 ml of them were collected in a citrated tube for PT, PC, and INR, and the other 8 ml were collected into sterile vacutainers with gel, left to clot, centrifuged at 1000g for 10 min, and then the sera were separated and divided into four aliquots, one for the blood chemistry which was assayed on the same day of sample collection, the second for AFP, the third for Annexin II, and the fourth for Follistatin. Annexin II was done using Usen Life Science Inc. Wuhan, China by Enzyme-linked Immunosorbent

Assay Kit for ANNEXIN A2 (ANXA2), Catalog Number: E91944Hu 96 tests [20]. Follistatin was done using Assay Biotechnology Company, Inc. Sunnyvale, USA by Human Follistatin Enzyme-linked Immunosorbent Assay (ELISA) Kit (96 Tests), Catalog Number: OK-0116 [16].

Statistical methods

Data was analyzed using IBM SPSS advanced statistics version 20 (SPSS Inc., Chicago, IL). Chi-square test was used to examine the relation between qualitative variables. For not normally distributed quantitative data, comparison between two groups was done using Mann-Whitney test (non-parametric *t* test). Comparison between three groups was done using Kruskal-Wallis test (non-parametric ANOVA) then post Hoc "Scheffe test" on rank of the variables was used for pair-wise comparison. The Receiver Operating Characteristic (ROC) curve was used for prediction of cutoff values. A *p* value < 0.05 was considered significant.

Results

In our study, 50 HCC patients were recruited (group I). The majority (92 %) had a compensated liver status (24 and 22 patients were Child Pugh scores A and B, respectively while only 4 were Child Pugh score C). They predominantly developed liver cirrhosis and HCC on top of chronic HCV infection (80 %) rather than HBV infection (14 %) while 7 patients (14 %) were tested negative for both hepatitis viruses. Moreover, 27 patients (54 %) had single hepatic focal lesions while 40 % developed three or more malignant hepatic lesions. Concerning the biochemical parameters among the different groups, high statistical significance was documented for all the laboratory parameters (ALT, AST, ALP, INR, serum albumin, and bilirubin) (Table 1).

The tumor markers were compared with the different prognostic factors that could be related to HCC (Table 2). The studied tumor markers were not statistically different in

comparison to the selected prognostic factors (age, sex, child's grade, and number of focal lesions).

Evaluation of serum ANXA2 for HCC diagnosis

Annexin A2 was significantly higher in the sera of HCC patients (median=69.6 ng/ml) compared to the cirrhotic group (median=16.8 ng/ml) and the normal control group (median=9.5 ng/ml) ($p<0.001$). It showed 100 % sensitivity and a good specificity (84 %) at a cutoff level of 29.3 ng/ml. Positive (PPV) and negative (NPV) predictive values were 100 and 86.2 %, respectively, which provided 92 % diagnostic accuracy (DA). Meanwhile, Youden index J and positive likelihood ratio were 0.84 and 6.25, respectively.

As for AFP, serum levels were significantly higher in the HCC patients (median, 376.5 ng/ml) compared to the cirrhotic group (median, 3.7 ng/ml) and normal control group (median, 2.3 ng/ml) ($p<0.001$). It showed a sensitivity of 82 % and a specificity of 88 % at a cutoff level of 12.9 ng/ml. The PPV was 87.2 %, NPV was 83 %, and the DA was 85 %. Combining annexin A2 with AFP markedly increased the specificity (98 %) and the PPV (97.6 %) for HCC diagnosis, while Youden index J and positive likelihood ratio were 0.80 and 41, respectively (Tables 3 and 4). As for the area under the receiver operating characteristic curve (ROC) for the whole range of sensitivities and specificities, our results showed that it was 0.91 (95 % CI 0.84 0.97) for ANXA2 and 0.93 (95 % CI 0.89 0.97) for AFP (Fig. 1).

Evaluation of serum follistatin for HCC diagnosis

Follistatin was significantly higher in the sera of HCC patients (median, 24.4 ng/ml) compared to the normal control group (median, 4.2 ng/ml) at p value=0.002. However, this statistical significance was not observed between HCC and cirrhotic groups ($p=0.8$). Follistatin showed a sensitivity and specificity of 66 % at a cutoff level of 15.7 ng/ml, while Youden index J and positive likelihood ratio were 0.32 and 1.94, respectively (Tables 3 and 4). Combining Follistatin with AFP markedly increased the specificity (92 %), PPV to 86.2, diagnostic accuracy to 71 %, Youden index J to 0.42 and LR+ to 6.25

Table 1 Biochemical parameters among the different studied groups

	Group I	Group II	Group III	<i>P</i> value
ALT (U/L)	51.5 (8–247)	34 (5.4–270)	20.4 (7.7–39.3)	<0.001
AST (U/L)	78 (24–1299)	42.7 (9.6–297)	25.5 (12.3–47)	<0.001
ALP (U/L)	162.5 (47–901)	96 (24–581)	77.5 (29–120)	<0.001
Albumin (g/dl)	3 (1.5–4.9)	2.8 (1.3–4.3)	3.5 (2.6–4.5)	0.008
Total Bilirubin (mg/dl)	1.3 (0.2–16)	0.9 (0.12–16.4)	0.63 (0.23–0.98)	0.001
INR	1.18 (1–2.62)	1.54 (1–2.2)	1.09 (1–1.13)	<0.001

Results presented as median (range)

Table 2 Association between the studied tumor markers and the different prognostic factors in the HCC group

	Annexin A2	<i>p</i> value	Follistatin	<i>p</i> value	AFP	<i>p</i> value
Age (years)		0.408		0.690		0.070
Up to 60	70.5 (33.9–542.1)		24.9 (2–89)		173.2 (3.4–414377)	
>60	69.5 (30.1–543)		22.8 (1.6–578.7)		2891 (3.4–137743)	
Sex		0.941		0.899		0.743
Males	69.5 (31.8–543)		23.9 (1.6–97.2)		416 (3.4–368530)	
Females	69.7 (30.1–400.4)		24.9 (3.1–578.7)		117 (5.2–414377)	
Child score		0.035		0.218		0.180
A	82 (30.1–543)		16.1 (1.6–97.2)		531.5 (4.8–414377)	
B	54.6 (31.8–400.4)		25.4 (2.6–38.4)		162.1 (3.4–368530)	
C	235 (40.2–542.1)		63.2 (23.9–578.7)		14992.4 (3.4–38810)	
Hepatic lesions		0.663		0.154		0.175
Single	70 (30.1–300.3)		23.3 (1.6–41.5)		454.5 (3.4–414377)	
Multiple	69.4 (31.8–543)		24.9 (2–578.7)		77.9 (3.4–38810)	

Results presented as median (range)

for HCC diagnosis. The area under the curve (AUC) in ROC analysis was 0.63 (95 % CI 0.52–0.74) (Fig. 1).

Discussion

Hepatocellular carcinoma (HCC) is most common primary cancer of the liver, the fifth most common malignancy worldwide [1] and the third leading cause of cancer-related death [21]. It has always been described as a tumor of poor prognosis. Most of studies referred this dismal prognosis to the late onset of diagnosis and the absence of the ideal diagnostic marker with sufficient diagnostic efficiency. Annexin A2 (ANXA2) is a 36-kDa calcium-dependent phospholipid-binding protein that is located on the surface of most eukaryotic cells [22]. It has been implicated in exocytosis, endocytosis, vesicle transport, regulating ion channels, immune response, cell to cell adhesions, and fibrinolysis [4, 22, 23]. It is also documented as one of key players in carcinogenesis [22]. Follistatin (FST) is a glycoprotein that could inhibit the release of follicle-stimulating hormone from pituitary cells [24]. It interacts with activins and other members of the transforming

growth factor β (TGF- β) family. Several reports have shown that follistatin regulates a variety of processes of angiogenesis, metastasis, and cell apoptosis [25–27].

Our results revealed that annexin A2 was significantly higher in the sera of HCC patients compared to the cirrhotic and the normal control groups. This was documented by previous studies that demonstrated a similar role for ANXA2 in HCC development [10, 20, 28, 29]. In our study, the area under the receiver operating characteristic curve (AUC) was 0.91 (95 % CI 0.84–0.97) for ANXA2. It ranged between 0.73 and 0.8 in different studies that compared ANXA2 in sera of HCC patients versus control groups that included normal individuals, chronic viral hepatitis as well as cirrhotic patients [10, 20, 29].

We found a more potent diagnostic role for ANXA2 when we combined it with AFP. Specificity increased to 98 % and the positive predictive value to 97.6 % while the sensitivity decreased. These results were in agreement with other researchers who reported that the sensitivity and specificity of the combination of annexin A2 and AFP were 76 and 80.5 %, respectively, while improving only the specificity [29]. Another study stated that combined detection of serum ANXA2 and AFP substantially improved the diagnostic efficiency

Table 3 Descriptive statistics of the studied tumor markers in the different studied groups

	Group I	Group II	Group III	<i>P</i> value
Annexin A2 (ng/ml)	69.6 (30.1–543) ^a	16.8 (10.2–162.5) ^b	9.5 (1.3–19.7)	<0.001
Follistatin (ng/ml)	24.4 (1.6–578.7) ^a	23.9 (1.6–86.7) ^a	4.2 (2.3–10.6) ^b	0.002
AFP (ng/ml)	376.5 (3.4–414,377) ^a	3.7 (0.9–62.7) ^b	2.3 (0.7–4.5)	<0.001

Results presented as median (range). Groups having the same letter are not statistically significant

Table 4 Diagnostic accuracy of the studied tumor markers, either single or combined

	Sensitivity (%)	Specificity (%)	PPV (%)	NPV (%)	Diagnostic accuracy	Youden index	LR+	LR-
Annexin A2 ^a	100	84	86.2	100	92	0.84	6.25	0.0
Follistatin ^b	66	66	66	66	66	0.32	1.94	0.52
AFP ^c	82	88	87.2	83	85	0.70	6.83	0.20
Annexin A2 and AFP	82	98	97.6	84.5	90	0.80	41.0	0.18
Follistatin and AFP	50	92	86.2	64	71	0.42	6.25	0.54

PPV positive predictive value, NPV negative predictive value, DA diagnostic accuracy, DOR diagnostic odd's ratio, LR+ positive likelihood ratio, LR- negative likelihood ratio

^a Cutoff value of annexin A2 at 29.3 ng/ml

^b Cutoff value of follistatin at 15.7 ng/ml

^c Cutoff value of AFP at 12.9 ng/ml

(96.5 %) and the negative predictive value (96.6 %) for HCC [20]. These results encourage using ANXA2 with AFP for the management of HCC diagnosis.

Comparing annexin A2 levels and the different prognostic factors in the HCC group, showed no significant difference, although annexin A2 level was found higher in child's C group compared to its levels in patients with child's grade A and B, statistical evaluation was not possible due to small number of patients in this group (four patients). Annexin A2 plays an important role in hepatocyte malignant transformation and HCC development which might result from the change in the tumor microenvironment and the transfer of tumor cells. This may be related with the advanced progression of liver cirrhosis that is considered as a precancerous step. In addition, previous reports suggested that ANXA2 binds with plasminogen and tissue plasminogen activator on the cell surface and promotes tumor metastasis by inducing the conversion of plasminogen to plasmin, which leads to activation of matrix metalloproteinase and degradation of extracellular matrix components [22, 30].

Regarding follistatin, our results showed that it was significantly higher in the sera of HCC patients compared to the

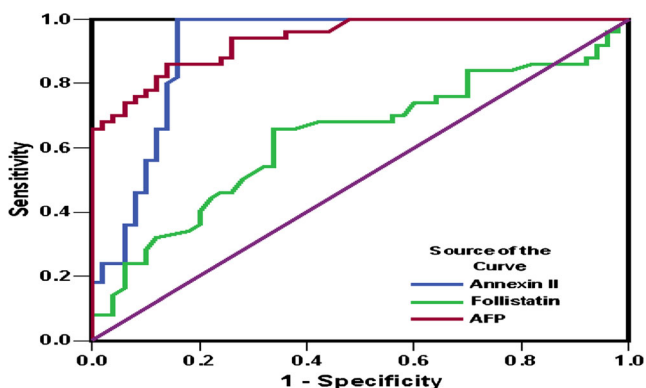


Fig. 1 Shows ROC curve comparing annexin A2, follistatin, and AFP

normal control group, but there were no significant differences between HCC and cirrhotic patients. Sensitivity and specificity were 66 % at a cutoff level of 15.7 ng/ml with an AUC in ROC analysis as 0.63 (95 % CI 0.52–0.74). No clear explanation for the absence of statistical difference between HCC and cirrhosis could be found. However, it may be assumed that the discrepancy occurs between the normal persons and the post-hepatic status with all steps from chronic hepatitis to cirrhosis and HCC. Combining Follistatin with AFP markedly increased the specificity up to 92 % for HCC diagnosis. Although AFP is best used as a prognostic rather than a diagnostic marker, it still plays here a good role in raising the diagnostic power of other HCC markers. Other studies found a similar good diagnostic role for follistatin while others proved a more evident prognostic role and the higher the follistatin, the worse was the survival of HCC patients [12, 31, 32]. A study concluded that the balanced expression of follistatin and activins becomes deregulated and shifted towards follistatin during hepatocarcinogenesis. Other studies described the release of follistatin from human hepatoma cell lines [33, 34]. Moreover, it has been suggested that follistatin, in concert with vascular endothelial growth factor, may promote the formation of new blood vessels by stimulating the production of matrix metalloproteinase-2 (MMP-2), a proteolytic enzyme which has been implicated in cancer angiogenesis and metastasis [35, 36].

Finally, our results suggested that annexin A2 is a promising diagnostic marker for HCC, and its combination with AFP markedly increases the diagnostic power. Its serum level can serve as a useful non-invasive tumor marker for detection of HCC. In contrast, follistatin could not differentiate between HCC and cirrhosis but its combination with AFP appeared to enhance the specificity for HCC diagnosis.

Conflicts of interests The authors declare that they have no conflict of interest. The study was not sponsored by any organization.

References

1. Jemal A, Bray F, Center MM, Ferlay J, Ward E, Forman D. Global cancer statistics. *CA Cancer J Clin.* 2011;61(2):69–90.
2. El-Zayadi AR, Badran HM, Barakat EM, et al. Hepatocellular carcinoma in Egypt: a single center study over a decade. *World J Gastroenterol.* 2005;11:5193–8.
3. Anwar WA, Khaled HM, Amra HA, El-Nezami H, Loffredo CA. Changing pattern of hepatocellular carcinoma (HCC) and its risk factors in Egypt: possibilities for prevention. *Mutat Res.* 2008;659(1–2):176–84.
4. Gerke V, Moss SE. Annexins: from structure to function. *Physiol Rev.* 2002;82:331–71.
5. Sharma MR, Koltowski L, Ownbey RT, et al. Angiogenesis associated protein annexin II in breast cancer: selective expression in invasive breast cancer and contribution to tumor invasion and progression. *Exp Mol Pathol.* 2006;81:146–56.
6. Mohammad HS, Kurokohchi K, Yoneyama H, et al. Annexin A2 expression and phosphorylation are up-regulated in hepatocellular carcinoma. *Int J Oncol.* 2008;33:1157–63.
7. Inokuchi J, Narula N, Yee DS, et al. Annexin A2 positively contributes to the malignant phenotype and secretion of IL-6 in DU145 prostate cancer cells. *Int J Cancer.* 2009;124:68–74.
8. Esposito I, Penzel R, Chaib-Harrireche M, et al. Tenascin C and annexin II expression in the process of pancreatic carcinogenesis. *J Pathol.* 2006;208:673–85.
9. Shiozawa Y, Havens AM, Jung Y, et al. Annexin II/annexin II receptor axis regulates adhesion, migration, homing, and growth of prostate cancer. *J Cell Biochem.* 2008;105:370–80.
10. Ji NY, Park MY, Kang YH, et al. Evaluation of annexin II as a potential serum marker for hepatocellular carcinoma using a developed sandwich ELISA method. *Int J Mol Med.* 2009;24:765–71.
11. Wang Q, Keutmann HT, Schneyer AL, Sluss PM. Analysis of human follistatin structure: identification of two discontinuous N-terminal sequences coding for activin A binding and structural consequences of activin binding to native proteins. *Endocrinology.* 2000;141:3183–93.
12. Grusch M, Drucker C, Peter-Vorosmarty B, et al. Deregulation of the activin/follistatin system in hepatocarcinogenesis. *J Hepatol.* 2006;45(5):673–80.
13. Rodgarkia-Dara C, Vejda S, Erlach N, et al. The activin axis in liver biology and disease. *Mutat Res.* 2006;613:123–37.
14. Welt CK. The physiology and pathophysiology of inhibin, activin and follistatin in female reproduction. *Curr Opin Obstet Gynecol.* 2002;14:317–23.
15. Sulyok S, Wankell M, Alzheimer C, Werner S. Activin: an important regulator of wound repair, fibrosis, and neuroprotection. *Mol Cell Endocrinol.* 2004;225(1–2):127–32.
16. Beale G, Chattopadhyay D, Gray J, et al. AFP, PIVKAI, GP3, SCCA-1 and follistatin as surveillance biomarkers for hepatocellular cancer in non-alcoholic and alcoholic fatty liver disease. *BMC Cancer.* 2008;8:200.
17. Bruix J, Sherman M. Management of hepatocellular carcinoma. An update. *Hepatology.* 2011;53(3):1020–2.
18. Torane VP, Shastri JS. Comparison of ELISA and rapid screening tests for the diagnosis of HIV, hepatitis B and hepatitis C among healthy blood donors in a tertiary care hospital in Mumbai. *Indian J Med Microbiol.* 2008;26:284–5.
19. Thorpe GH, Bronstein I, Kricka LJ, Edwards B, Voyta JC. Chemiluminescent enzyme immunoassay of alpha-fetoprotein based on an adamantyl dioxetane phenyl phosphate substrate. *Clin Chem.* 1989;35(12):2319–21.
20. Zhang HJ, Yao DF, Yao M, et al. Expression characteristics and diagnostic value of annexin A2 in hepatocellular carcinoma. *World J Gastroenterol.* 2012;18(41):5897–904.
21. Forner A, Hessheimer AJ, Isabel Real M, Bruix J. Treatment of hepatocellular carcinoma. *Crit Rev Oncol Hematol.* 2006;60(2):89–98.
22. Lokman NA, Ween MP, Oehler MK, Ricciardelli C. The role of annexin A2 in tumorigenesis and cancer progression. *Cancer Microenviron.* 2011;4:199–208.
23. Bandorowicz-Pikula J, Wos M, Pikula S. Do annexins participate in lipid messenger mediated intracellular signaling? A question revisited. *Mol Membr Biol.* 2012;29(7):229–42.
24. Ueno N, Ling N, Ying SY, Esch F, Shimasaki S, Guillemin R. Isolation and partial characterization of follistatin: a single-chain Mr 35,000 monomeric protein that inhibits the release of follicle-stimulating hormone. *Proc Natl Acad Sci.* 1987;84(23):8282–6.
25. Krmeta J, Kroll J, Alves F, et al. Dissociation of angiogenesis and tumorigenesis in follistatin- and activin-expressing tumors. *Cancer Res.* 2006;66(11):5686–95.
26. Oginio H, Yano S, Kakiuchi S, et al. Follistatin suppresses the production of experimental multiple-organ metastasis by small cell lung cancer cells in natural killer cell-depleted SCID mice. *Clin Cancer Res.* 2008;14(3):660–7.
27. Fujiwara M, Marusawa H, Wang HQ, et al. Parkin as a tumor suppressor gene for hepatocellular carcinoma. *Oncogene.* 2008;27(46):6002–11.
28. Liu Z, Ling Q, Wang J, Xie H, Xu X, Zheng S. Annexin A2 is not a good biomarker for hepatocellular carcinoma in cirrhosis. *Oncol Lett.* 2013;6(1):125–9.
29. Sun Y, Gao G, Cai J, et al. Annexin A2 is a discriminative serological candidate in early hepatocellular carcinoma. *Carcinogenesis.* 2013;34:595–604.
30. Zhao P, Zhang W, Tang J, et al. Annexin II promotes invasion and migration of human hepatocellular carcinoma cells in vitro via its interaction with HAb18G/CD147. *Cancer Sci.* 2010;101:387–95.
31. Yuen MF, Norris S, Evans LW, Langley PG, Hughes RD. Transforming growth factor-beta 1, activin and follistatin in patients with hepatocellular carcinoma and patients with alcoholic cirrhosis. *Scand J Gastroenterol.* 2002;37(2):233–8.
32. Tomoda T, Nouse K, Miyahara K, et al. Prognostic impact of serum follistatin in patients with hepatocellular carcinoma. *J Gastroenterol Hepatol.* 2013;28(8):1391–6.
33. Mashima H, Kanzaki M, Nobusawa R. Derangements in the activin-follistatin system in hepatoma cells. *Gastroenterology.* 1995;108(3):834–40.
34. Rossmannith W, Chabicovsky M, Grasl-Kraupp B, Peter B, Schausberger E, Schulte-Hermann R. Follistatin overexpression in rodent liver tumors: a possible mechanism to overcome activin growth control. *Mol Carcinog.* 2002;35(1):1–5.
35. Björklund M, Koivunen E. Gelatinase-mediated migration and invasion of cancer cells. *Biochim Biophys Acta.* 2005;1755(1):37–69.
36. Littlepage LE, Sternlicht MD, Rougier N, et al. Matrix metalloproteinases contribute distinct roles in neuroendocrine prostate carcinogenesis, metastasis, and angiogenesis progression. *Cancer Res.* 2010;70(6):2224–34.