

A Retrospective Study of Ovarian Sex Cord Stromal Tumors at the Egyptian National Cancer Institute

Ihab Samy Fayek¹, Gamal Amira¹, Nevine Fayez Habashy², Mohamed A. Abd Elrauf Attia³

¹Department of Surgical Oncology, National Cancer Institute, Cairo University, Cairo, Egypt

²Department of Surgical Pathology, National Cancer Institute, Cairo University, Cairo, Egypt

³Department of Surgical Oncology, El Agouza Police Authority Hospital, Cairo, Egypt

Email: drihab74@cu.edu.eg

How to cite this paper: Fayek, I.S., Amira, G., Habashy, N.F. and Attia, M.A.A.E. (2019) A Retrospective Study of Ovarian Sex Cord Stromal Tumors at the Egyptian National Cancer Institute. *Journal of Cancer Therapy*, 10, 920-937.

<https://doi.org/10.4236/jct.2019.1012079>

Received: November 13, 2019

Accepted: December 7, 2019

Published: December 10, 2019

Copyright © 2019 by author(s) and Scientific Research Publishing Inc.

This work is licensed under the Creative Commons Attribution-NonCommercial International License (CC BY-NC 4.0).

<http://creativecommons.org/licenses/by-nc/4.0/>



Open Access

Abstract

Background: Ovarian sex cord-stromal tumors are an uncommon heterogeneous group of tumors with different biological behaviors and clinico-pathologic aspects. **Aim of the Work:** This study will review the clinico-pathologic aspects of sex-cord stromal ovarian tumors at the National Cancer Institute (NCI), Cairo University, Egypt, as well as their management and follow-up regarding disease free survival and overall survival. **Patients and Methods:** This retrospective study was conducted at the National Cancer Institute Cairo University, Egypt on female patients with ovarian sex cord stromal tumors in the period from January 2008 to December 2012 with a follow-up period of 24 to 84 months. The age of the patients, different clinical presentations, radiological findings, associated uterine bleeding (need for endometrial biopsy), pre-operative CA125 levels, surgical management done, different histopathological types, different biological behaviors, presence of ascites (and its correlation with the histopathology), Adjuvant chemotherapy (according to biological behavior and pathological type), and follow-up of non-benign cases for up to 84 months will all be documented and studied. **Results:** The mean age at presentation was 47.34; abdominal pain and mass were the commonest presentations 54.5% and 53.2% respectively; the main radiologic findings were a pelvic mass +/- ascites which had no correlation to the pathological type ($p = 0.075$). Endometrial hyperplasia and endometrial carcinoma were associated with 22% and 2.5% of cases respectively. Stages I and II represented 95% of patients with non-benign tumors (48 patients). Panhysterectomy +/- infracolic omentectomy or fertility sparing surgery were done in 70.1% and 29.9% of patients respectively. AGCTs were the commonest pathological type (49.4%). Adjuvant chemotherapy was given to 14 patients (46.7%) with non-

benign tumors. 6 recurrences (20%) in 30 patients with non-benign tumors on regular follow-up were documented. The median of disease free survival (DFS) was 50.5 months. The median overall survival was 49.5 months. Conclusion: Ovarian SCSTs are uncommon neoplasms with different biological behaviors where AGCTs are the commonest among Egyptian females. Hormonal manifestations are uncommon where abnormal vaginal bleeding is the commonest one. The presence of ascitic fluid has no correlation with the pathological type of the tumor. Early stages (I and II) represented about 95% of non-benign tumors. Surgical management without lymphadenectomy +/- adjuvant chemotherapy is the main line of treatment at our institute. The OS was shorter than that documented in the literature. A small number of patients, reluctance of follow-up and unavailability of some patients' data were the main drawbacks in this study.

Keywords

Ovarian Sex Cord Stromal Tumors, National Cancer Institute Egypt, Granulosa Cell Tumor

1. Introduction

Ovarian sex cord-stromal tumors (SCSTs) are uncommon neoplasms that represent approximately 7% of all ovarian tumors [1]. These tumors comprise a heterogeneous group and are formed by diverse cell types that arise from the primitive sex cords or stromal cells [2].

SCSTs are considered as a low-grade disease [3] and their prognosis is associated with tumor grade and disease stage [4]. They generally occur in young women of reproductive age [5].

Sex cord-stromal tumors are commonly associated with various hormone-mediated syndromes and exhibit a wide spectrum of clinical features. Tumors formed from ovarian cells (e.g., granulosa cells and theca cells) are often hyperestrogenic, whereas those comprising testicular cell types (e.g., Sertoli and Leydig cells) are usually hyperandrogenic. However, many tumors are nonfunctioning, and those comprising female cells may produce androgens and vice-versa [6].

Hormonal signs (precocious puberty, premature thelarche, Menarche) are common in younger patients and led to an early diagnosis [7]

The association of ovarian sex cord-stromal tumors with typical clinical syndromes is not the only characteristic distinguishing these tumors from the more common ovarian epithelial neoplasms [1].

Sex cord-stromal neoplasms may present in a subacute fashion (e.g. adnexal mass, pelvic or abdominal pain, gastrointestinal symptoms) in women with either early or advanced disease. These conditions are usually evaluated in an outpatient setting. Infrequently, sex cord-stromal neoplasms are discovered at the time of surgery performed for another indication [8].

Ovarian sex cord-stromal tumors may exhibit characteristic radiologic features with which radiologists should become familiar. Conversely, recognition of the spectrum of the ultrasonography (US), computed tomography (CT), and magnetic resonance imaging (MRI) appearances as well as clinicopathologic features of ovarian sex cord-stromal tumors may assist radiologists to narrow the differential diagnosis when facing ovarian tumors [1].

In Egypt and worldwide very few research studies addressed this rare group of ovarian tumors with a limited number of patients focusing mainly on the pediatric age group [7] [9] [10] [11] [12] [13], or as review articles [14] [15].

2. Aim of This Work

This study will review the clinico-pathologic aspects of sex-cord stromal ovarian tumors at the National Cancer Institute (NCI), Cairo University (Egypt), as well as their management and follow-up regarding disease free survival and overall survival.

3. Patients and Methods

This was a retrospective study that was conducted at the National Cancer Institute Cairo University-Egypt on female patients with ovarian sex cord stromal tumors in the period from January 2008 to December 2012 with a follow up period of (24 to 84 months).

The surgical management done and pathology of these tumors was reviewed for patients who presented and managed at NCI in this period of time.

The age of the patients, different clinical presentations, radiological findings, associated uterine bleeding (need for endometrial biopsy), pre-operative CA125 levels, surgical management done, different histopathological types, different biological behaviors, presence of ascites (and its correlation with the histopathology), Adjuvant chemotherapy (according to biological behavior and pathological type), and follow-up of non-benign cases for up to 84 months will all be documented and studied.

Exclusion Criteria:

- Patients diagnosed and treated outside NCI;
- Other types of ovarian tumors;
- Recurrent cases;
- Patients presented with double primary lesions;
- Mixed Pathology (not pure sex-cord stromal cells).

Outcome (End Point):

- **Overall survival** was calculated from the date of diagnosis till the date of death or last follow-up if not dead (according to availability of data).
- **Disease free survival** was calculated from the date of surgery or end of adjuvant therapy till the date of recurrence or metastasis or both or date of last follow up if no recurrence (according to availability of data).

Statistical Analysis:

Descriptive statistics was used to describe different clinicopathologic characteristic of age, symptoms, histopathology, stage, treatment categories, response to treatment and survival analysis was done. Relations between qualitative data will be done using Chi-square test or Fisher's exact test. Moreover, survival analyses will be done using Kaplan Meier's method and Comparison will be done using log-rank test. A p-value less than 0.05 will be considered significant.

Ethical Committee Approval:

Approval of surgical oncology department NCI and approval of cancer pathology department NCI were obtained. No individual patient consent was needed as the study poses no risk of harm to any of the study subjects.

4. Results

During the period from January 2008 to December 2012 according to the available recorded data at the National Cancer Institute Cairo University -Egypt, and after applying the exclusion criteria listed, seventy seven (77) female patients were diagnosed with and treated from ovarian sex-cord stromal tumors. The mean age (years) \pm standard deviation (SD) at presentation was 47.34 ± 15.92 years with a range between 13 - 84 years (**Table 1**).

At the time of presentation, More than half of the patients presented with abdominal pain in 42 patients (54.5%) and abdominal mass in 41 patients (53.2%) (**Table 2**).

Radiological findings using pelvi-abdominal ultrasound, chest X-ray and computed tomography of the chest, abdomen and pelvis with contrast showed that all patients had a pelvic mass; on the other hand, all radiological data didn't reveal any abdominal metastasis (**Table 3**).

Patients with granulosa cell tumor pathology were the main cases who presented with abnormal uterine bleeding at presentation and were subjected to endometrial biopsy, 14 patients (18.2%), followed by granulose theca cell tumor 3 patients (3.9 %) (**Table 4**).

N.B.: Only 2 cases of granulosa cell tumors were associated with synchronous endometrial carcinoma, and the rest of cases were associated with endometrial hyperplasia.

CA125 levels ranged from 5 to 849 U/ml (normal value is up to 35 U/ml). 34 patients (44.2%) had a normal level while 43 patients (55.8%) had high CA125 levels (**Table 5**).

23 young patients (29.9%) in the reproductive period with unilateral tumors confined to the ovary with no capsular rupture and no distant metastases had conservative surgery (fertility sparing surgery), while 54 patients (70.1%) underwent panhysterectomy and infracolic omentectomy. Ascitic fluid cytology was done in 8 patients with no malignant cells found in all specimens. Pelvic lymphadenectomy was sporadically done in 2 patients with no nodal metastasis in the results (**Table 6**).

Stage I and II were found in 46 patients out of 48 non-benign cases (95.8%),

Table 1. Age distribution of the patients.

Age	Total No. = 77
<50 years	46 (59.7%)
≥50 years	31 (40.3%)
Mean ± SD	47.34 ± 15.921
Range	13 - 84

Table 2. Clinical presentations of the patients.

Clinical Presentation		No.	Percent
Abdominal pain	Negative	35	45.5%
	Positive	42	54.5%
Abdominal mass +/- distention	Negative	36	46.8%
	Positive	41	53.2%
Abnormal bleeding	Negative	58	75.3%
	Positive	19	24.7%
Irregular cycle	Negative	68	88.3%
	Positive	9	11.7%
Infertility	Negative	73	94.8%
	Positive	4	5.2%

Table 3. Radiological findings of the patients.

Radiological Findings		No.	Percent
Pelvic mass	Negative	0	0.0%
	Positive	77	100.0%
Ascites	Negative	70	90.9%
	Positive	7	9.1%
Abdominal metastasis	Negative	77	100.0%
	Positive	0	0.0%
Pleural effusion	Negative	76	98.7%
	Positive	1	1.3%
Lung metastasis	Negative	76	98.7%
	Positive	1	1.3%

Table 4. Patients who underwent an endometrial biopsy according to ovarian pathology.

Type of Ovarian Tumor	No.	%
Granulosa cell tumor	14	18.2
Granulosa theca cell tumor	3	3.9
Fibroma	1	1.3
Fibrothecoma	1	1.3

Table 5. Serum CA 125 levels.

CA 125 Level	No. = 77
Median (IQR)	39 (17 - 122)
Range	5 - 849
Normal	34 (44.2%)
High	43 (55.8%)

Table 6. Operative findings and surgical procedures.

Operation	No.	%
Panhysterectomy and infracolic omentectomy	No	23 (29.9%)
	Yes	54 (70.1%)
Fertility sparing surgery	No	54 (70.1%)
	Yes	23 (29.9%)
Fluid aspiration	No	69 (89.6%)
	Yes	8 (10.4%)
Lymph nodal iliac dissection	No	75 (97.4%)
	Yes	2 (2.6%)
Metastatectomy (omental nodule)	No	76 (98.7%)
	Yes	1 (1.3%)

31 patients for stage I (64.58%) and 15 patients with stage II (31.25%), one case of GCT (2.08%) showed omental deposits (Stage III) and the other one was also of GCT subtype (2.08%) presented as stage IV with lung metastases.

Regarding the pathological types of the ovarian tumors about half of the patients (38 patients) had granulosa cell tumors (49.4%) and about one third (26 patients) had fibroma (33.8%) While the lowest percentage of patients had sertoli-leydig cell tumor and juvenile granulosa cell tumor one patient each (1.3%) (Table 7).

With further pathological categorization of the patients according to the tumor behavior, more than two thirds of the patients had benign tumors (37.7%) and borderline tumors (35.1%) collectively, while about one fifth of them had malignant tumors (18.2%) (Table 8).

Fibroma and fibrothecoma tumors represented all the benign cases in this study, 29 patients (100%). While granulosa and Granulosa theca cell tumors (12 patients) represented 85.7% of malignant cases, in this study, from 14 patients with malignancy (Table 9).

No significant relation was found between the presence of ascitic fluid and any pathological type (p -value = 0.075) (Table 10).

18 patients (23.3%) had no available postoperative recorded data. The remaining 30 patients, 14 of them (46.67%) received chemotherapy as adjuvant treatment and the rest 16 patients (53.3%) didn't receive adjuvant chemotherapy, they underwent surgical treatment then follow up (Table 11).

Table 7. Pathological types of the ovarian tumors.

Pathology	no.	%
Granulosa cell tumor	38	49.4%
Fibroma	26	33.8 %
Granulosa theca cell tumor	6	7.8%
Fibrothecoma	3	3.9%
Gynandroblastoma	2	2.6%
Juvenile granulosa cell tumor	1	1.3%
Sertoli-leydig cell tumor	1	1.3%

Table 8. Biological behaviors of the ovarian tumors and surgical procedures done.

	Benign	Borderline	Malignant	Unpredicted Biologic Behavior	Low-Grade Malignancy	Total
Panhysterectomy & infracolic omentectomy	22	20	8	3	1	54 (70.1%)
Fertility sparing surgery	7	7	6	3	0	23 (29.9%)
Total	29 (37.7%)	27 (35.1%)	14 (18.2%)	6 (7.8%)	1 (1.3%)	77 (100%)

Table 9. Biological behavior of each pathological type.

Pathology	Total No.	Benign		Border Line		Low-Grade Malignancy		Malignant		Unpredicted Biologic Behavior	
		No.	%	No.	%	No.	%	No.	%	No.	%
Granulosa cell tumor	38	0	0.0%	23	85.2%	1	100.0%	8	57.1%	6	100.0%
Fibroma	26	26	89.7%	0	0.0%	0	0.0%	0	0.0%	0	0.0%
Granulosa theca cell tumor	6	0	0.0%	2	7.4%	0	0.0%	4	28.6%	0	0.0%
Fibrothecoma	3	3	10.3%	0	0.0%	0	0.0%	0	0.0%	0	0.0%
Gynandroblastoma	2	0	0.0%	2	7.4%	0	0.0%	0	0.0%	0	0.0%
Juvenile granulosa cell tumor	1	0	0.0%	0	0.0%	0	0.0%	1	7.1%	0	0.0%
Sertoli-leydig cell tumor	1	0	0.0%	0	0.0%	0	0.0%	1	7.1%	0	0.0%

Table 10. Relation between pathology and presence of ascites.

Pathology	No Ascites		Ascites	
	No.	%	No.	%
Fibroma	23	32.90%	3	42.90%
Fibrothecoma	3	4.30%	0	0.00%
Granulosa cell tumor	35	50.00%	3	42.90%
Granulosa theca cell tumor	6	8.60%	0	0.00%
Gynandroblastoma	2	2.90%	0	0.00%

Continued

Juvenile granulosa cell tumor	0	0.00%	1	14.30%
Sertoli-leydig cell tumor	1	1.40%	0	0.00%
Chi-square tests			11.454	
P-value			0.075	

Table 11. Adjuvant chemotherapy administration

	No.	%
Benign cases	29	37.7
Non-benign cases	48 (18 patients lost postoperative follow-up or no recorded data)	62.3
Chemotherapy	16 (15 + 1 patients refused CTH)	53.3% of non-benign cases
Yes	14	46.7% of non-benign cases

Local recurrence occurred in 2 patients out of 30 (6.67%), and underwent 2nd operation for resection of recurrent tumor. Only 6 patients developed lung metastasis including the 2 patients with local recurrence (20%). All recurrent and/or metastatic cases occurred with malignant granulosa cell tumors (**Table 12**).

The patients who lost their postoperative follow-up were 12 patients with borderline tumors, 4 patients with malignancy and 2 patients with unpredicted biologic behavior tumors. Their pathologic types were: 15 cases with granulosa cell tumor and 3 cases with granulosa-theca cell tumor.

Mainly the patients with granulosa cell tumors (11 out of 23 patients) (malignant 6 patients, borderline 3 patients or unpredicted behaviors 2 patients) who received adjuvant chemotherapy from stage Ic or higher. One patient with Sertoli-Leydig and One patient with juvenile granulosa cell tumors were malignant; one patient with granulosa-theca was borderline and all received adjuvant chemotherapy (**Table 13** and **Table 14**).

Only 20 patients had a regular follow-up for at least 2 years post treatment either surgical with or without adjuvant chemotherapy; the benign cases (29 patients) had no follow-up and the remaining 28 patients had no regular follow-up at NCI (loss of follow-up or no recorded data) (**Table 15**).

All of patients remained on regular follow up to 3 years (3-years survival 100%), 80% for 4 years, 50% for 5 years (5-years survival 50%), 45% for 6 years and 15% for 7 years (7-years survival 15%) (**Table 16**).

N.B: We had no data about the date of death for any patient, so all follow-ups were calculated till the time of last follow-up, or the diagnosis of recurrence and/or metastases.

The median overall survival of the patients on regular follow up till the date of

Table 12. Follow up of non-benign cases (30 patients).

		No.	%
Local recurrence	No	28	93.3
	Yes	2	6.67
Lung metastasis	No	24	80.0
	Yes	6	20.0
2nd operation for recurrence	No	28	93.3
	Yes	2	6.67

Table 13. Biological behavior and adjuvant chemotherapy (59 patients).

Category	Chemotherapy		
		No	Yes
Benign	No.	29	0
	%	100.0%	0.0%
Borderline	No.	11	4
	%	73.3%	26.7%
Low grade malignancy	No.	1	0
	%	100.0%	0.0%
Malignant	No.	2	8
	%	20.0%	80.0%
Unpredicted biologic behavior	No.	2	2
	%	50.0%	50.0%
Total	No.	45	14
	%	76.3%	23.7%

Table 14. Pathological types and adjuvant chemotherapy (59 patients).

Pathology	Chemo Therapy		
	No	Yes	
Fibroma (benign)	No.	26	0
	%	100.0%	0.0%
Fibrothecoma (benign)	No.	3	0
	%	100.0%	0.0%
Granulosa cell tumor	No.	12	11
	%	52.17%	47.8%
Granulosa theca cell tumor	No.	2	1
	%	66.7%	33.3%
Juvenile granulosa cell tumor	No.	0	1
	%	0.0%	100.0%
Sertoli-leydig cell tumor	No.	0	1
	%	0.0%	100.0%
Gynandroblastoma	No.	2	0
	%	100.0%	0.0%

Table 15. Follow up of the patients.

	Number	Percentage
Follow-up at least 2 years	20	25.974
Lost follow-up	28	36.364
No follow-up (benign tumors)	29	37.662
Total	77	100

Table 16. Percentages of patients follow up/year.

First Two Years	Third Year	Fourth Year	Fifth Year	Sixth Year	Seventh Year
20 patients	20 patients	16 patients	10 patients	9 patients	3 patients
100%	100%	80%	50%	45%	15%

last follow up was 49.5 months (more than 4 years), and the Mean \pm SD was 51.75 ± 16.63 months (**Figure 1**).

The median of disease free survival (DFS) was 50.5 months. With a range of 1 - 78 months and the Mean \pm SD was 44.46 ± 19.18 months (**Figure 2**).

N.B: Only 2 patients showed local recurrence and lung metastasis; 3 patients showed lung metastasis. The rest of the patients' disease free survival ended at the last documented follow-up.

5. Discussion

Sex-cord stromal tumors of the ovary (SCSTs) are a heterogeneous group of uncommon tumors with different pathological types and biological behaviors [14] [15] [16], they present with a variety of clinical presentations and should be kept in mind by clinicians as a possible diagnosis [1] [17] [18].

SCSTs tend to present early with indolent course and late recurrences with a good prognosis [19] [20].

In Egypt, according to a literature review, no studies addressed this group of tumors, apart from a study in Mansoura, Egypt which focused only on pediatric age group on 42 patients with mixed pathology [9].

This retrospective study is focusing on the clinico-pathologic aspects, management, disease free and overall survival of a group of seventy seven Egyptian female patients diagnosed as, and treated from ovarian SCSTs at the National Cancer Institute, Cairo University-Egypt.

To our knowledge, this is the first Egyptian study of ovarian SCSTs in different age groups excluding mixed pathologies with germ cell tumors, and with the largest number of patients.

Although SCSTs usually present at young age, there is wide age range of presentation and wider morphologic spectrum of these tumors [1] [21]. In our study, the age in years ranged from 13 to 84 years old with a mean \pm SD of (47.34 ± 15.921) nearly as reported in the literature. Haroon *et al.*, 2013 reported a median age of 45 years (range 1 - 92), mean \pm SD was (44.3 ± 16.8) years [22].

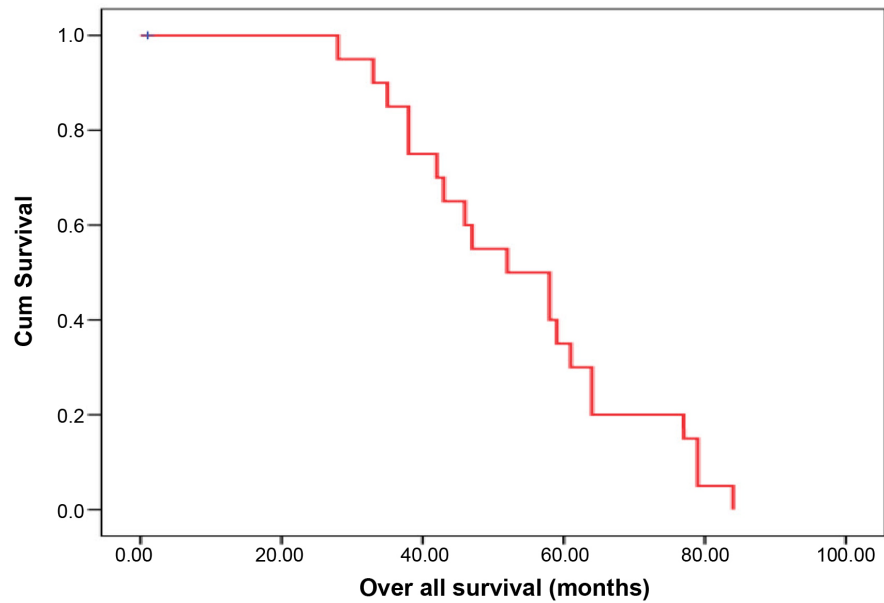


Figure 1. Overall survival (OS)/months.

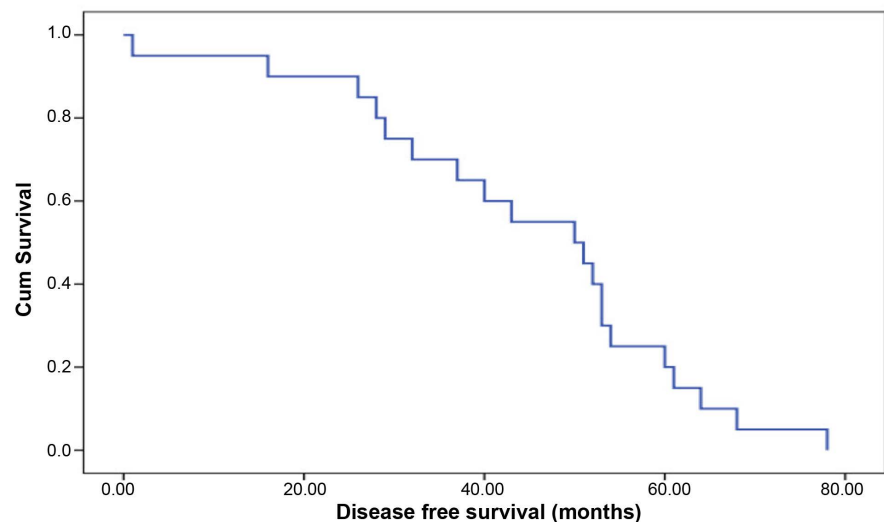


Figure 2. Disease free survival (DFS)/months.

Chan *et al.*, 2005 reported a median age of 49 years (rang 15 - 89) [19]. Zhang *et al.*, 2007 reported a mean age of (52.1 ± 0.9) years with a median age of 51 years (range 9 - 93) [20]. Holscher *et al.*, 2009 reported a mean age = median age = 55 years [23].

The main clinical presentation in more than half of our study population was abdominal pain 42 patients (54.5%) and abdominal mass +/- distension in 41 patients (53.2%), in concordance with other studies [7] [9] [10] [11] [14] [15] [24]. However, in spite the vast reputation of this group of tumors to secrete sex hormones giving rise to various clinical syndromes, none of our patients presented clinically with hormonal manifestations of precocious puberty or virilization as in other studies [1] [6] [7] [11] [19] [22] [25] [26] [27] apart from uterine

bleeding (24.7%) (2 cases had synchronous endometrial carcinoma), irregular cycles (11.7%) and infertility (5.2%), in concordance with other studies [10] [12] [28] [29] [30]. Endometrial hyperplasia was detected in 17 patients (22%) mainly with granulosa cell tumors (12 patients granulosa cell tumor, 3 patients granulosa theca cell tumor, one patient fibrothecoma and one patient fibroma), in concordance with van Meurs *et al.*, 2013 who reported endometrial hyperplasia in 25 to 50 percent of women with granulosa cell tumors and carcinoma in 5 to 10 percent [31].

A coincidental association between endometrial hyperplasia and ovarian fibroma, which is a hormonally inactive tumor [32], was recorded in our study.

CA125 (the widely used serum tumor marker for recently discovered ovarian masses at the NCI) was high (up to 849 U/ml) in more than half (55.8%) of our patients including all 7 patients where ascites was found, and patients with non-benign pathology with stage II or more. However, we didn't find a significant correlation between the presence of ascites and any pathological type ($p = 0.075$).

Almost all studies confirm that most of ovarian SCSTs present mainly in an early stage, namely stage I [1] [11] [12] [16] [20] [27] [29] [33] [34] [35], this is in agreement with our study where stage I represented 64.58% and stage II 31.25% of non-benign tumors, collectively representing 95.8%.

Primary therapy for SCSTs generally begins with standard surgical staging including a total abdominal hysterectomy and bilateral salpingo-oophorectomy. For younger patients with early-stage disease, conservative surgery (Fertility sparing surgery, FSS) in the form of unilateral salpingo-oophorectomy has been suggested as a safe treatment alternative for those wishing to retain fertility [9] [10] [11] [12] [14] [20] [22] [23] [35] [36] [37]. On the other hand, Thomakos *et al.*, 2016 in a recent retrospective, population-based cohort of 255 premenopausal women with SCSTs confined to the ovary, findings showed that patients who underwent FSS presented a cancer-specific survival over 20 years follow-up (but not overall survival) that was inferior to those who conducted a definitive surgery (bilateral salpingo oophorectomy and hysterectomy [38]). In our study conservative surgery (fertility sparing surgery) was done for 23 patients (30%), and radical surgery in the form of total abdominal hysterectomy and bilateral salpingo-oophorectomy was done for 54 patients (70%). On the other hand, Zhang *et al.* 2007 performed non conservative surgery in 63% and uterine preserving surgery in 34% of their patients [20]. Elashry *et al.*, 2013 performed FSS in Twenty-eight cases (66.7%) of pediatric age group in their study [9]. Zanagalo *et al.*, 2004 in a Clinical review of 63 cases of sex cord stromal tumors performed conservative surgical treatment in 11 out of 47 cases (23%) of early stage tumors [12].

As a part of the surgical management in our institute for this kind of tumors, pelvic nodal dissection is only done if preoperative radiologic findings and intraoperative findings revealed suspicious nodal metastasis. Only 2 patients out

of 48 with non-benign tumors (4.16%) in this study underwent pelvic nodal dissection which proved free by pathological examination, this is in concordance with many studies that stated that lymph node metastases are rare with the possibility of omitting nodal dissection without affecting the prognosis of SCSTs of the ovary [20] [23] [34] [38] [39] [40].

Brown *et al.* 2009 operated 58 patients (22%) who had nodal tissue examined during initial surgery; none of them had positive nodes [39]. Thrall *et al.* 2011 operated 47 patients (54%) who had some lymph nodal tissue examination, there was no nodal involvement [34]. However, with Chan *et al.* 2005 66% of patients underwent lymph node sampling and pathological assessment only 7% of them had nodal metastasis [19].

There is almost an agreement among many studies that adult Granulosa cell tumors (AGCTs) are the most frequent pathological type of SCSTs with different percentages among their patients, 70% [20]; 42.4% [24]; 95% [41] [42] and 49.4% in our study.

Next to AGCTs in incidence among our study population was the fibromas (33.8%), mixed granulosa cell and theca cell tumors (7.8%), fibrothecoma (3.9%), juvenile granulosa cell tumor (1.3%), and sertoli-leydig cell tumor (poorly differentiated) (1.3%). Nearly the same percentages were reported in the literature with mild differences had been found [12] [19] [20] [23] [24] [32] [41] [42].

On the other hand some pathological types were not reported in our study may be due to the small sample size, short time of the study (5 years) compared to other studies, as long as 10 years with Zhang *et al.* 2007; 20 years with Brown *et al.* 2009; Thrall *et al.* 2011; Haroon *et al.* 2013 and 28 years with Holscher *et al.* 2009; Chan *et al.* 2005; in addition to the rarity of these tumors.

We documented 48 non-benign tumors with different biological behaviors, borderline 27 tumors, malignant 14 tumors, low-grade malignancy one tumor and unpredicted biologic behavior 6 tumors. Unfortunately, we were not able to retrieve the data about postoperative adjuvant therapy or follow up of 18 patients out of the 48 non-benign cases. From the rest of the patients (30 patients) only 14 (46.67%) patients received adjuvant chemotherapy (mainly *bleomycin/etoposide/cisplatinum or fluorouracil*). as reviewed in the literature There are no data that support specific postoperative adjuvant treatment for patients with (FIGO-Stage I) [23], also no evidence-based guidelines to inform the postoperative treatment of malignant sex cord stromal tumors, multiple lines of treatment were used. Due to the rarity of ovarian sex cord-stromal tumors, no prospective randomized clinical trial data still exist [23] [27] [32] [42].

In this study we had 6 recurrent cases (20 %) of non-benign cases (30 patients) with available data, this is the same percentage of relapse documented by Coquard *et al.*, 2018 stating that the majority can be cured but relapses may be fatal [35], and less than Wilson *et al.*, 2015 who reported 32% relapse given that the median overall survival in the population that experienced relapse was more than 20 years [43]. Two patients with local recurrence associated with pulmo-

nary nodules, second operation of excision was done for locally recurrent masses, 3 patients presented on follow up with pulmonary nodules and only one patient with lung nodules associated with small hepatic focal lesion likely metastasis but this patient refused treatment and follow up (not included in survival analysis). All our recurrent cases were granulosa cell tumor in concordance with the largest studies [19] [34] [39]. In comparison with what reported in the literature [19] [34] [39], we had low numbers of recurrences, may be due to the short time of follow-up

Ovarian SCSTs may take a long time for recurrence to develop. Chan *et al.*, 2005 reported 24% of recurrences with a median time of recurrence 49 months (range 7 - 193 months) [19]. Thrall *et al.*, 2011 reported 20.6% of patients who at least had one episode of disease recurrence with a median time to recurrence of 46.6 months (range 2.6 - 186 months) following diagnosis [34]. Brown *et al.*, 2009 with the largest sample size (257 patients) 45% of cases had recurrences in median time to last follow up (100.6 months) mainly with granulosa cell tumors with local recurrence, distant metastasis (mainly liver, lung and spleen) and small number of cases with lymph node metastasis. Patients of recurrent disease had negative lymph node at the time of their primary surgery. Multiple recurrences had occurred in 18.6% of patients (range 2 - 11 episodes).

Chan *et al.*, 2005 reported a median DFS of 49 months (range: 7 - 193) with additional recurrences may be expected with longer follow up [19]. Nearly similar, to the median DFS in our study, this was 50.5 months. With a (range of 1 - 78 months) and the Mean \pm SD was 44.46 ± 19.18 months.

Due to shorter follow-up period in our study compared to other studies, and the increased loss of follow-up of our patients, the resulting median overall survival for our patients was 49.50 months and the mean \pm SD was 51.75 ± 16.63 months, which is shorter in comparison with other studies where the median survival was 130 months (10.83 years) in Thrall *et al.*, 2011 [34]; in Holscher *et al.*, 2009 the mean survival was 10.8 years (58.6% lost their follow up and 41.4 % deceased) [23].

The 5-year survival reported ranged from 55% - 95% in Shah *et al.*, 2009 [44]; and 49% - 86% in Chan *et al.*, 2005 [19]; and 57% - 90% in Kottarathil *et al.*, 2013 [29]; in Zhang *et al.*, 2007 the 10-years survival was 79% [20]. In our study, the 5-year survival for all stages was 50% and the 7-year survival was as low as 15%, this is mainly due to the small sample size with loss of some follow-ups and unavailability of certain documented data. Further studies, on a multi-institutional base, with a larger sample size and a longer follow-up period are needed.

6. Conclusion

Ovarian SCSTs are uncommon neoplasms with different biological behaviors where AGCTs are the commonest among Egyptian females. Hormonal manifestations are uncommon where abnormal vaginal bleeding is the commonest one. The presence of ascitic fluid has no correlation with the pathological type of the

tumor. Early stages (I and II) represented about 95% of non-benign tumors. Surgical management without lymphadenectomy +/- adjuvant chemotherapy is the main line of treatment at our institute. The OS was shorter than that documented in the literature. The limited number of patients, reluctance of follow-up and unavailability of some patients' data were the main drawbacks in this study.

Conflicts of Interest

The authors declare no conflicts of interest regarding the publication of this paper.

References

- [1] Horta, M. and Cunha, T.M. (2015) Sex Cord-Stromal Tumors of the Ovary: A Comprehensive Review and Update for Radiologists. *Diagnostic and Interventional Radiology*, **21**, 277-286. <https://doi.org/10.5152/dir.2015.34414>
- [2] Shim, S.H., Kim, D.Y., Lee, S.W., *et al.* (2013) Laparoscopic Management of Early Stage Malignant Non-Epithelial Ovarian Tumors: Surgical and Survival Outcomes. *International Journal of Gynecological Cancer*, **23**, 249-255. <https://doi.org/10.1097/IGC.0b013e318272e754>
- [3] Zhang, N., Chen, R., Hua, K. and Zhang, Y. (2017) A Retrospective Study of Reproductive Outcomes after Fertility-Sparing Surgery and Postoperative Adjuvant Chemotherapy in Malignant Ovarian Germ Cell Tumors and Sex Cord-Stromal Tumors. *Journal of Ovarian Research*, **10**, 52. <https://doi.org/10.1186/s13048-017-0348-x>
- [4] Akman, L., Ertas, I., Gokcu, M., Terek, M., Sancı, M., Sanlı, U., *et al.* (2016) Ovarian Sertoli-Leydig Cell Tumors: A Multicenter Long-Term Clinicopathological Analysis of 27 Patients. *Journal of Cancer Research and Therapeutics*, **12**, 290-294. <https://doi.org/10.4103/0973-1482.158037>
- [5] Stavrakis, T., Kalogiannidis, I., Petousis, S., Tsompanidou, C., Delkos, D., Prapas, N., *et al.* (2016) Fertility-Sparing Management and Obstetric Outcomes in a 20-Year-Old Patient with a Sertoli-Leydig Cell Tumor of the Ovary: A Case Report and Review of the Literature. *Oncology Letters*, **12**, 1079-1082. <https://doi.org/10.3892/ol.2016.4695>
- [6] Pratt, J. (2004) Pathology of the Ovary. Saunders, Philadelphia, 197-226.
- [7] Cecchetto, G., Ferrari, A., Bernini, G., Alaggio, R., Collini, P., Virgone, C., Terenziani, M., Dall'Igna, P., Ra Cozza, R., Conte, M. and Bisogno, G. (2011) Sex Cord Stromal Tumors of the Ovary in Children: A Clinicopathological Report from the Italian TREP Project. *Pediatric Blood & Cancer*, **56**, 1062-1067. <https://doi.org/10.1002/pbc.22918>
- [8] Shanbhogue, A.K., Shanbhogue, D.K., Prasad, S.R., *et al.* (2010) Clinical Syndromes Associated with Ovarian Neoplasms: A Comprehensive Review. *Radiographics*, **30**, 903. <https://doi.org/10.1148/rg.304095745>
- [9] Elashry, R., Hemida, R., Goda, H. and Abdel-Hady, el-S. (2013) Prognostic Factors of Germ Cell and Sex Cord-Stromal Ovarian Tumors in Pediatric Age: 5 Years' Experience. *Journal of Experimental Therapeutics and Oncology*, **10**, 181-187.
- [10] Ghalleb, M., Bouzaiene, H., Sghaier, S., Bouaziz, H., Hechiche, M., Hassouna, J.B. and Rahal, K. (2018) Fertility Sparing Surgery for Ovarian Sex Cord Stromal Tumors: A Nine Case Series. *Pan African Medical Journal*, **31**, 221. <https://doi.org/10.11604/pamj.2018.31.221.15531>

- [11] Haroon, S., Idrees, R., Zia, A., Memon, A., Fatima, S. and Kayani, N. (2014) Ovarian Sex Cord Stromal Tumours in Children and Young Girls—A More than Two Decade Clinicopathological Experience in a Developing Country, Pakistan. *Asian Pacific Journal of Cancer Prevention*, **15**, 1351-1355. <https://doi.org/10.7314/APJCP.2014.15.3.1351>
- [12] Zanagnolo, V., Pasinetti, B. and Sartori, E. (2004) Clinical Review of 63 Cases of Sex Cord Stromal Tumors. *European Journal of Gynaecological Oncology*, **25**, 431-438.
- [13] Schneider, D.T., Calaminus, G., Harms, D. and Göbel, U. (2005) Ovarian Sex Cord-Stromal Tumors in Children and Adolescents. *The Journal of Reproductive Medicine*, **50**, 439-446.
- [14] Schultz, K.A., Harris, A.K., Schneider, D.T., Young, R.H., Brown, J., Gershenson, D.M., Dehner, L.P., Hill, D.A., Messinger, Y.H. and Frazier, A.L. (2016) Ovarian Sex Cord-Stromal Tumors. *Journal of Oncology Practice*, **12**, 940-947. <https://doi.org/10.1200/JOP.2016.016261>
- [15] Boussios, S., Moschetta, M., Zarkavelisa, Papadakia, G.A., Kefasa, A. and Tatsid, K. (2017) Ovarian Sex-Cord Stromal Tumours and Small Cell Tumors: Pathological, Genetic and Management Aspects. *Critical Reviews in Oncology/Hematology*, **120**, 43-51. <https://doi.org/10.1016/j.critrevonc.2017.10.007>
- [16] Young, R.H. (2018) Reflections on a 40-Year Experience with a Fascinating Group of Tumors, Including Comments on the Seminal Observations of Robert E. Scully. *Archives of Pathology & Laboratory Medicine*, **142**, 1459-1484. <https://doi.org/10.5858/arpa.2018-0291-RA>
- [17] Chin, V.L., Sheffer-Babila, S., Lee, T.A., Tanaka, K. and Zhou, P. (2012) A Case of Complete Androgen Insensitivity Syndrome with a Novel Androgen Receptor Mutation. *Journal of Pediatric Endocrinology and Metabolism*, **25**, 1145-1151. <https://doi.org/10.1515/jpem-2012-0135>
- [18] Virgone, C., Cecchetto, G., Ferrari, A., *et al.* (2012) GATA-4 and FOG-2 Expression in Pediatric Ovarian Sex Cord-Stromal Tumors Replicates Embryonal Gonadal Phenotype: Results from the TREP Project. *PLoS ONE*, **7**, e45914. <https://doi.org/10.1371/journal.pone.0045914>
- [19] Chan, J.K., Zhang, M., Kaleb, V., *et al.* (2005) Prognostic Factors Responsible for Survival in Sex Cord Stromal Tumors of the Ovary—A Multivariate Analysis. *Gynecologic Oncology*, **96**, 204-209. <https://doi.org/10.1016/j.ygyno.2004.09.019>
- [20] Zhang, M., Cheung, M.K., Shin, J.Y., *et al.* (2007) Prognostic Factors Responsible or Survival in Sex Cord Stromal Tumors of the Ovary—An Analysis of 376 Women. *Gynecologic Oncology*, **104**, 396. <https://doi.org/10.1016/j.ygyno.2006.08.032>
- [21] Nucci, M.R. and Oliva, E. (2009) Gynecologic Pathology. In: Deaver, M.T., Oliva, E. and Nucci, M.R., Eds., *Sex Cord-Stromal Tumors of the Ovary*, Elsevier, Churchill Livingstone, 457-460.
- [22] Haroon, S., Zia, A., Idrees, R., *et al.* (2013) Clinicopathological Spectrum of Ovarian Sex Cord-Stromal Tumors; 20 Years' Retrospective Study in a Developing Country. *Journal of Ovarian Research*, **6**, 87. <https://doi.org/10.1186/1757-2215-6-87>
- [23] Hölscher, G., Anthuber, C., Bastert, G., *et al.* (2009) Improvement of Survival in Sex cord Stromal Tumors—An Observational Study with More than 25 Years Follow-Up. *Acta Obstetrica et Gynecologica Scandinavica*, **88**, 440. <https://doi.org/10.1080/00016340902741208>
- [24] Bhargava, S., Vyas, J. and Bhargava, A. (2017) Ovarian Sex Cord Stromal Tumors: An Institutional Experience. *International Journal of Reproduction, Contraception, Obstetrics and Gynecology*, **6**, 3924-3926.

- <https://doi.org/10.18203/2320-1770.ijrcog20174036>
- [25] Hricak, H. (2007) Fibrothecoma and Sclerosing Stromal Tumor. In: Hricak, H., Akin, O., Sala, E., Ascher, S.M., Levine, D. and Reinhold, C., Eds., *Diagnostic Imaging. Gynecology*, Amirsys, Salt Lake City, 728-731.
- [26] Tanaka, Y.O., Tsunoda, H., Kitagawa, Y., Ueno, T., Yoshikawa, H. and Saida, Y. (2004) Functioning Ovarian Tumors: Direct and Indirect Findings at MR Imaging. *Radiographics*, **24**, S147-S166. <https://doi.org/10.1148/rg.24si045501>
- [27] Gershenson, D.M. (2012) Current Advances in the Management of Malignant Germ Cell and Sex Cord-Stromal Tumors of the Ovary. *Gynecologic Oncology*, **125**, 515-517. <https://doi.org/10.1016/j.ygyno.2012.03.019>
- [28] Ranganath, R., Sridevi, V., Shirley, S.S. and Shantha, V. (2008) Clinical and Pathologic Prognostic Factors in Adult Granulosa Cell Tumors of the Ovary. *International Journal of Gynecological Cancer*, **18**, 929-933. <https://doi.org/10.1111/j.1525-1438.2007.01154.x>
- [29] Kottarathil, V.D., Antony, M.A., Nair, I.R. and Pavithran, K. (2013) Recent Advances in Granulosa Cell Tumor Ovary: A Review. *Indian Journal of Surgical Oncology*, **4**, 37-47. <https://doi.org/10.1007/s13193-012-0201-z>
- [30] Schneider, D.T., Calaminus, G., Wessalowski, R., et al. (2003) Ovarian Sex Cord-Stromal Tumors in Children and Adolescents. *Journal of Clinical Oncology*, **21**, 2357-2363. <https://doi.org/10.1200/JCO.2003.05.038>
- [31] van Meurs, H.S., Bleeker, M.C., van der Velden, J., et al. (2013) The Incidence of Endometrial Hyperplasia and Cancer in 1031 Patients with a Granulosa Cell Tumor of the Ovary: Longterm Follow-Up in a Population-Based Cohort Study. *International Journal of Gynecological Cancer*, **23**, 1417-1422. <https://doi.org/10.1097/IGC.0b013e3182a57fb4>
- [32] Cho, Y.J., Lee, H.S., Kim, J.M., Joo, K.Y. and Kim, M.L. (2013) Clinical Characteristics and Surgical Management Options for Ovarian Fibroma/Fibrothecoma: A Study of 97 Cases. *Gynecologic and Obstetric Investigation*, **76**, 182-187. <https://doi.org/10.1159/000354555>
- [33] Ferrari, A., Bisogno, G., De Salvo, G.L., et al. (2007) The Challenge of Very Rare Tumors in Childhood: The Italian TREP Project. *European Journal of Cancer*, **43**, 654-659. <https://doi.org/10.1016/j.ejca.2006.08.028>
- [34] Thrall, M.M., Paley, P., Pizer, E., et al. (2011) Patterns of Spread and Recurrence of Sex Cord-Stromal Tumors of the Ovary. *Gynecologic Oncology*, **122**, 242. <https://doi.org/10.1016/j.ygyno.2011.03.020>
- [35] Coquard, I.R., Morice, P., Lorusso, D., Prat, J., Oaknin, A., Pautier, P. and Colombo, N. (2018) Non-Epithelial Ovarian Cancer: ESMO Clinical Practice Guidelines. *Annals of Oncology*, **29**, iv1-iv18. <https://doi.org/10.1093/annonc/mdy001>
- [36] Ray-Coquard, I., Brown, J., Harter, P., Provencher, D.M., Fong, P.C., Maenpaa, J., et al. (2014) Gynecologic Cancer InterGroup (GCIg) Consensus Review for Ovarian Sex Cord Stromal Tumors. *International Journal of Gynecological Cancer*, **24**, S42-S47. <https://doi.org/10.1097/IGC.0000000000000249>
- [37] Rasool, N. and Rose, P.G. (2010) Fertility-Preserving Surgical Procedures for Patients with Gynecologic Malignancies. *Clinical Obstetrics and Gynecology*, **53**, 804-814. <https://doi.org/10.1097/GRF.0b013e3181f97d02>
- [38] Thomakos, N., Biliatis, I., Koutroumpa, I., Sotiropoulou, M., Bamias, A., Liontos, M., et al. (2016) Prognostic Factors for Recurrence in Early Stage Adult Granulosa Cell Tumor of the Ovary. *Archives of Gynecology and Obstetrics*, **294**, 1031-1036. <https://doi.org/10.1007/s00404-016-4135-5>

- [39] Brown, J., Sood, A.K., Deavers, M.T., *et al.* (2009) Patterns of Metastasis in Sex Cord-Stromal Tumors of the Ovary: Can Routine Staging Lymphadenectomy Be Omitted? *Gynecologic Oncology*, **113**, 86. <https://doi.org/10.1016/j.ygyno.2008.12.007>
- [40] Nasioudis, D., Kanninen, T.T., Holcomb, K., *et al.* (2017) Prevalence of Lymph Node Metastasis and Prognostic Significance of Lymphadenectomy in Apparent Early Stage Malignant Ovarian Sex Cord Stromal Tumors. *Gynecologic Oncology*, **145**, 243-247. <https://doi.org/10.1016/j.ygyno.2017.03.005>
- [41] Outwater, E.K., Wagner, B.J., Mannion, C., McLarney, J.K. and Kim, B. (1998) Sex Cord-Stromal and Steroid Cell Tumors of the Ovary. *Radiographics*, **18**, 1523-1546. <https://doi.org/10.1148/radiographics.18.6.9821198>
- [42] Jung, S.E., Lee, J.M. and Rha, S.E. (2002) CT and MR Imaging of Ovarian Tumors with Emphasis on Differential Diagnosis. *Radiographics*, **22**, 1305-1325. <https://doi.org/10.1148/rg.226025033>
- [43] Wilson, M.K., Fong, P., Mesnage, S., *et al.* (2015) Stage I Granulosa Cell Tumours: A Management Conundrum? Results of Long-Term Follow up. *Gynecologic Oncology*, **138**, 285-291. <https://doi.org/10.1016/j.ygyno.2015.05.011>
- [44] Shah, S.P., Köbel, M., Senz, J., Morin, R.D., Clarke, B.A., Wiegand, K.C., *et al.* (2009) Mutation of FOXL2 in Granulosa-Cell Tumors of the Ovary. *The New England Journal of Medicine*, **360**, 2719-2729.