

# Colocasia esculenta L. Schott Corm Mucilage: A Selective COX-2 Inhibitor for Treatment of Irritable Bowel Syndrome

Nesrin M. Fayek, Samar M. Mouneir<sup>1</sup>, Azza Ramy Abdel Monem, Samia M. Abdelwahab, Nebal D. Eltanbouly

Department of Pharmacognosy, Faculty of Pharmacy, Cairo University, <sup>1</sup>Department of Pharmacology, Faculty of Veterinary Medicine, Cairo University, Cairo, Egypt

Submitted: 20-Oct-2020

Revised: 08-Jan-2021

Accepted: 23-Mar-2021

Published: 12-Jul-2021

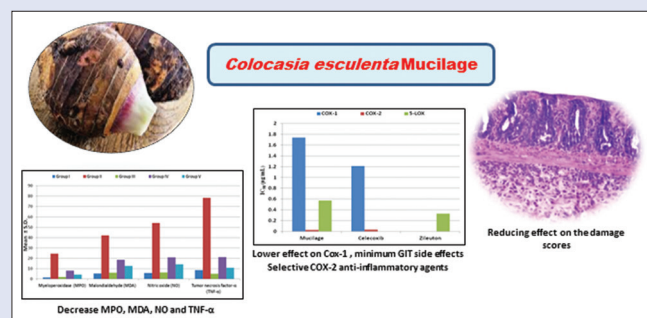
## ABSTRACT

**Background:** Therapeutic strategies used for the treatment of irritable bowel syndrome having many limitations due to their side effects; this necessitates searching for new substitutes with similar therapeutic results and limited side effects. In the present study, the anti-inflammatory activity of the mucilage of *Colocasia esculenta* L. Schott var. typical corm cultivated in Egypt was explored both *in vivo* and *in vitro*. **Materials and Methods:** *In vivo* anti-inflammatory activity was evaluated based on histopathological examination, determination of ulcer area and ulcer index, and measurement of inflammatory mediators, namely, myeloperoxidase, malondialdehyde, nitric oxide, and tumor necrosis factor- $\alpha$ , in acetic acid-induced ulcerated rat colon, comparing to Prednisolone as a reference drug. *In vitro* evaluation of the anti-inflammatory activity of the tested mucilage was carried out by measuring its cyclooxygenase (COX-1/COX-2) and 5-lipoxygenase inhibitory activity comparing to Celecoxib and Zileuton as reference drugs, respectively. **Results:** Pretreatment with the mucilage improved the histopathological features of the rats ulcerated colon and decreased the ulcer area and the ulcer index in a dose-dependent manner. The mucilage improved all the tested inflammatory mediators. In addition, it has a potent COX-2 inhibitory activity with lower effect on COX-1 and 5-lipoxygenase. **Conclusion:** The obtained results support the use of *C. esculenta* corm mucilage as an alternative for the treatment of inflammatory bowel disease with minimum gastrointestinal side effects. **Key words:** Anti-inflammatory activity, *Colocasia esculenta*, mucilage

## SUMMARY

- *Colocasia esculenta* corm mucilage improved the histopathological features in acetic acid induced ulcerated rat colon and decreased the ulcer area and ulcer index in a dose dependent manner. The mucilage improved all the tested inflammatory mediators viz. myeloperoxidase, malondialdehyde, nitric oxide and tumor necrosis factor- $\alpha$ , comparing to Prednisolone. The mucilage

showed a potent cyclooxygenase-2 inhibitory activity with lower effect on cyclooxygenase-1 and 5-lipoxygenase comparing to Celecoxib and Zileuton, respectively.



**Abbreviation list:** COX: cyclooxygenase; IBD: inflammatory bowel disease; LOX: lipoxygenase; MDA: malondialdehyde; MPO: myeloperoxidase; NO: nitric oxide; p.o.: per oral; pg/mg: picograms/mg; TNF- $\alpha$ : tumor necrosis factor- $\alpha$ ; g: gram; h: hour; mg/kg/day: milligram/kilogram/day; IC50: Half-maximal inhibitory concentration; mg/kg b.wt: milligram/kilogram/body weight;  $\mu$ g/mL: microgram/milliliter

## Correspondence:

Prof. Azza Ramy Abdel Monem,  
Department of Pharmacognosy, Faculty of  
Pharmacy, Cairo University, Cairo 11562, Egypt.  
E-mail: [azza.abdelmonem@pharma.cu.edu.eg](mailto:azza.abdelmonem@pharma.cu.edu.eg)  
DOI: 10.4103/pm.pm\_488\_20

## Access this article online

Website: [www.phcog.com](http://www.phcog.com)

## Quick Response Code:



## INTRODUCTION

Inflammatory diseases of the intestinal tract (inflammatory bowel disease [IBD]) include ulcerative colitis and Crohn's disease. Ulcerative colitis is limited to the colon and/or rectum and affects only the inner lining of the intestine, while Crohn's disease can affect any part of the gut from mouth to anus as skip lesions and affect the whole thickness of the bowel wall.<sup>[1]</sup> Nonsteroidal anti-inflammatory drugs, worldwide, are commonly used for excellent anti-inflammatory effect, but with limited use as a result of their severe side effects such as gastrointestinal ulceration, perforation, obstruction, and bleeding.<sup>[2]</sup> This suggests that seeking for other drugs harboring similar therapeutic results and limited side effects are urgently necessary. Several reports describe a significant anti-inflammatory activity for plants rich in mucilage, for example, *Trigonella foenum-graecum*<sup>[3]</sup> and *Aloe littoralis*.<sup>[4]</sup> *Colocasia esculenta* L. Schott corm is rich with mucilage, up to 22.3%,<sup>[5]</sup> and it is used in Egypt as a food. Although previous studies proved that *C. esculenta* L. Schott leaves have anti-inflammatory activity,<sup>[6,7]</sup> no study has been performed to evaluate the anti-inflammatory activity of *C. esculenta* L. Schott corm mucilage. Consequently, this study was carried out to evaluate the *in vivo*

and *in vitro* anti-inflammatory activity of the mucilage of *C. esculenta* corms cultivated in Egypt.

## MATERIALS AND METHODS

### Plant material

The fresh *C. esculenta* L. Schott var. typical corms were collected in 1<sup>st</sup> week of January 2017 from the experimental field in Faculty of Agriculture. The plant was identified by Prof. Dr. Hassan Ali Hassan, Department of vegetable crops, Faculty of Agriculture, Cairo University, Giza, Egypt.

This is an open access journal, and articles are distributed under the terms of the Creative Commons Attribution-NonCommercial-ShareAlike 4.0 License, which allows others to remix, tweak, and build upon the work non-commercially, as long as appropriate credit is given and the new creations are licensed under the identical terms.

For reprints contact: [WKHLRPMedknow\\_reprints@wolterskluwer.com](mailto:WKHLRPMedknow_reprints@wolterskluwer.com)

**Cite this article as:** Fayek NM, Mouneir SM, Monem AR, Abdelwahab SM, Eltanbouly ND. *Colocasia esculenta* L. schott corm mucilage: A selective COX-2 inhibitor for treatment of irritable bowel syndrome. Phcog Mag 2021;17:387-90.

## Preparation of mucilage

Preparation of mucilage was done following the method described by Sarkar *et al.*<sup>[8]</sup>

## Drugs and chemicals

Acetic acid was purchased from Merck, Darmstadt, Germany. Prednisolone, Celecoxib and Zileuton, as an anti-inflammatory reference drugs, were obtained from Chemical Industries Development Co., Giza, Egypt.

## Experimental animals

Three-month-old male and female Wistar strain rats (130–150 g) were purchased from laboratory animal house of Faculty of Veterinary Medicine, Cairo University. The animal room was maintained at 22°C–24°C and a lighting regimen of 12 h light/12 h dark. Animals had free access to standard house chow and water *ad libitum*. All experimental procedures were performed according to the ethical roles of Faculty of Veterinary Medicine, Cairo University.

## In vivo evaluation of the anti-inflammatory effect

### Induction of ulcerative colitis

Experimental ulceration in colon tissue was done according to the method described by Al-Rejaie *et al.* 2013.<sup>[9]</sup>

## Experimental design

Twenty-five animals were divided into five groups (five animals in each) as follow: Group I: Normal animals; received 2 mg/kg/day of distilled water. Group II: Acetic acid control animals; received 2 mL of 4% acetic acid solution intrarectally on the 8<sup>th</sup> day. Group III: Prednisolone standard treated animals; received prednisolone (2 mg/kg, p.o., for 3 days) and acetic acid (2 mL of 4% solution, once on the 8<sup>th</sup> day, intrarectally). Prednisolone and acetic acid treatment were started on the same day. Group IV: Mucilage (10 mg/kg) treated animals; received 7 days pretreatment with 10 mg/kg of mucilage, p. o. and 2 mL of 4% acetic acid solution, intrarectally on the 8<sup>th</sup> day. Drug treatment was continued till 11<sup>th</sup> day. Group V: Mucilage (20 mg/kg)-treated animals; received 7 days pretreatment with 20 mg/kg of mucilage, p.o., and 2 mL of 4% acetic acid solution, intrarectally on the 8<sup>th</sup> day. Drug treatment was continued till the 11<sup>th</sup> day.

On the 11<sup>th</sup> day, animals were euthanized by over dose of chloroform anesthesia and their colons were collected for examination and preparation of tissue homogenate.

## Histopathological study

Autopsy samples were taken from the colon of rats in the different animal groups and prepared for microscopic examination following the method of Bancroft *et al.*<sup>[10]</sup>

## Ulcer index

Determination of ulcer area and ulcer index was done according to Kandhare *et al.*<sup>[11]</sup>

## Biochemical assays

Samples from the colon were stored immediately at –80°C till analysis. Tissue samples were homogenized in 10 mmol Tris–HCl buffer (pH 7.1), and the homogenate was utilized for the measurement of inflammatory mediators.<sup>[12]</sup> Myeloperoxidase (MPO) and malondialdehyde (MDA) detection kits were purchased from Hycult biotech and Sigma-Aldrich Co., respectively, while nitric oxide (NO) and tumor necrosis

factor- $\alpha$  (TNF- $\alpha$ ) detection kits were purchased from Thermo Fisher Scientific and RayBiotech, Inc., respectively.

## In vitro evaluation of the anti-inflammatory effect Cyclooxygenase-1/cyclooxygenase-2 inhibition assay

The inhibitory cyclooxygenase (COX) activity of the tested mucilage and the reference drug (Celecoxib) was assayed using Cayman colorimetric COX (ovine) inhibitor screening assay kit (Catalog No. 760111), purchased from Cayman chemicals, MI, USA and IBL International GmbH, Hamburg, Germany according to the manufacturer's instructions.<sup>[12]</sup>


### 5-lipoxygenase inhibition assay

It was carried out on the tested mucilage and the reference drug (Zileuton) using CM760700 kit, purchased from Cayman chemicals, MI, USA and IBL International GmbH, Hamburg, Germany, according to the manufacturer's instructions.<sup>[13]</sup>

## Statistical analysis

Data of *in vivo* anti-inflammatory activity were expressed as the mean  $\pm$  standard deviation, determination was carried out in triplicates. The statistical significance of differences between the mean values was analyzed by one-way analysis of variance followed by *posthoc* test and least-significant difference,<sup>[14]</sup> using SPSS software (SPSS INnc., Chicago, USA). A value of  $P < 0.05$  was considered statistically significant for analysis.

The IC<sub>50</sub> values of *in vitro* anti-inflammatory activity and anticancer activity were calculated according to the equation for the Boltzmann sigmoidal concentration response curve using non-linear regression



**Figure 1:** Histopathological changes of (a) control negative group; (b) control positive group; (c) standard (prednisolone) group; (d) treated group with 10 mg/kg. b.wt of mucilage; (e) treated group with 20 mg/kg b.wt of mucilage (X = 40)

fitting models (Graph Pad, Prism Version 5 (GraphPad Software, San Diego, California)).

## RESULTS

### *In vivo* anti-inflammatory activity

#### Histopathological examination

The histopathological investigation as presented in Figure 1, showing no alteration in the control negative group [Group I and Figure 1a] with normal histological structure of the mucosa with glandular structure and lamina propria and the underlying submucosa, muscularis and serosa. In the control positive group [Group II and Figure 1b], focal ulceration and necrosis with inflammatory cells infiltration were detected in the mucosa, submucosa, and serosal layers. In the standard (Prednisolone) group [Group III, Figure 1c], the mucosa was intact, while the underlying submucosa showed inflammatory cells infiltration. In the group treated with 10 mg/kg b.wt of mucilage [Group IV, Figure 1d], focal ulceration and necrosis were seen, while the underlying submucosa had inflammatory cells infiltration and hemorrhages. In higher dose of the mucilage [20 mg/kg. b.wt, Group V, Figure 1e], edema with inflammatory cells infiltration were seen and congested blood vessels were recorded in the lamina propria of the mucosa as well as in the submucosa.

#### Effect of colocasia mucilage on ulcer area and ulcer index

The mean ulcer area and ulcer index of acetic acid control group were ( $27.8 \pm 1.92$ ) mm<sup>2</sup> and ( $55.6 \pm 1.94$ ), respectively, indicating high ulcerogenic effect of acetic acid. Pretreatment of *Colocasia* mucilage (10 and 20 mg/kg, p.o.) for 7 days decreased the ulcer area ( $[20 \pm 2.54]$  and  $[11.6 \pm 1.51]$  mm<sup>2</sup>, respectively) and the ulcer index ( $[22.8 \pm 1.92]$  and  $[18.6 \pm 2.40]$ , respectively) as compared to acetic acid control group in a dose-dependent manner [Table 1].

#### Inflammatory and oxidative alternations of the colonic mucosa

Seven-day pretreatment with mucilage significantly reduced the acetic acid-induced colonic mucus content and prevented oxidative and inflammatory response in a dose-dependent manner [Table 2 and Figure 2].

**Table 1:** Effect of *Colocasia* mucilage on the ulcer index in acetic acid-induced inflammatory bowel disease in rats

Groups	Mean±SD	
	Ulcer area (mm <sup>2</sup> )	Ulcer index
Normal	-	-
Acetic acid	$27.8 \pm 1.92^d$	$55.6 \pm 1.94^d$
Prednisolone	$4.8 \pm 1.14^a$	$9.8 \pm 1.92^a$
Mucilage (10 mg/kg)	$20 \pm 2.54^c$	$22.8 \pm 1.92^c$
Mucilage (20 mg/kg)	$11.6 \pm 1.51^b$	$18.6 \pm 2.40^b$

Means within each column followed by the same letter are not statistically different at 5% level of probability following LSD. LSD: Least-significant difference; SD: Standard deviation

**Table 2:** Effect of *Colocasia* mucilage on the myeloperoxidase, malondialdehyde, nitric oxide, and tumor necrosis factor- $\alpha$  activity in acetic acid-induced colitis in rats

Group	MPO (unit/g tissue)		MDA (nanomol/g tissue)		NO ( $\mu$ g/mg tissue)		TNF- $\alpha$ (pg/mg tissue)	
	Mean±SD	Percentage decrease	Mean±SD	Percentage decrease	Mean±SD	Percentage decrease	Mean±SD	Percentage decrease
Normal	$1.34 \pm 0.11^a$	-	$5.16 \pm 0.73^a$	-	$5.72 \pm 0.70^a$	-	$8.54 \pm 0.36^a$	-
Acetic acid	$24.5 \pm 2.64^d$	-	$42.2 \pm 4.37^d$	-	$54.2 \pm 8.27^d$	-	$78.3 \pm 11.24^d$	-
Prednisolone	$1.92 \pm 0.19^a$	92.1	$6.04 \pm 0.20^a$	85.6	$6.23 \pm 0.39^a$	88.3	$4.96 \pm 0.49^a$	93.6
Mucilage (10 mg/kg)	$7.98 \pm 1.31^c$	67.4	$18.54 \pm 1.81^c$	56.1	$20.78 \pm 2.06^c$	61.6	$21.16 \pm 2.93^b$	72.9
Mucilage (20 mg/kg)	$4.22 \pm 0.89^b$	82.7	$12.7 \pm 1.47^b$	69.9	$14.32 \pm 1.67^b$	73.5	$10.9 \pm 0.78^a$	86.1

Means within each column followed by the same letter are not statistically different at 5% level of probability following LSD. MPO: Myeloperoxidase; TNF: Tumor necrosis factor; SD: Standard deviation; MDA: Malondialdehyde; NO: Nitric oxide; LSD: Least-significant difference

Group V, receiving the higher dose of the mucilage (20 mg/kg), showed higher decrease (82.7%, 69.9%, 73.5%, and 86.1%) in the MPO, MDA, NO, and TNF- $\alpha$  levels, respectively, in comparison to prednisolone (92.1%, 85.6%, 88.3%, and 93.6%, respectively). Meanwhile, the second mucilage-treated group (Group IV; 10 mg/kg) showed lower decrease in the same mentioned parameters (67.4%, 56.1%, 61.6%, and 72.9%, respectively).

### *In vitro* anti-inflammatory activity

#### Cyclooxygenase-1/cyclooxygenase-2 inhibition assay

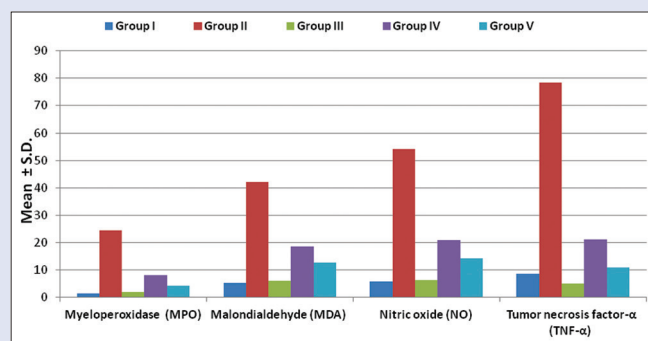
The obtained results [Table 3 and Figure 3] revealed that *C. esculenta* mucilage has a potent COX-2 inhibitory activity ( $IC_{50}$  of 0.027  $\mu$ g/mL) more than the standard drug, Celecoxib ( $IC_{50}$  of 0.034  $\mu$ g/mL), with lower effect on COX-1 ( $IC_{50}$  of 1.74  $\mu$ g/mL) upon comparing to Celecoxib ( $IC_{50}$  of 1.21  $\mu$ g/mL).

#### 5-Lipoxygenase inhibition assay

The mucilage showed lower 5-lipoxygenase (5-LOX) inhibitory activity ( $IC_{50}$  of 0.57  $\mu$ g/mL) than the standard drug, Zileuton ( $IC_{50}$  of 0.33  $\mu$ g/mL) [Table 3 and Figure 3].

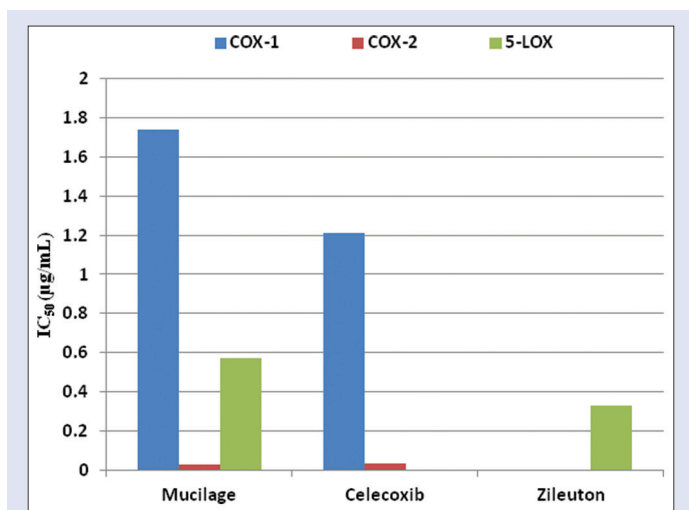
## DISCUSSION

Intrarectal administration of acetic acid causes protonation and migration of acetic acid molecule into colonic microflora, leading to epithelial denudation followed by infiltration of neutrophils into colonic tissue which indicates inflammatory conditions.<sup>[11]</sup> The histopathological examination highlighted the reducing effect of the mucilage on the damage scores of acetic acid comparing to prednisolone as a standard drug. The MPO and TNF- $\alpha$  activities were the main parameters for evaluating the degree of acetic acid-induced



**Figure 2:** Effect of *Colocasia esculenta* L. Schott corm mucilage on myeloperoxidase, malondialdehyde, nitric oxide and tumor necrosis factor- $\alpha$  activity in acetic acid-induced rat colitis comparing to reference drugs





**Figure 3:** IC<sub>50</sub> of the *Colocasia esculenta* L. Schott corm mucilage on COX-1, COX-2 and 5-LOX activity in acetic acid-induced rat colitis comparing to reference drugs

**Table 3:** Effect of *Colocasia esculenta* mucilage (IC<sub>50</sub> values) on cyclooxygenase-1, cyclooxygenase-2, and 5-lipoxygenase activity comparing to standard drugs

IC <sub>50</sub> (µg/mL)	COX-1	COX-2	5-LOX
Mucilage	1.74	0.027	0.57
Celecoxib	1.21	0.034	-
Zileuton	-	-	0.33

COX: Cyclooxygenase; LOX: Lipoxygenase

colonic inflammation in rats, while MDA and NO content were the prominent parameters for evaluating the oxidative stress of the colonic mucosa. Compared with the normal group (Group I), all these parameters were significantly increased by acetic acid ( $P < 0.05$ ) in the colonic mucosa of the model group (Group II). After the model rats were treated with mucilage (10, 20 mg/kg; Group IV and V) or prednisolone (2 mg/kg; Group III), these elevated parameters were significantly improved in a dose-dependent manner ( $P < 0.05$ ). Accordingly, the therapeutic dose protocol of 20 mg/kg of the mucilage (Group V) can be considered as an effective drug in the treatment of this rat model of colitis. In addition, this natural mucilage overcomes the side effects of prednisolone-like anxiety, blurred vision, nervousness, depression, and restlessness and hence, mucilage can be prescribed for geriatric patients.<sup>[11]</sup> The mucilage forms a protective viscous layer that could attenuate irritation, independently from the origin (mechanic, thermic, chemical, etc.).<sup>[15]</sup>

A promising approach in the treatment of inflammatory diseases includes the inhibition of COX and LOX pathways. COX is a prostaglandin endoperoxide synthase enzyme. In mammalian cells, COX exists in at least two isoforms COX-1 (expressed in all cell types and regulated as a house keeping enzyme for various physiological functions) and COX-2 (expressed during tissue damage or inflammation).<sup>[16]</sup> 5-LOX pathway is the major source of potent pro-inflammatory leukotrienes.<sup>[17]</sup> Nonsteroidal anti-inflammatory drugs possess excellent anti-inflammatory effect through inhibition of COX-2, but with limited use as a result of its severe side effects on gastrointestinal tract through inhibition of COX-1.<sup>[2]</sup> Nevertheless, the anti-inflammatory agents having selective COX-2 inhibition but less reactive toward COX-1

are appreciated as novel anti-inflammatory agents in the mainstream of anti-inflammatory research.<sup>[16]</sup> The promising anti-inflammatory activity of *C. esculenta* corm mucilage compared to Celecoxib makes it good candidates for further optimization and development of potent and safe anti-inflammatory agents having selective COX-2 inhibition with minimum gastrointestinal side effects.

The findings of the present study strongly suggested that the freeze-dried mucilage of Egyptian cultivated *C. esculenta* var. typical corm could serve as an alternative modality for the treatment of IBD and may pose promising outcomes for future clinical usage of mucilage as a natural nontoxic effective supplement in IBD. However, further fractionation of the mucilage needs to be carried out to determine the bioactive moieties particularly responsible for these activities.

## Financial support and sponsorship

Nil.

## Conflicts of interest

There are no conflicts of interest.

## REFERENCES

- Huang BL, Chandra S, Shih DQ. Skin manifestations of inflammatory bowel disease. *Front Physiol* 2012;3:13.
- Urban MK. COX-2 specific inhibitors offer improved advantages over traditional NSAIDs. *Orthopedics* 2000;23:S761-4.
- Sindhu G, Ratheesh M, Shyni GL, Nambisan B, Helen A. Anti-inflammatory and antioxidative effects of mucilage of *Trigonella foenum graecum* (Fenugreek) on adjuvant induced arthritic rats. *Int Immunopharmacol* 2012;12:205-11.
- Hajhashemi V, Ghannadi A, Heidari AH. Anti-inflammatory and wound healing activities of *Aloe littoralis* in rats. *Res Pharm Sci* 2012;7:73-8.
- Ghumman SA, Bashir S, Ahmad J, Hameed H, Khan IU. *Colocasia esculenta* corms mucilage-alginate microspheres of oxcarbazepine: Design, optimization and evaluation. *Acta Pol Pharm* 2017;74:505-17.
- Biren NS, Nayak B, Bhatt S, Jalalpure S, Seth A. The anti-inflammatory activity of the leaves of *Colocasia esculenta*. *Saudi Pharm J* 2007;15:228-32.
- Agyare C, Boakye YD, Apenteng JA, Dapaah SO, Appiah T, Adow A. Antimicrobial and anti-inflammatory properties of *Anchomanes difformis* (Bl.) Engl. and *Colocasia esculenta* (L.) Schott. *Bio Pharmacol* 2016;5:1-5.
- Sarkar G, Saha NR, Roy I, Bhattacharyya A, Bose M, Mishra R, et al. Taro corms mucilage/HPMC based transdermal patch: An efficient device for delivery of diltiazem hydrochloride. *Int J Biol Macromol* 2014;66:158-65.
- Al-Rejaie SS, Abuhashish HM, Al-Enazi MM, Al-Assaf AH, Parmar MY, Ahmed MM. Protective effect of naringenin on acetic acid-induced ulcerative colitis in rats. *World J Gastroenterol* 2013;19:5633-44.
- Bancroft JD, Stevens A, Turner DR. *Theory and Practice of Histological Techniques*. 4th Edition, Churchill Livingstone, London, Toronto, 1996.
- Kandhare AD, Raygude KS, Ghosh P, Ghule AE, Gosavi TP, Badole SL, et al. Effect of hydroalcoholic extract of *Hibiscus rosasinensis* Linn. leaves in experimental colitis in rats. *Asian Pac J Trop Biomed* 2012;2:337-44.
- Kulmacz RJ, Lands WE. Requirements for hydroperoxide by the cyclooxygenase and peroxidase activities of prostaglandin H synthase. *Prostaglandins* 1983;25:531-40.
- Jacob J, Kumar PB. Dual COX/LOX inhibition: Screening and evaluation of effect of medicinal plants of Kerala as anti-inflammatory agents. *Pharmacogn Phytochem* 2015;3:62-6.
- Snedecor GW, Cochran WG. *Statistical Methods*. Iowa State, USA: University Press; 1982.
- Reynolds T, Dweck AC. Aloe vera leaf gel: A review update. *J Ethnopharmacol* 1999;68:3-7.
- Shaikh RU, Pund MM, Gacche RN. Evaluation of anti-inflammatory activity of selected medicinal plants used in Indian traditional medication system *in vitro* as well as *in vivo*. *J Trad Compl Med* 2016;6:355-61.
- Hedi H, Norbert G. 5-lipoxygenase pathway, dendritic cells, and adaptive immunity. *J Biomed Biotechnol* 2004;2004:99-105.