

Areas of Interest (AOIs)

Delineation

in Head & Neck Cancer

Ashraf Hamed Hassouna

Professor of Radiation Oncology

NCI, Cairo University

Target Volumes

GTV – CTV – PTV

Dose Prescription

- **70**Gy: Primary and involved nodes.
- **66**Gy: +ve margins or extranodal spread.
- **60**Gy: Adjuvant RT (-ve margins) or high-risk nodal areas.
- **50**Gy: Prophylactic to uninvolved low risk nodal levels.

Essentials of Contouring

- Clinical Exam
- Imaging
- Understanding of Patterns of Spread
 - Local and Regional Coverage
 - Anatomy
 - Histology
- Operative Considerations

GTV

- **Primary tumor** and any **LN**s thought to contain tumor (>1cm in short axis, necrotic center, rounded contour, PET +ve).
- **If induction CT** has been used, the post-CT GTV is contoured, but the pre-CT extent of tumor should be included in the CTV (70 or 60).

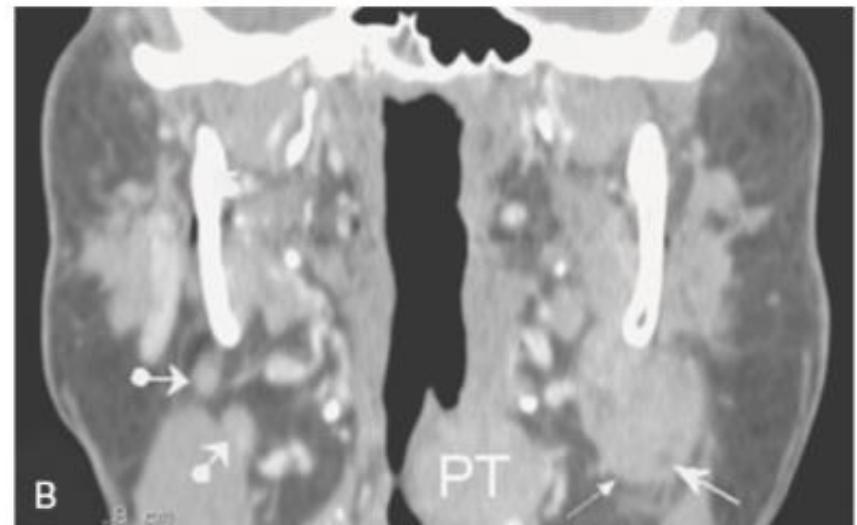
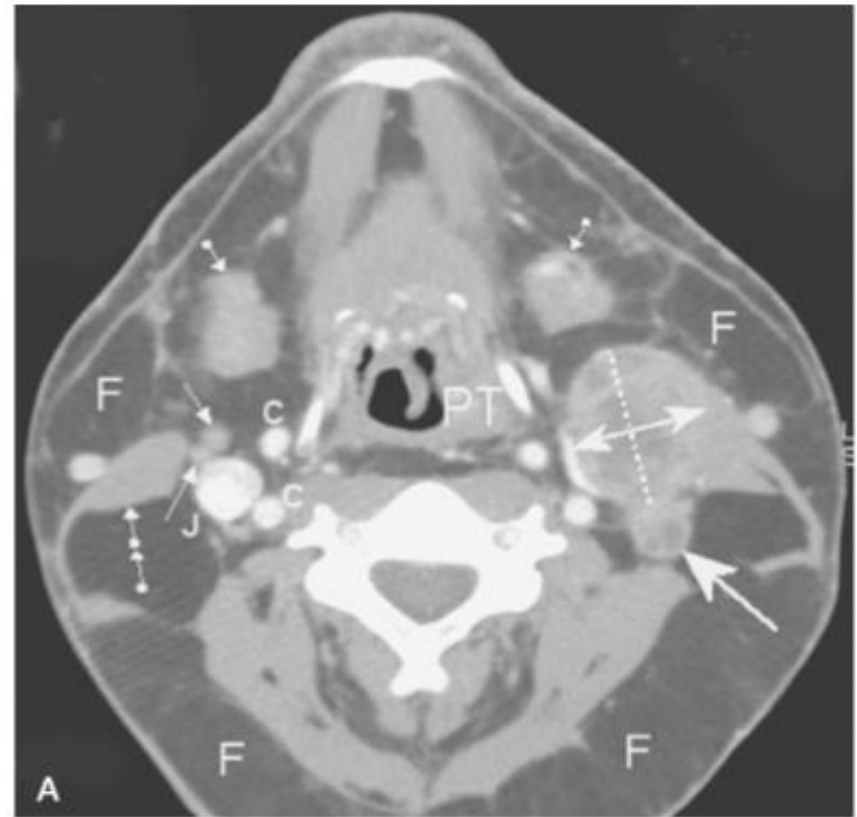
- Oral cavity and oropharynx are better visualized by **MRI**.
- Larynx and hypopharynx are better visualized by **CT**.
- **PET/CT** is only recommended for locally advanced tumours. For small tumours (e.g. T₁₋₂) and superficial lesions, PET is not enough for delineation.

- Starting on a central slice of the primary tumor, the GTV is defined on each axial CT image moving superiorly and then inferiorly. Involved nodes can then be defined in the same way.
- Viewing the GTV on coronal and sagittal views ensures consistency of definition between slices.

CT in left OPC

A, fatty (F) environment allows clear delineation of the neck structures. Left oropharyngeal SCC (PT). Abnormal nodes in left level II (long axis of 26 mm is shown as dotted line; short transverse axis of 18 mm is shown between the double-ended arrow) and a posterior, normal-sized node showing necrotic hypodensity (thick arrow). Normal-sized contralateral nodes (thin arrows). Submandibular glands (ball-arrowhead), muscles (double ball-arrowhead), Jugular veins (J), and carotid arteries (C). Notice the lamination of the left internal jugular vein by adenomegaly.

B, primary tumor (PT), left metastatic adenomegaly, and contralateral, normal-sized nodes (ball-arrowhead). Observe the irregularities of the inferior aspect of the enlarged node, suggesting extranodal spread (thin arrow) and hypodense foci corresponding to necrotic areas (thick arrow).



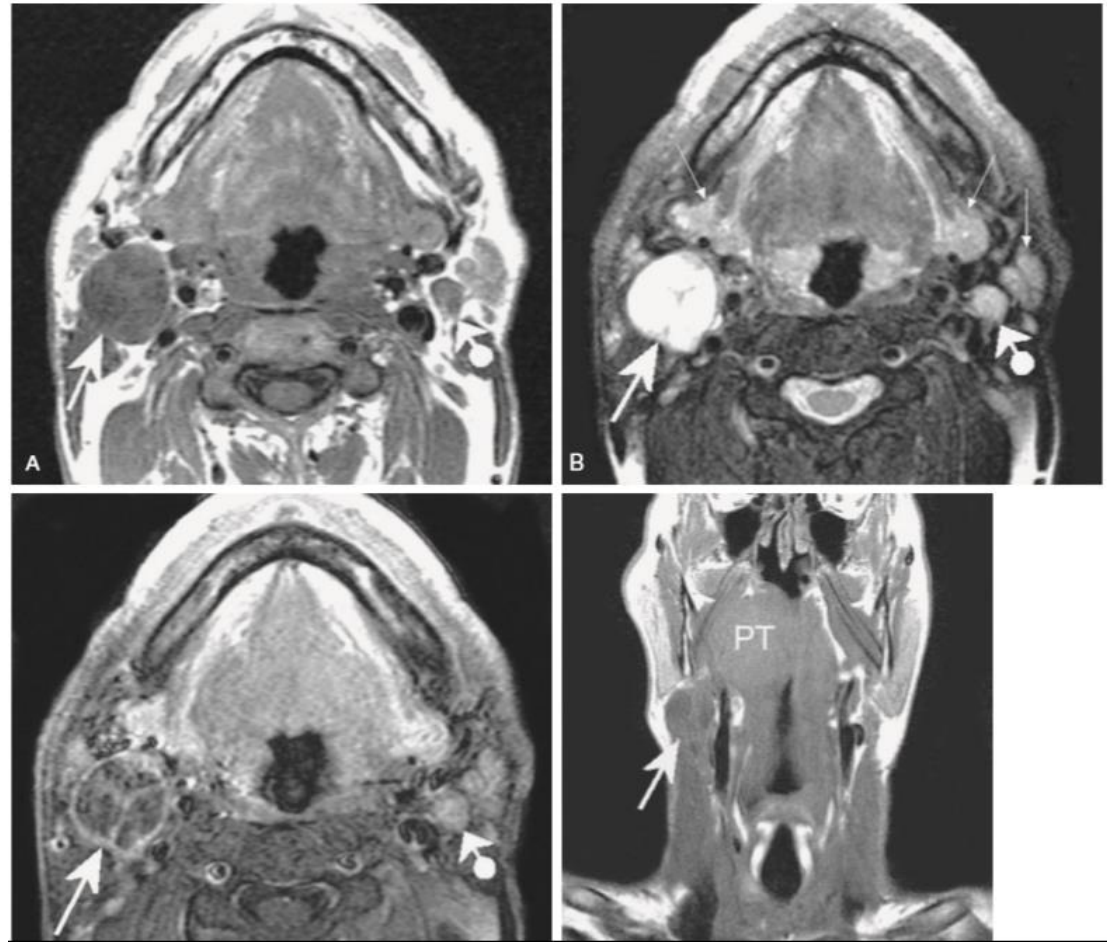
MRI in right OPC

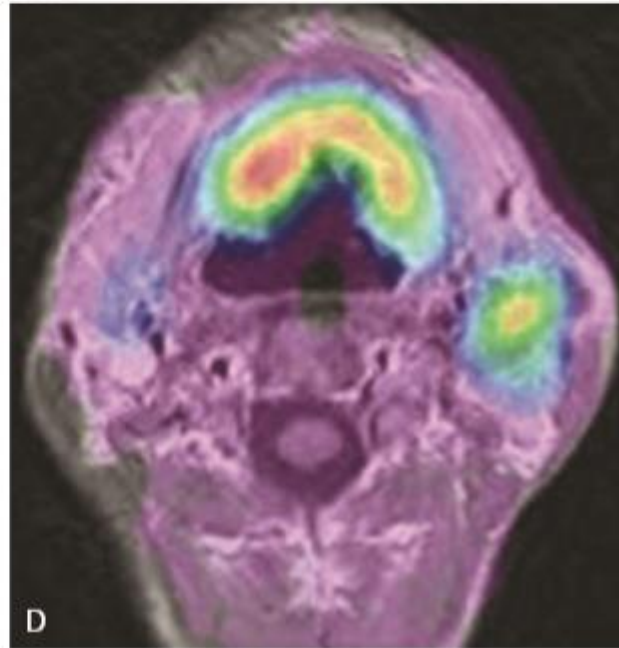
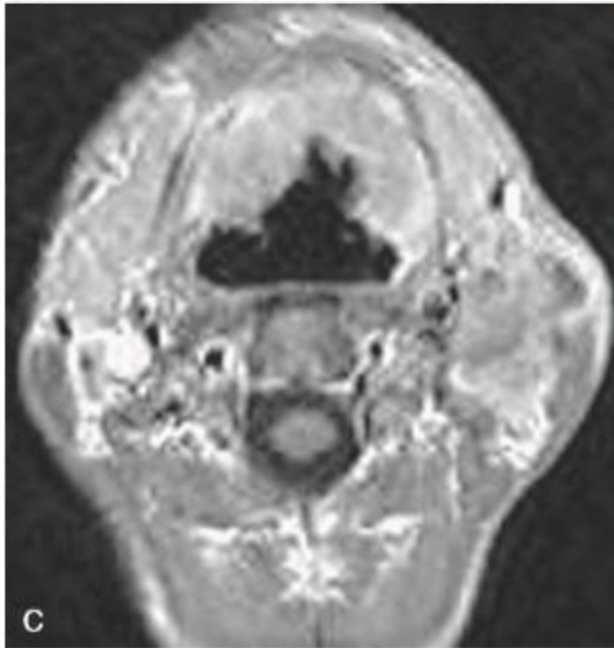
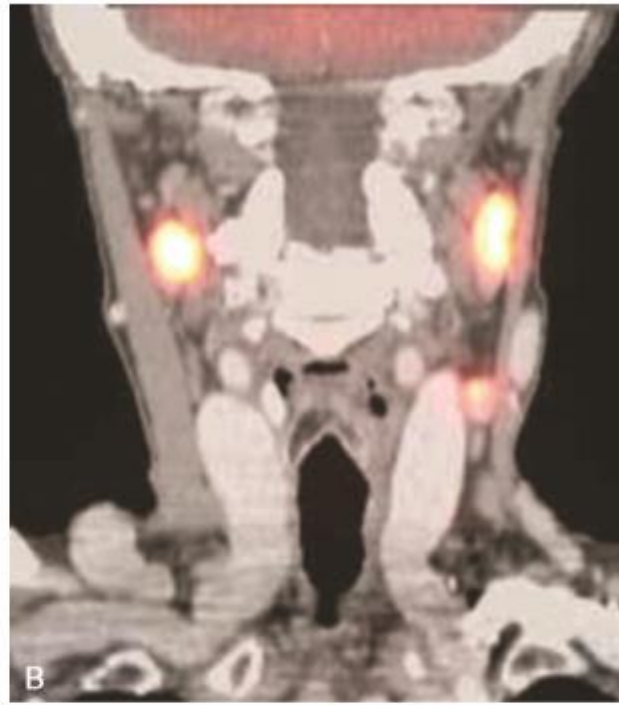
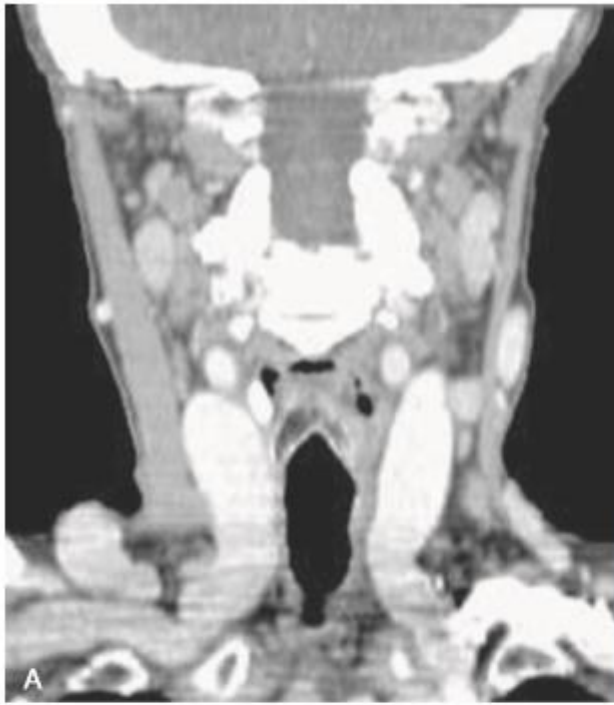A, Right level II hypointense necrotic adenomegaly (arrow) with a normal contralateral node in level II (ball-arrowhead).

B, Strong hyper-intensity of the necrotic node due to fluid-like content (arrow) compared with the normal contralateral node (ball-arrowhead). Observe the almost similar signal intensity of the normal node and of the parotid and submandibular glands (thin arrows).

C, Only peripheral ring-like enhancement of the margin of the necrotic adenomegaly (arrow). The normal contralateral node enhances slightly and homogeneously (ball-arrowhead).

D, Primary tumor (PT) and hypointense necrotic adenomegaly (arrow).





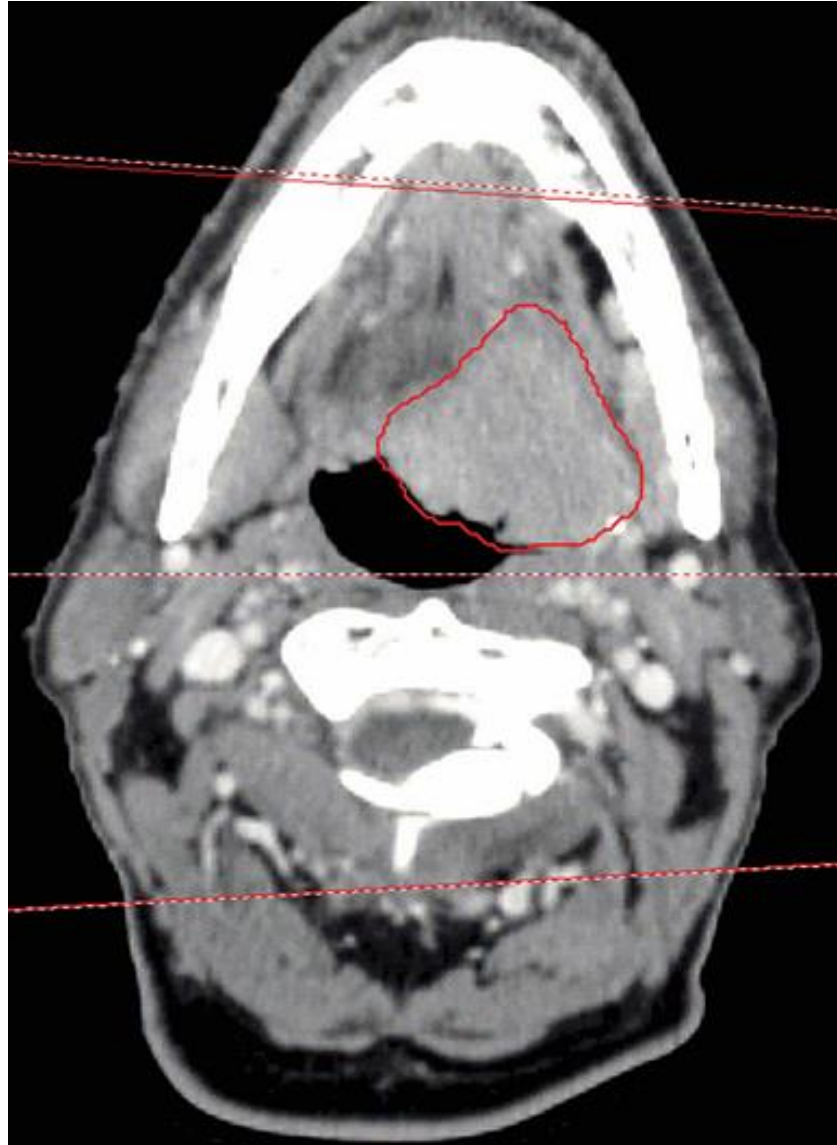
CT-MRI-PET fusion

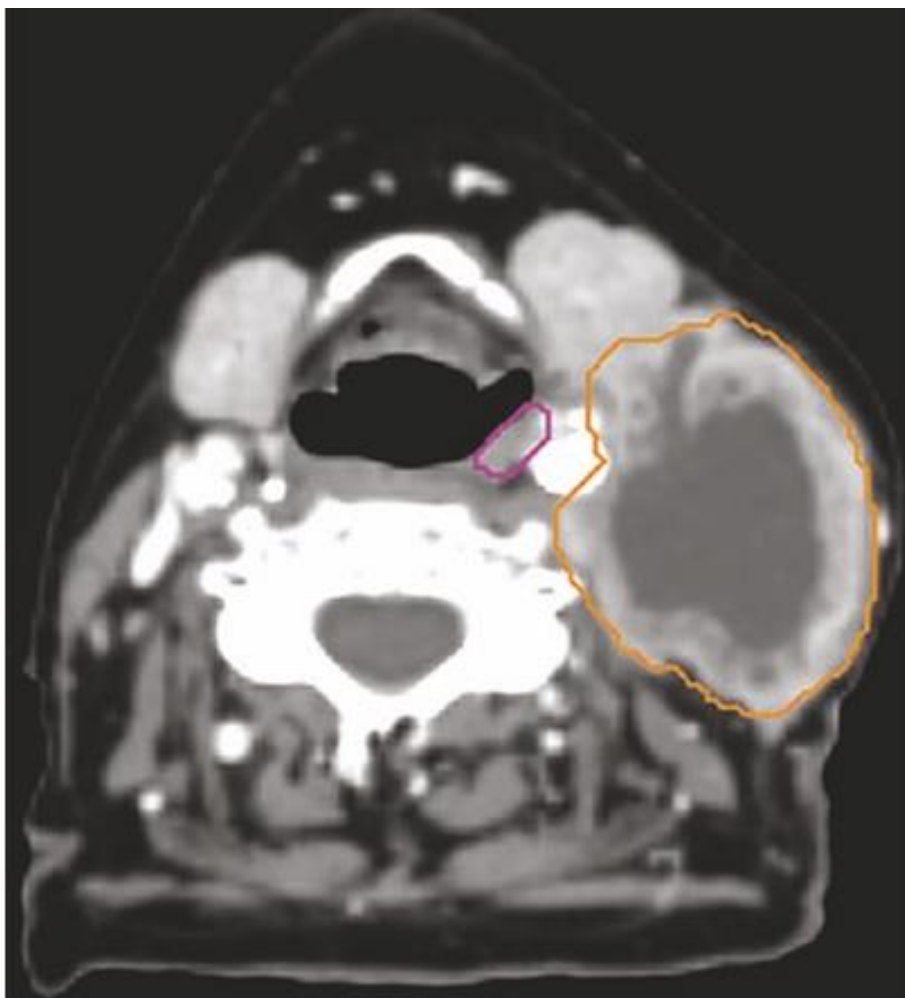
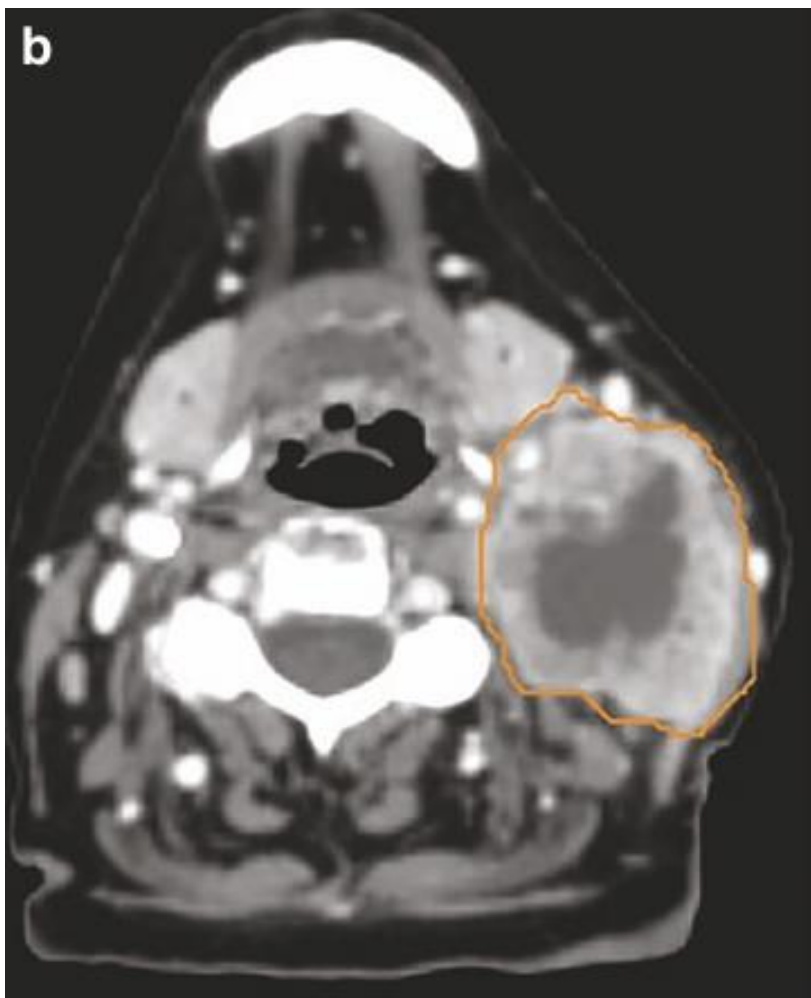
A, Postcontrast, CT: bilateral, mildly enlarged nodes in the carotid-jugular chains. Tumoral involvement of the nodes remains speculative because of the borderline short-axis diameter and absence of obvious necrosis.

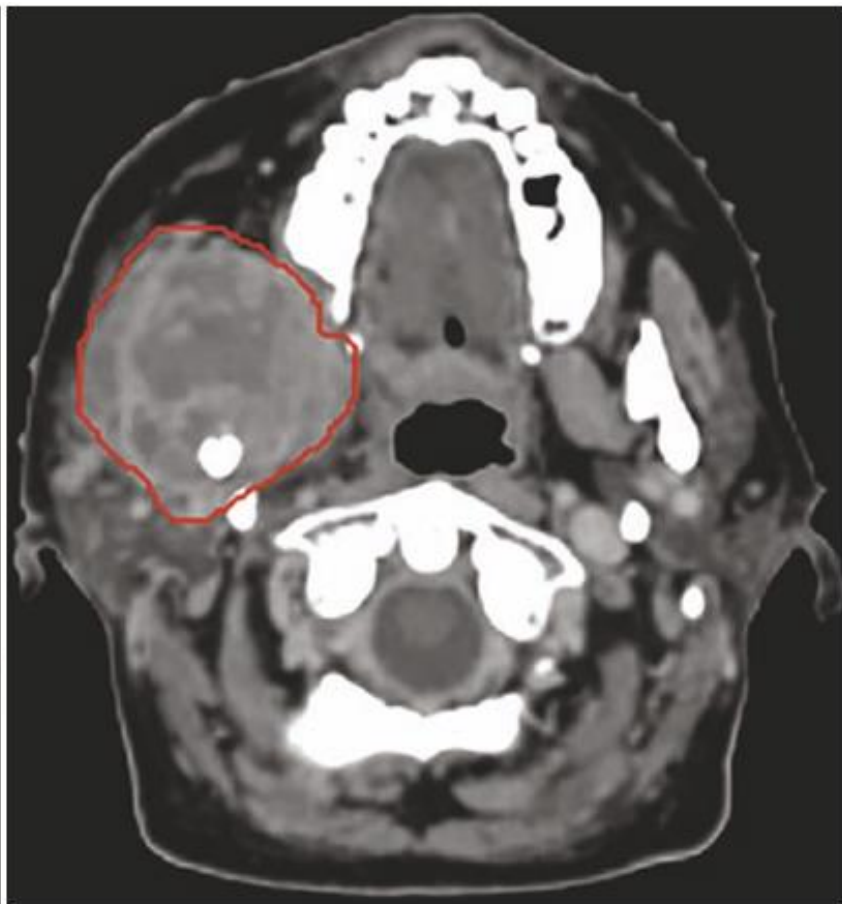
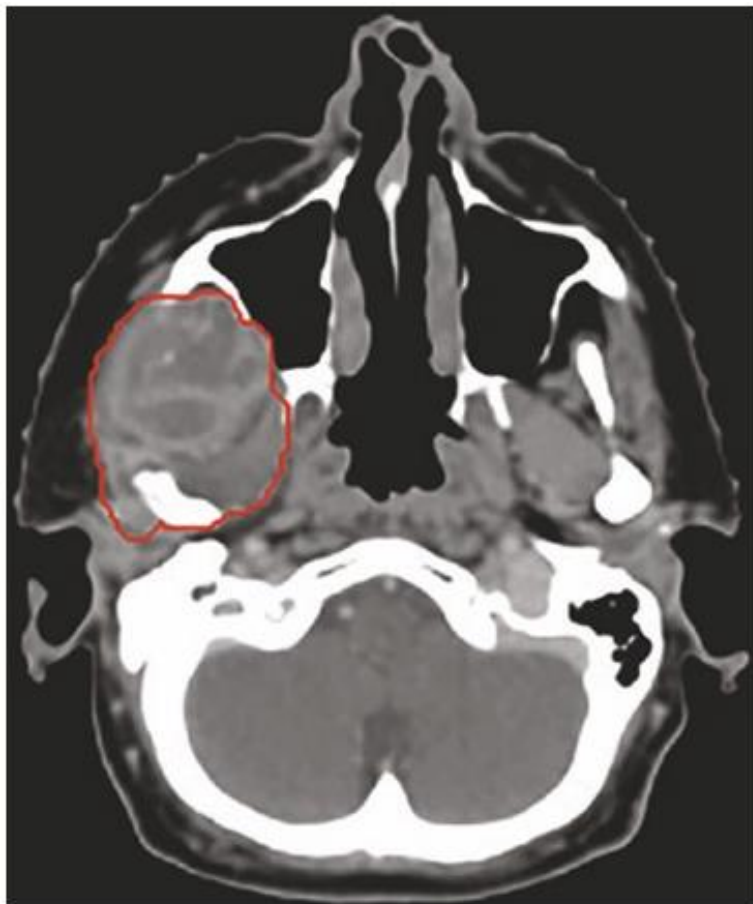
B, FDG-PET-CT: increased glucose uptake within the nodes.

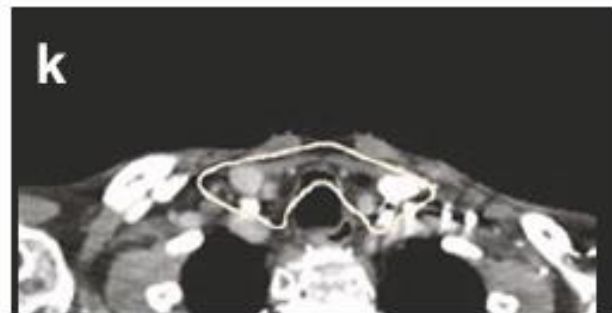
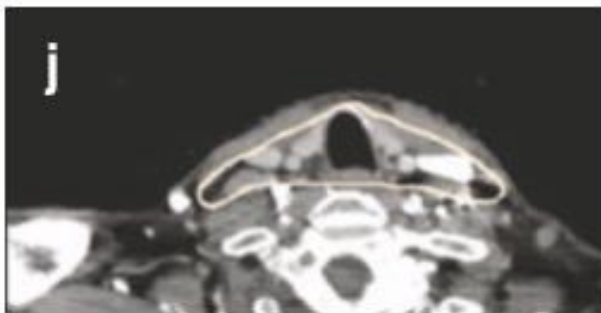
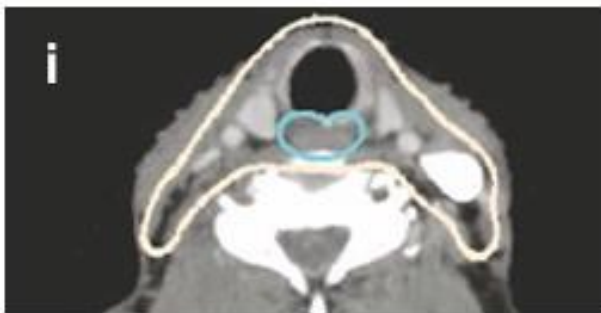
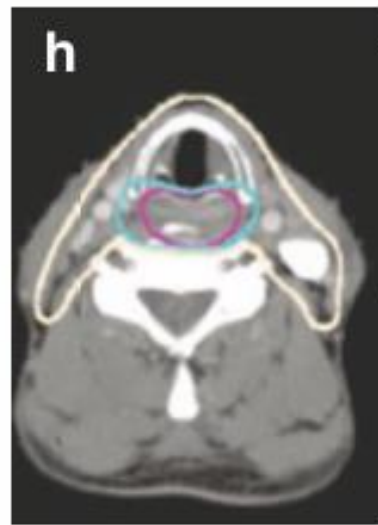
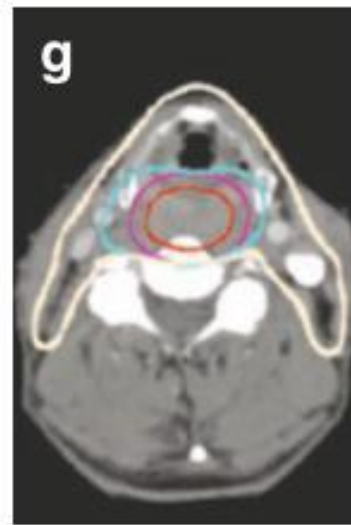
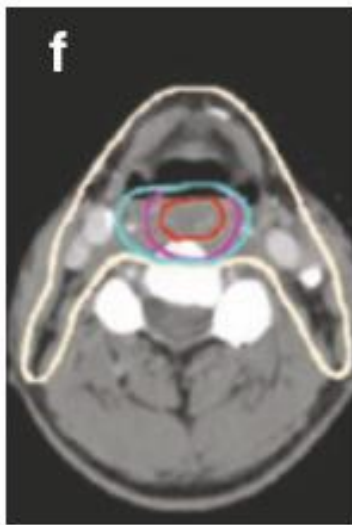
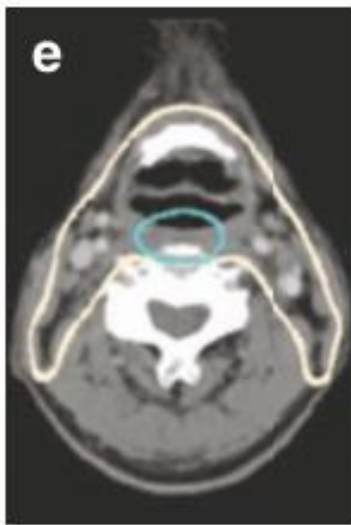
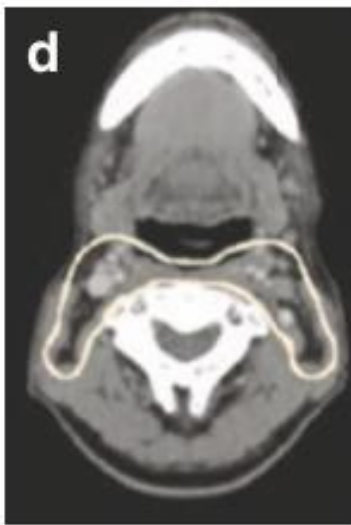
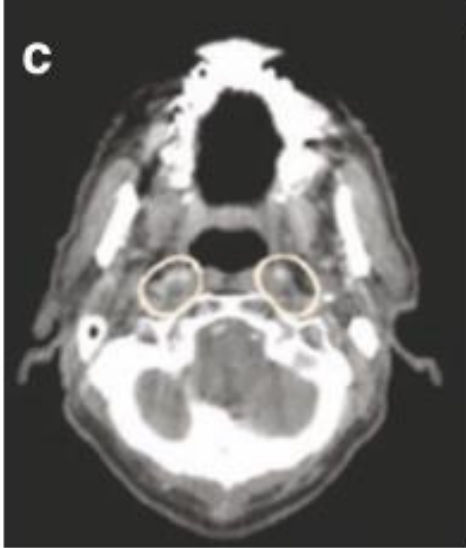
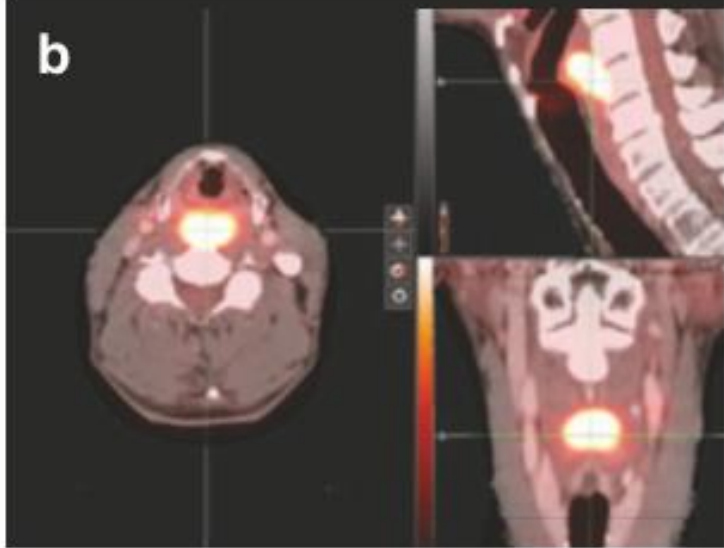
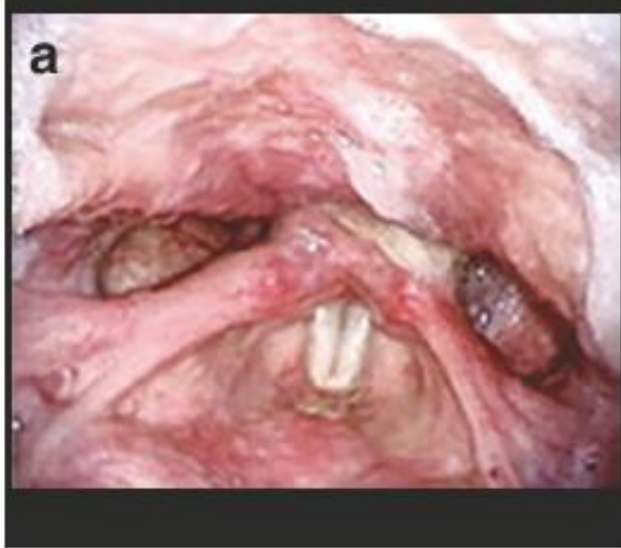C, Contrasted T1-MRI: anterior, horseshoe-sized OPC and left-sided level II metastatic nodes.

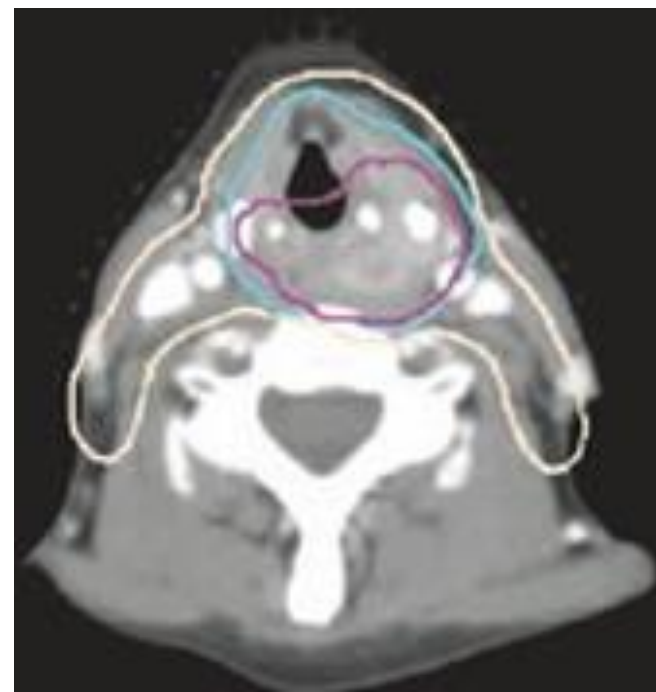
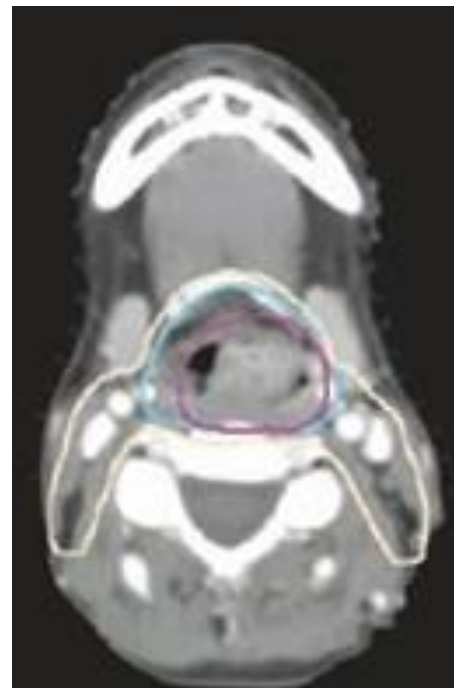
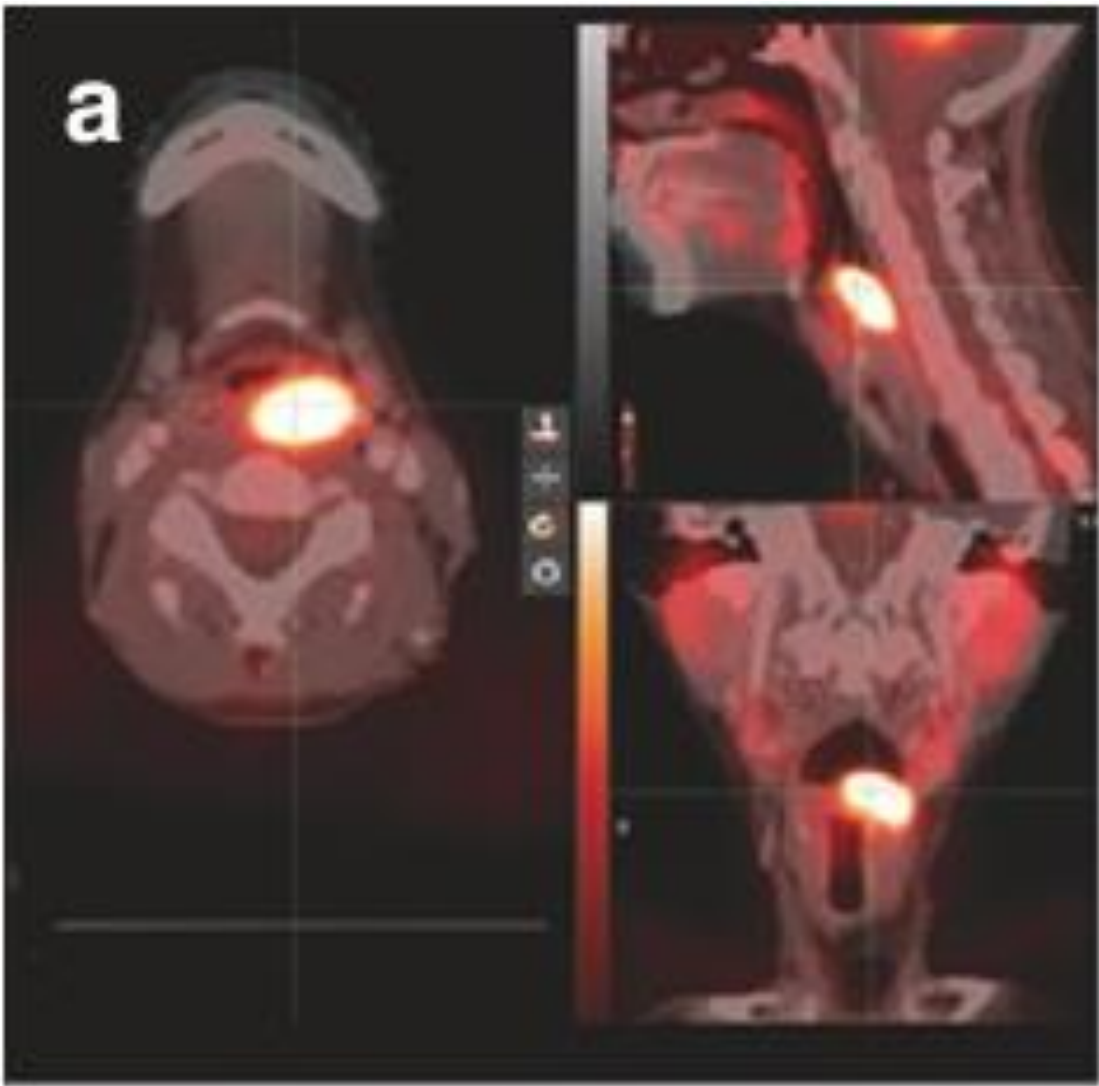D, FDG-PET-MRI: increased glucose uptake within the primary tumor and metastatic nodes.











Primary tumor CTV (CTV₇₀ & CTV₆₀)

- Microscopic tumour infiltration occurs within a distance of **0-10 mm** from the edge of the GTV.
- The Danish national guidelines (2013) for CTV delineation of HNSCC were revised to propose the concept of isocentric geometric expansion of the GTV-P (5+5 mm expansion) with corrections for natural anatomic boundaries.

CTV-P delineation cannot be a straightforward **geometric expansion** of the GTV-P without performing some modification that takes into account patient **anatomy**:

- Air cavities.
- Anatomic barriers.
- Complex head and neck anatomy.
- Experience gained from surgical series.

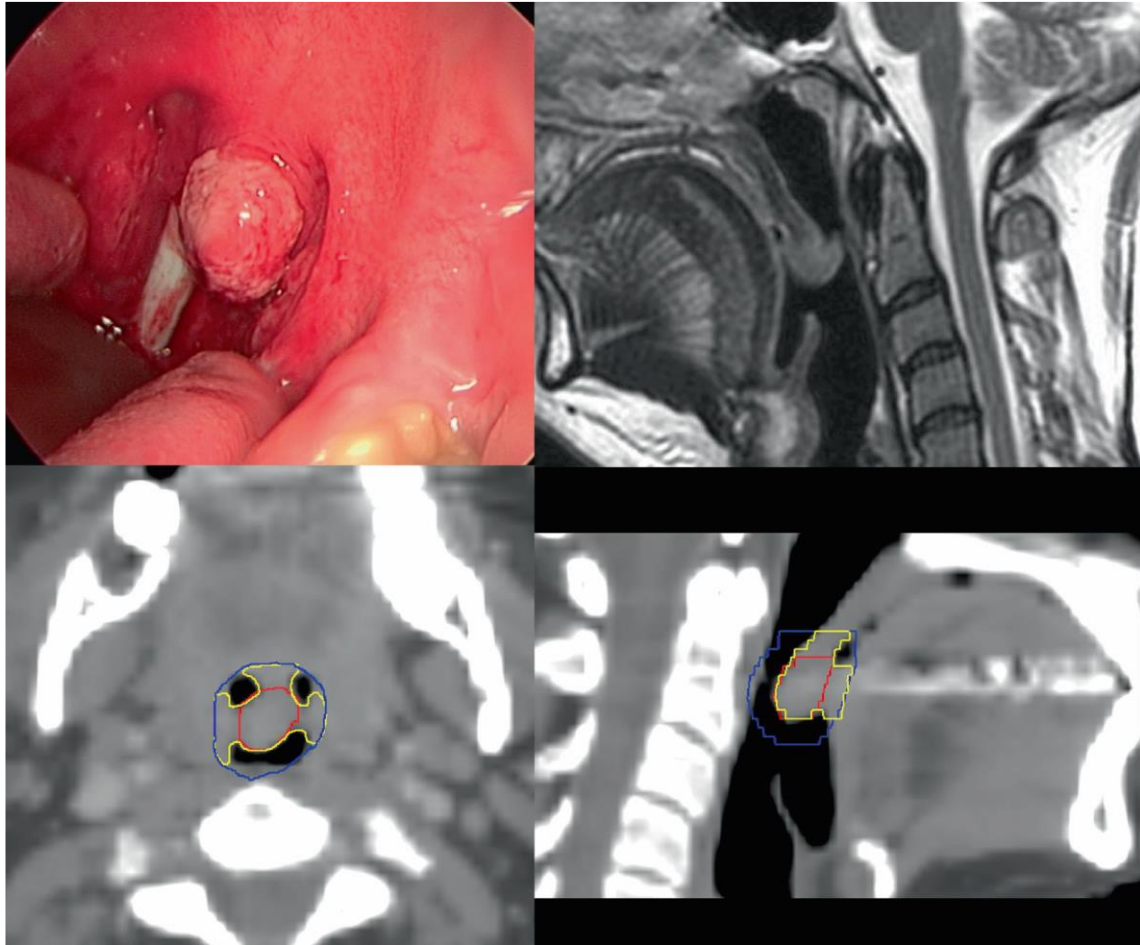
Air cavities.

Head and neck anatomic barriers: such as the mandible, the maxillary bone, the cervical spine, the hyoid bone and muscular fascia. The GTV-P expansion should be edited for these structures, unless infiltrated.

Complex head and neck anatomy

Regions of abutting but not directly contiguous mucosal surfaces.

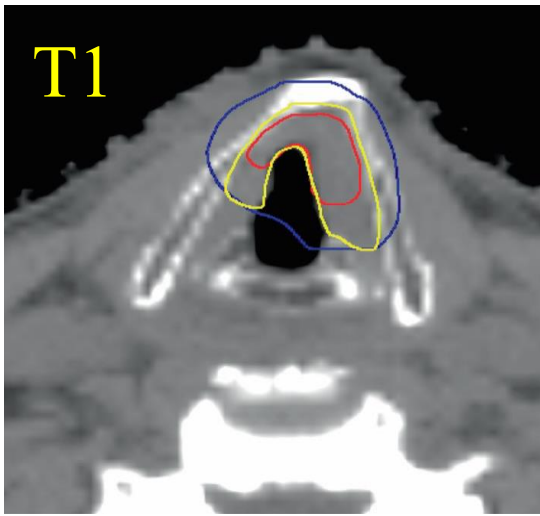
Soft palate GTV-P expansion will be edited at the tongue level as will an inter-arytenoid laryngeal GTV-P at the level of the post-cricoid area.



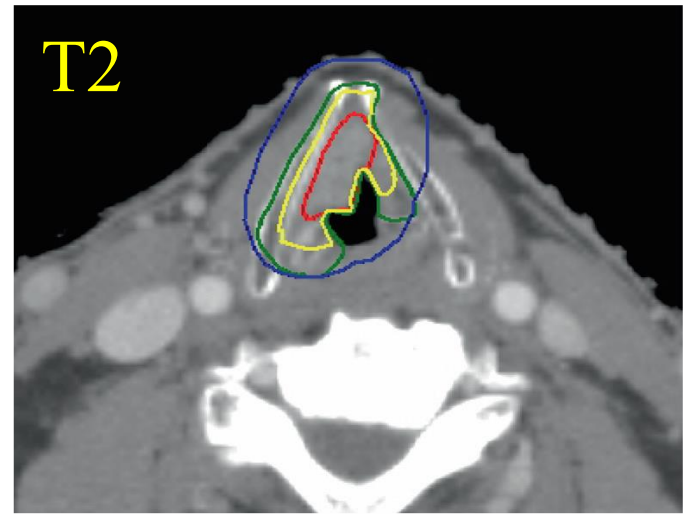
Surgical consideration: for small tumors (e.g. T1 glottic or T1 tonsillar ca) surgical series with endoscopic surgery (laser or TORS) reported very high LC (without PORT) with lower margins around the GTV, which suggests that different margin extension for these small tumors could be adopted.

These series included highly selected patients, and surgeons have the advantage of the on-line visualization during their resection, especially regarding mucosal infiltration.

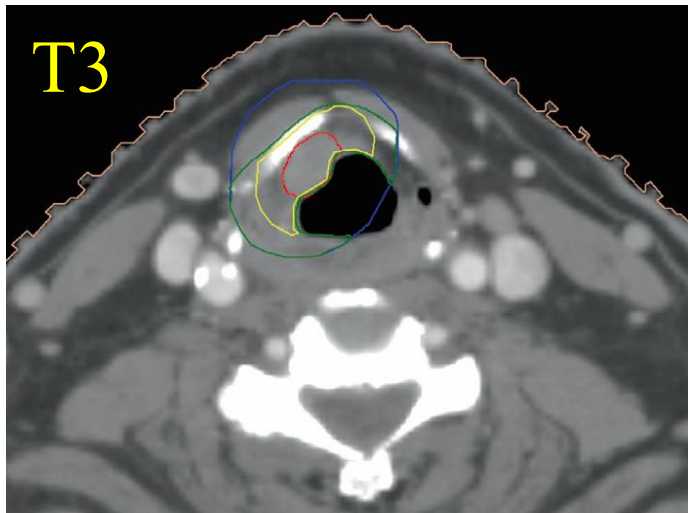
- For T1 glottic SCC, the delineation of a CTV-P2 is not recommended.
- In hypopharyngeal SCC, extensive sub-mucosal extension has been reported, so consider 15 mm margin from the GTV-P to the CTV-P2 in the cranio-caudal direction.



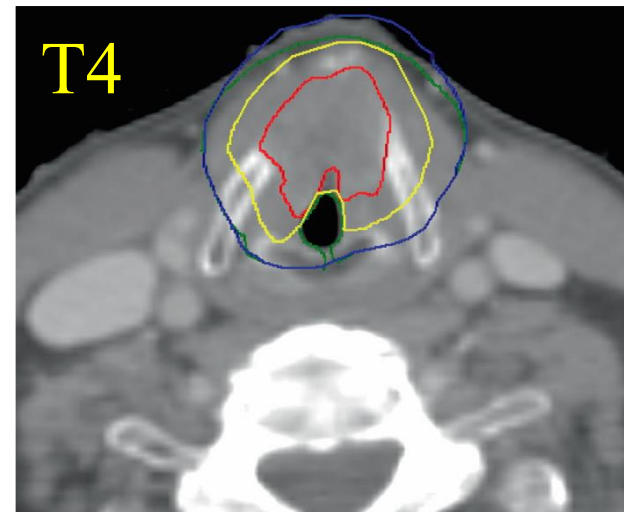
T1
Crop from cartilage



T2
Include cartilage, no muscles

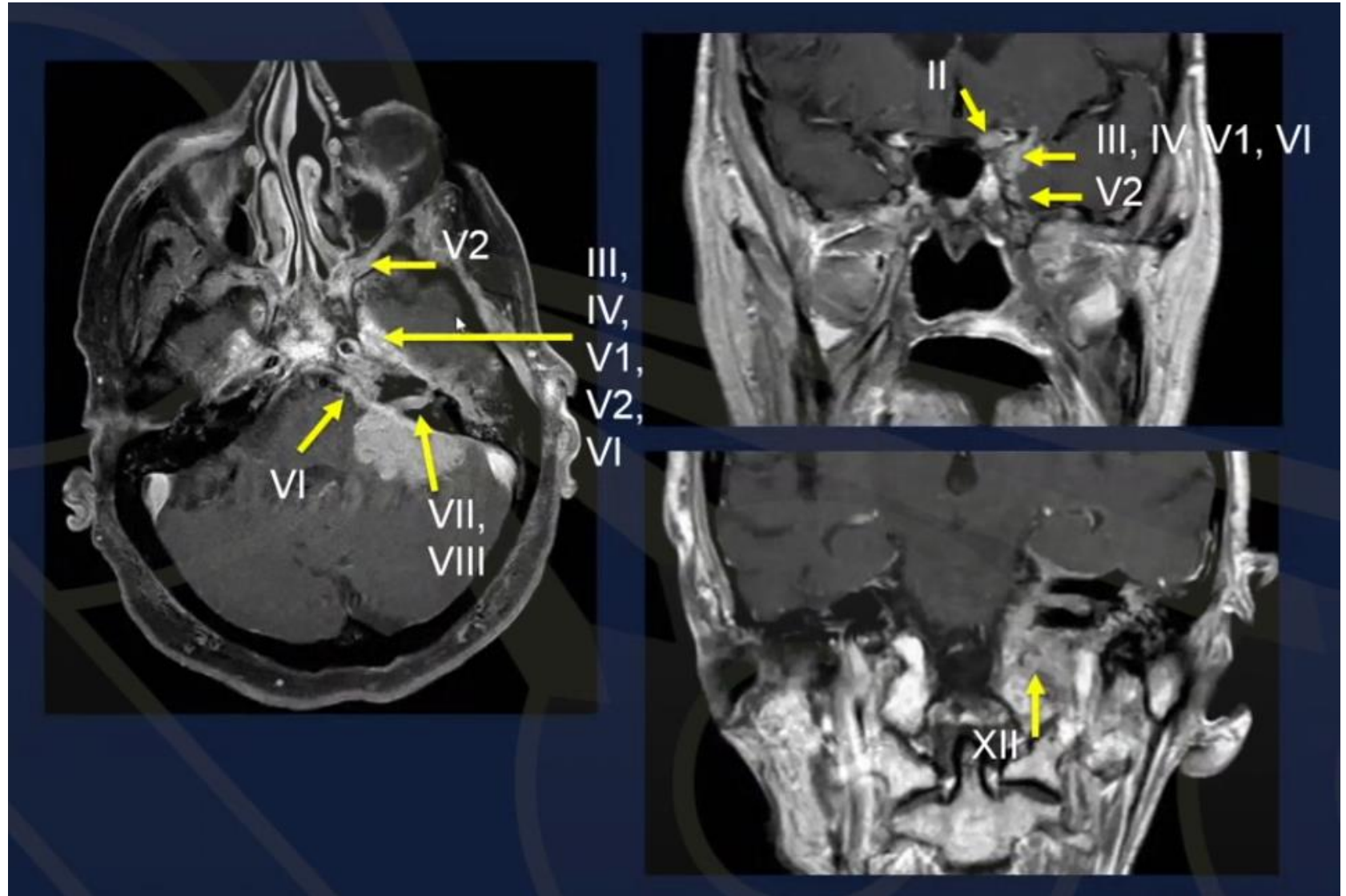


T3
If cartilage not invaded, include cartilage but not muscle. If cartilage invaded, include cartilage and muscle

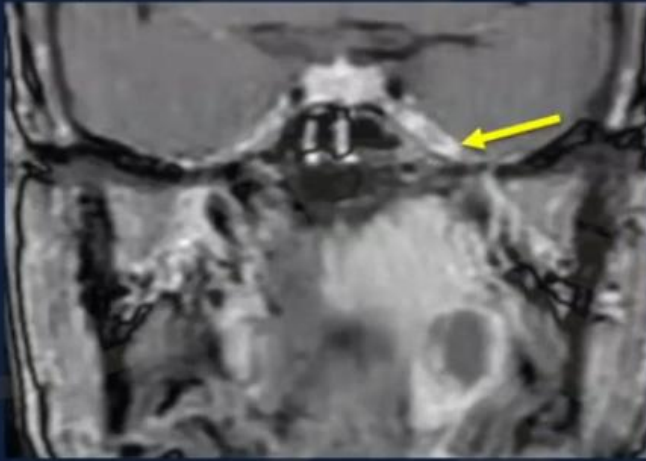

T4
Do not crop

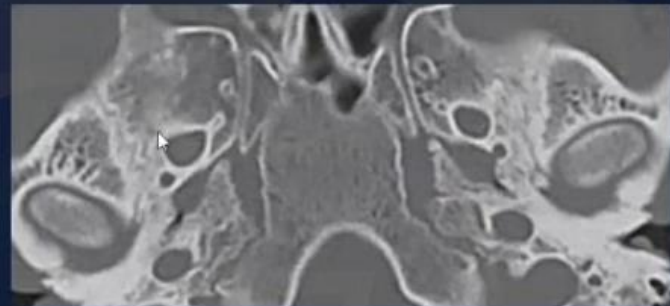
Perineural invasion

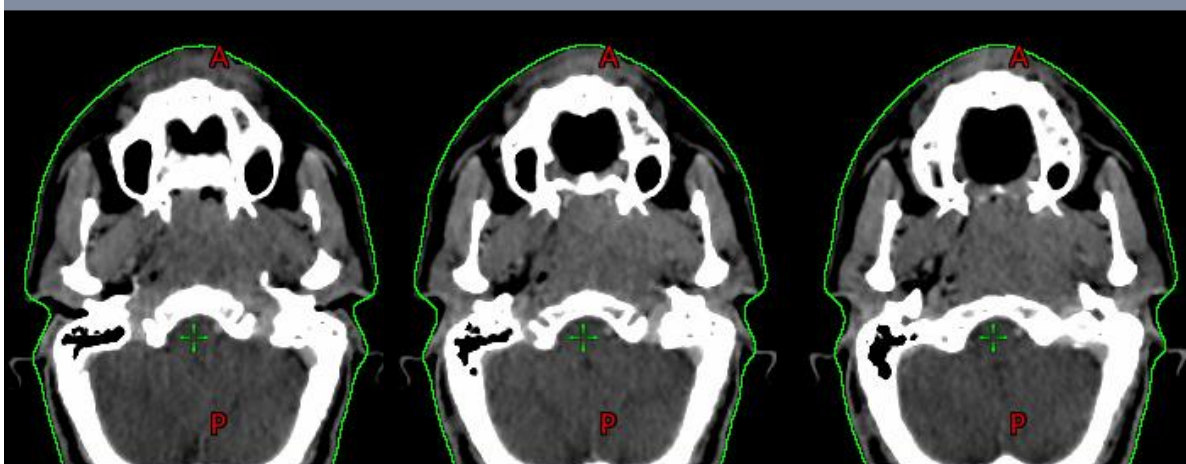
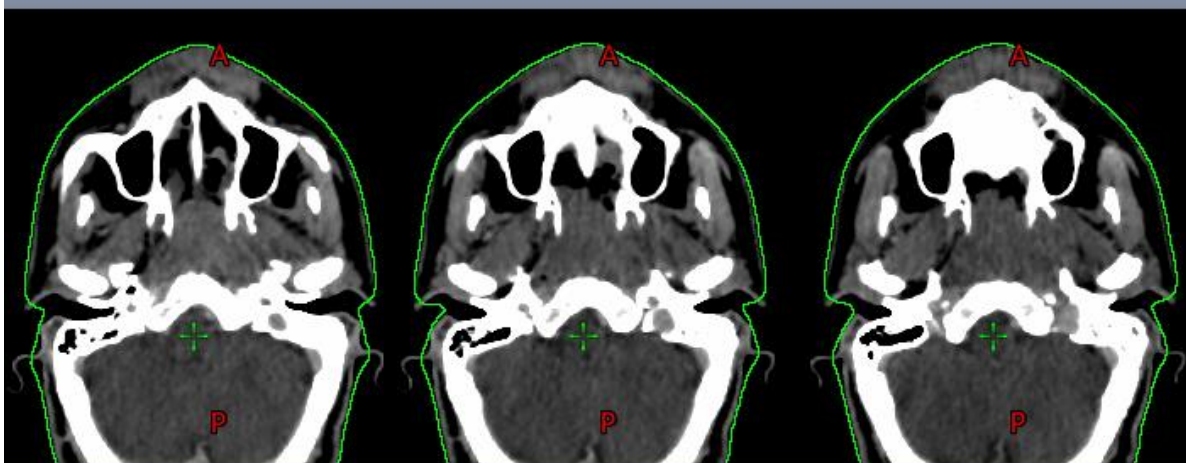
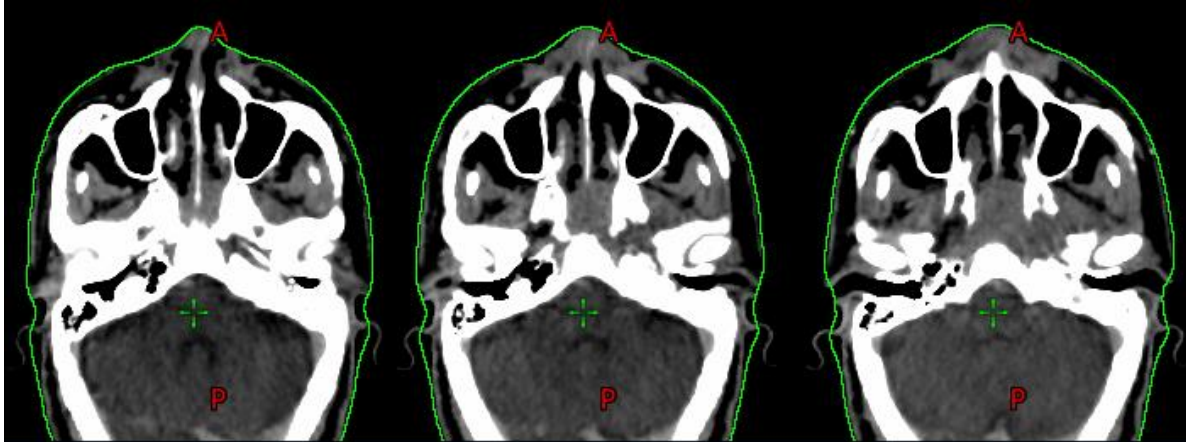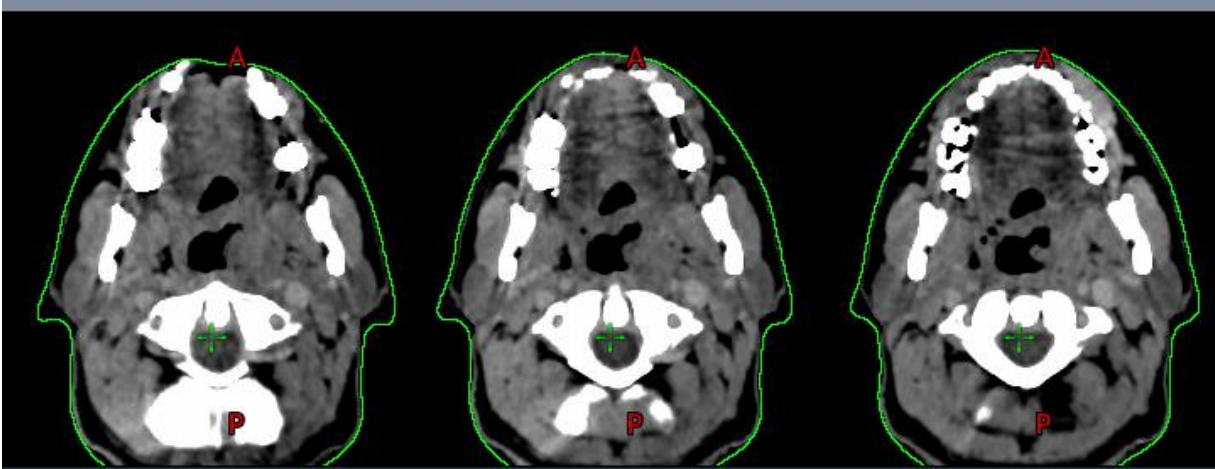
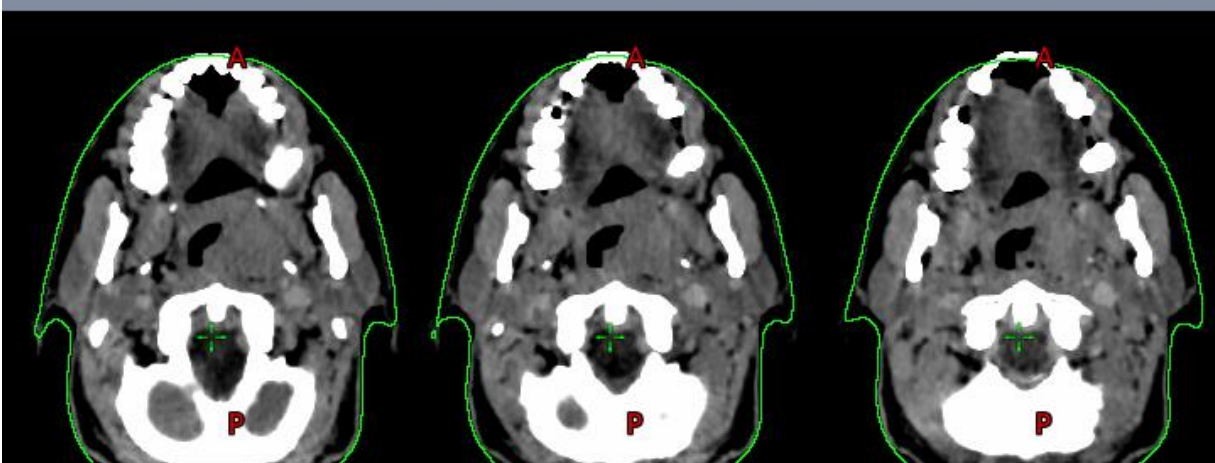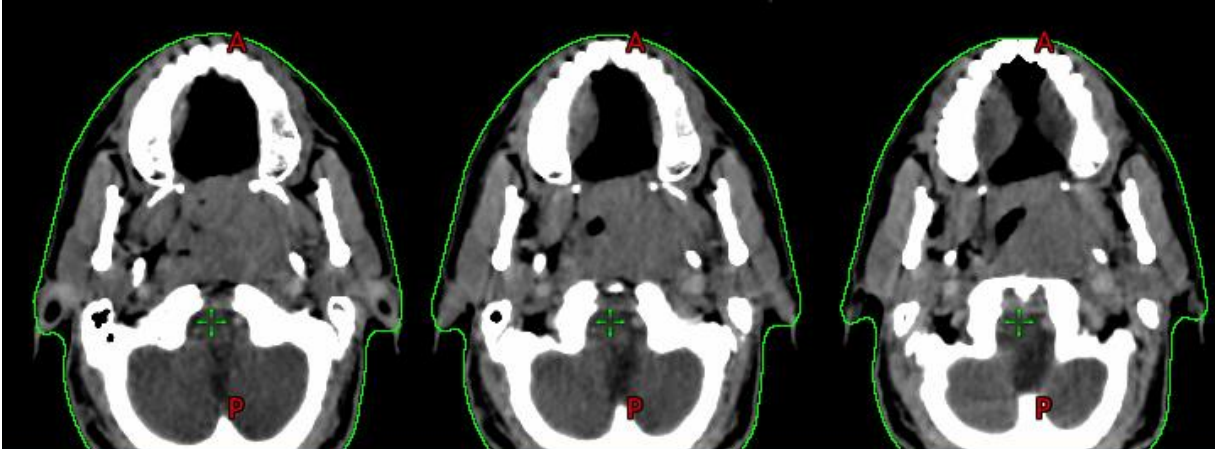
CN V: NPCA

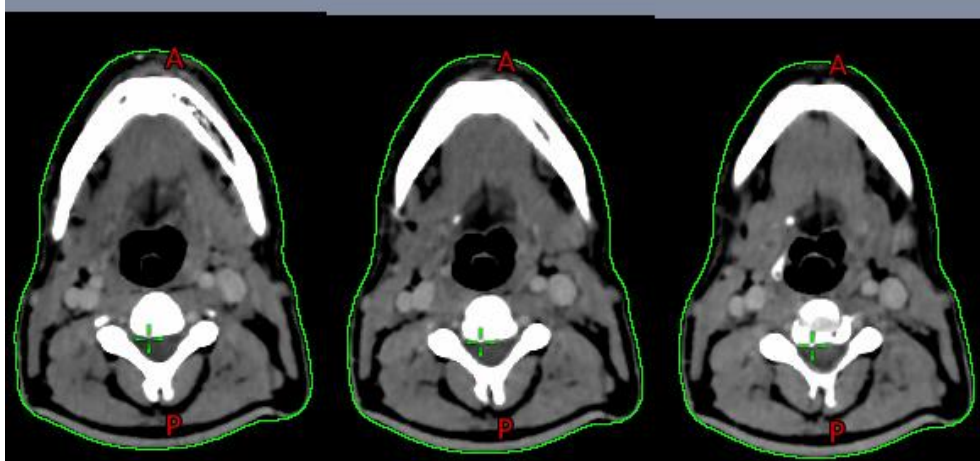
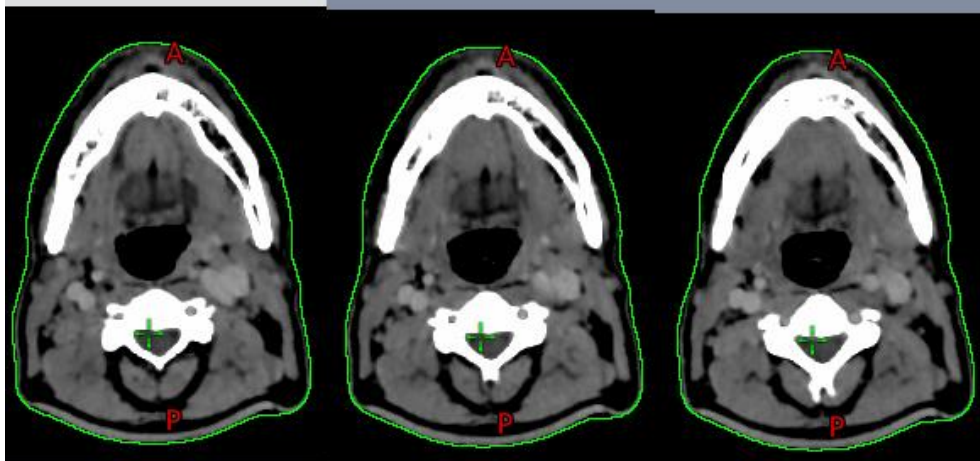
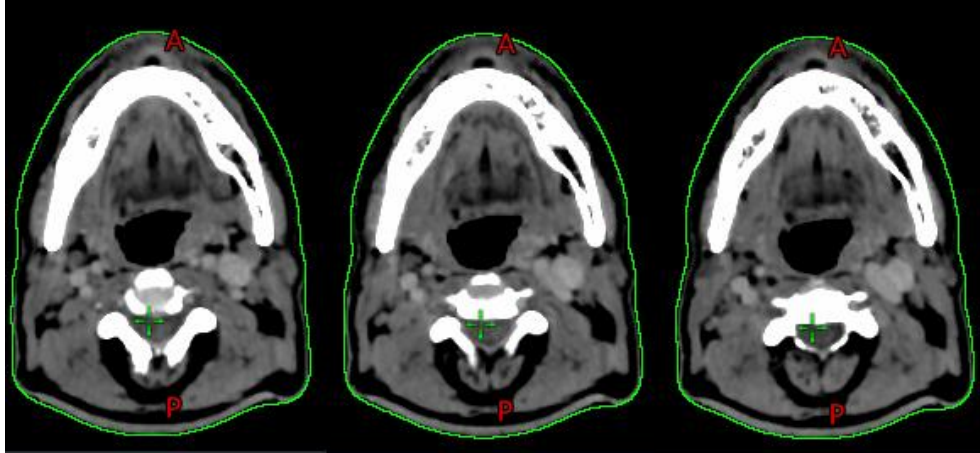


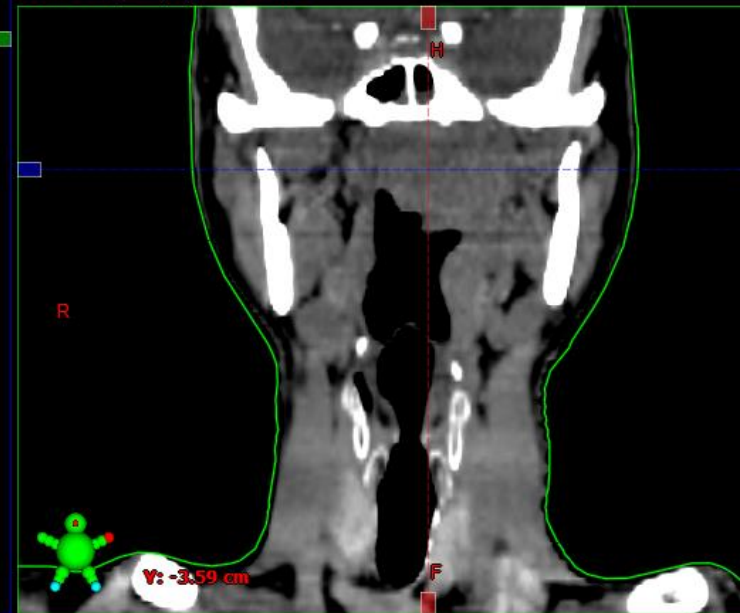
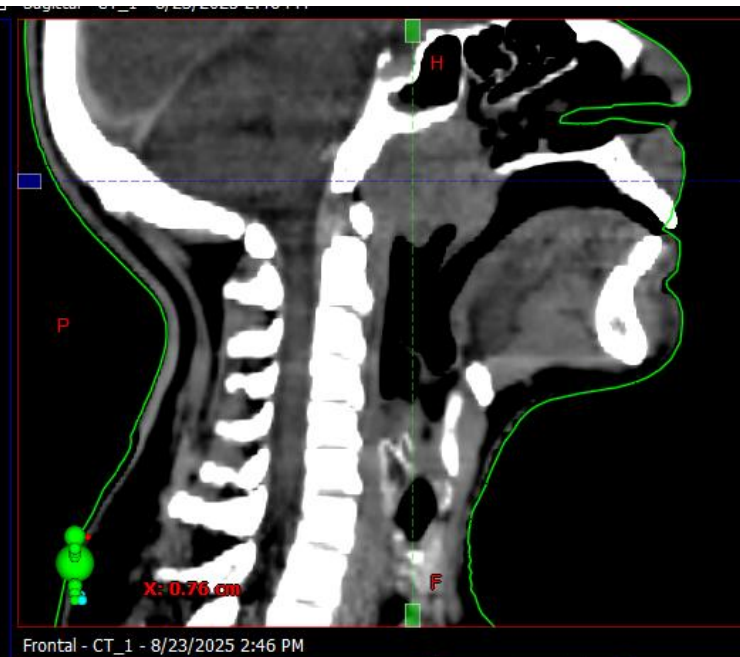
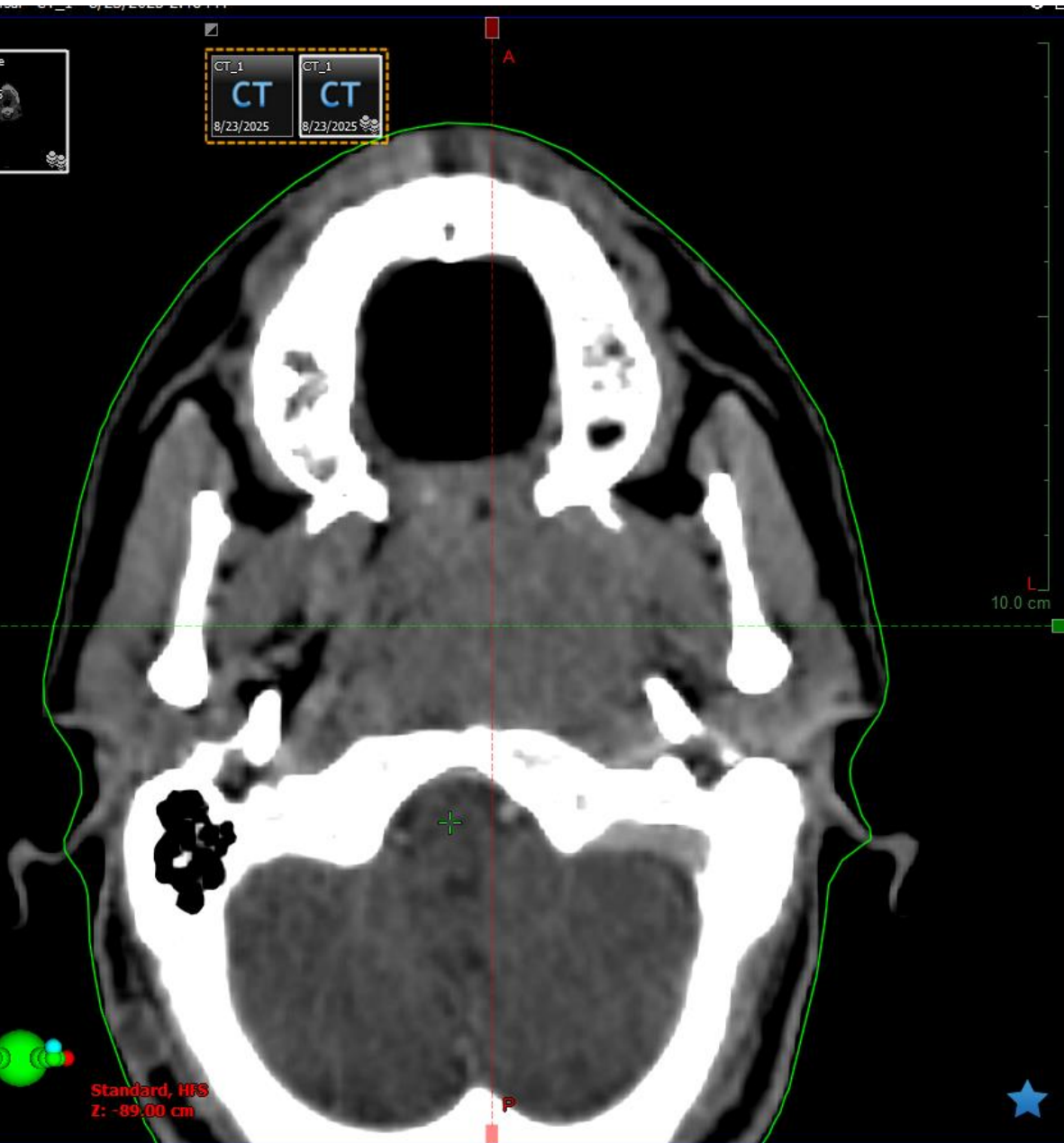
Via Foramen Ovale to Cavernous Sinus

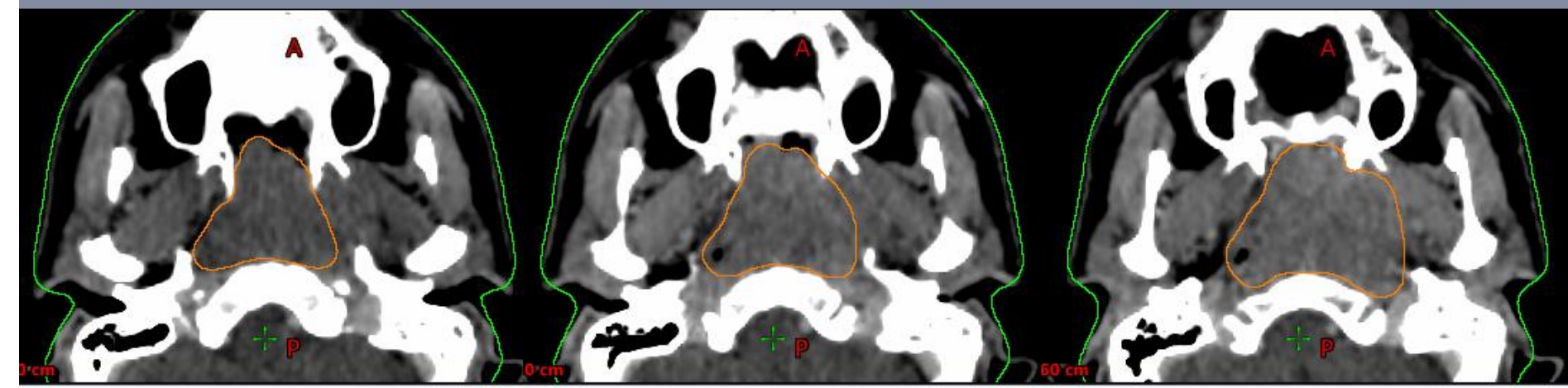
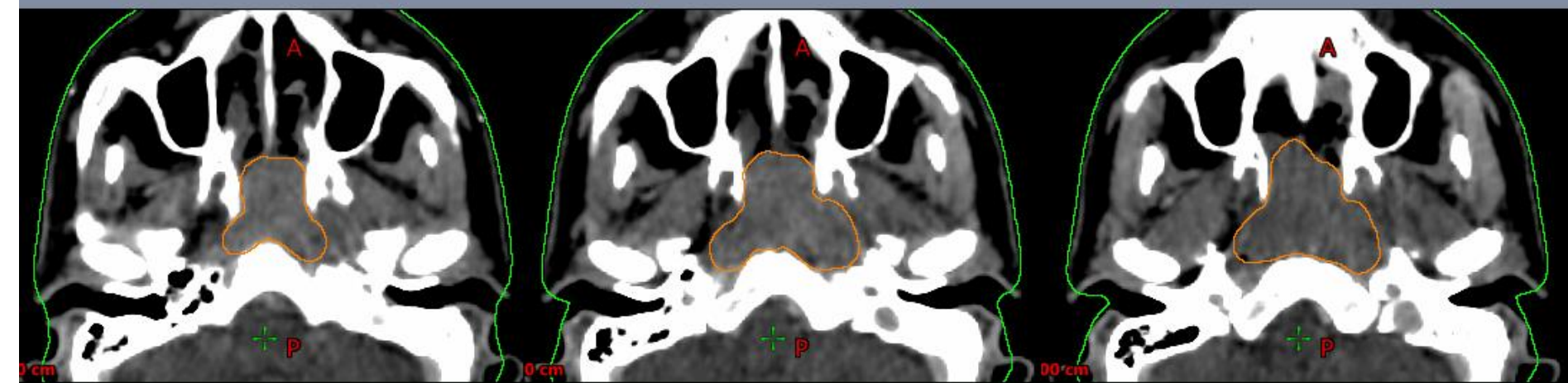
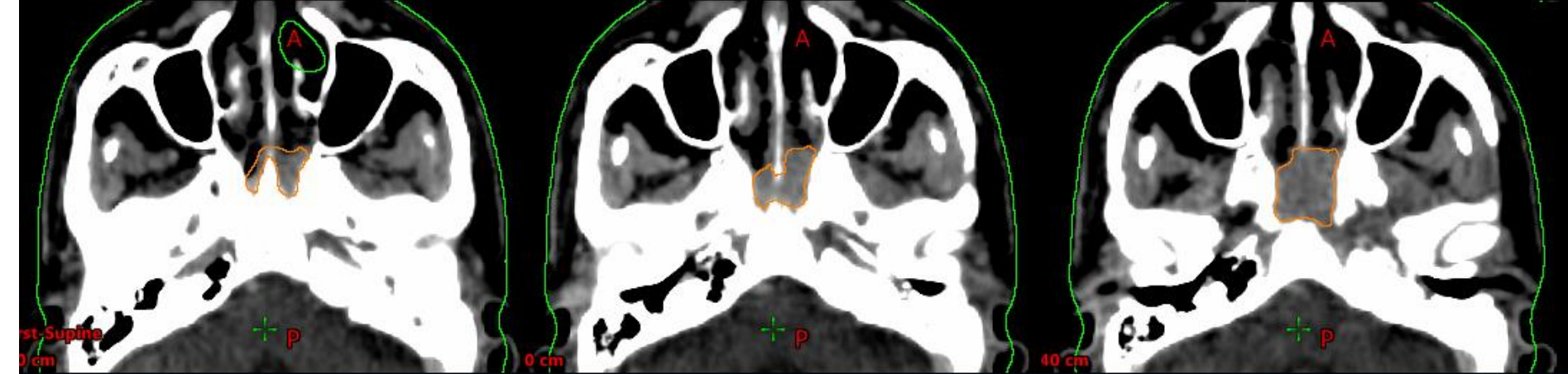


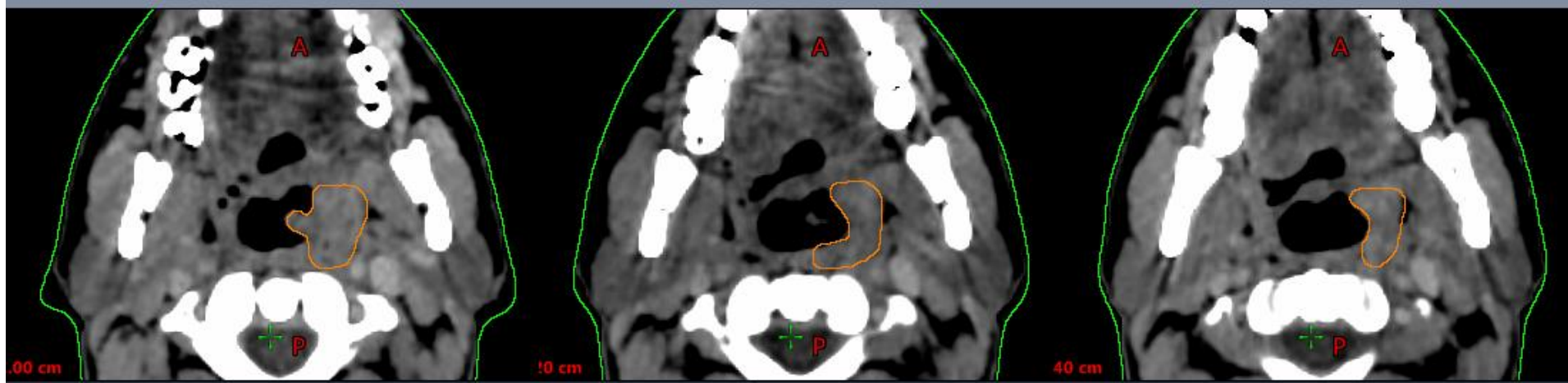
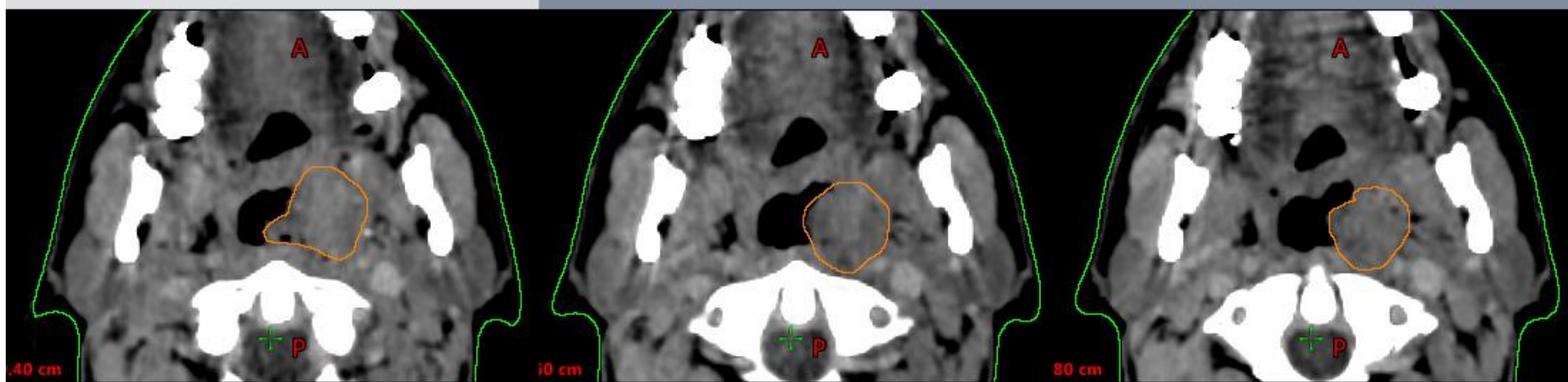
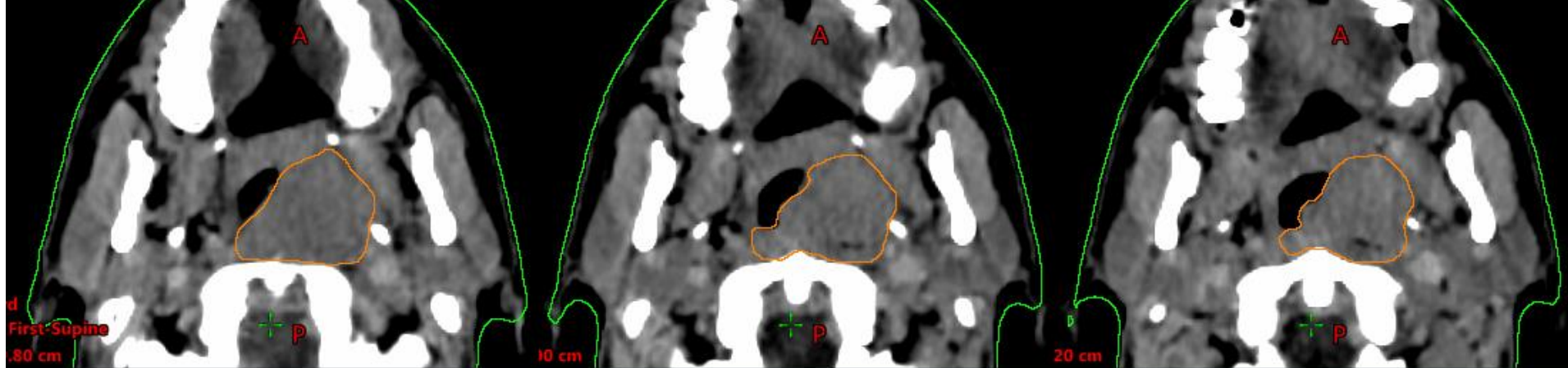


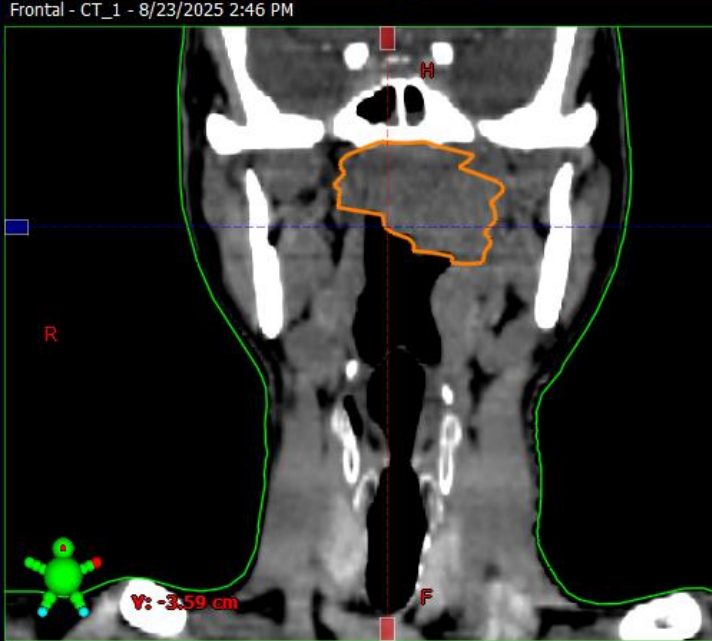
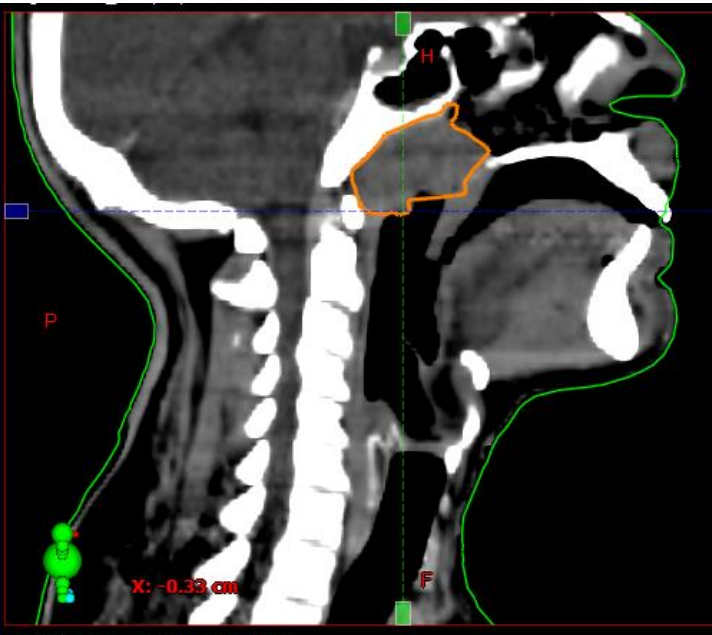
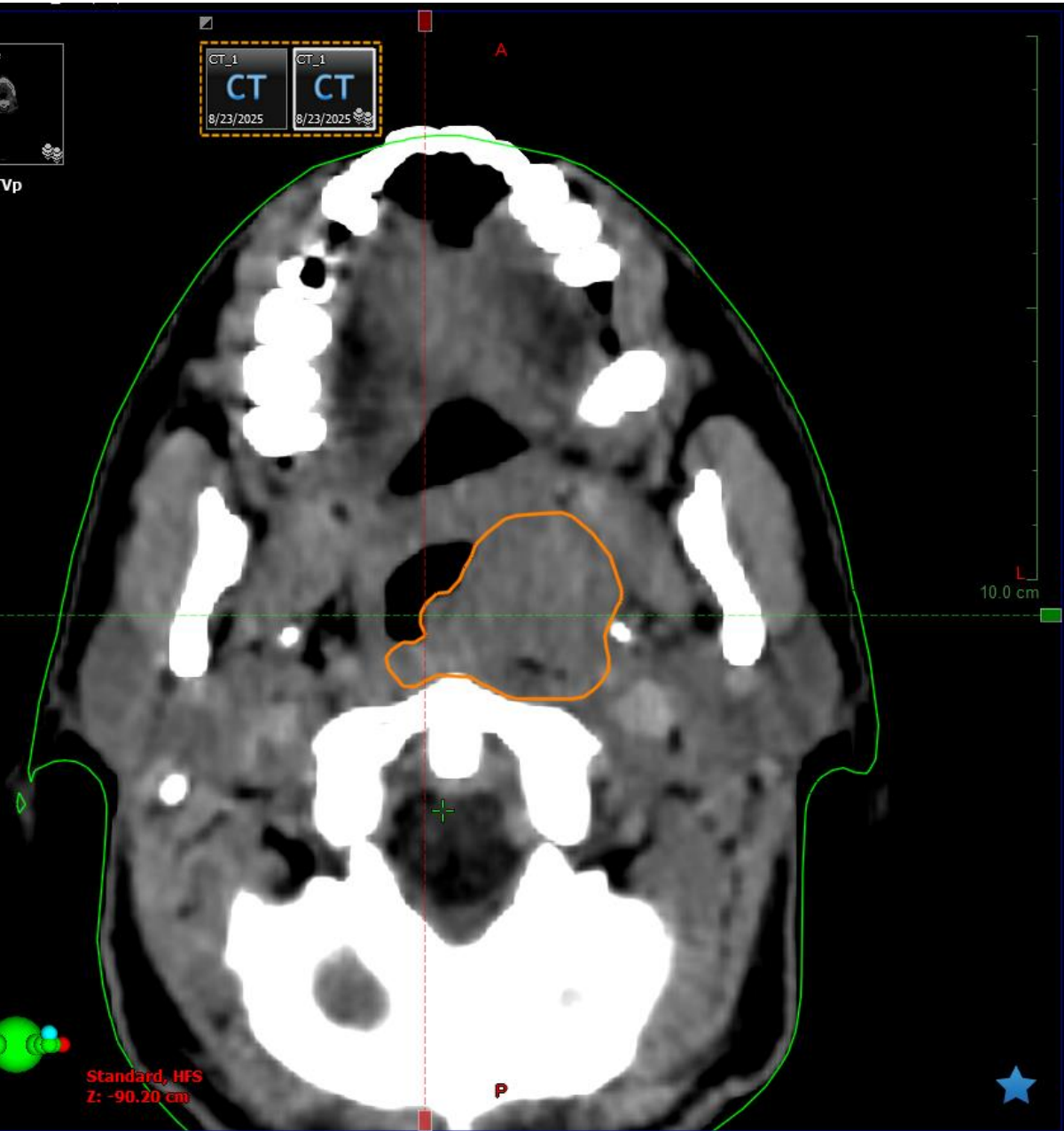


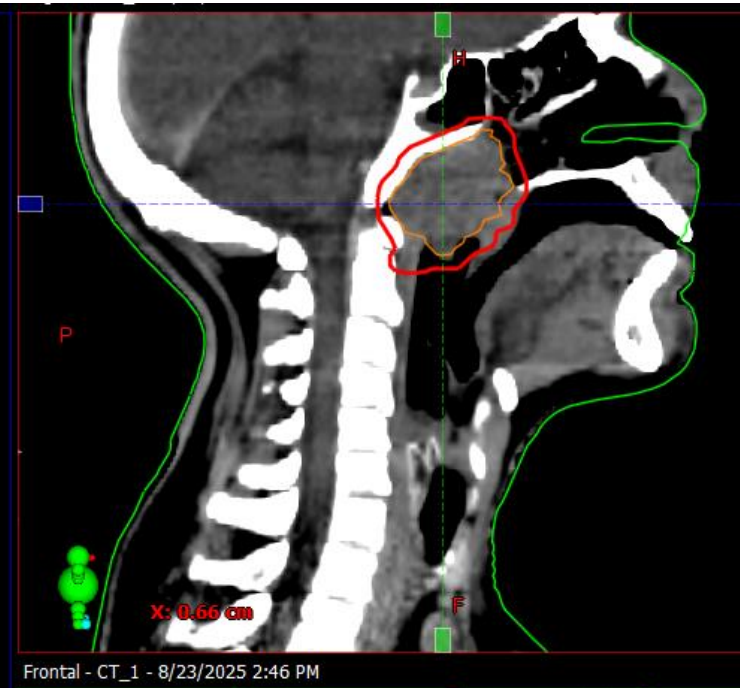
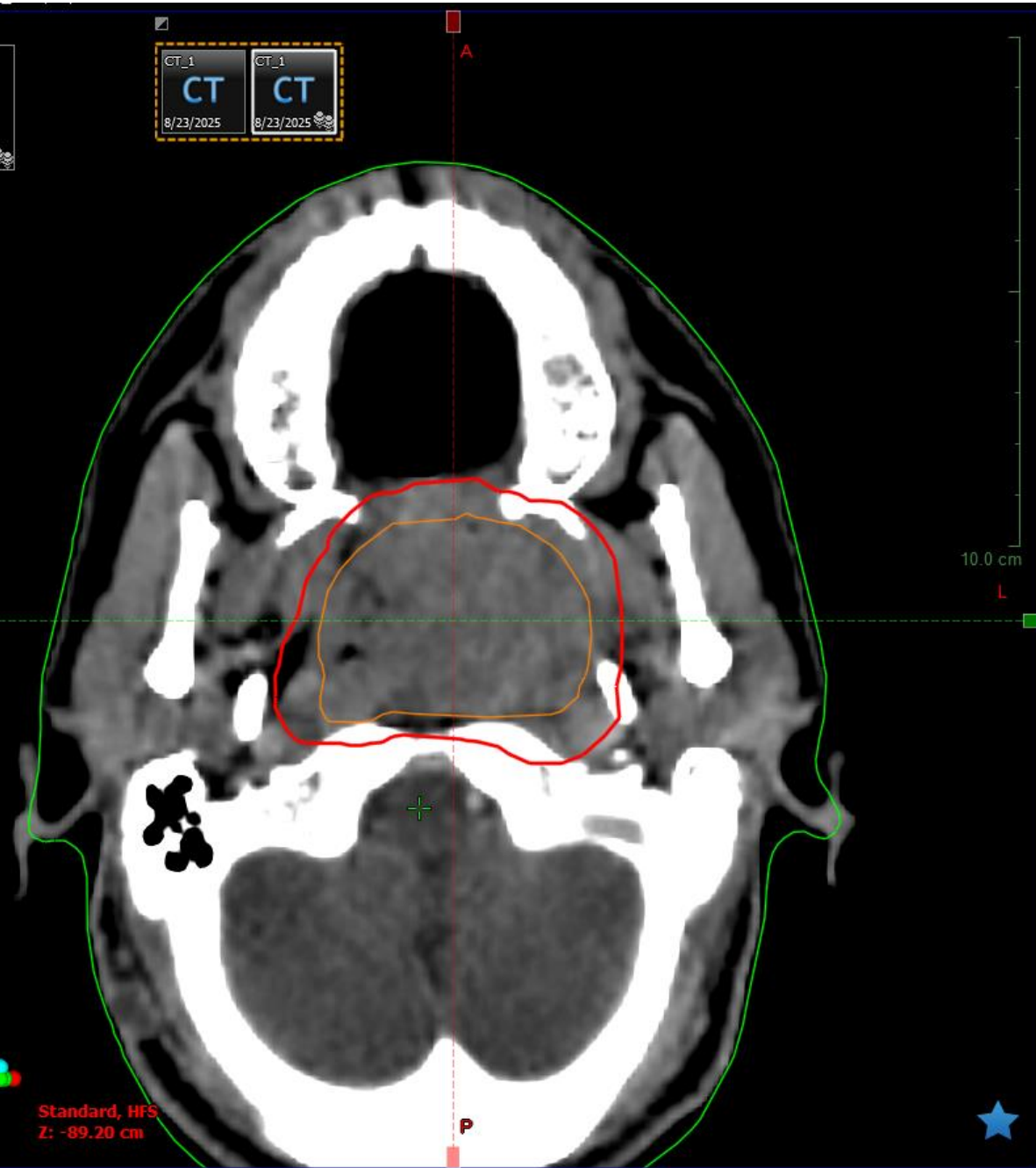




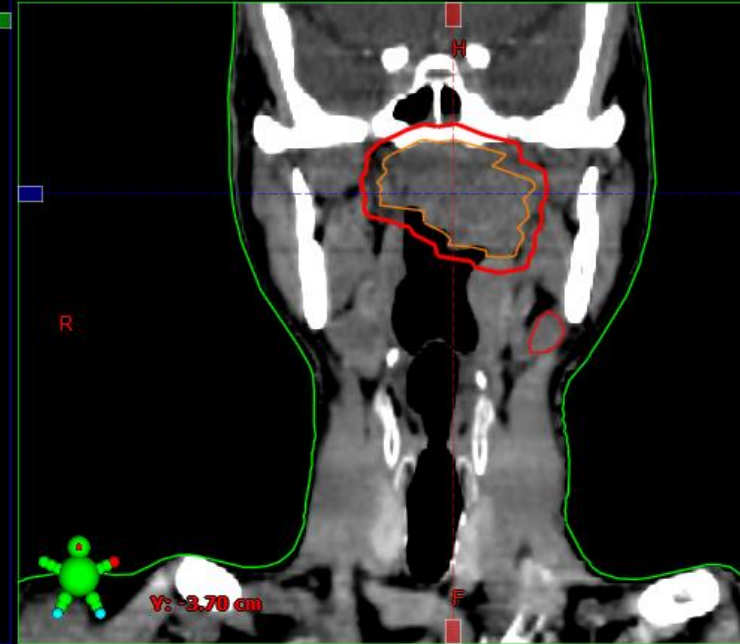


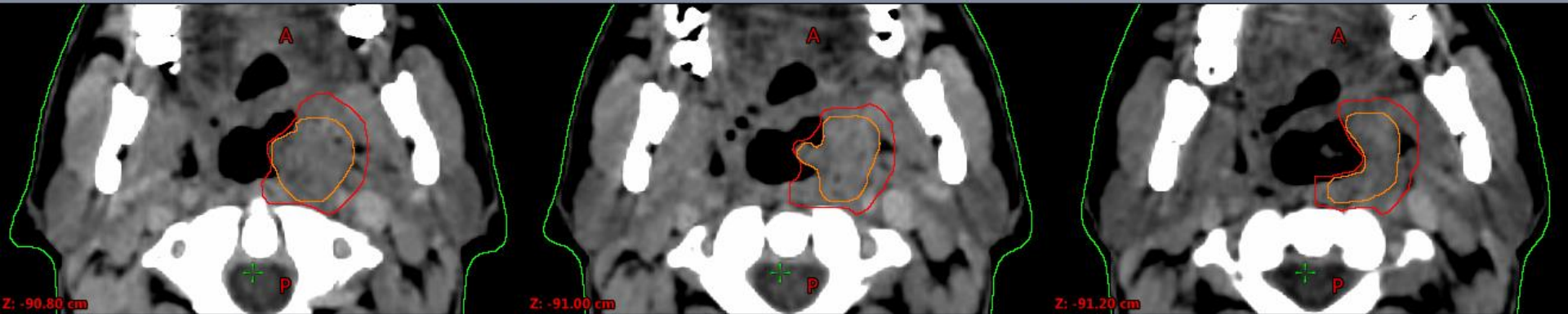
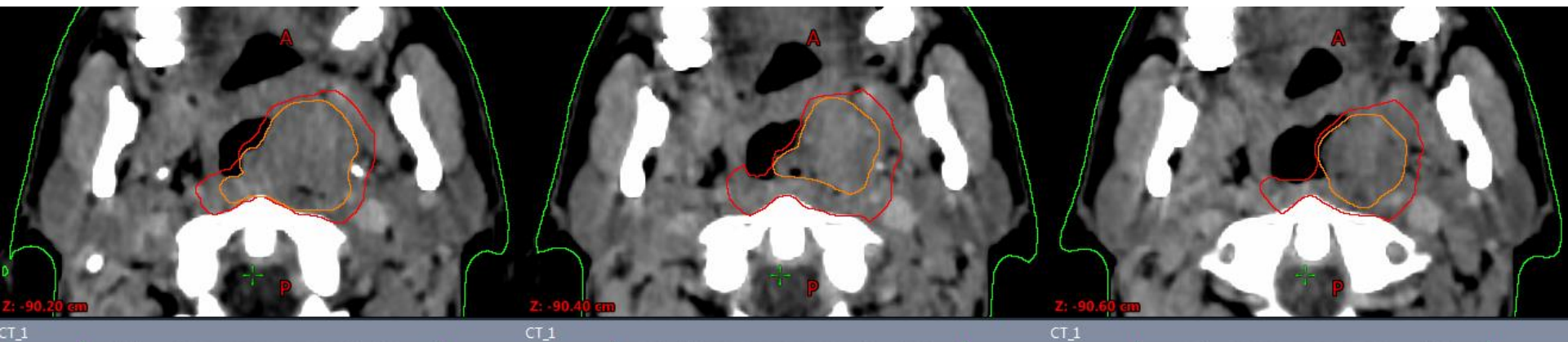


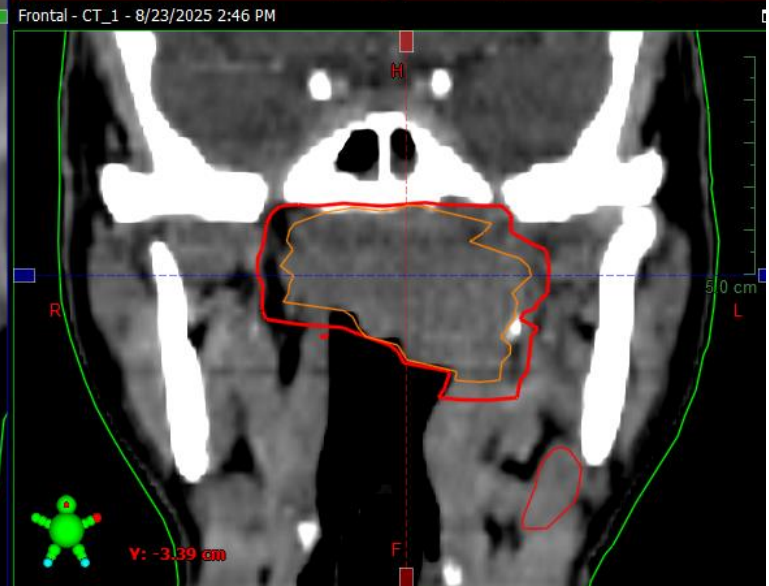
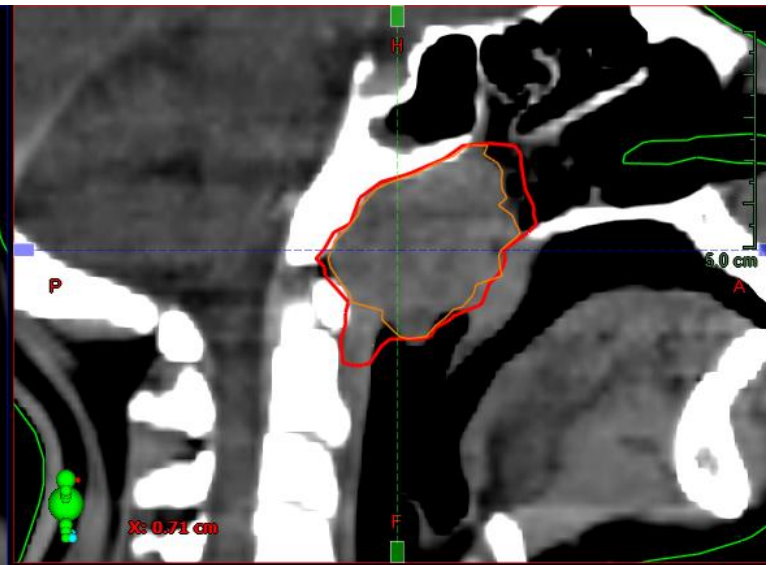
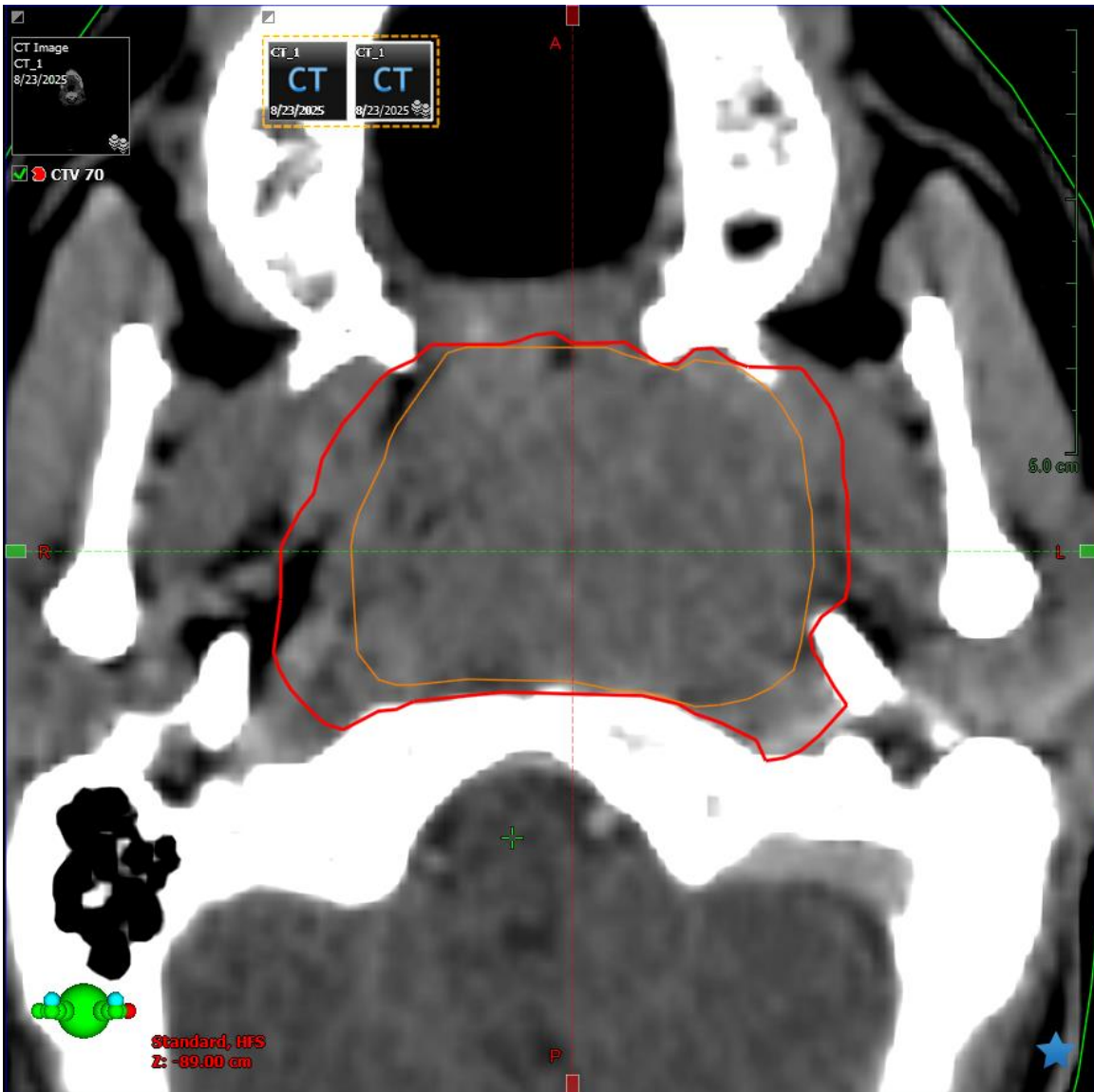




Frontal - CT_1 - 8/23/2025 2:46 PM







Postoperative primary tumor CTV

- It is **difficult** to specify guidance for CTV definition postoperatively as the **anatomy is distorted** (resection and reconstructive flaps).
- A **discussion** between surgeon, pathologist and oncologist is important to define the exact anatomical sites at risk of residual disease.
- Radio-opaque **clips** used to mark close or involved margins can be helpful.

- It is useful to define the site of the **preoperative GTV** on the planning CT to orientate the possible sites of microscopic disease but this is less helpful when the anatomy is very different following a major resection.
- If there is **bulky residual** disease a GTV can be defined and expanded to form the CTV as above.
- It is not known whether the whole **operative field** should be included in the CTV but a more **individualized**, selective approach seems reasonable.

Musculocutaneous Flaps ?

- CTV includes entire flap + margin (about 1 cm) + clips to encompass fully the surgical bed.
- The flap itself is not at risk for recurrence, but the highest risk tissues are adjacent to the flap-normal tissue interface.

Cervical lymph node CTV

- **Selective approach** to neck dissection is as effective as more radical operations, so this give the ability to create and treat relevant smaller nodal volumes.
- Defining nodal CTV requires both selection of appropriate nodal levels and delineation of those levels on CT.
- Two nodal CTVs are selected (CTV₆₀, CTV₅₄):
 - **High risk** containing involved nodes or those close to the primary site
 - **Low risk** containing levels thought to be at risk of microscopic disease

Risk Groups

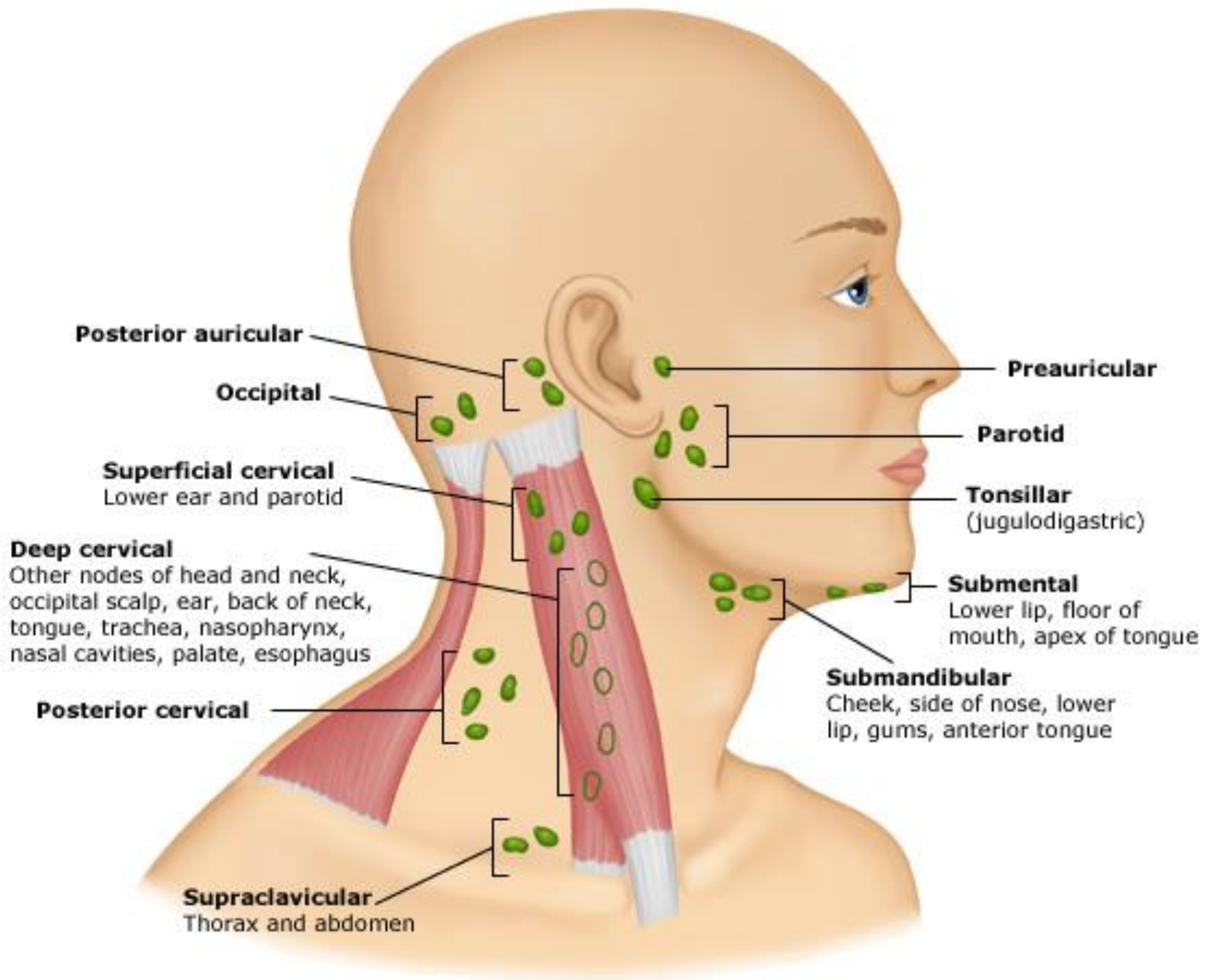
Group	Risk	Stage	Site
Low risk	< 20%	T1	Floor of mouth, retromolar trigone, gingiva, hard palate, buccal mucosa.

Risk Groups (Cont.)

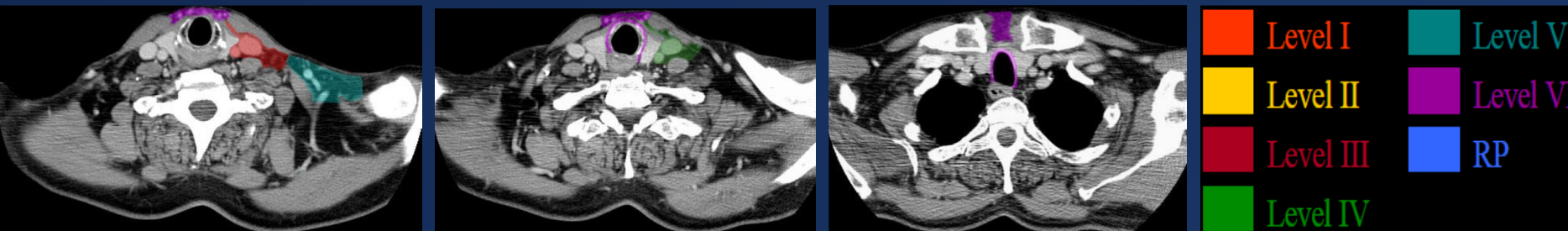
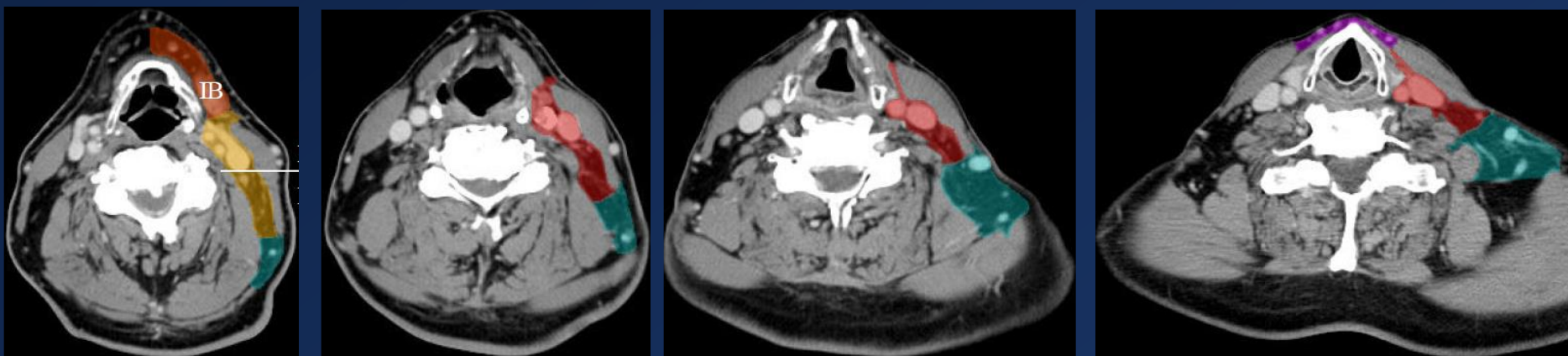
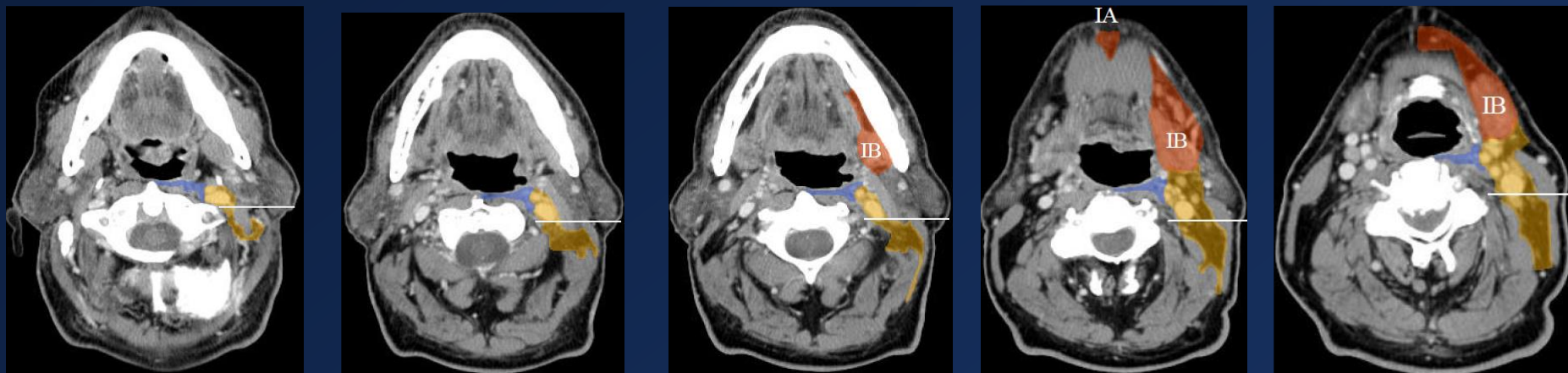
Group	Risk	Stage	Site
Intermediate risk	20-30%	T1	Oral tongue, soft palate, tonsil, pharyngeal wall, supraglottic larynx.
		T2	Floor of mouth, retromolar trigone, gingiva, hard palate, buccal mucosa.

Risk Groups (Cont.)

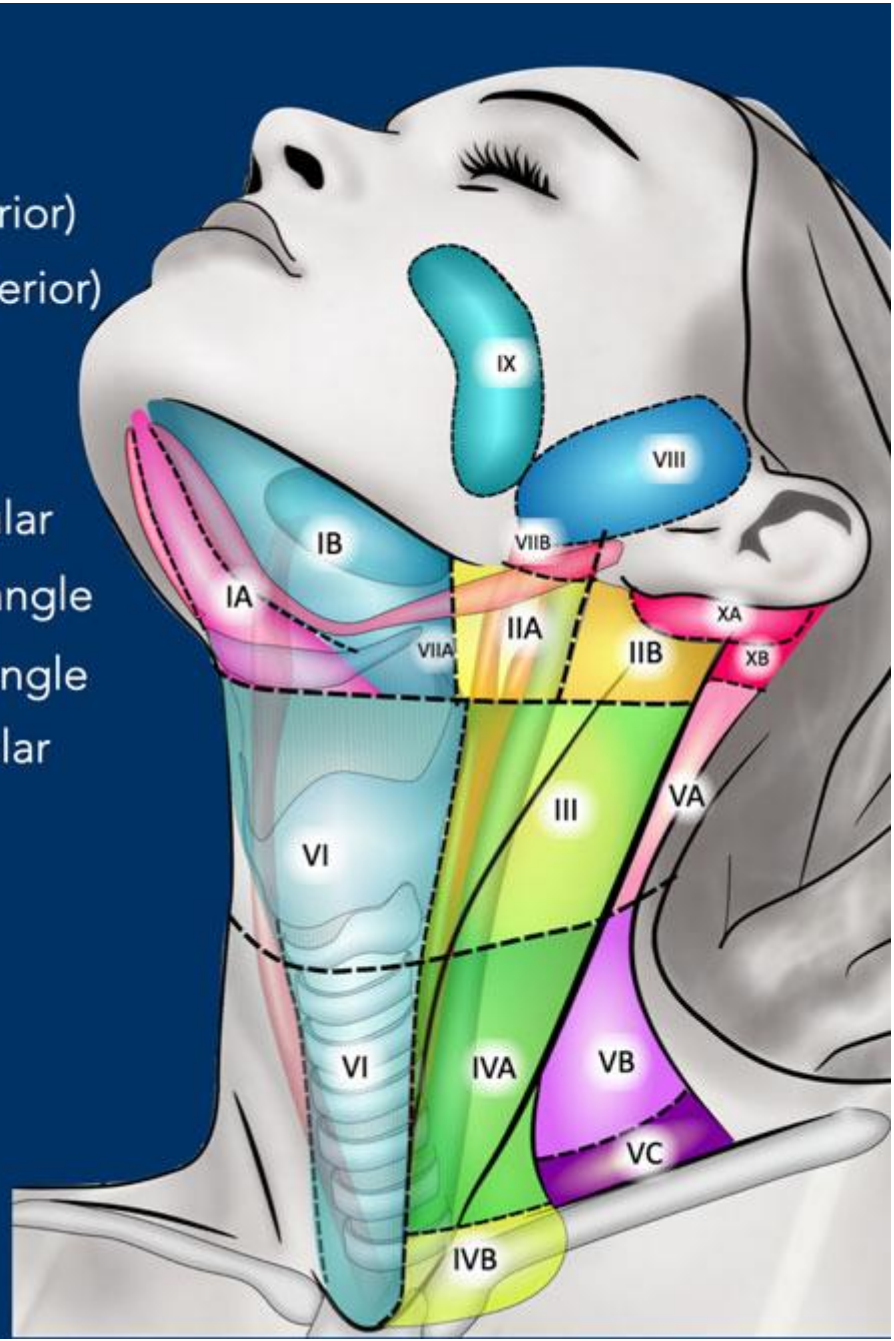
Group	Risk	Stage	Site
High risk	> 30%	T1-4	Nasopharynx, pyriform sinus, base of tongue.
		T2-4	Oral tongue, soft palate, tonsil, pharyngeal wall, supraglottic larynx.
		T3-4	Floor of mouth, retromolar trigone, gingiva, hard palate, buccal mucosa.

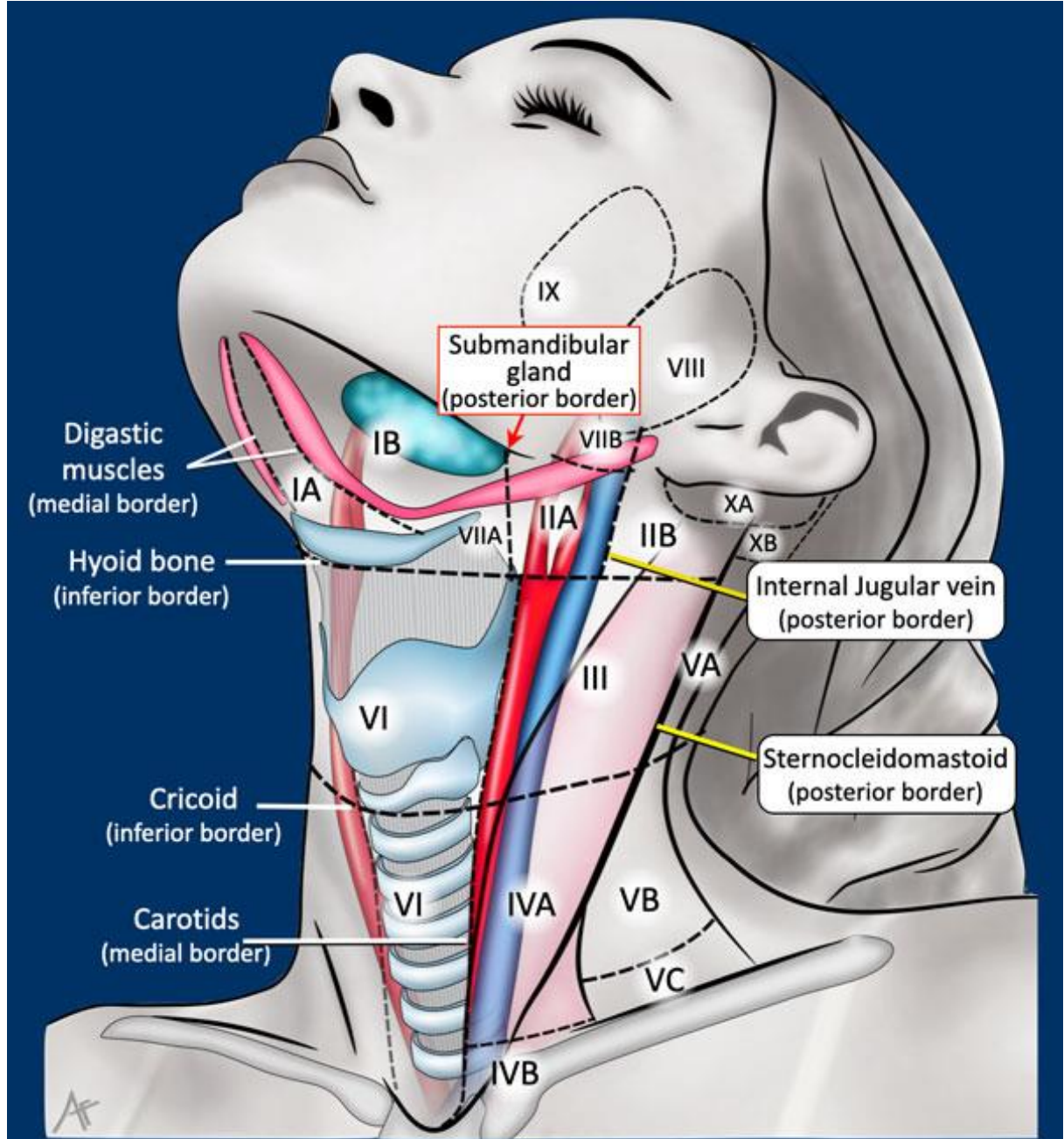


CTV_{LN} Delineation

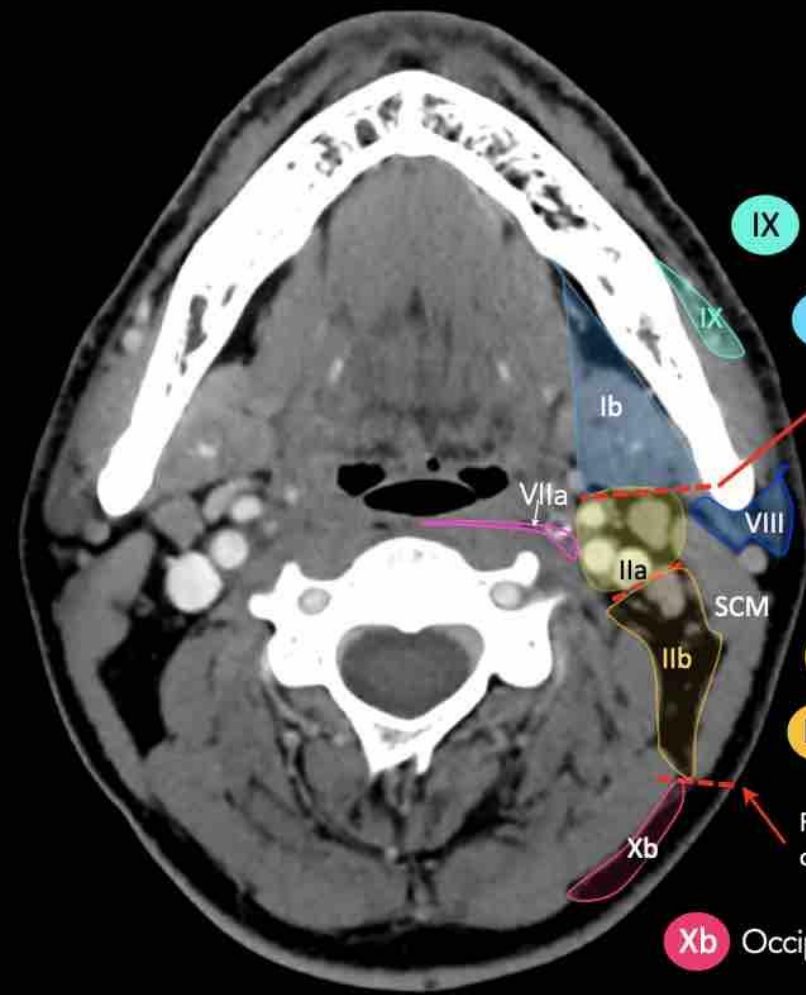


- IA Submental
- IB Submandibular
- IIA Upper jugular (anterior)
- IIB Upper jugular (posterior)
- III Mid jugular
- IVA Lower jugular
- IVB Medial supraclavicular
- VA Upper posterior triangle
- VB Lower posterior triangle
- VC Lateral supraclavicular
- VI Anterior cervical
- VIIA Retro-pharyngeal
- VIIIB Retro-styloid
- VIII Parotid
- IX Bucco-facial
- XA Retro-auricular
- XB Occipital

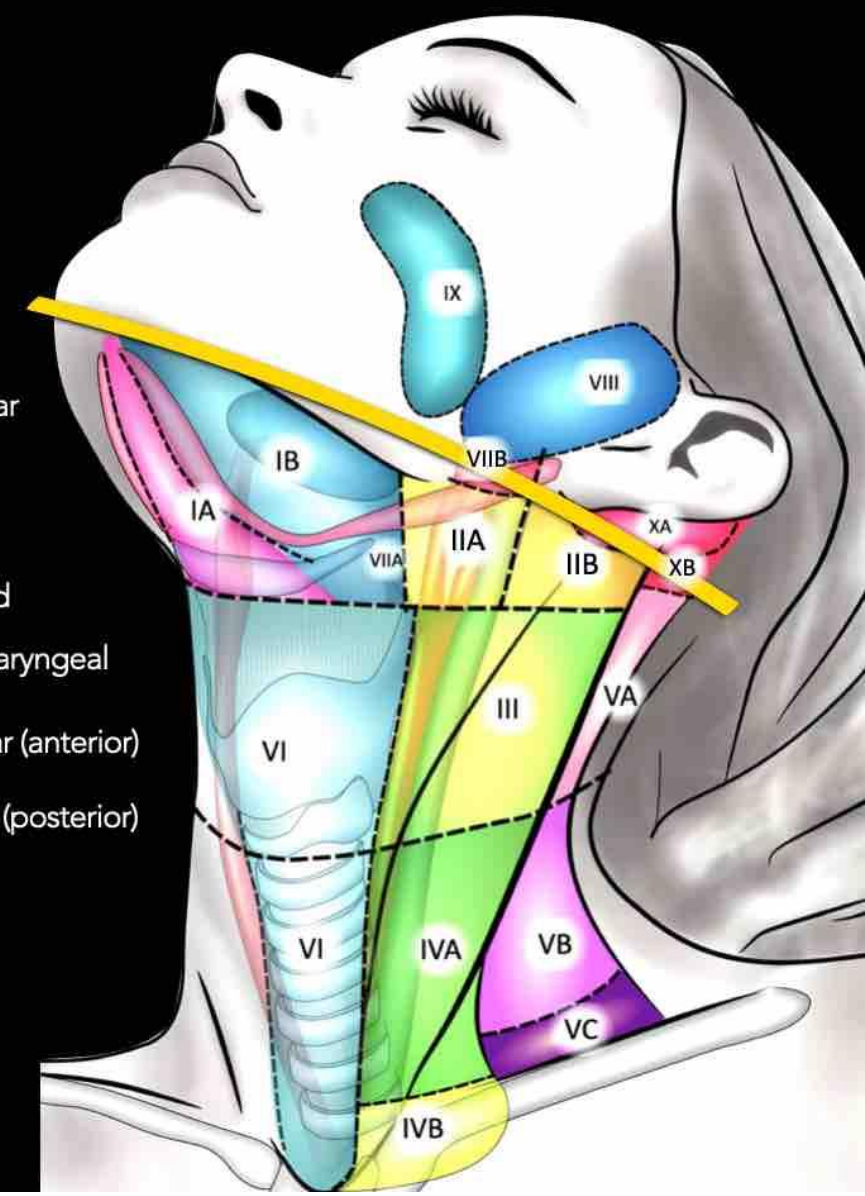


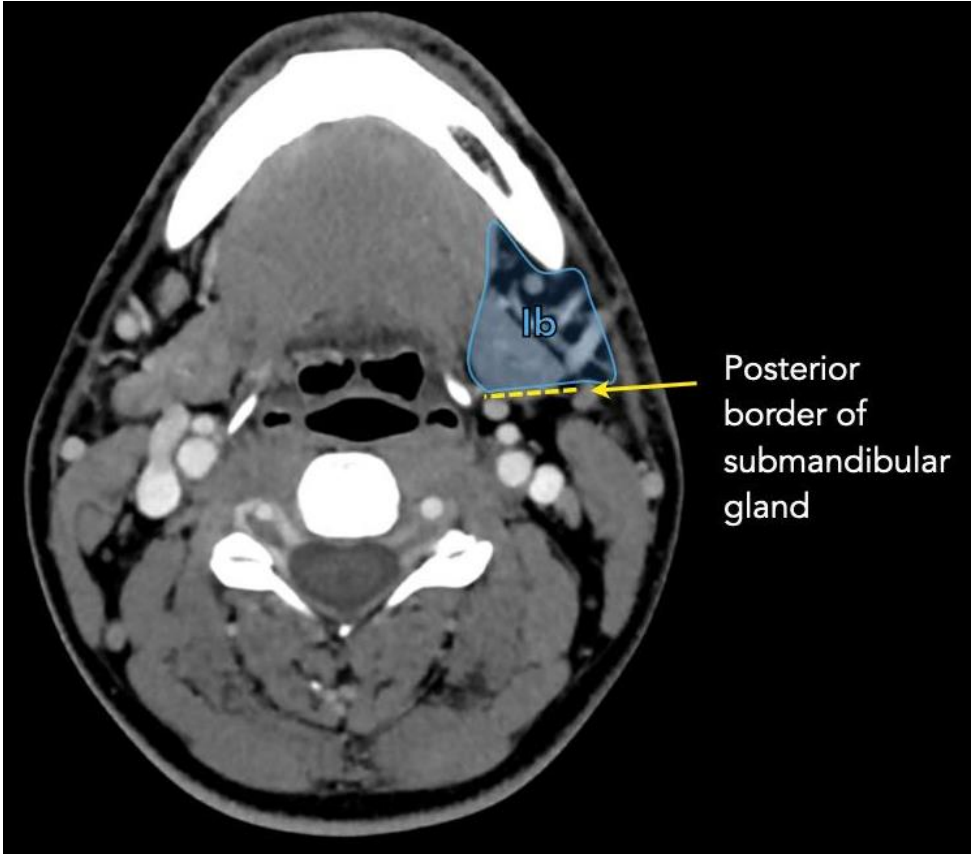
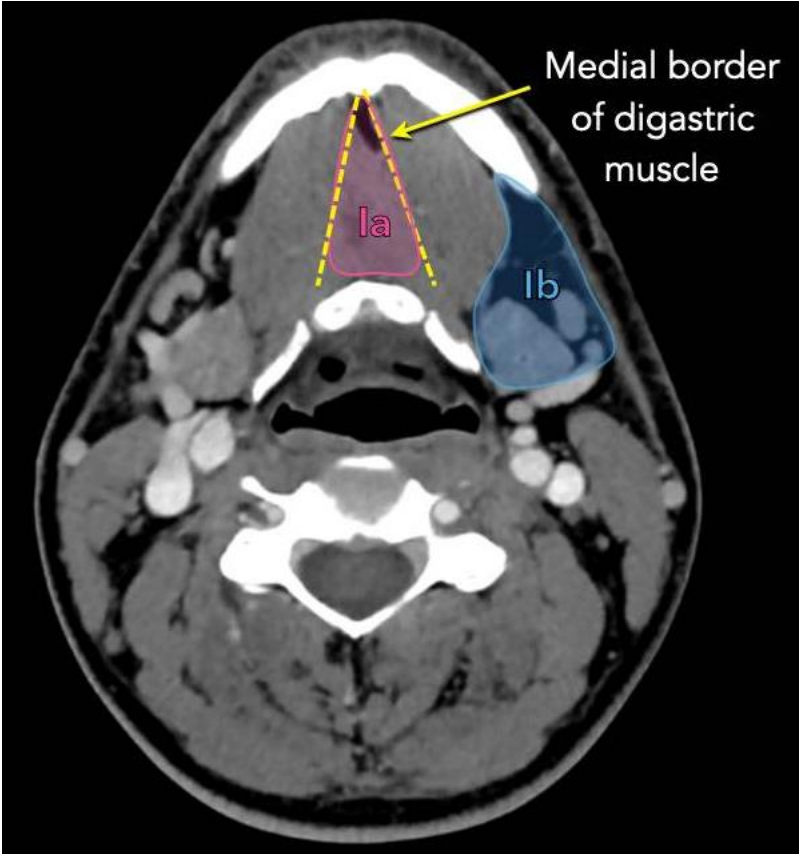
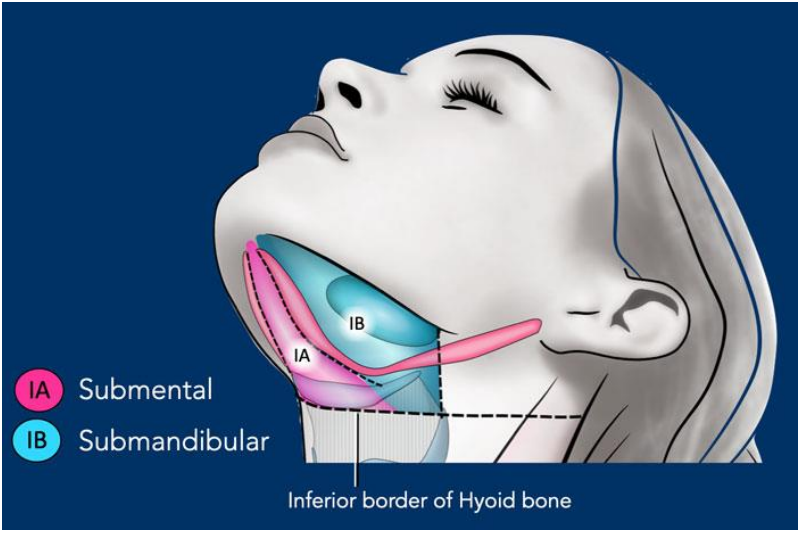


Manubrium of sternum
(superior border)



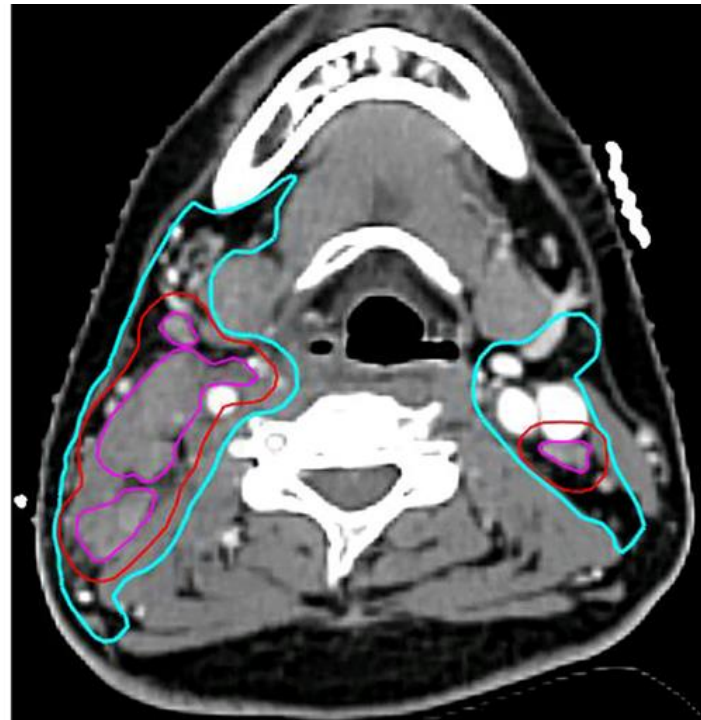
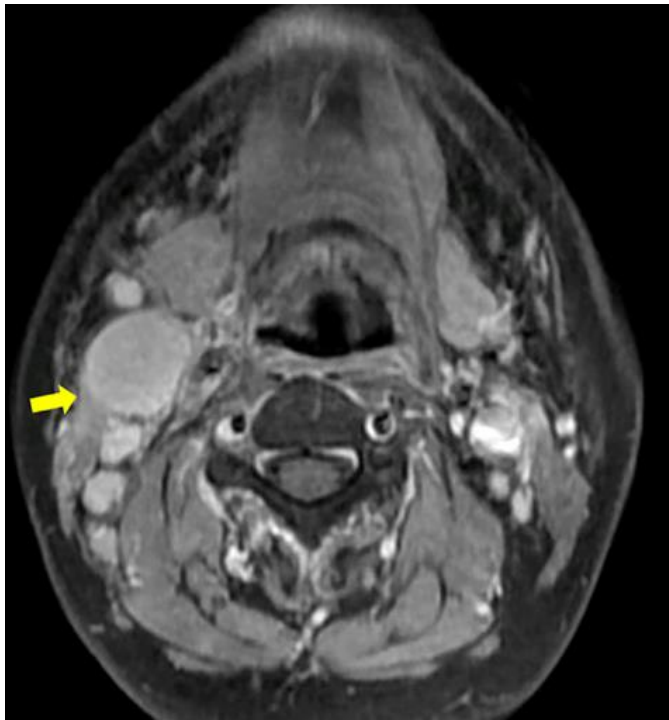
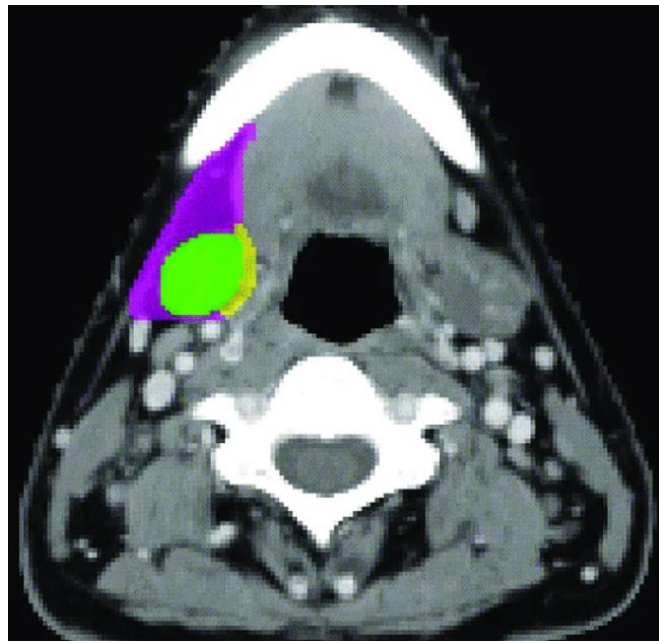
- IX** Bucco-facial
- Ib** Submandibular
- Posterior border of submand gland
- VIII** Parotid
- VIIa** Retro-pharyngeal
- IIa** Upper jugular (anterior)
- IIb** Upper jugular (posterior)
- Posterior border of sternoclav muscle
- Xb** Occipital

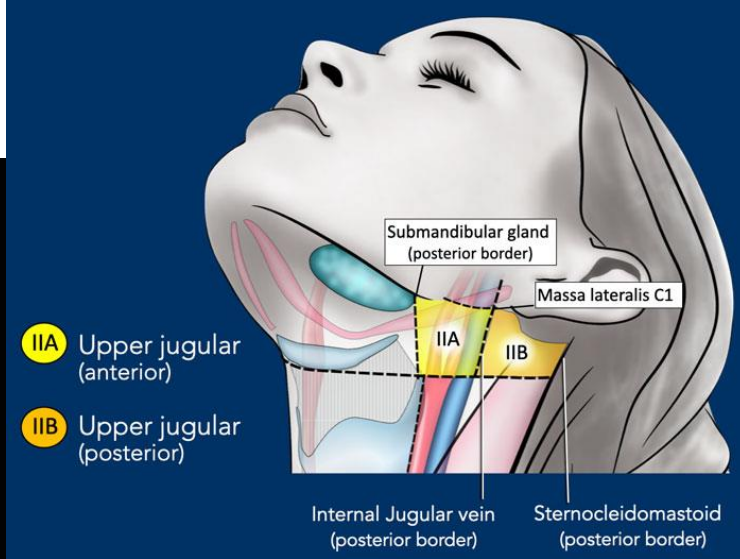
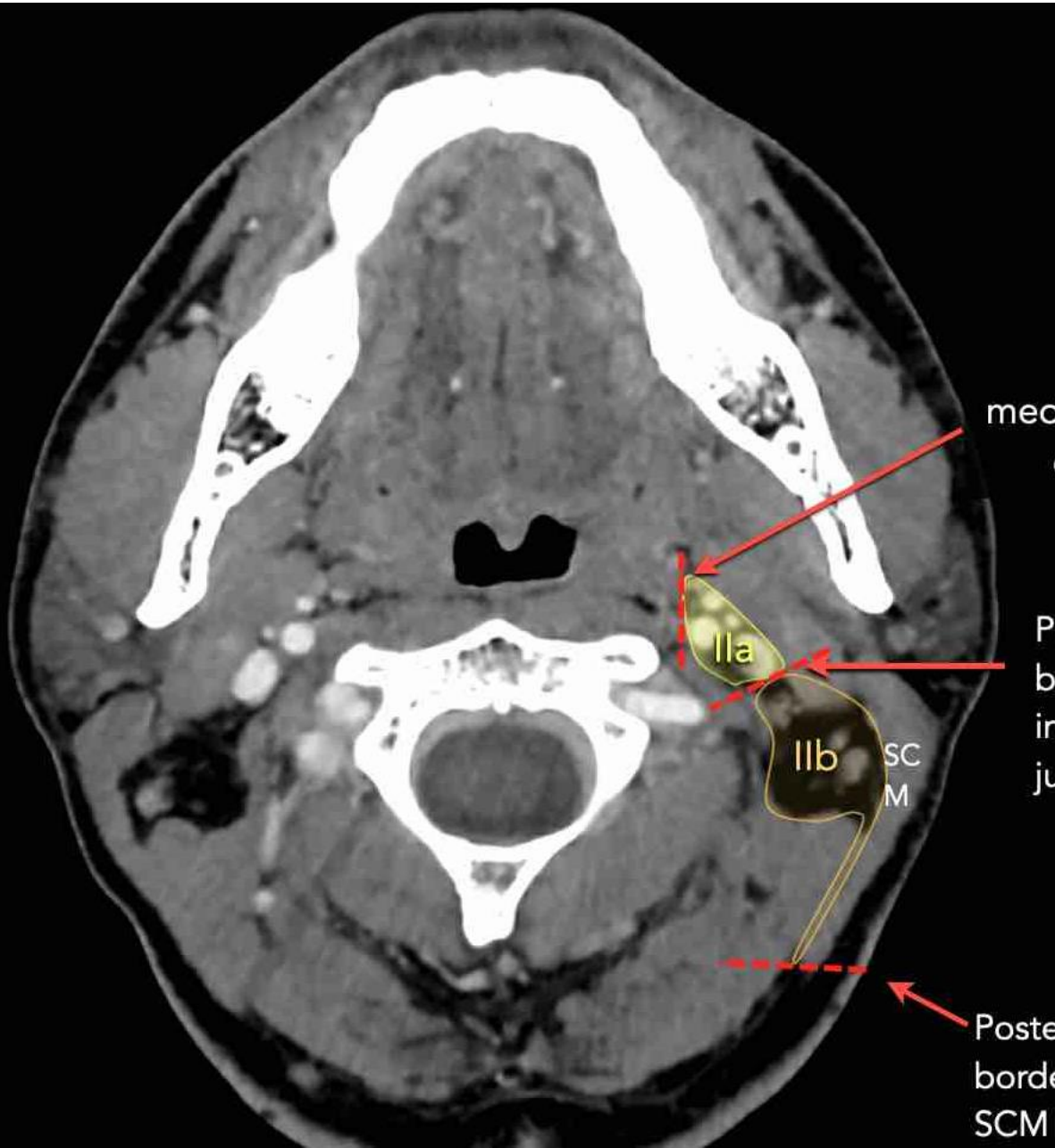




Modified level Ib??

- Recent studies showed that level Ib LNs are located in the anterolateral space, there is no evidence of metastatic LNs inside the submandibular gland.
- IG-2024 recommends that the submandibular gland might be spared in level Ib coverage unless involved.





medial border
of ACI

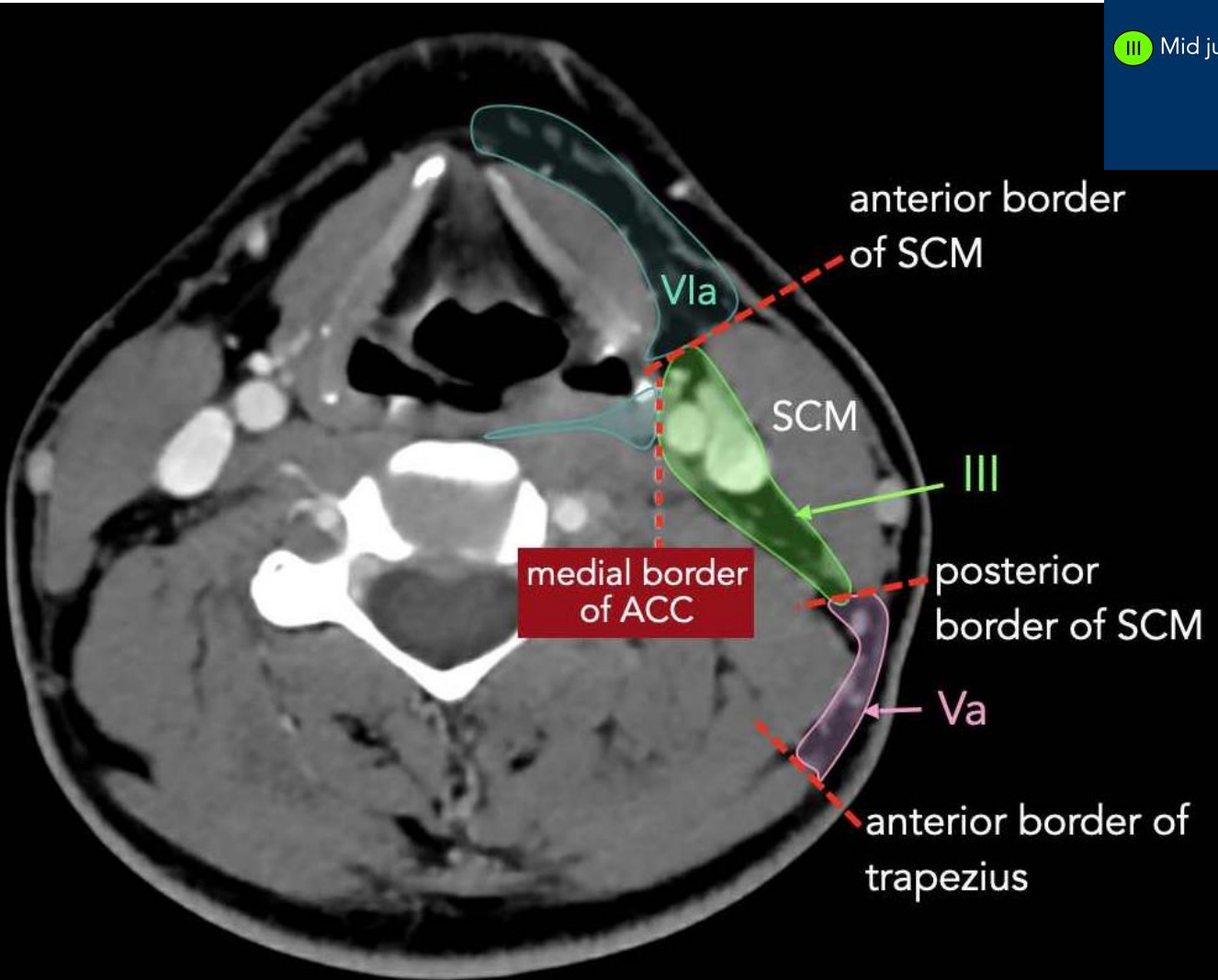
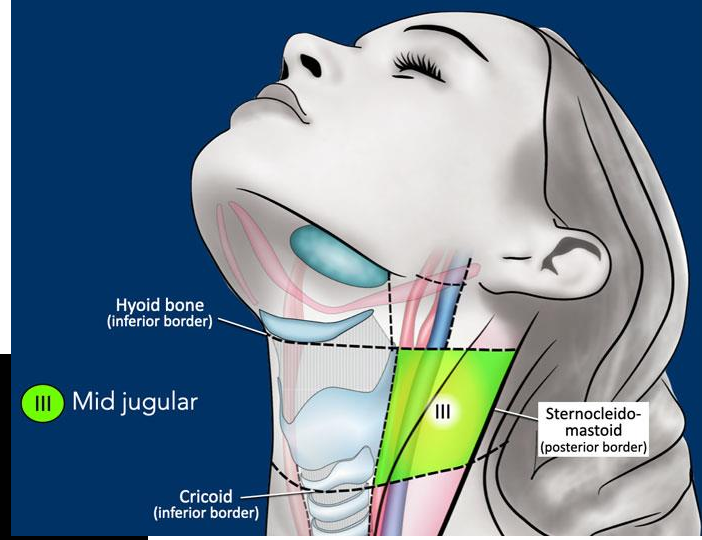
Posterior
border of
internal
jugular vein

Posterior
border of
SCM

Ila

IIB

SCM



IVA

Lower jugular

IVB

Medial supra-clavicular

Cricoid
(inferior border)

III

IVA

Sternocleido-
mastoid
(posterior border)

2cm > manubrium sternal

anterior border of SCM ❌

posterior
border of SCM

Vla

IVa

SCM

anterior border
of trapezius

Vlb

Vb

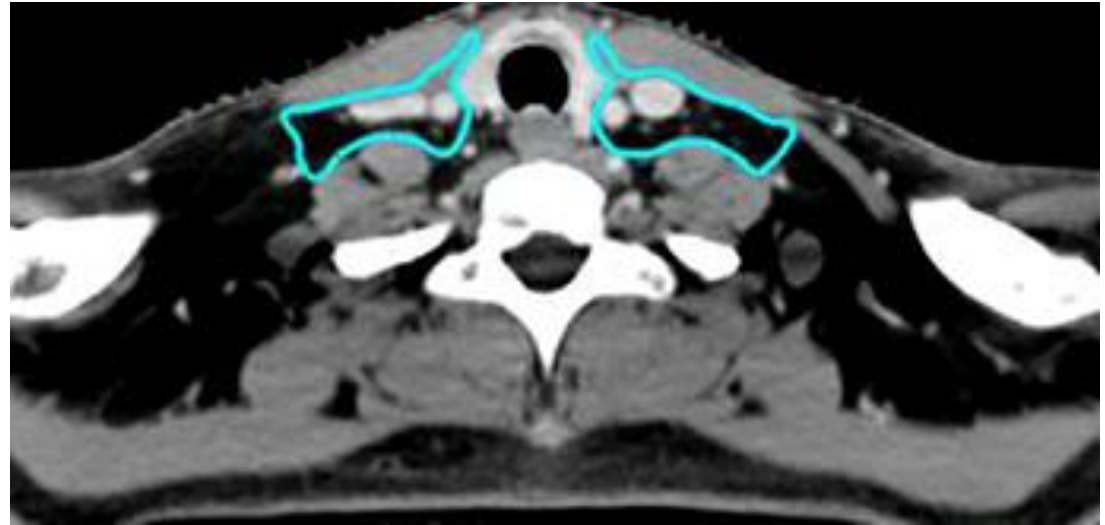
medial border
of ACC

trapezius

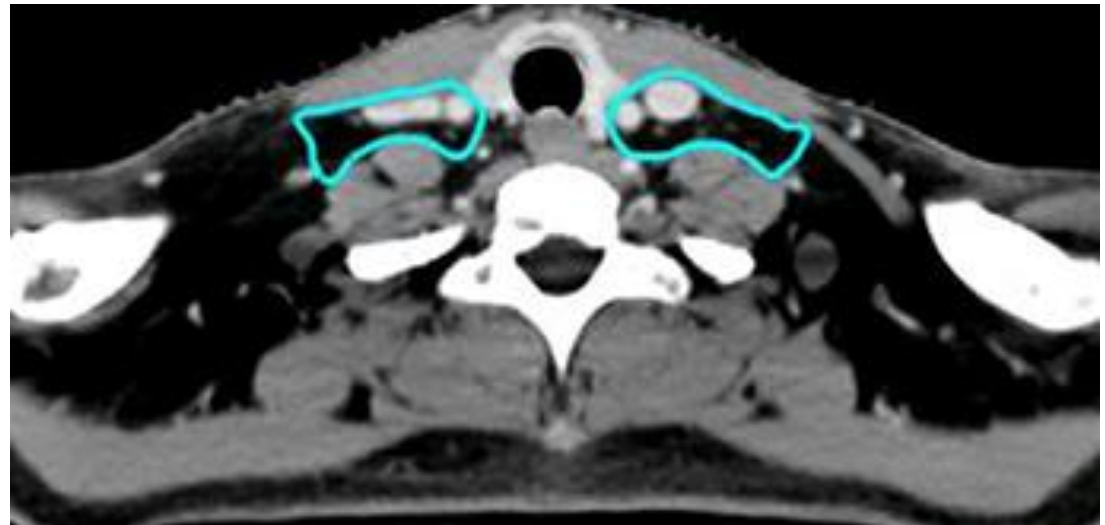
F

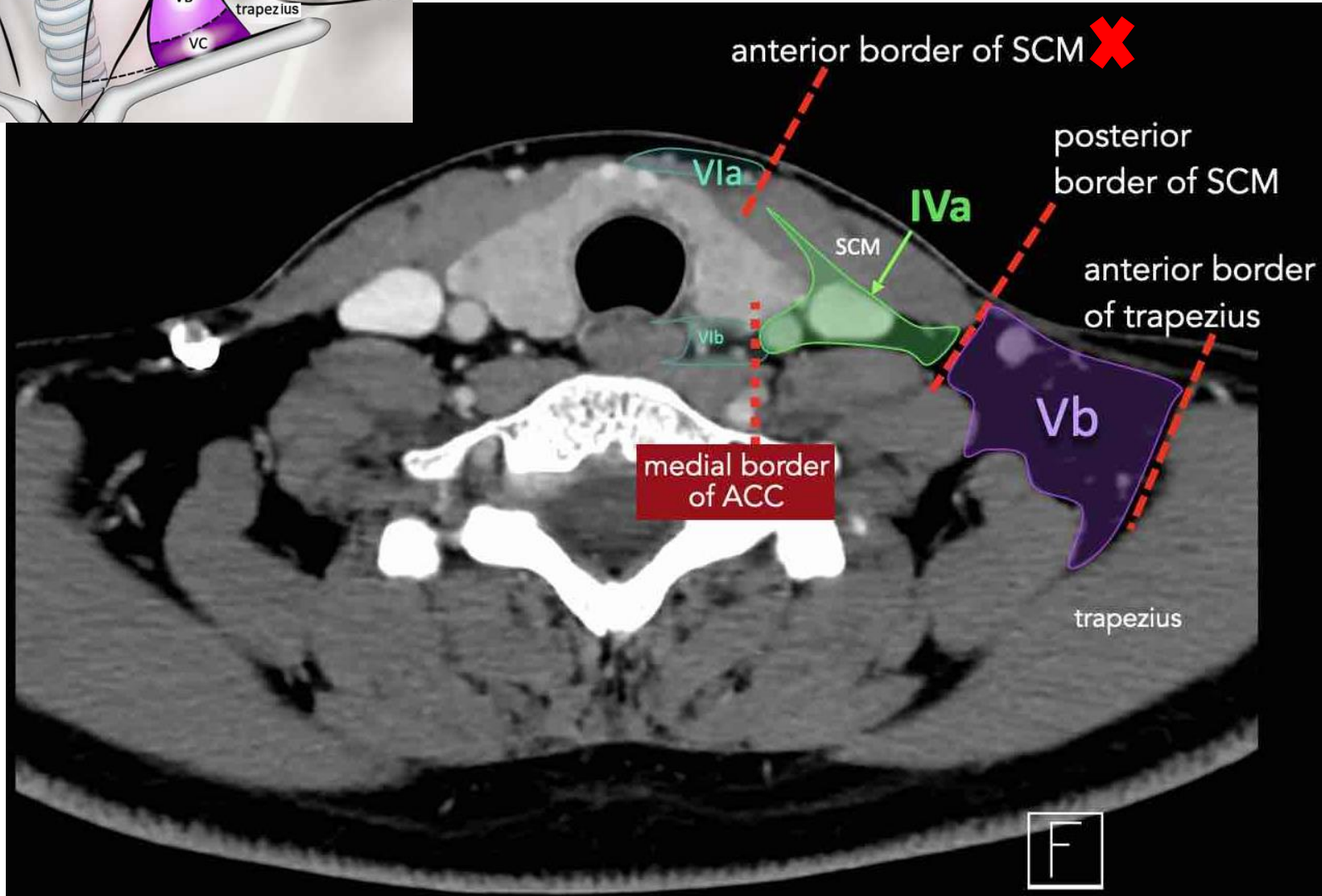
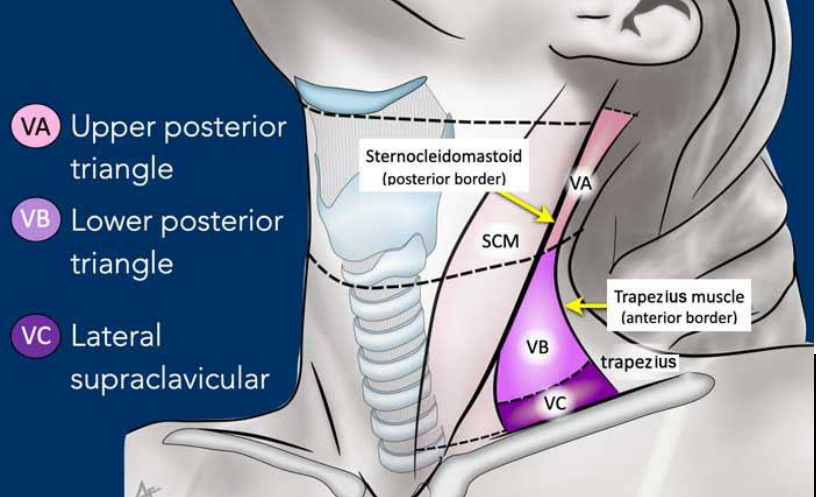
Anterior border of level IVa

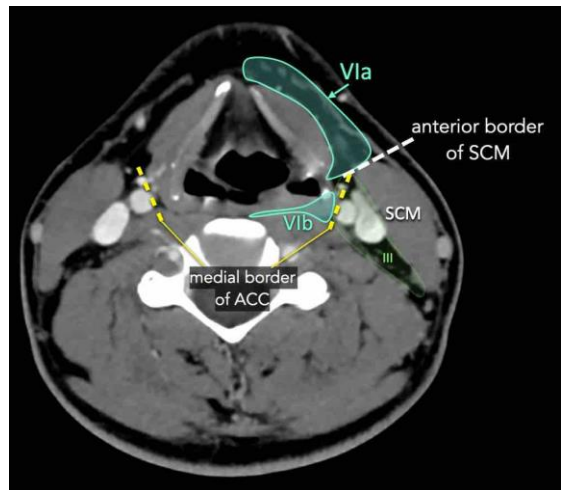
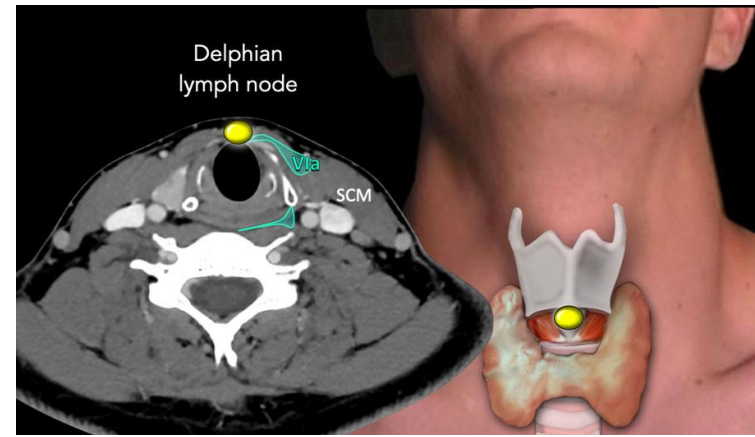
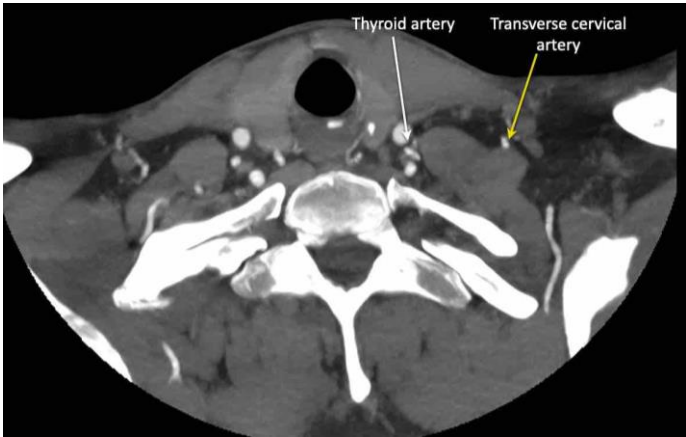
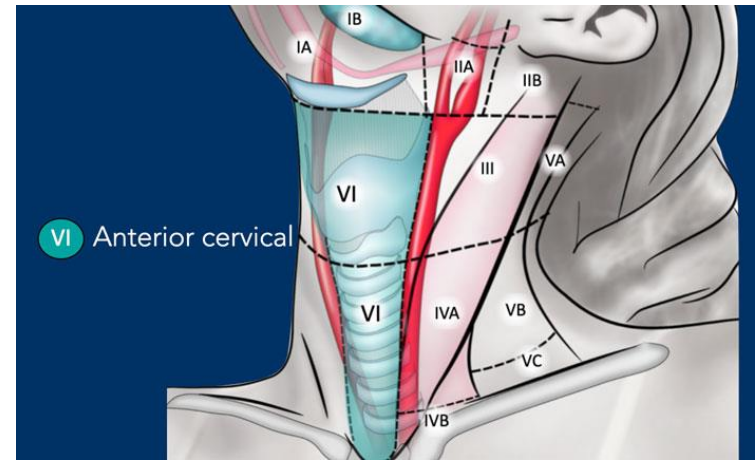
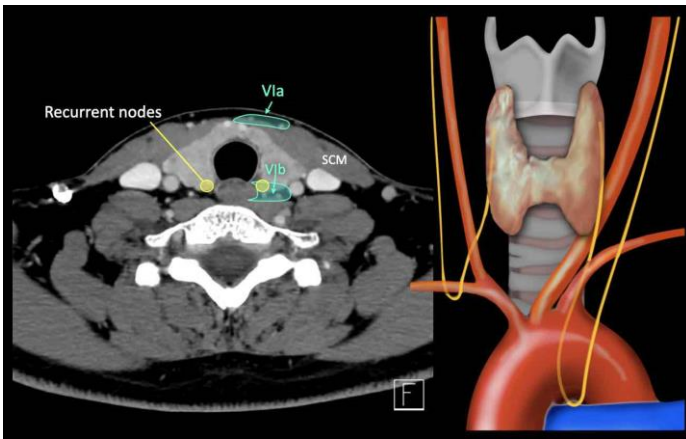
The 2013 consensus guideline by Gregoire et al. specifies the anterior edge of sternomastoid muscle as the landmark.

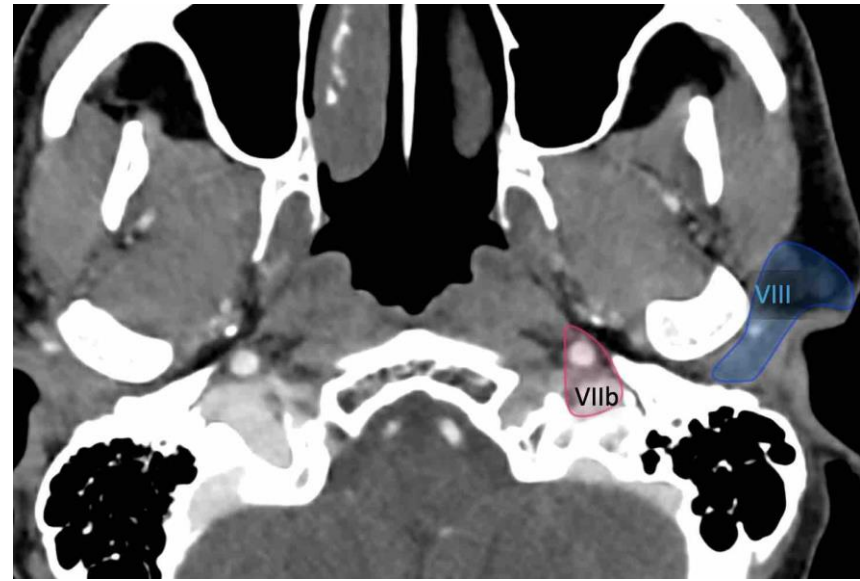
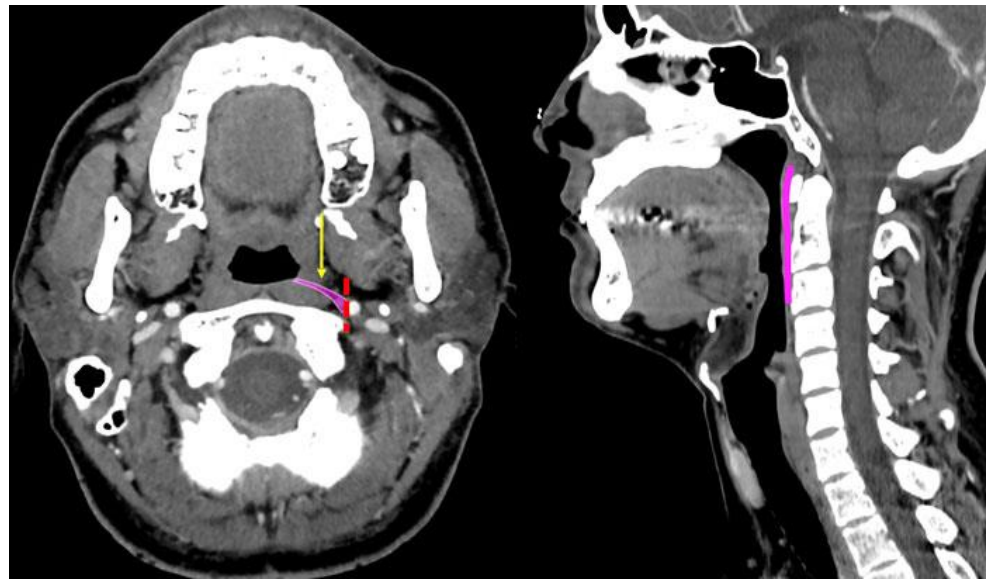
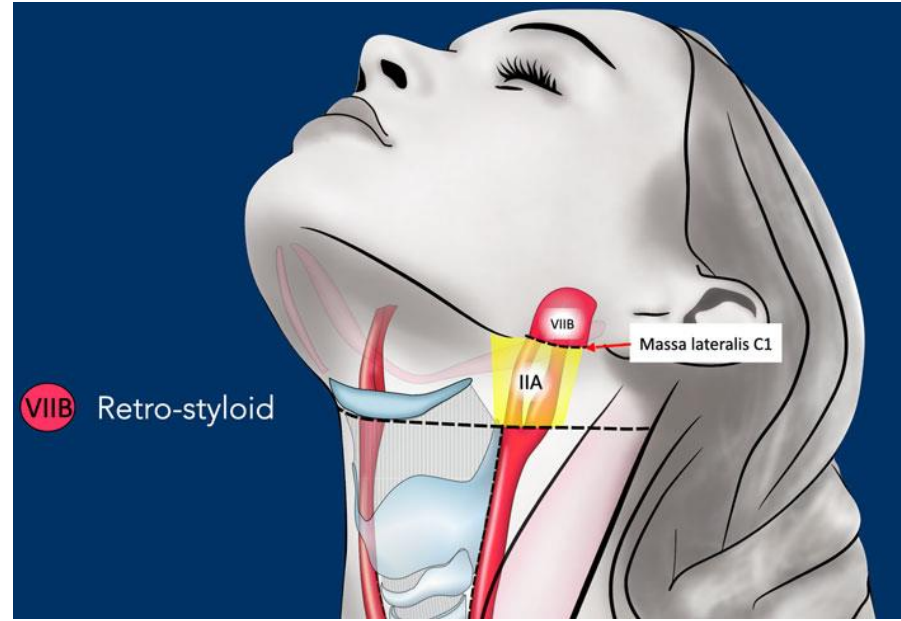
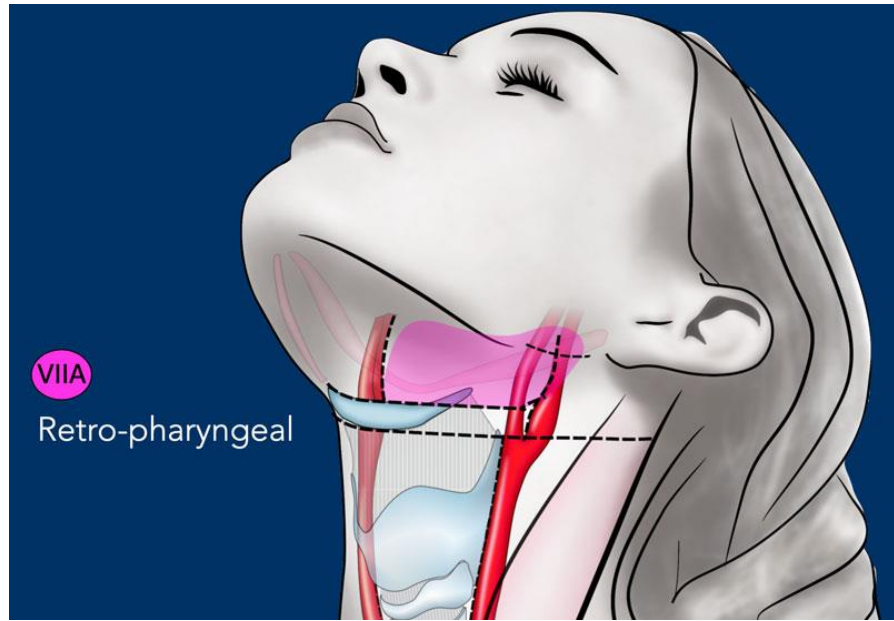


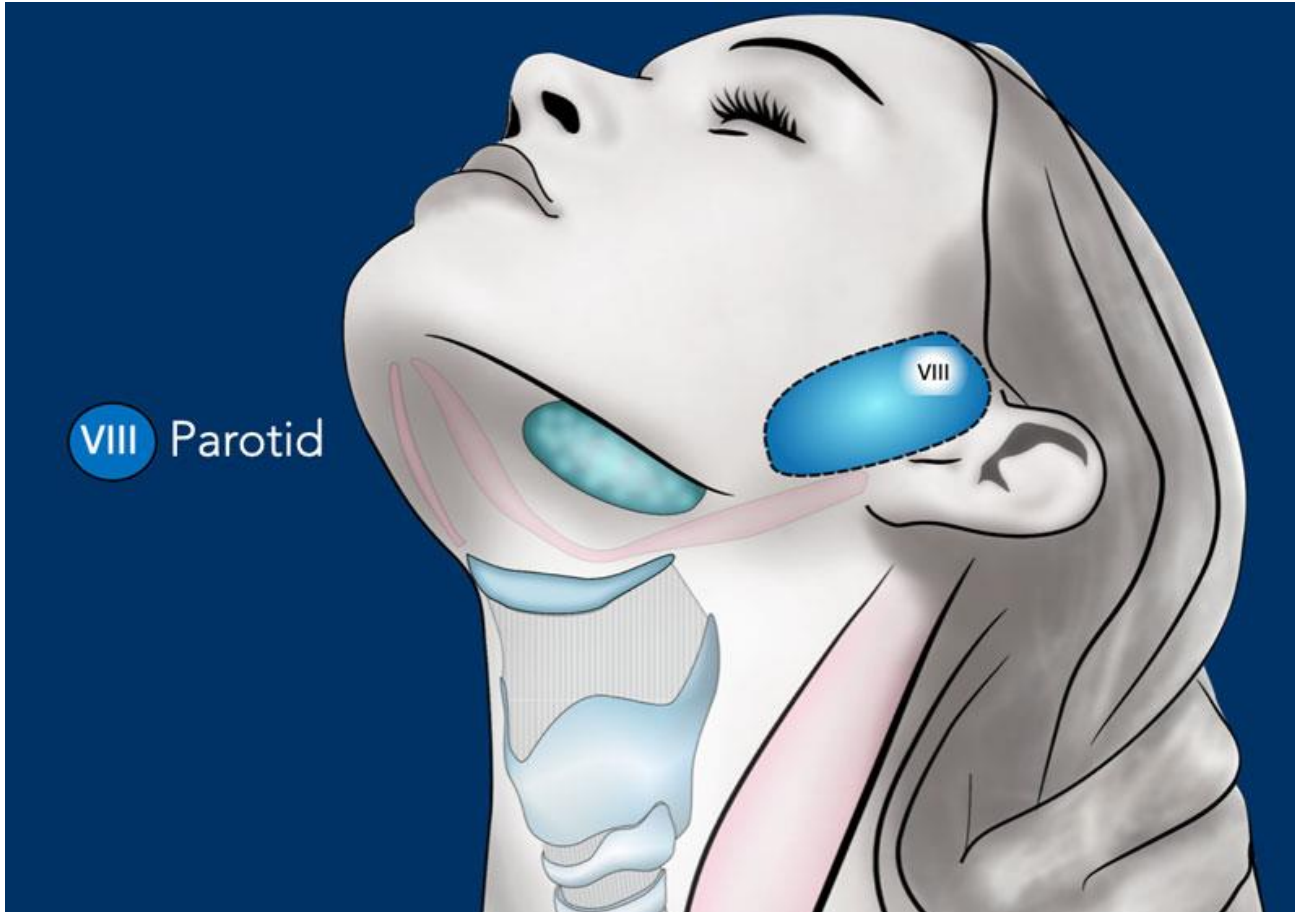
The current IG-2024 reduces the nodal CTV to the posterior edge of the infrahyoid muscles.



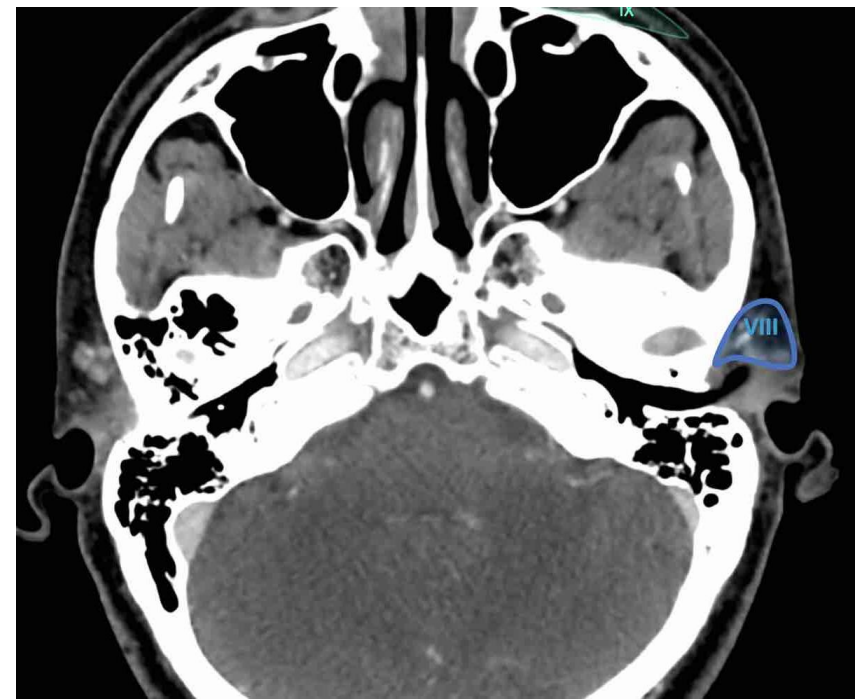
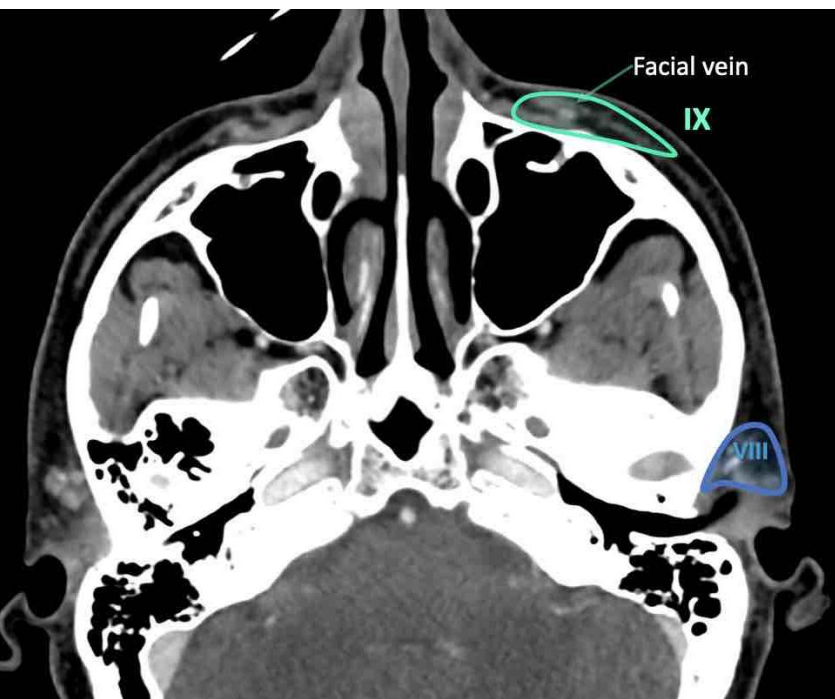
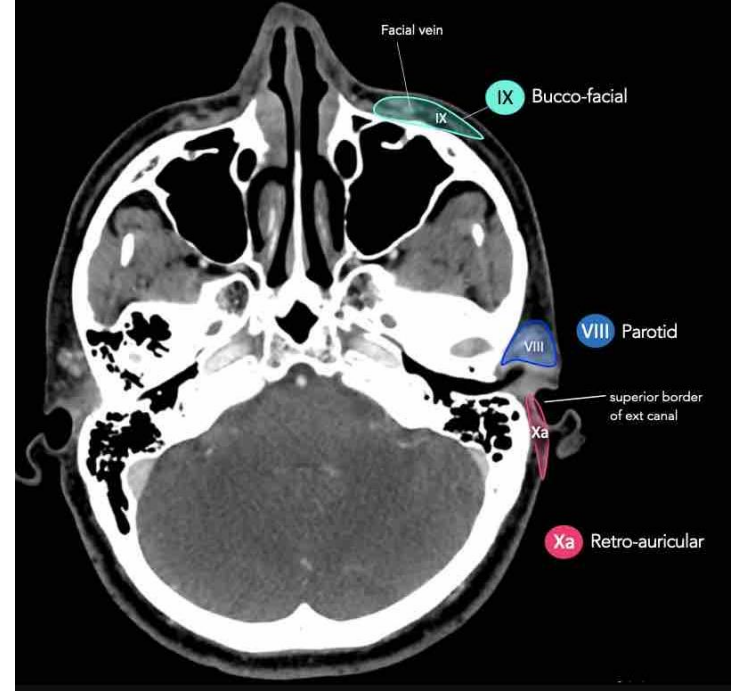
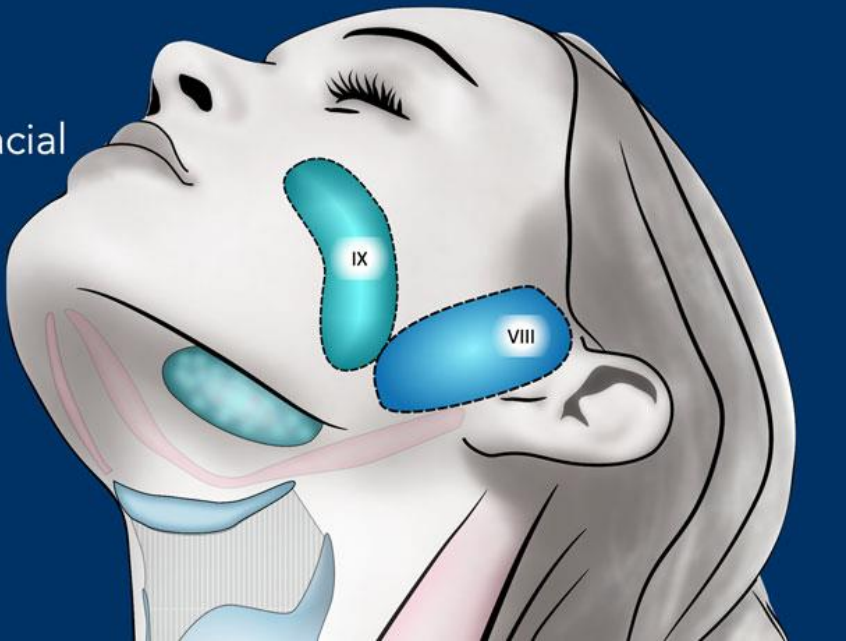


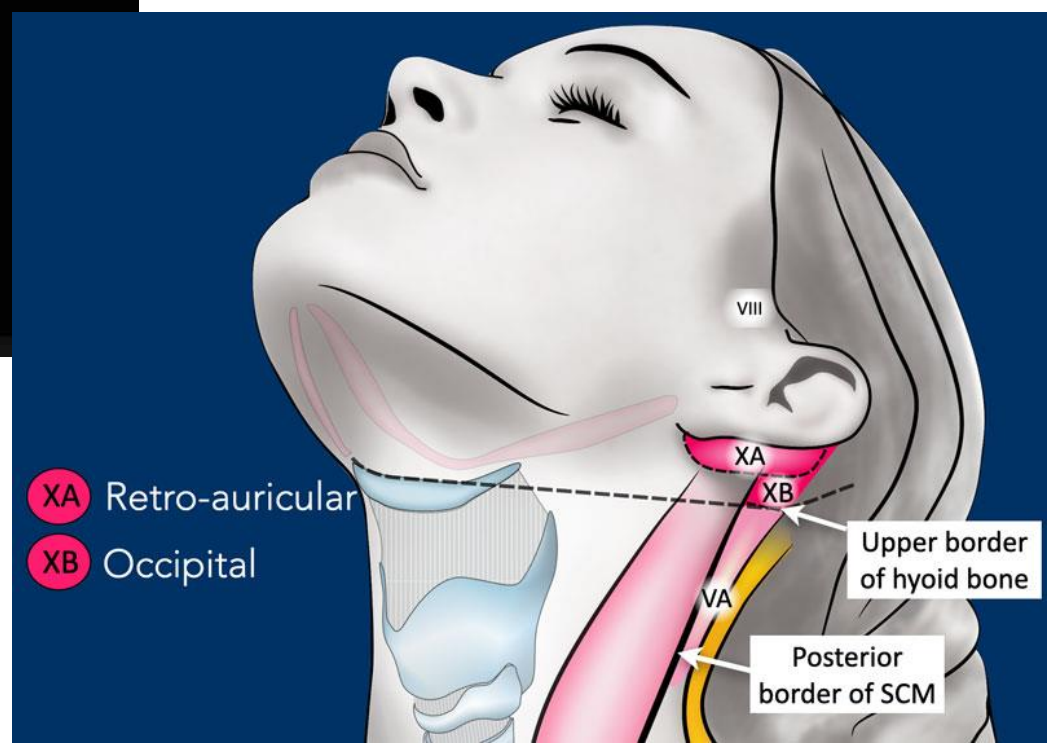
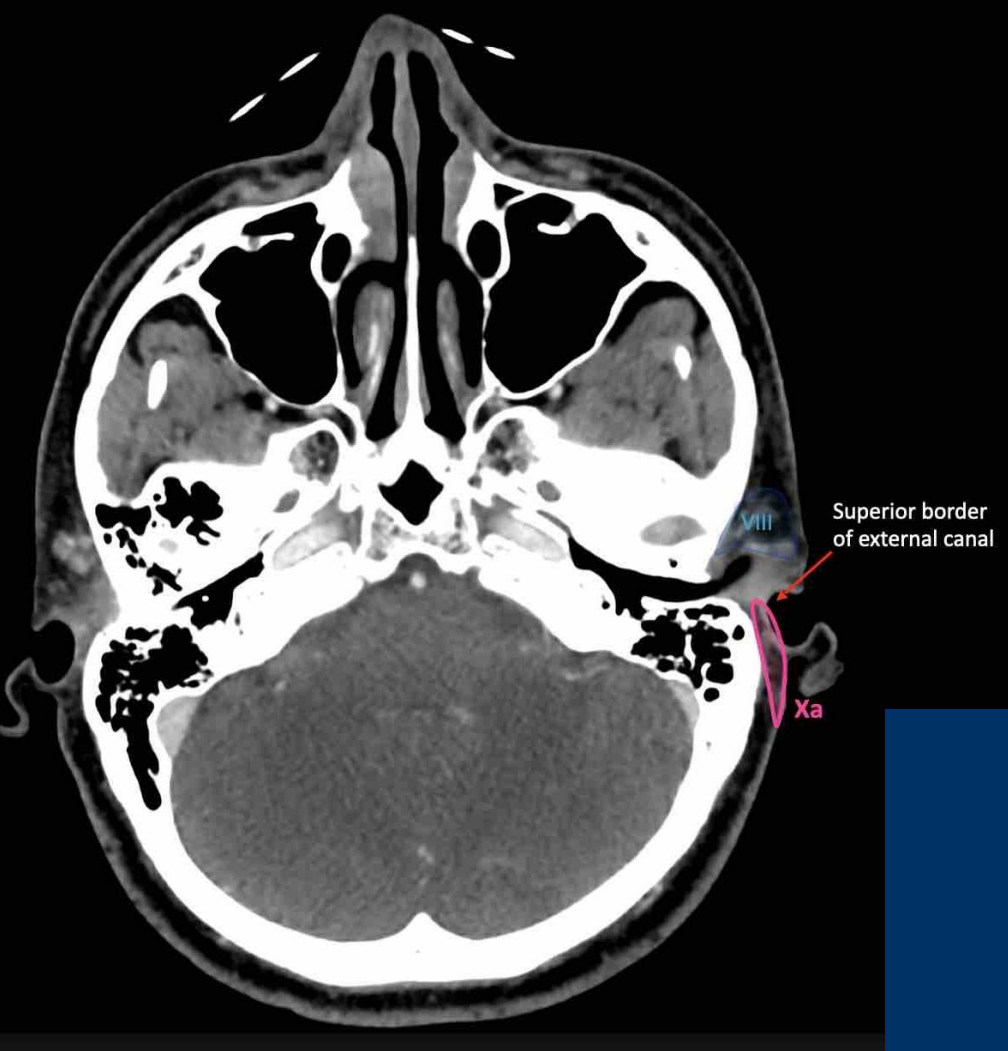






IX Bucco-facial



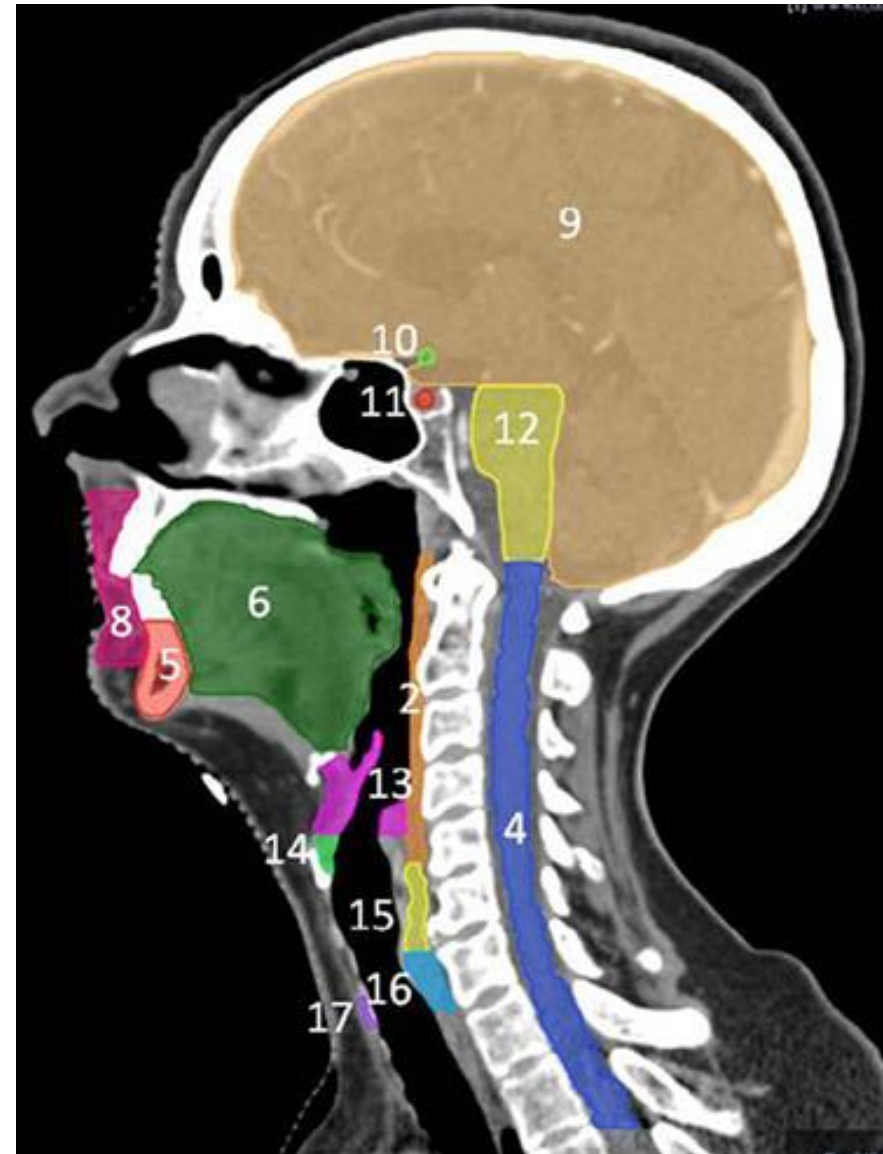
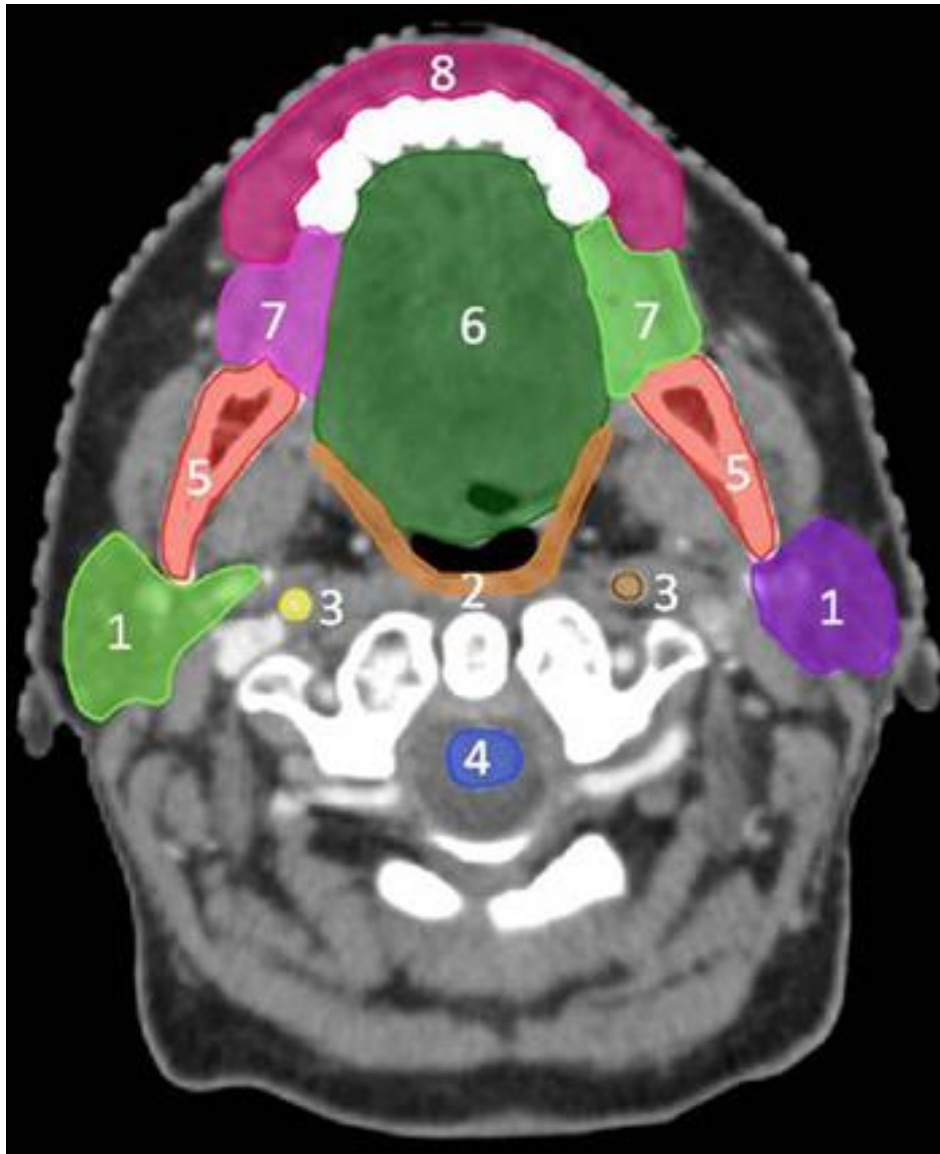


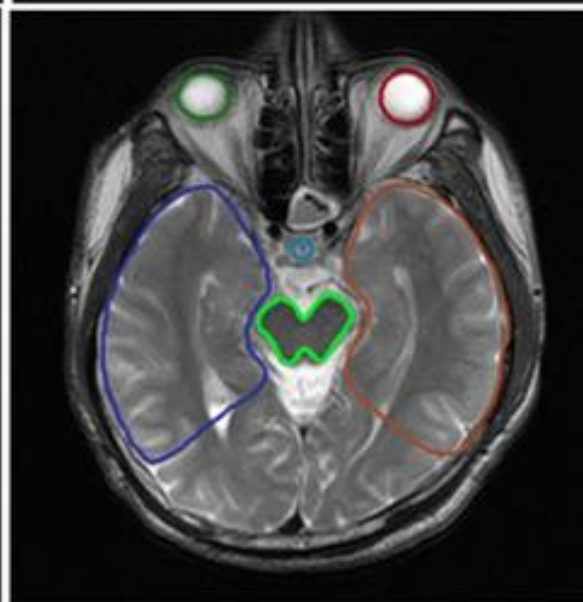
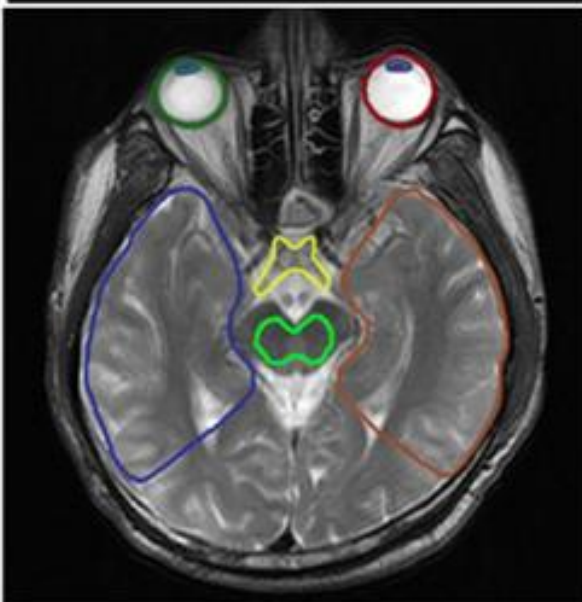
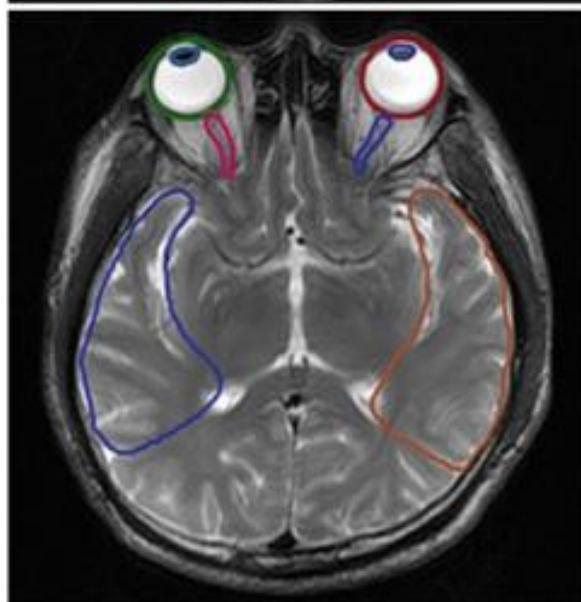
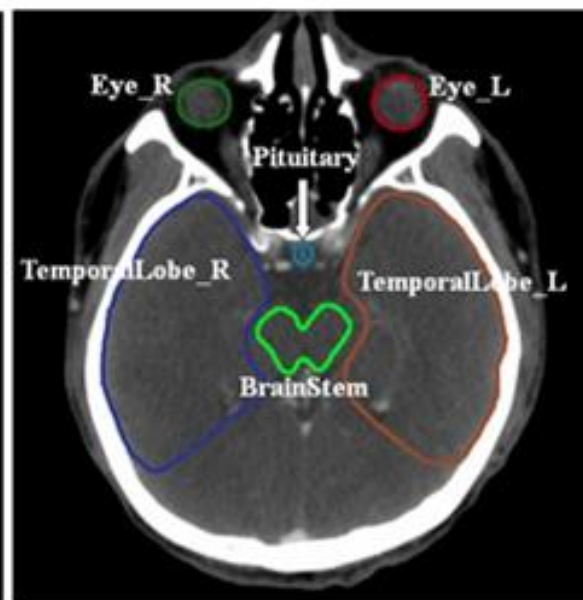
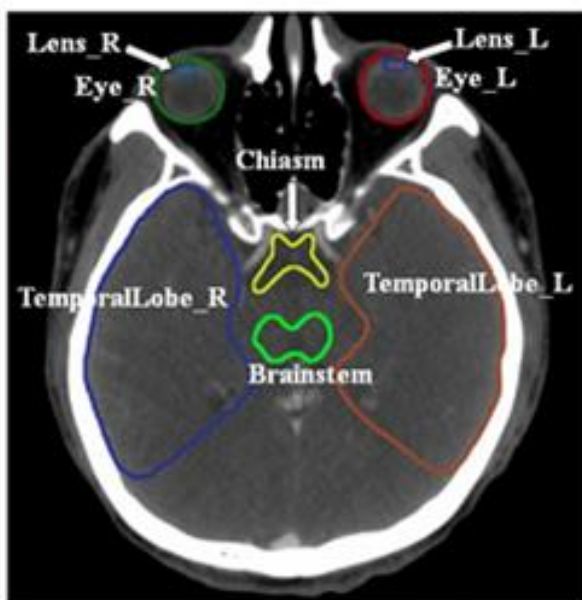
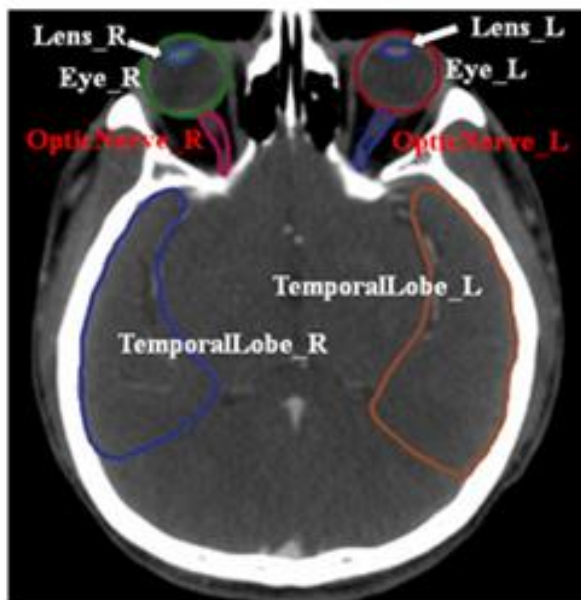
- XA Retro-auricular
- XB Occipital

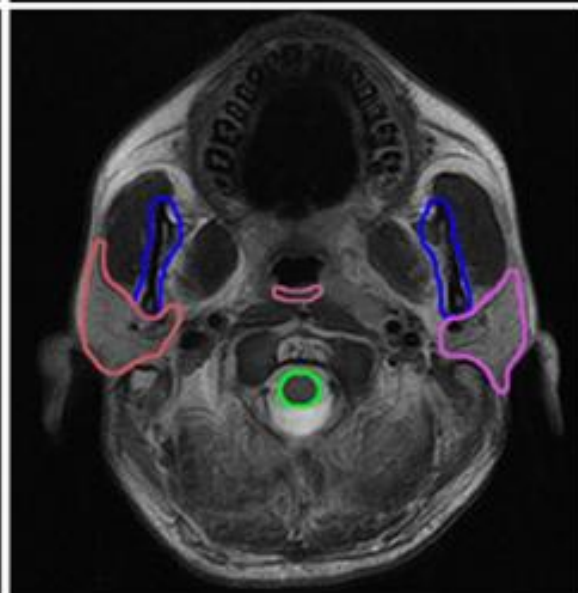
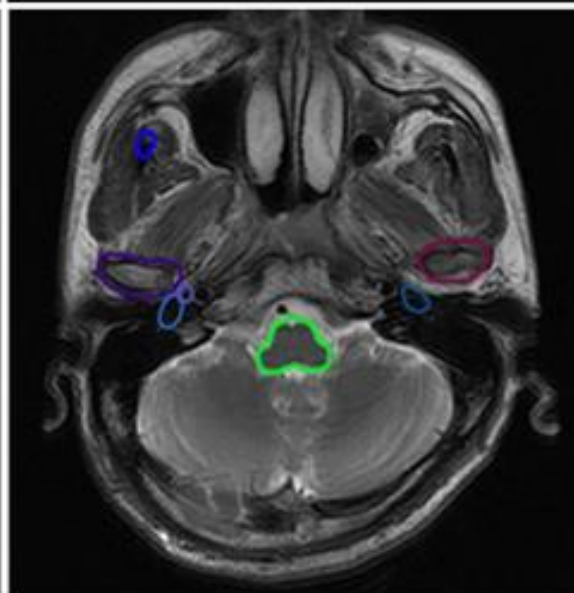
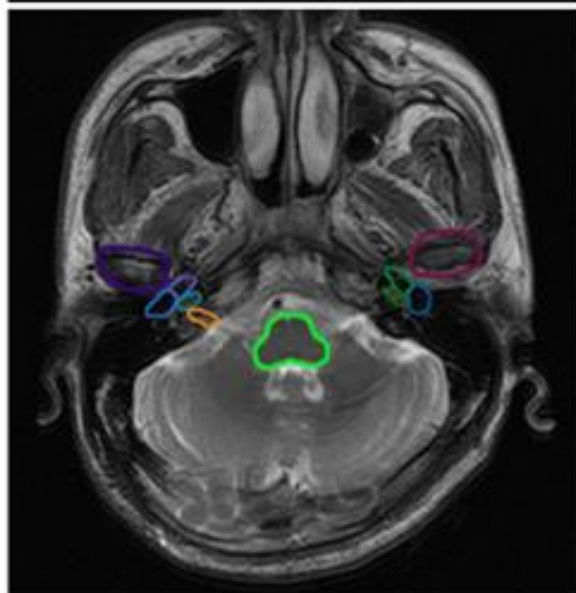
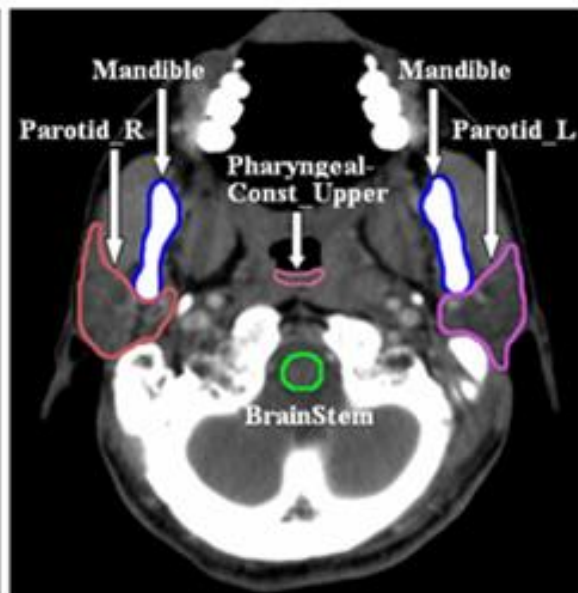
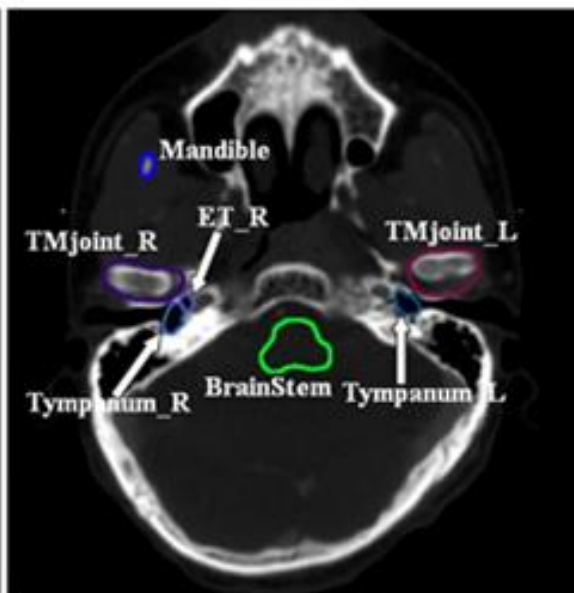
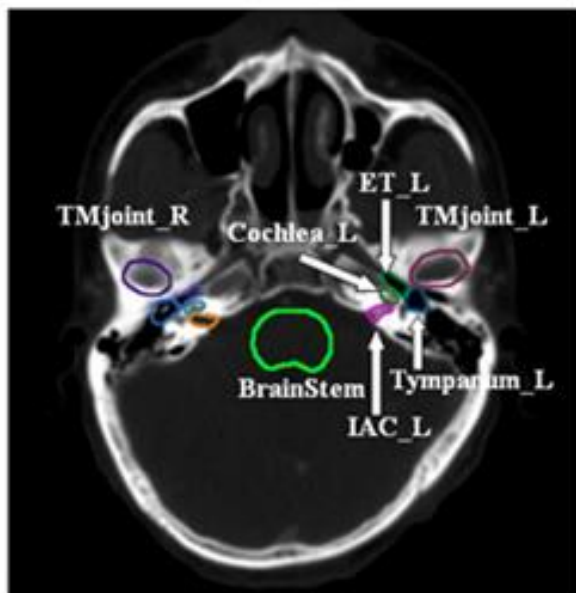
PTV (institutional)

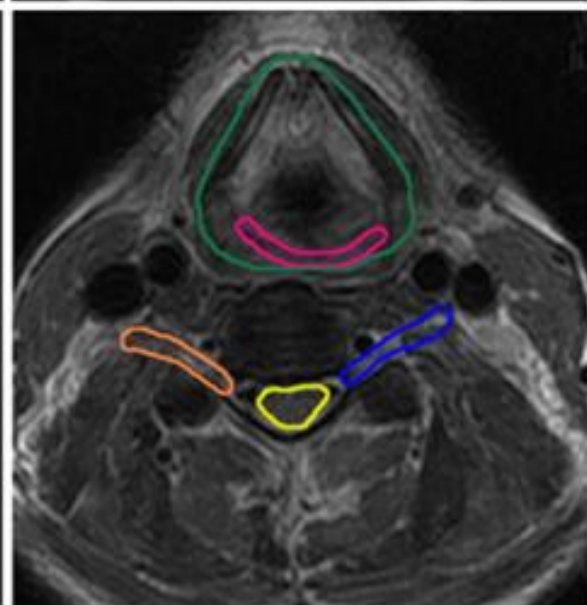
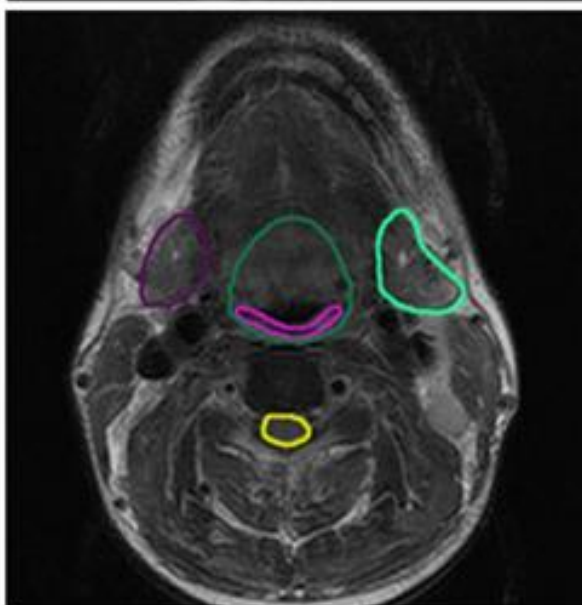
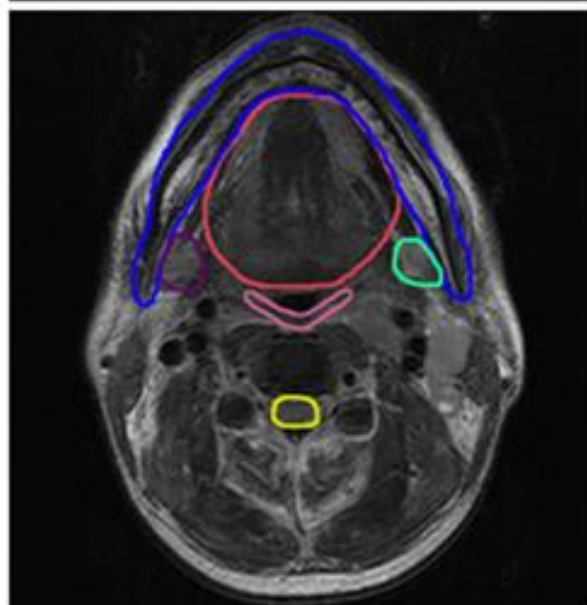
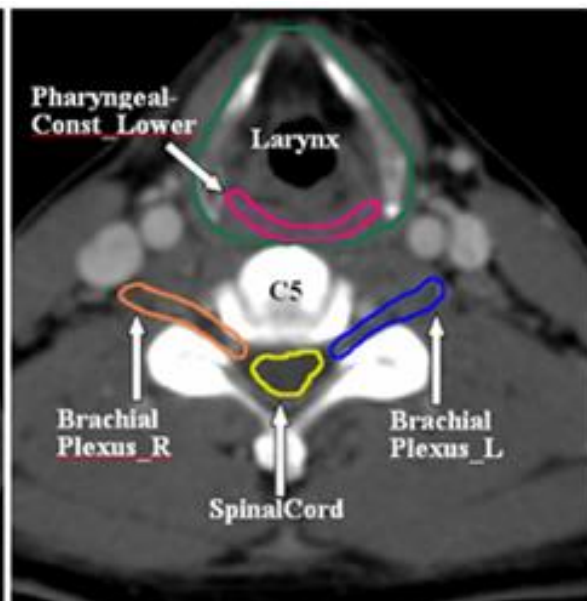
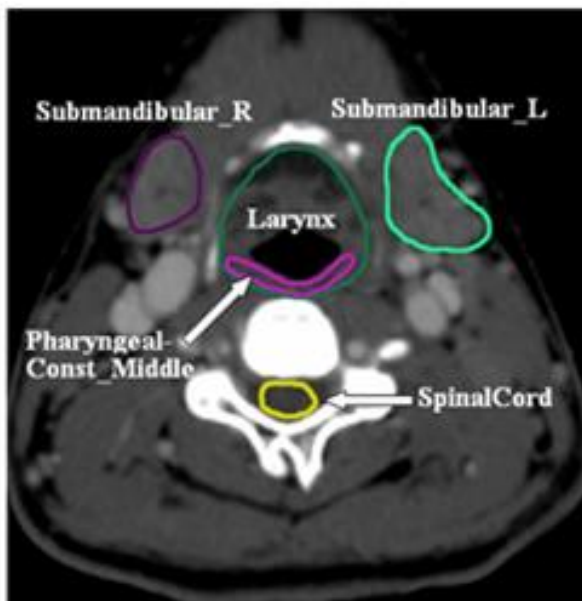
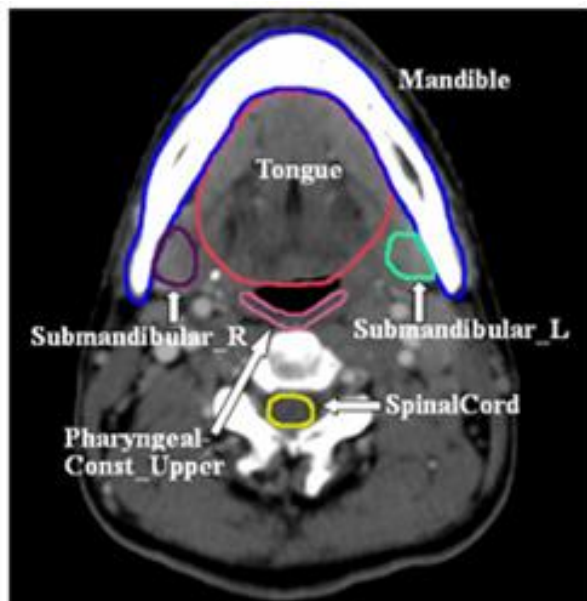
- Each CTV is grown to create a PTV.
- By recording and analyzing **systematic and random errors**, PTV margins for each center can be defined.
- Usually **3-5 mm**.

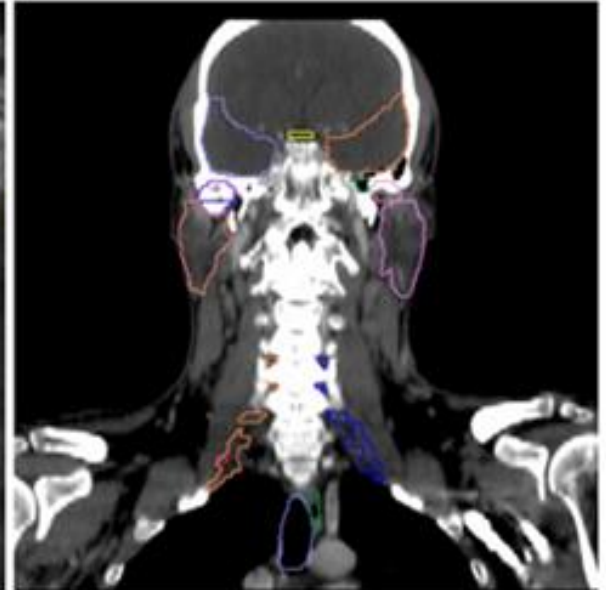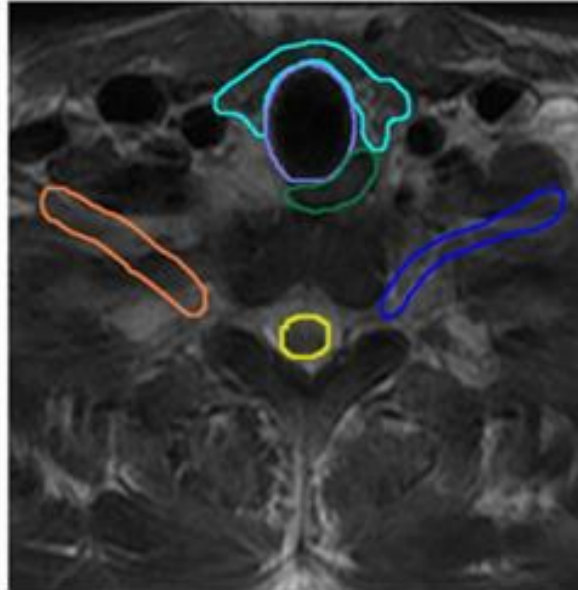
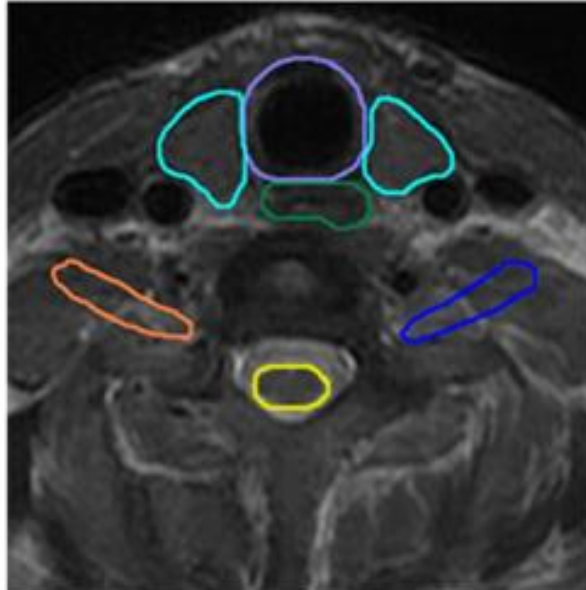
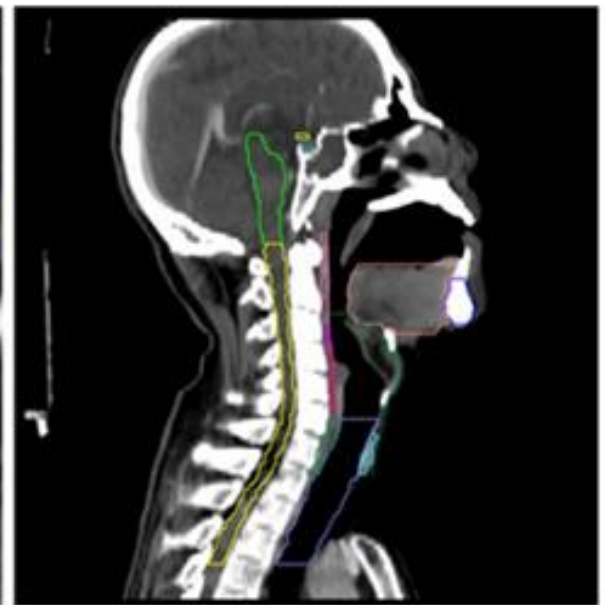
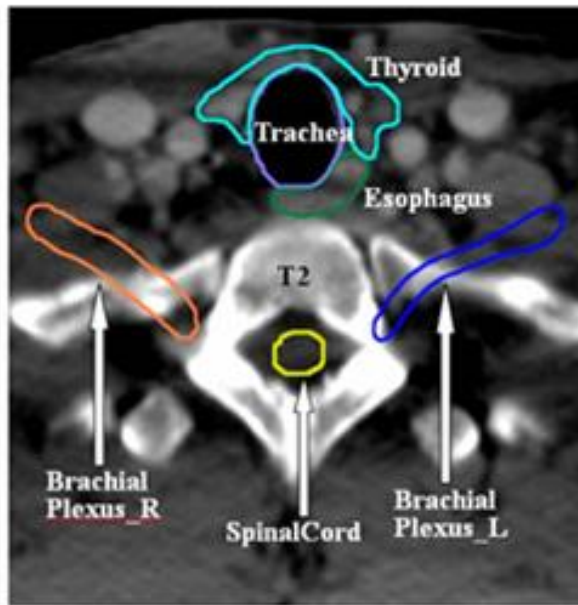
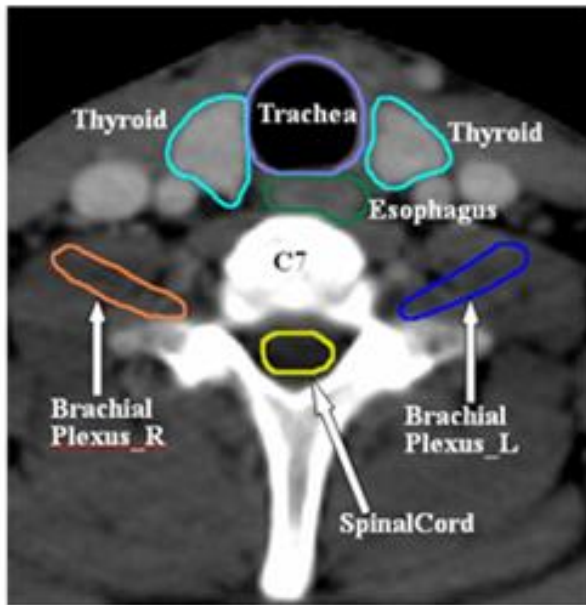
OARs

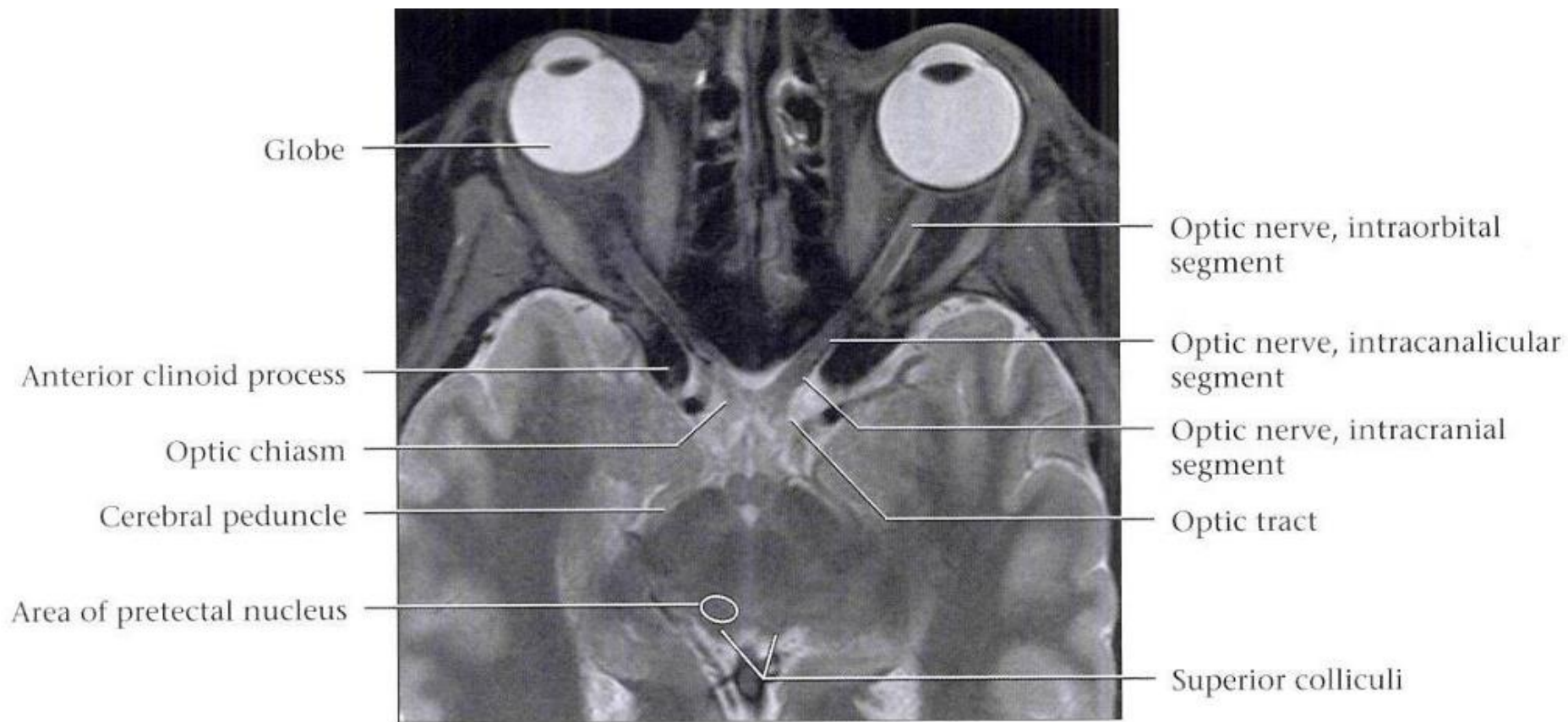


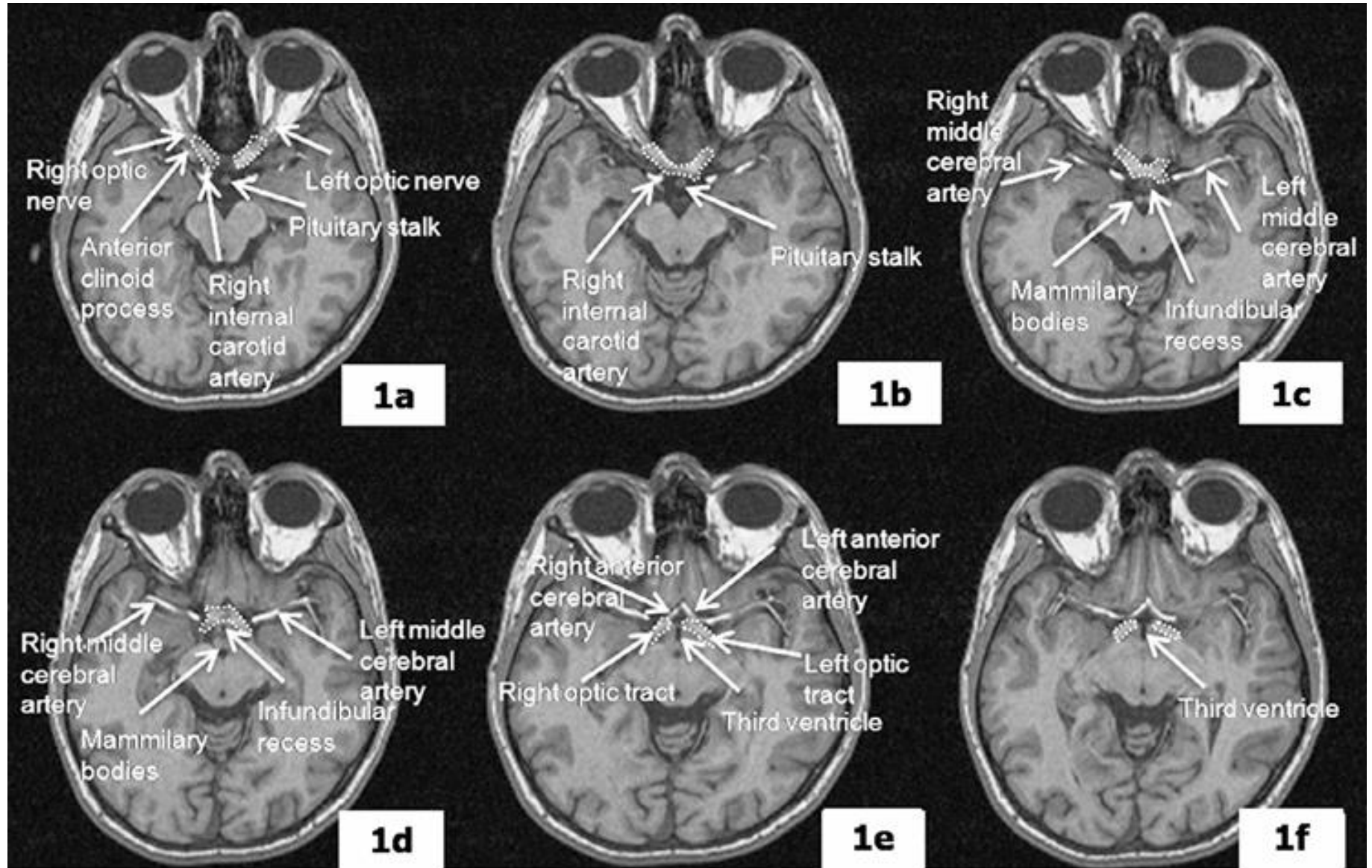


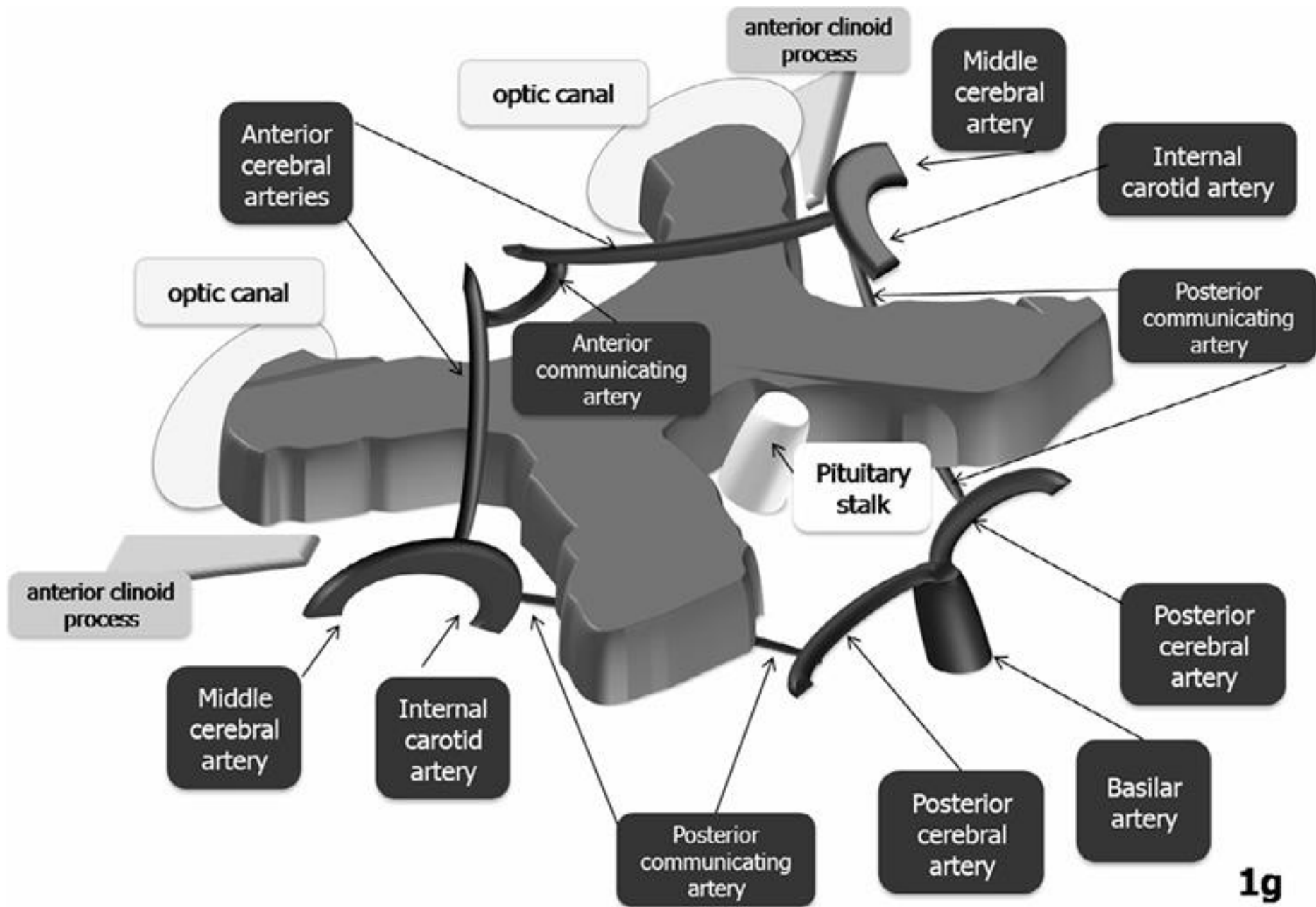


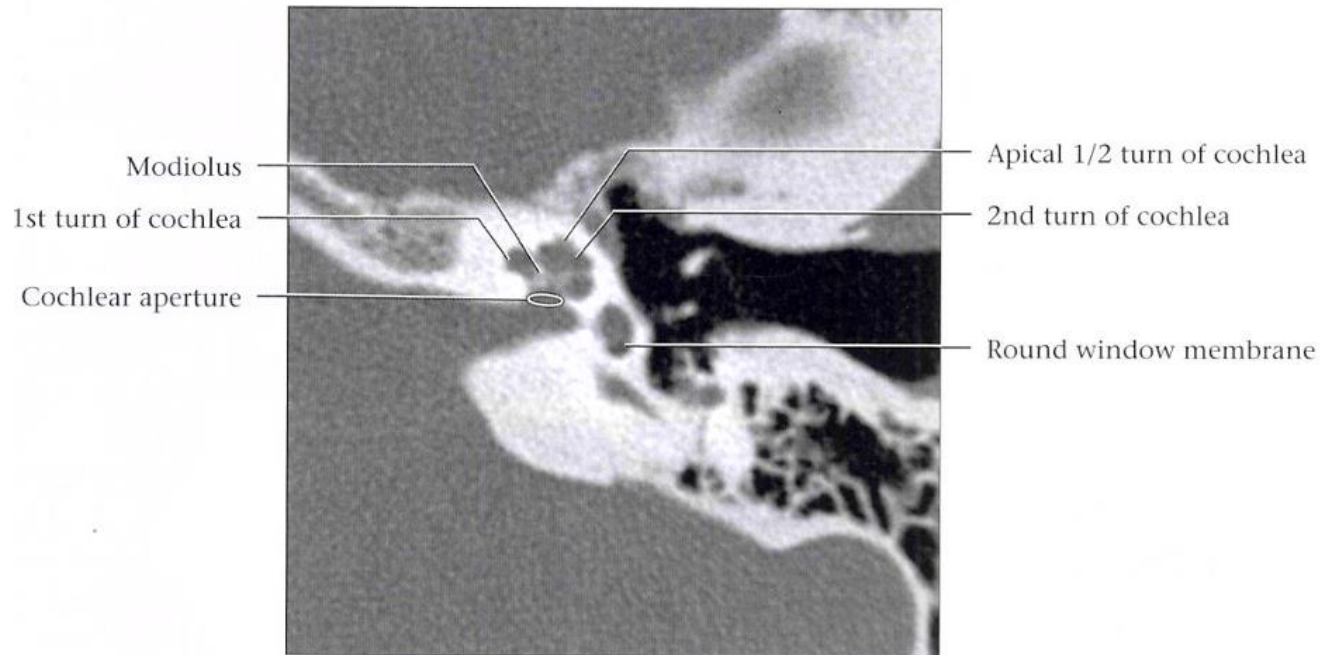
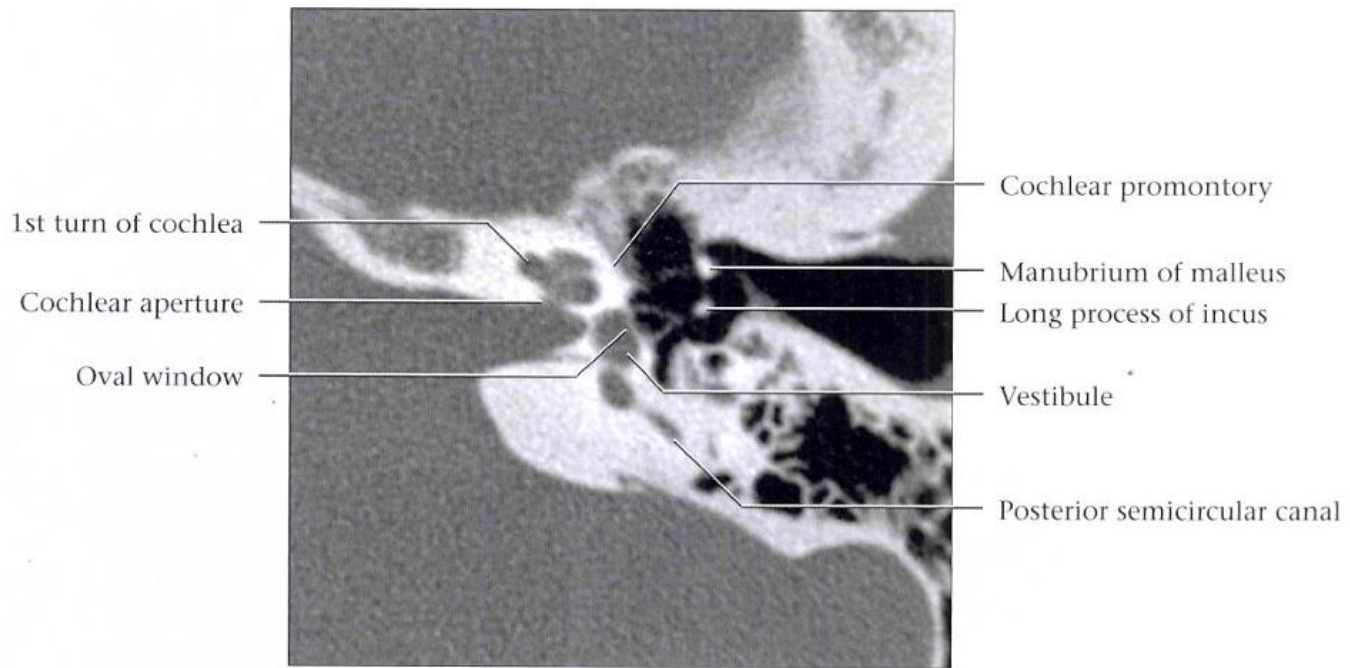


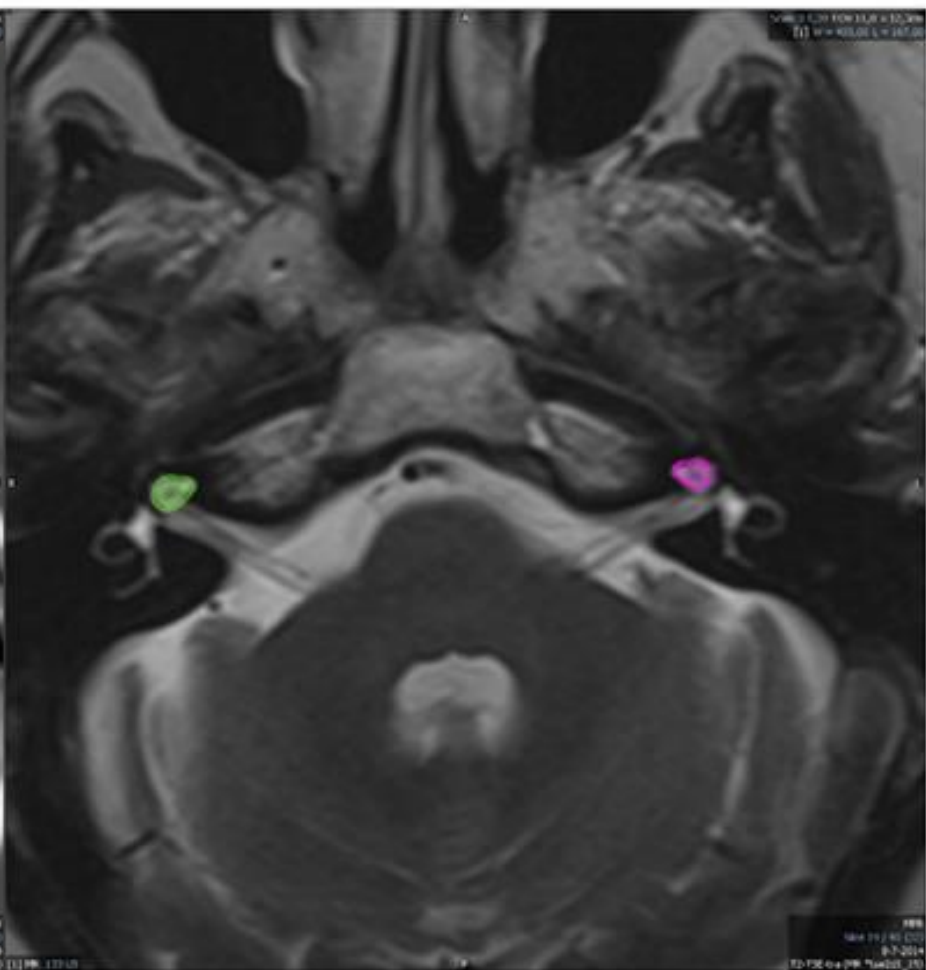
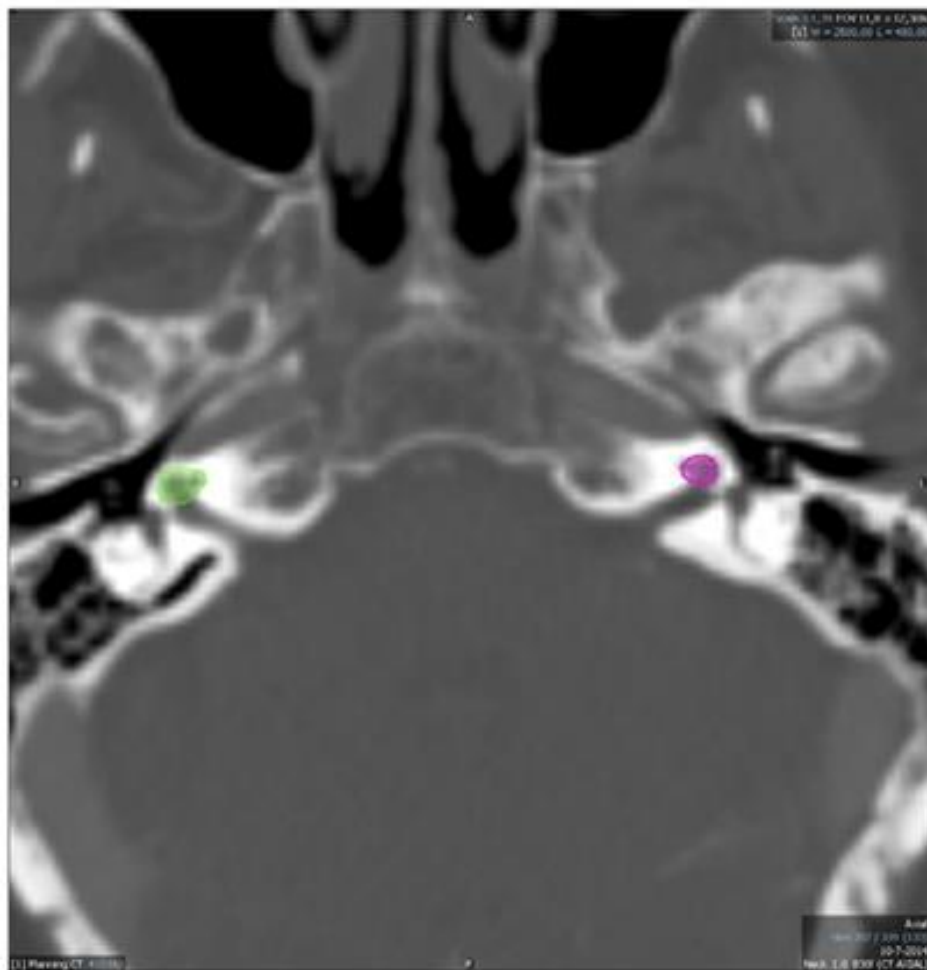


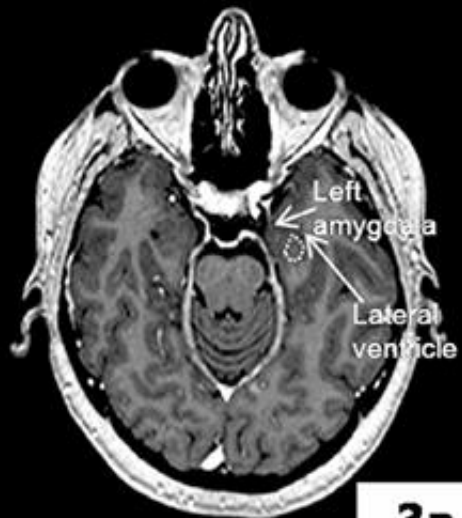




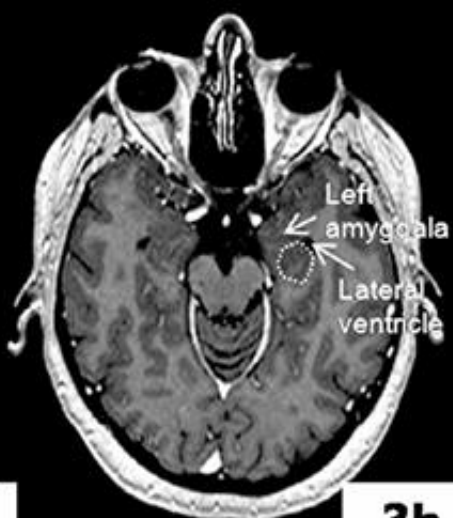


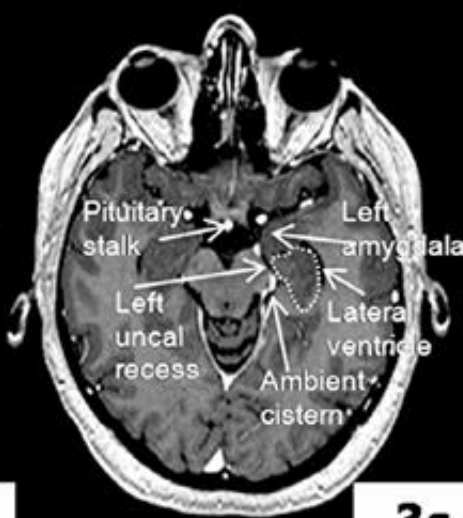




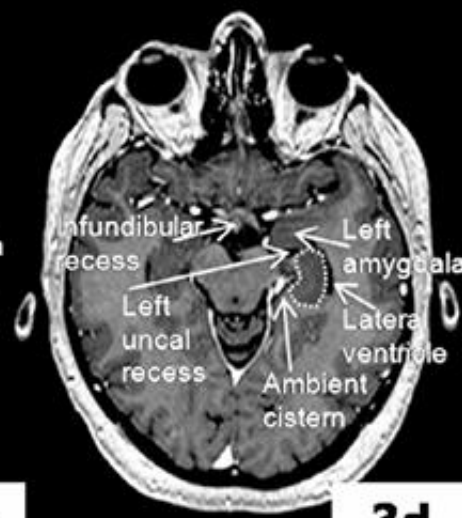
3a



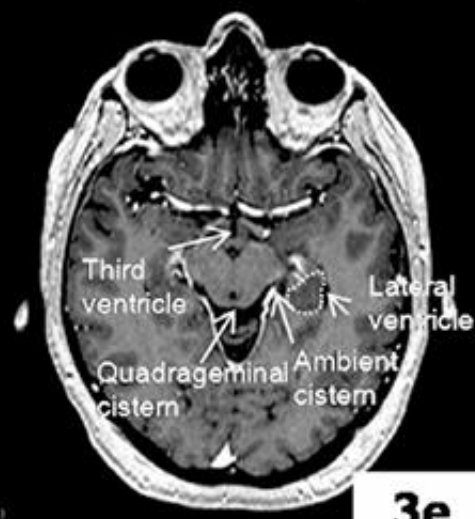3b



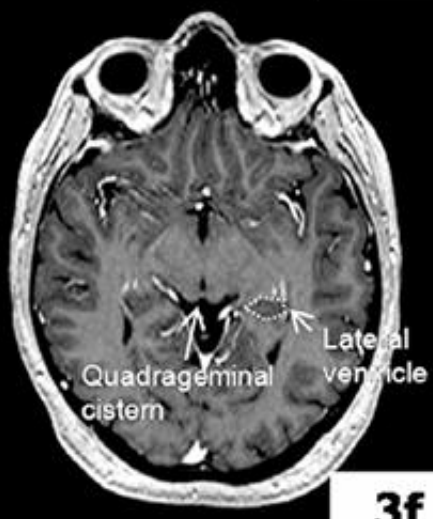
3c



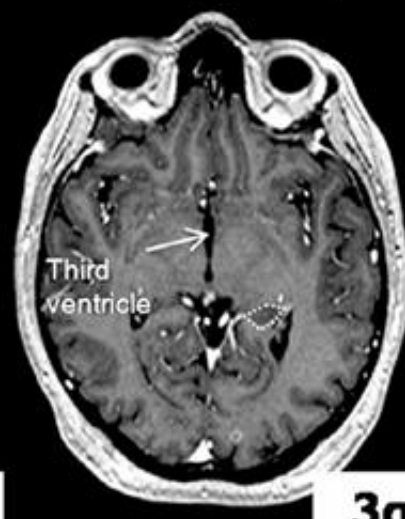
3d



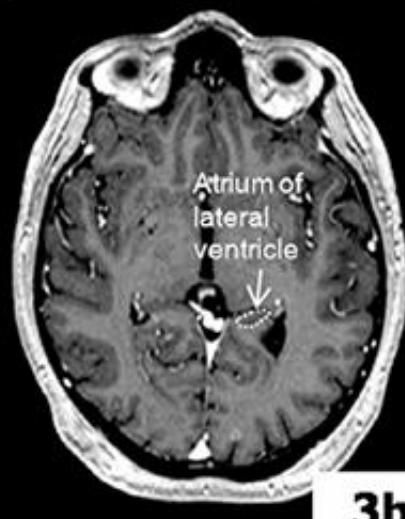3e



3f

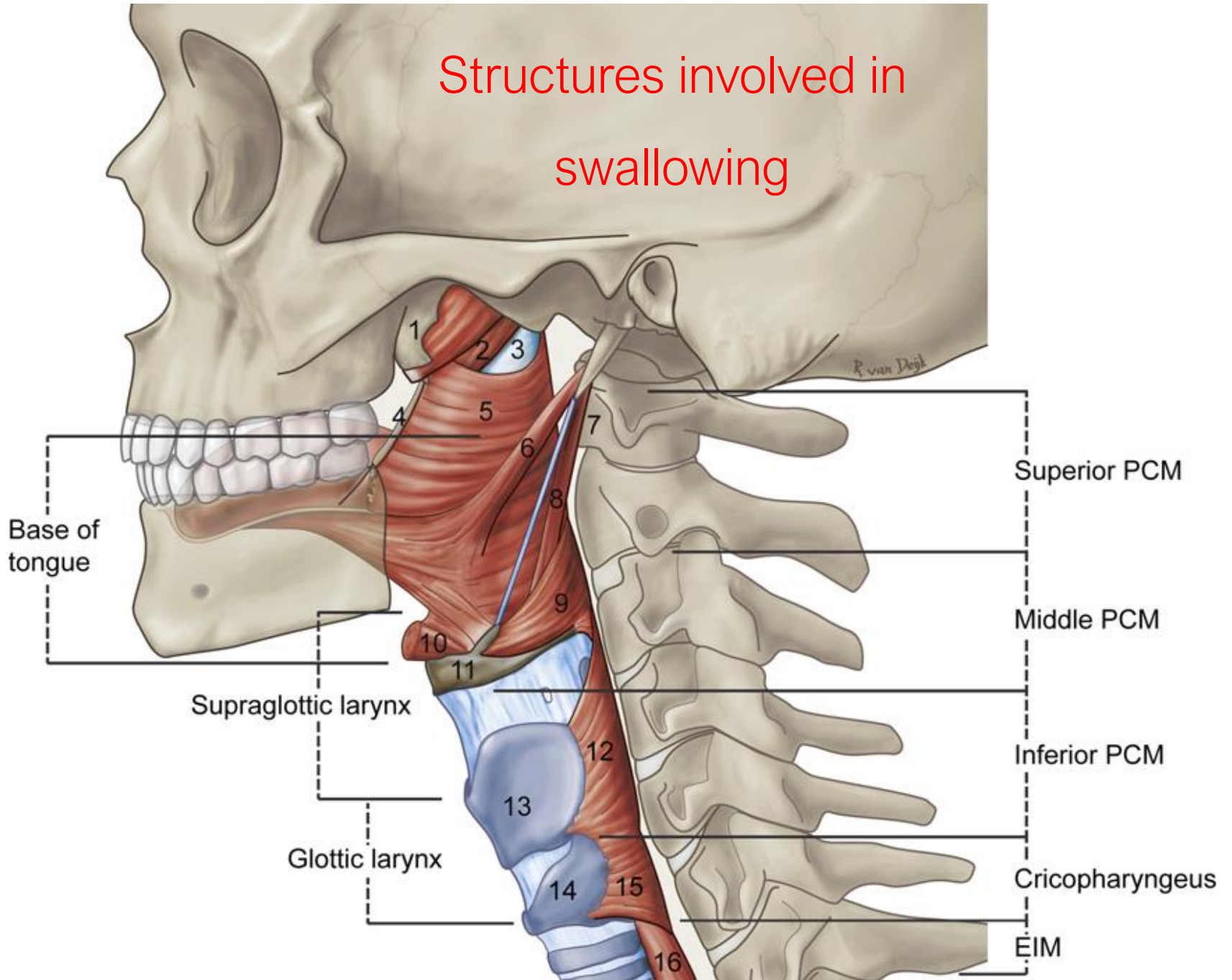


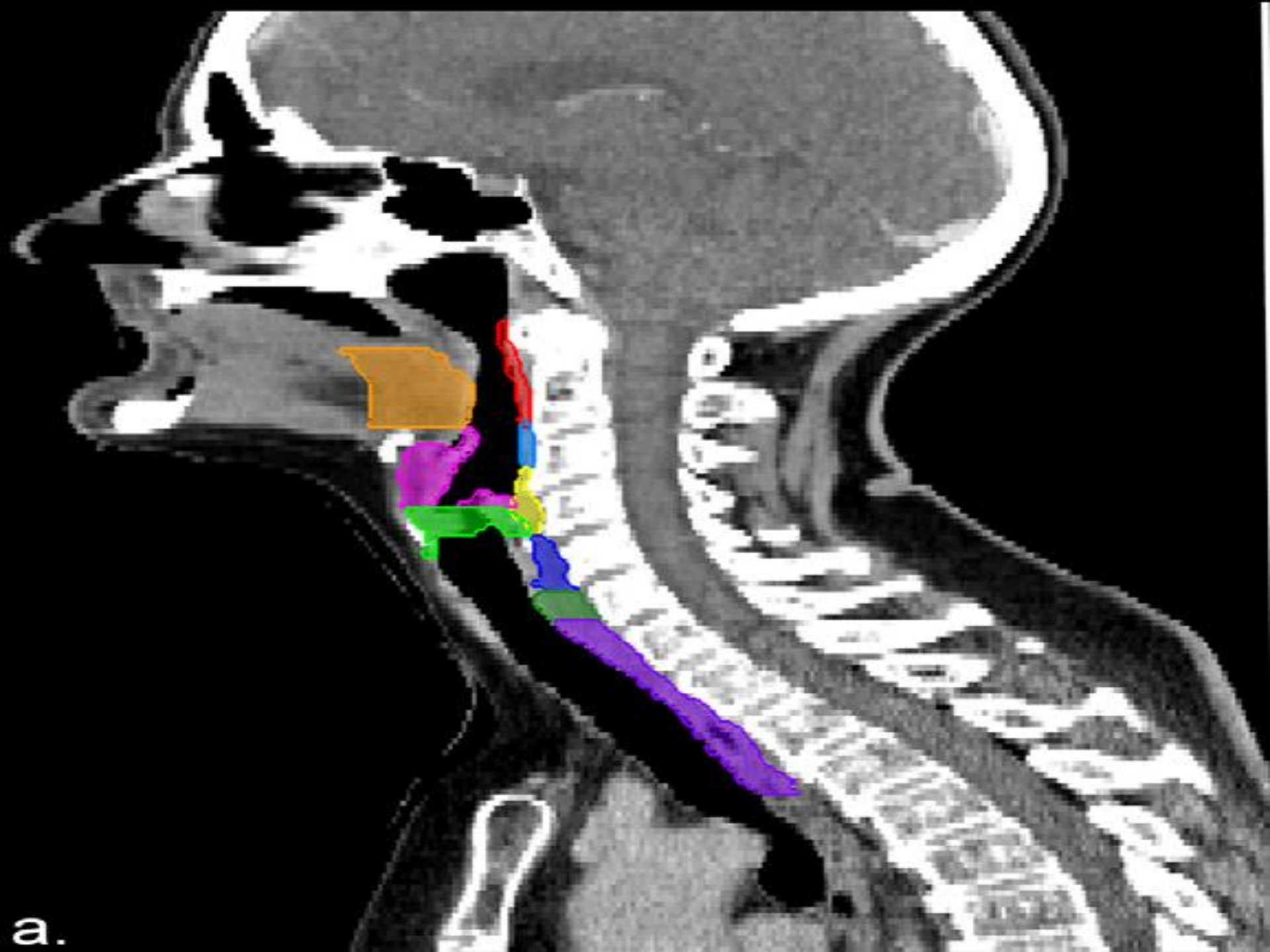
3g



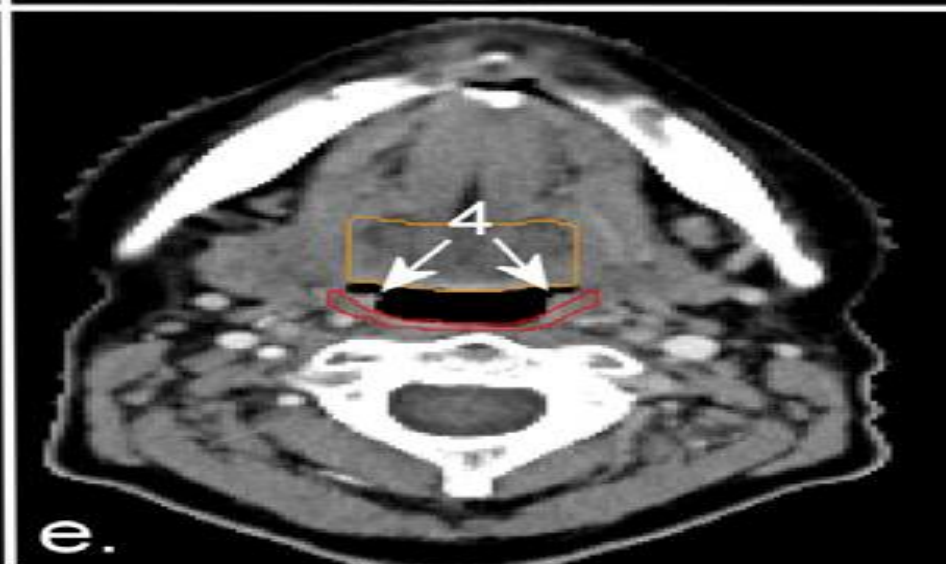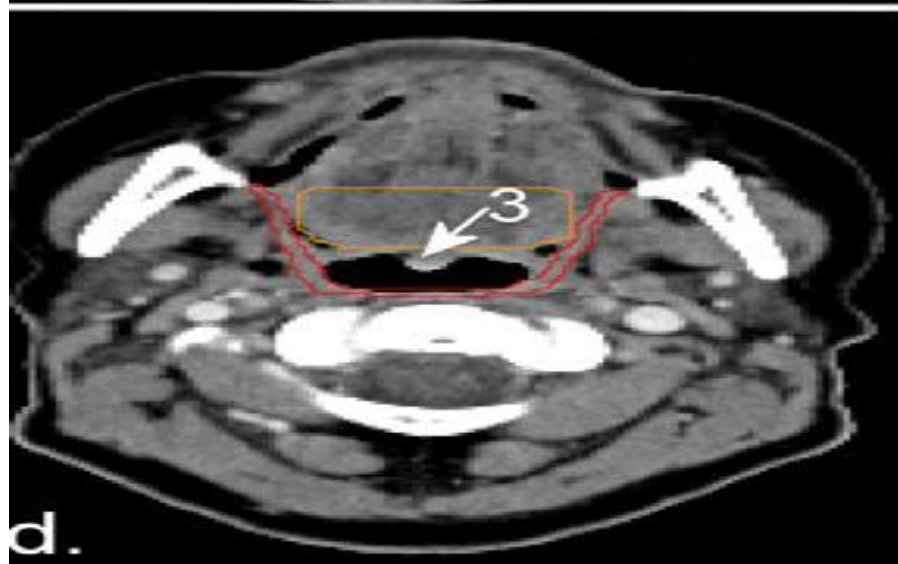
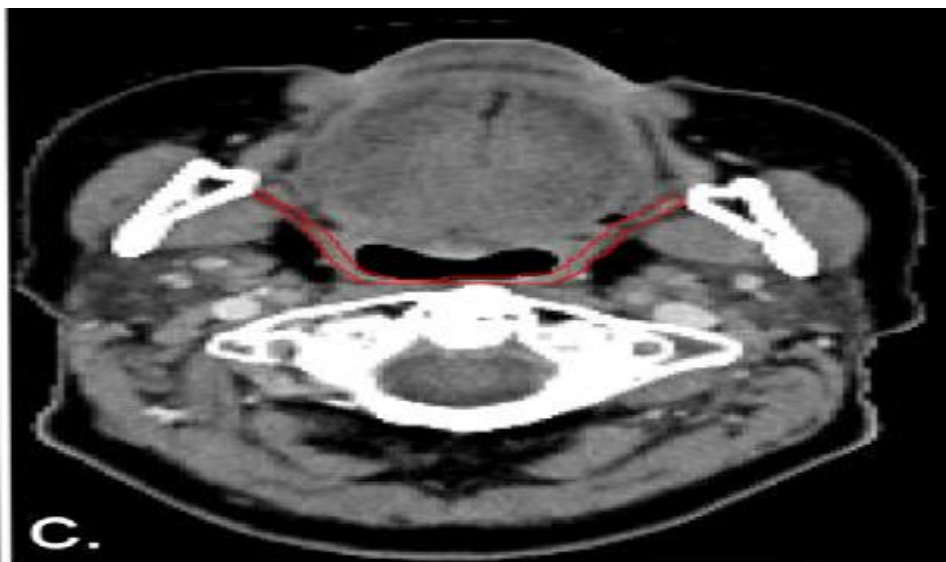
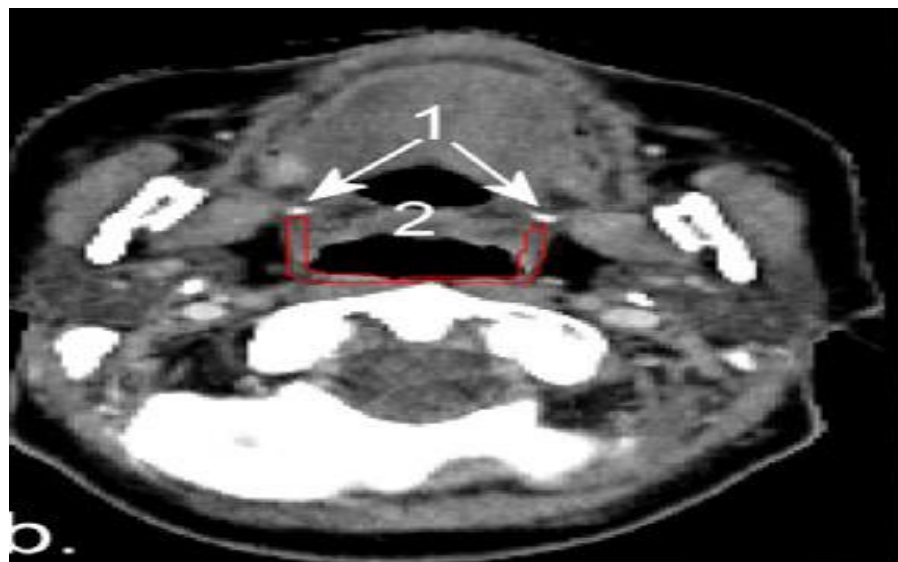
3h

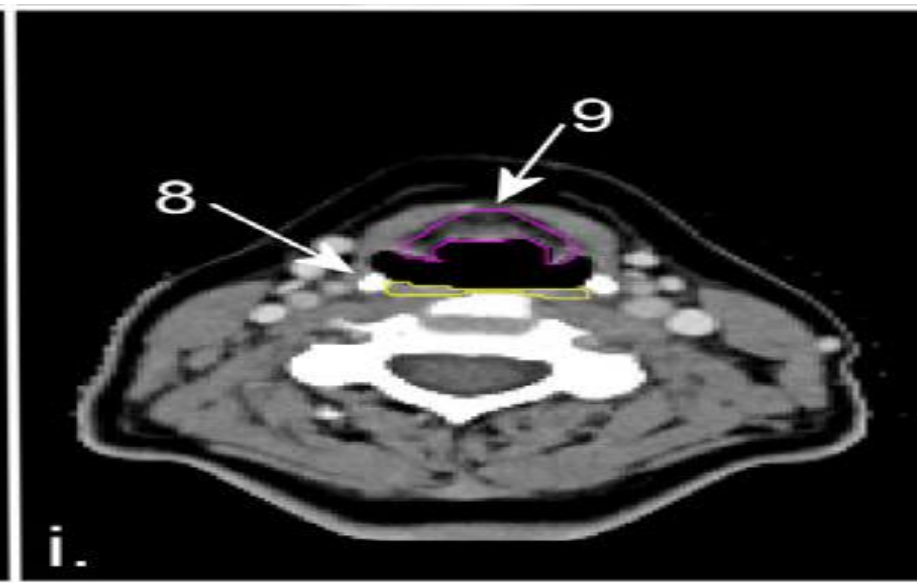
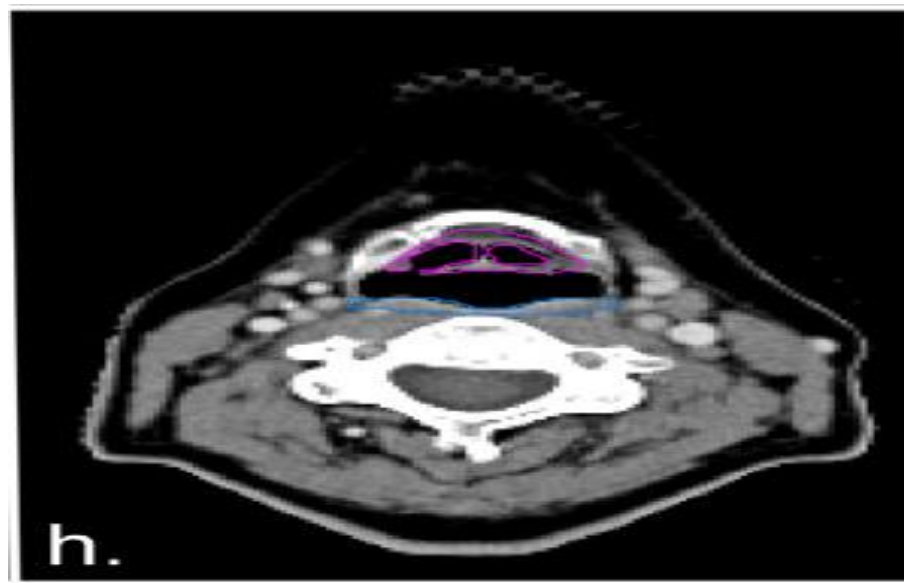
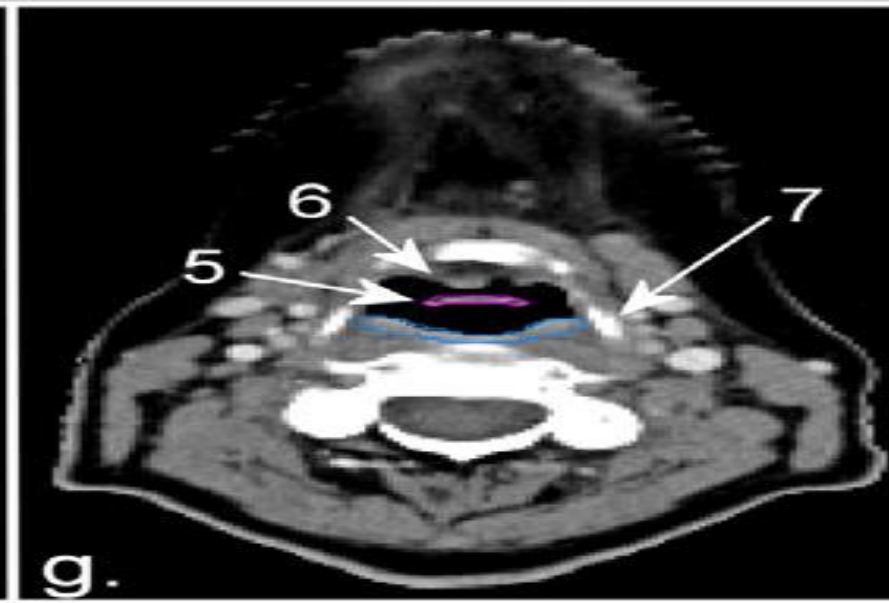
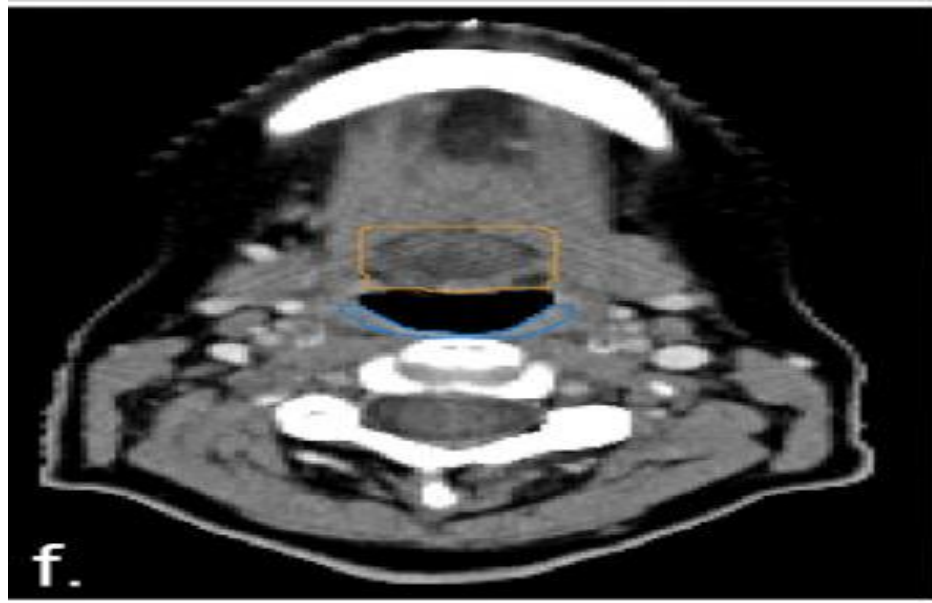Structures involved in swallowing

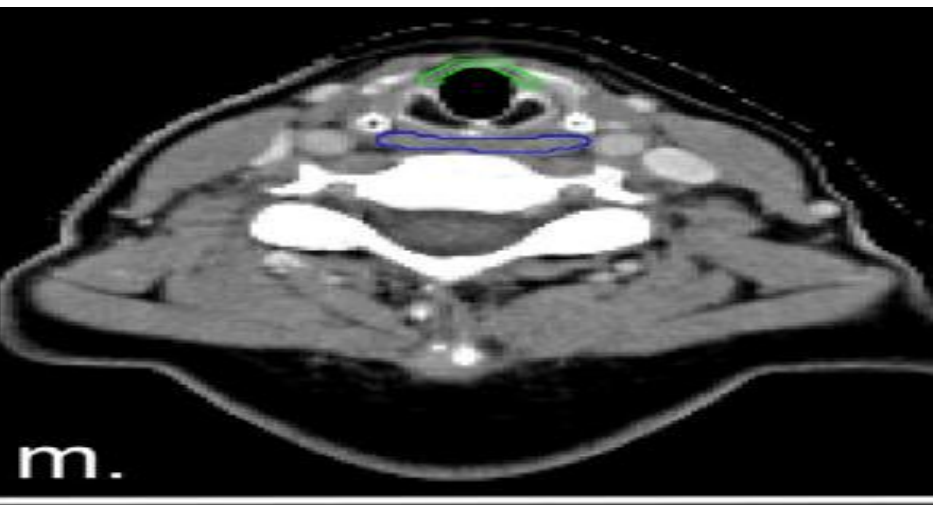
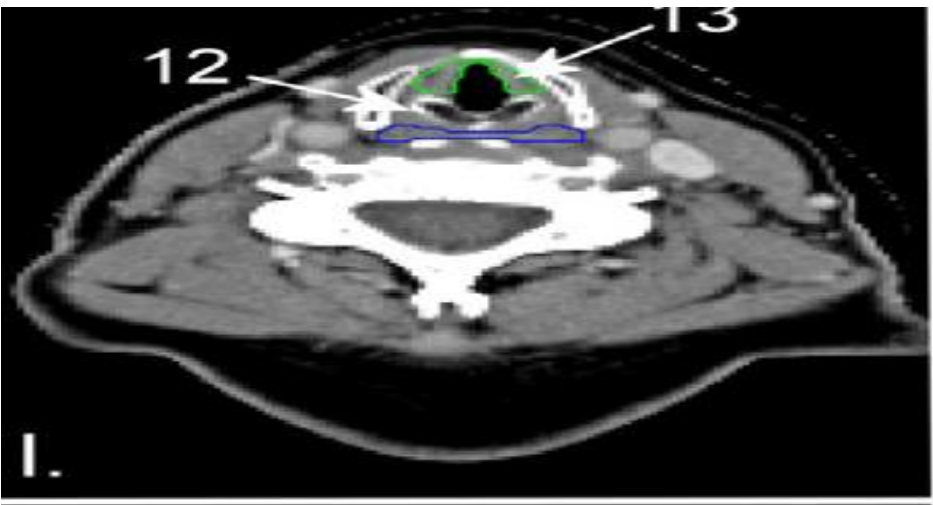
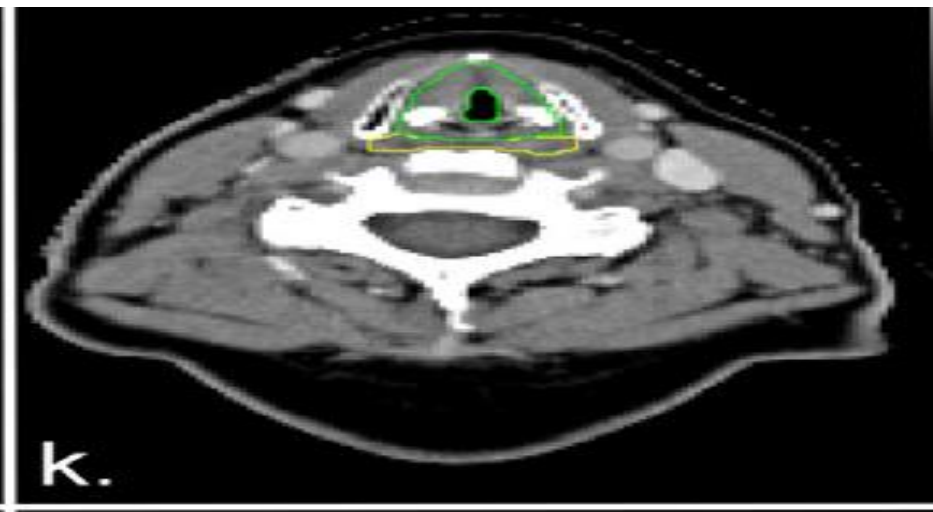
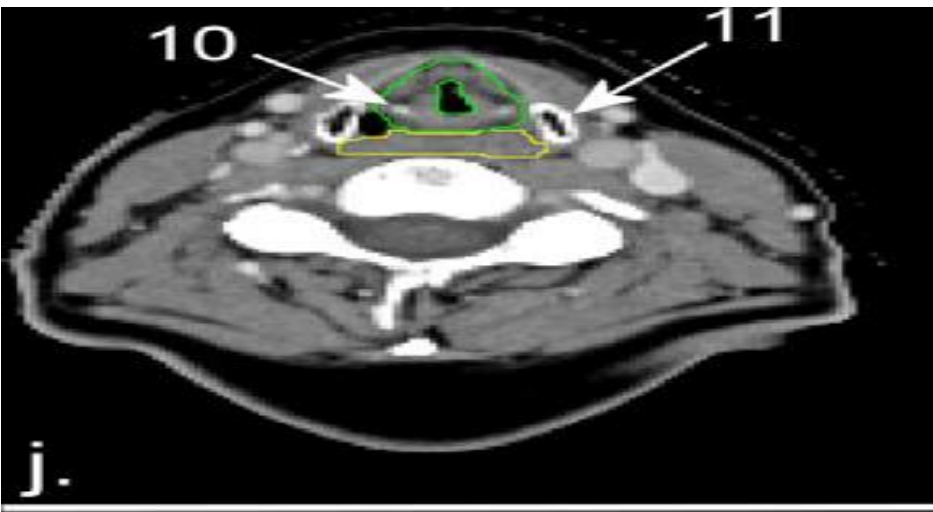


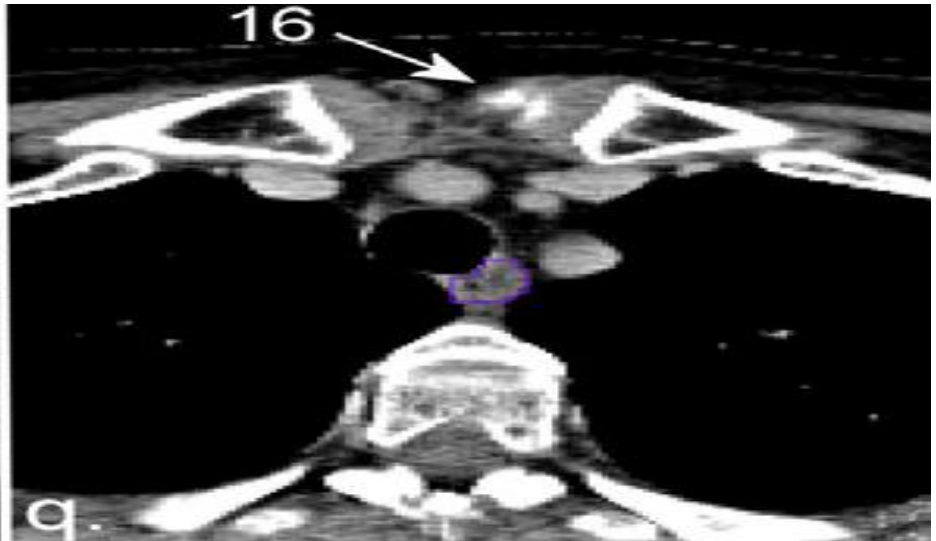
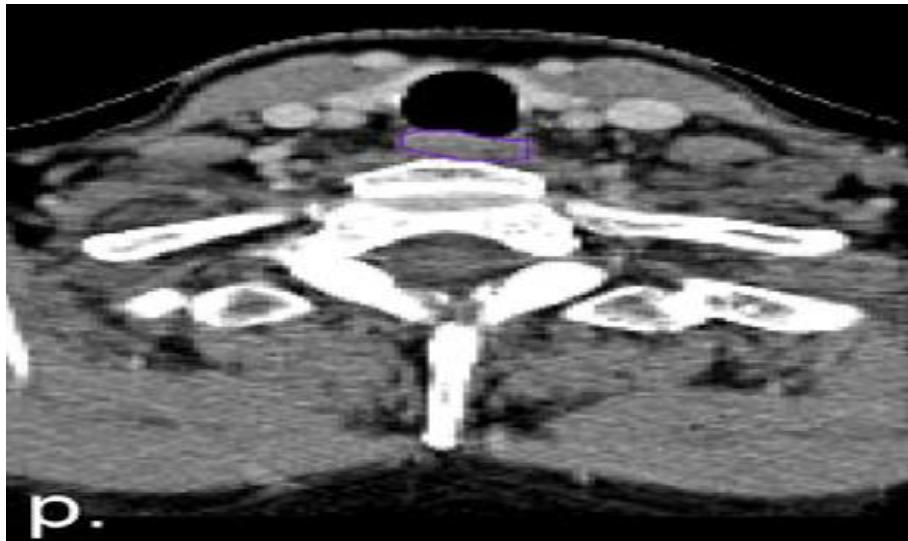
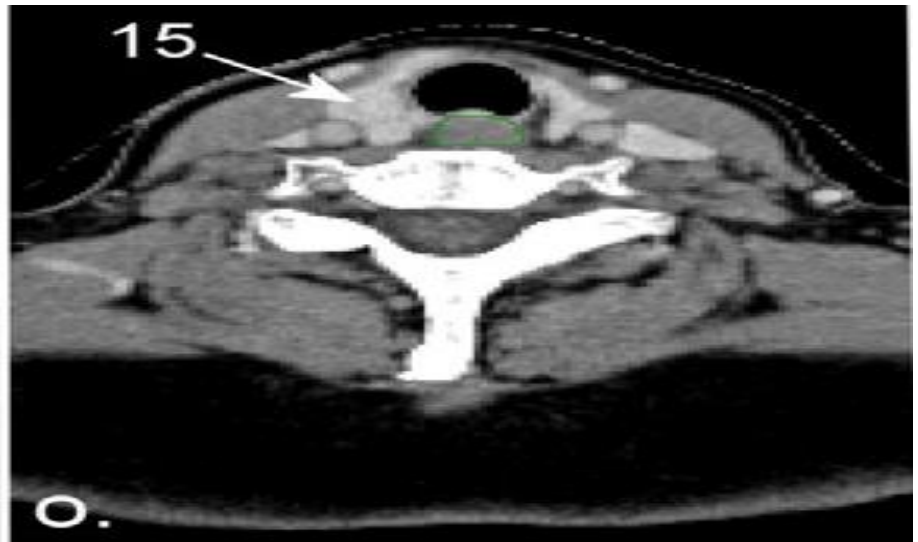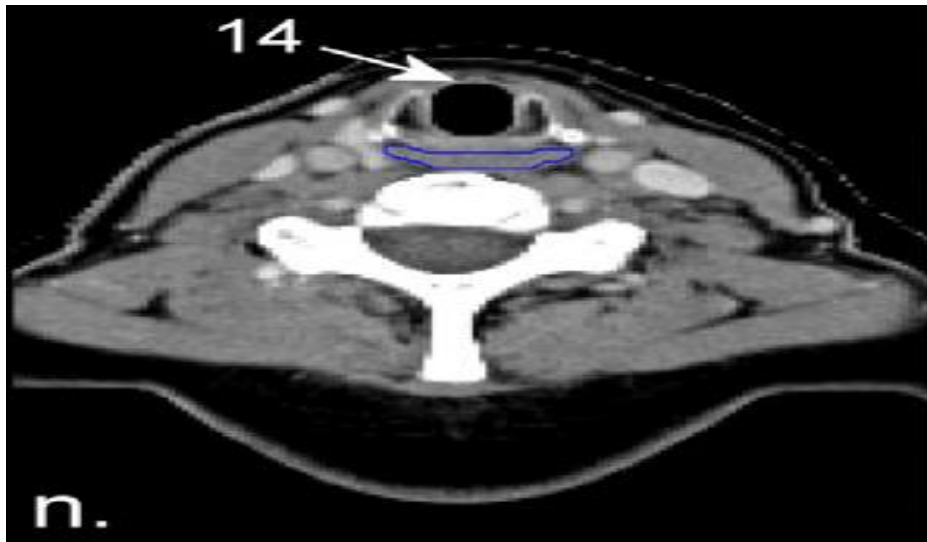


a.



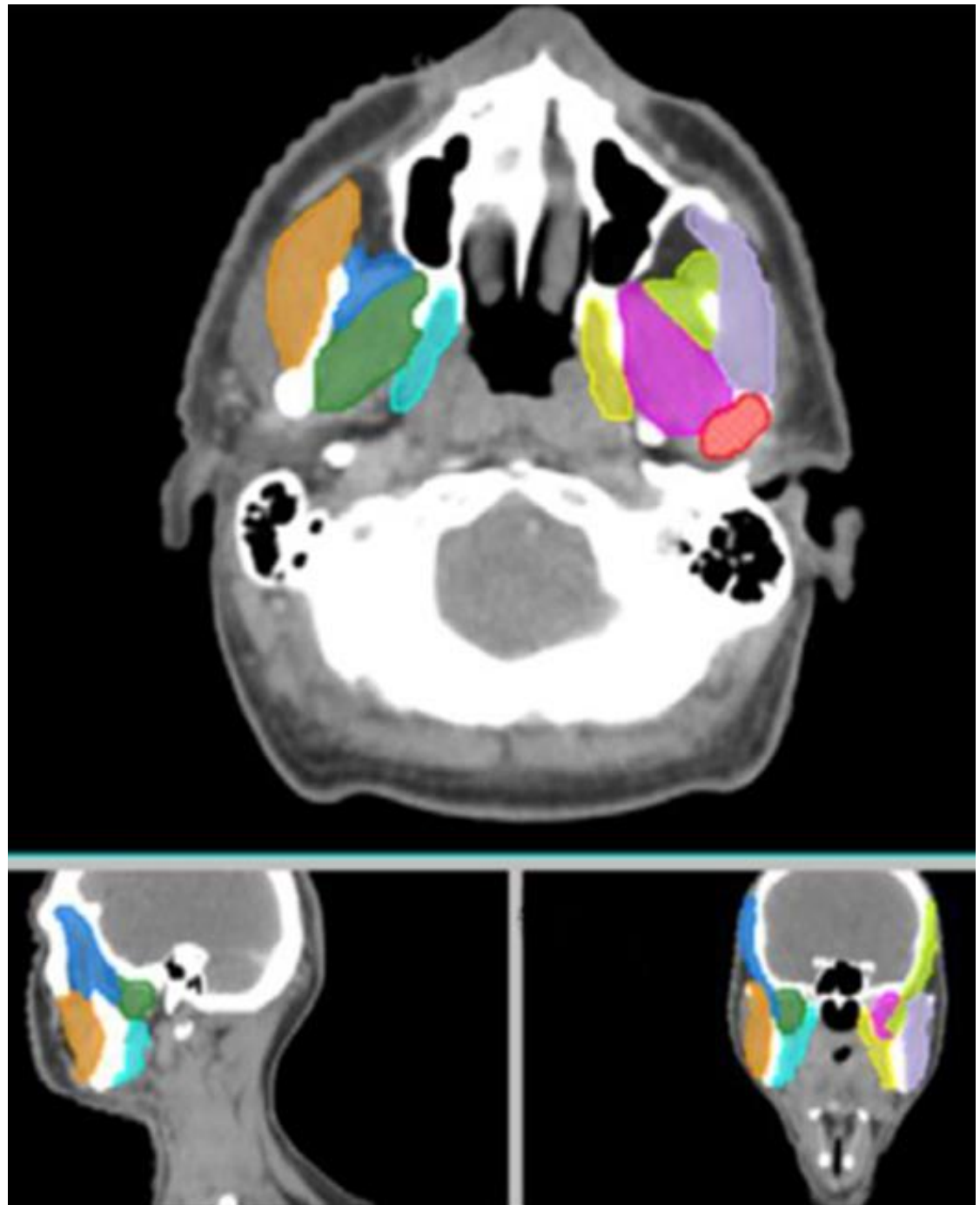


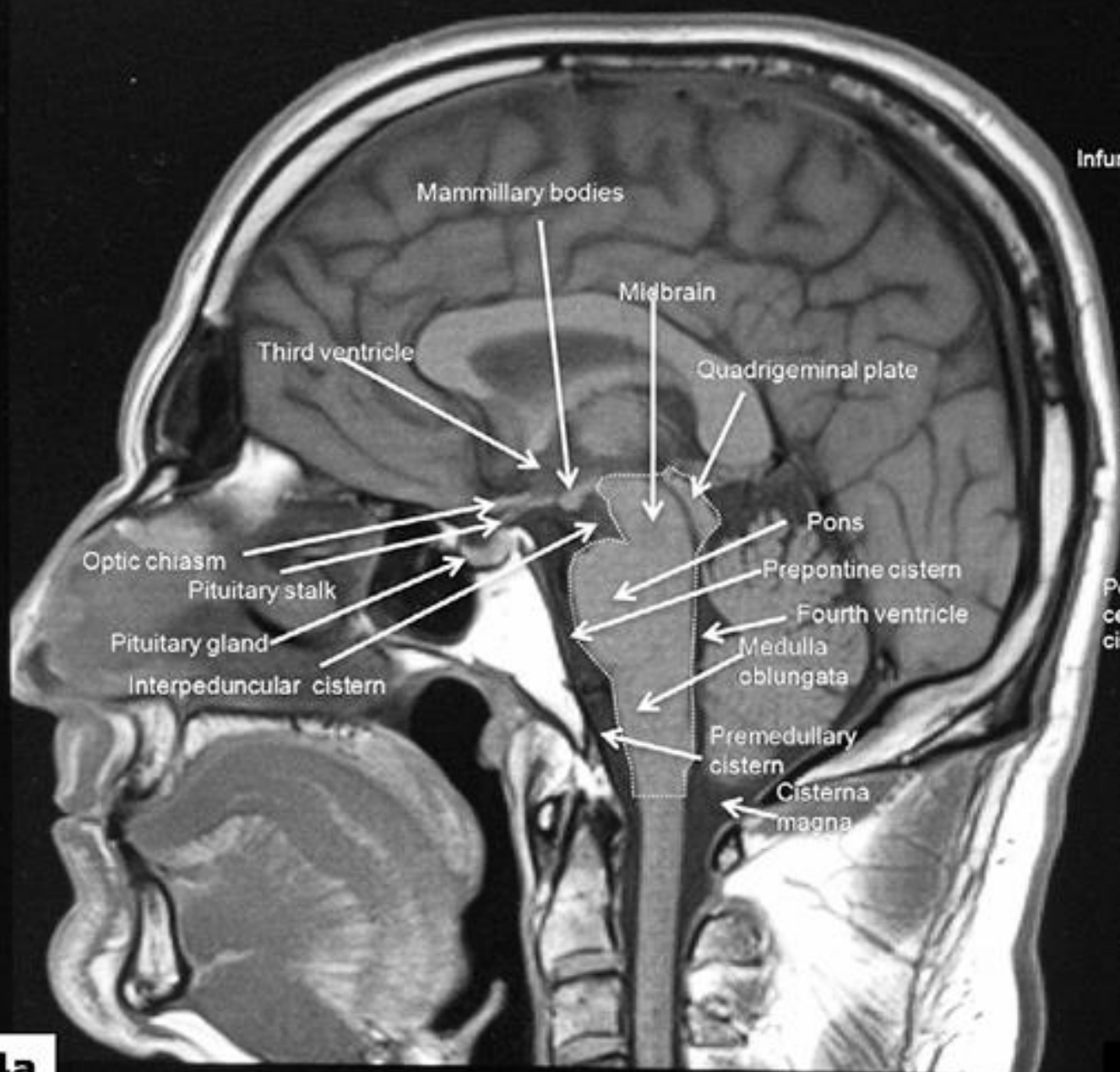




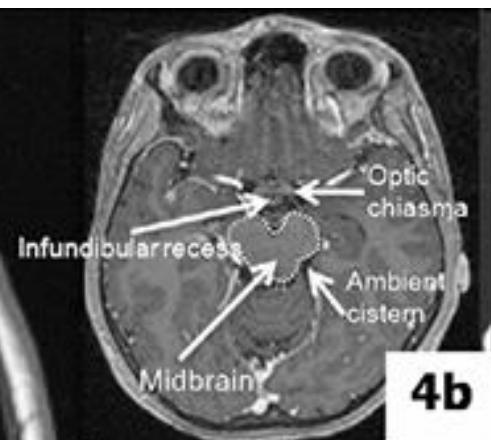
Masticatory Muscles

Colour	Structure
	leftLateralPterygoid
	leftMasseter
	leftMedialPterygoid
	leftTemporalis
	leftTMJ
	rightLateralPterygoid
	rightMasseter
	rightMedialPterygoid
	rightTemporalis
	rightTMJ

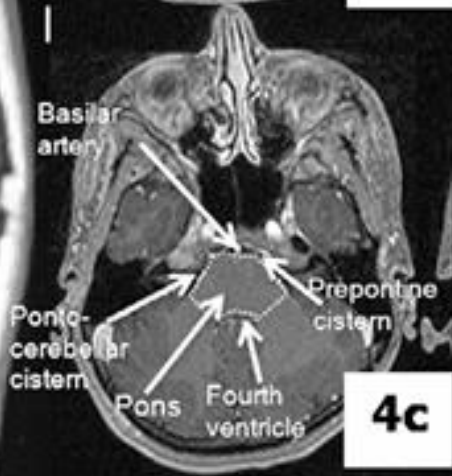




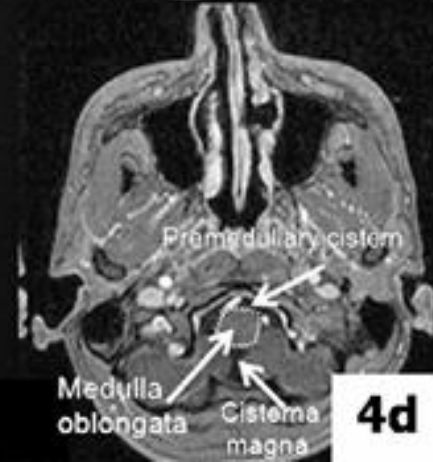4a



4b



4c



4d

Critical organ/tissue; dose constraint at MSKCC

Brainstem	$D_{\max} = 54 \text{ Gy or } 60 \text{ Gy to } 1\% \text{ of the volume}$
Optic nerves	$D_{\max} = 54 \text{ Gy or } 60 \text{ Gy to } 1\% \text{ of the volume}$
Optic chiasm	$D_{\max} = 54 \text{ Gy or } 60 \text{ Gy to } 1\% \text{ of the volume}$
Spinal cord	$D_{\max} = 45 \text{ Gy or } 50 \text{ Gy to } 1\% \text{ of the volume}$
Temporal lobes	$D_{\max} = 60 \text{ Gy or } 65 \text{ Gy to } 1\% \text{ of the volume}$
Mandible and TM joint	$D_{\max} = 70 \text{ Gy or } 75 \text{ Gy to } 1 \text{ cc of the volume}$

Noncritical

Parotid glands	$D_{\text{mean}} = 26 \text{ Gy (in at least one gland)}$
Submandibular glands	As low as possible
Oral cavity	$D_{\text{mean}} = 40 \text{ Gy}$
Larynx	$D_{\text{mean}} = 40 \text{ to } 45 \text{ Gy or } D_{\max} = 70 \text{ Gy or } = 105\% \text{ of prescription}$
Cochlea	$D_{\max} = 50 \text{ Gy}$
Retinas (globes)	$D_{\max} = 45 \text{ Gy}$
Lenses	$D_{\max} = 5 \text{ Gy}$
Brachial plexus	$D_{\max} = 65 \text{ Gy and D05 } D_{\max} = 70 \text{ Gy}$

OAR	Constraints for adults		Constraints for children
	Primary criteria	Secondary criteria	
Optic chiasma	$D_{\max} < 54$ [10,11] $D_{\max} < 55$ [12]	$D_{\max} < 60$ [10]	
Cochlea	$D_{\text{mean}} \leq 45$ Gy [13,14] $D_{\text{mean}} < 50$ Gy [10]		$D_{\text{mean}} < 35$ Gy [16]
Hippocampus	Hippocampus $D_{\max} \leq 6$ Gy and $V_{3 \text{ Gy}} \leq 20\%$ Hippocampal avoidance volume $D_{\max} < 25.2$ Gy and $V_{20 \text{ Gy}} \leq 20\%$ [21,22] $D_{\max} < 12$ Gy [23] $V_{7.2 \text{ Gy}} < 40\%$ [25] $D_{\text{mean}} < 30$ Gy [24]		
Brainstem	$D_{\max} < 54$ Gy [10,29]	$D_{\max} < 60$ Gy [10] $D_{59 \text{ Gy}} < 10$ cc [29]	
Pituitary gland	$D_{\max} < 50$ Gy [34] $D_{\max} < 60$ Gy [10]		$D_{\text{mean}} < 25$ or 30 Gy [32] $D_{\max} < 42$ Gy [35]
Retina	$D_{\max} < 45$ Gy [10, Yamazaki] $D_{\max} < 50$ Gy [Shaffer]		
Lacrimal gland	$V_{30 \text{ Gy}} < 50\%$ [Sreeraman] $D_{\max} < 40$ Gy [Jeganathan]		
Lens	$D_{\max} < 6$ Gy [Piroth] $D_{\max} < 10$ Gy [10, Yamazaki]		

Cairo University Scholars

<http://scholar.cu.edu.eg/?q=ashrafhassouna>



Ashraf Hamed Mohamed Hassouna

Professor of Radiation Oncology

[\(email\)](#)



CAIRO UNIVERSITY

[Publications](#)

[Bio](#)

[Classes](#)

[Images](#)

Bio

[Biography](#) [Curriculum Vitae](#)

M.D.
in Radiation Oncology

NCI, Cairo University,

Please Visit This Page You Can Get This Presentation andMore