


AUTHOR QUERY FORM

 ELSEVIER	Journal: ASJSUR Article Number: 236	Please e-mail your responses and any corrections to: E-mail: corrections.esch@elsevier.tnq.co.in
--	--	--

Dear Author,

Please check your proof carefully and mark all corrections at the appropriate place in the proof (e.g., by using on-screen annotation in the PDF file) or compile them in a separate list. Note: if you opt to annotate the file with software other than Adobe Reader then please also highlight the appropriate place in the PDF file. To ensure fast publication of your paper please return your corrections within 48 hours.

For correction or revision of any artwork, please consult <http://www.elsevier.com/artworkinstructions>.

Any queries or remarks that have arisen during the processing of your manuscript are listed below and highlighted by flags in the proof.

Location in article	Query / Remark: Click on the Q link to find the query's location in text Please insert your reply or correction at the corresponding line in the proof
Q1	Author affiliations. If applicable, please add name of department and/or division for both affiliations.
Q2	Please check to ensure ANOVA has been correctly expanded.
Q3	Please rewrite this sentence for clarity.
Q4	Please confirm if the Conflict of interest statement is correct and amend if necessary.
Q5	Please note that the part label C has been repeated twice in Figure 1 caption. Hence we made second occurrence C to D. Kindly check and amend if necessary.
Q6	Please confirm that given names and surnames have been identified correctly.
	<div data-bbox="304 1378 895 1561" style="border: 1px solid black; padding: 5px;"> <p data-bbox="311 1421 715 1517">Please check this box or indicate your approval if you have no corrections to make to the PDF file</p> <div data-bbox="791 1442 874 1523" style="border: 1px solid black; width: 40px; height: 40px; display: inline-block; vertical-align: middle;"></div> </div>

Thank you for your assistance.

Available online at www.sciencedirect.com

ScienceDirect

journal homepage: www.e-asianjournalsurgery.com

ORIGINAL ARTICLE

Technique and outcome of autotransplanting thyroid tissue after total thyroidectomy for simple multinodular goiters

Amr A. Mohsen^a, Ahmed A. Nada^a, Mohamed Y. Ibrahim^{a,*},
 Ashraf H. Ghaleb^a, Mahasen A. Abou-Gabal^a,
 Ahmed A. Mohsen^b, Arsany T. Wassef^a

^a Faculty of Medicine Cairo University, Cairo, Egypt

^b National Research Centre, Cairo, Egypt

Received 6 February 2015; received in revised form 27 April 2015; accepted 14 May 2015

KEYWORDS

multinodular goiter;
 thyroid auto-
 transplantation;
 thyroidectomy

Summary *Background/Objective:* Limited animal and human studies have shown function, albeit inadequate, of implanted thyroid tissue in muscles. This work aimed to ascertain results in a larger number of patients, finding practical method for implantation, studying the effect of changing weight of implant and effect of passage of time on its function.

Methods: Forty patients had total thyroidectomy for simple multinodular goiters. A piece of the excised gland was finely minced, mixed with saline as emulsion, and injected in thigh muscles. Twelve patients had 5-g implants, while 28 patients had 10-g implants. Four parameters were studied at 2 months, 6 months, and 12 months: technetium isotope uptake by the implant; thyroid stimulating hormone (TSH); free T3 (FT3); and free T4 (FT4).

Results: All autotransplanted thyroid tissue survived and functioned. After 12 months, mean values (\pm standard deviation) of isotope uptake, TSH, FT3, and FT4 of the 5-g implants were $0.44 \pm 0.16\%$, 27.74 ± 30.4 UI/mL, 3.07 ± 1.10 pg/mL, and 1.01 ± 0.3 ng/dL, respectively. Those for the 10 g implants were $0.71 \pm 0.20\%$, 22.78 ± 19.7 UI/mL, 3.92 ± 1.2 pg/mL, and 1.05 ± 0.3 ng/dL, respectively. Ten-gram implants showed significantly higher isotope uptake than 5-g. TSH, FT3, and FT4 significantly improved over the period of 1 year.

Conclusion: Injection of thyroid tissue suspension is a simple method for thyroid autotransplantation. TSH was elevated in the majority to maintain normal or near normal thyroid hormones. Ten-gram implants showed higher isotope uptake than 5-g, although this difference

Conflicts of interest: All contributing authors declare no conflicts of interest.

* Corresponding author. 1 el Hala Street from el Koba Street, Roxy, Heliopolis, Cairo 11341, Egypt.

E-mail address: dr.mohamed_yehia@yahoo.com (M.Y. Ibrahim).

<http://dx.doi.org/10.1016/j.asjsur.2015.05.007>

1015-9584/Copyright © 2015, Asian Surgical Association. Published by Elsevier Taiwan LLC. All rights reserved.

Please cite this article in press as: Mohsen AA, et al., Technique and outcome of autotransplanting thyroid tissue after total thyroidectomy for simple multinodular goiters, Asian Journal of Surgery (2015), <http://dx.doi.org/10.1016/j.asjsur.2015.05.007>

was not reflected by thyroid hormone profile. The implant seemed to function better with the passage of time from 2 months to 12 months.

Copyright © 2015, Asian Surgical Association. Published by Elsevier Taiwan LLC. All rights reserved.

1. Introduction

Whenever surgery is indicated for a simple multinodular goiter, the current trend is to do total thyroidectomy.^{1,2} Inevitably this makes the patient dependent on replacement therapy for life. Although it seems relatively easy to control hypothyroidism by levo-thyroxine, from the patient's point of view, a daily dependence on it and regular visits to hospital to check hormone levels are burdensome. Other problems that may interfere with reaching a euthyroid status using replacement therapy are malabsorption³ and noncompliance of patients.⁴

The clinical application of transplantation in the endocrine field, by autotransplantation of endocrine organs for hormone replacement has already been established in the field of parathyroid surgery. Before applying the same principles on the thyroid gland in humans, studies have been done on animals. Autologous transplantations were found to be successful in 70% of cases and histological examinations showed normal thyroid architecture.^{5–8} Very few studies have addressed this issue in humans. The number of patients in each study was very small,^{9–12} the largest study including only 15 patients.¹² Furthermore, the study methodology was not consistent.

The aims of the current work were to ascertain these results in a larger number of patients, find a practical method of transplanting sizable thyroid tissue, and study the effects of changing weight of implant and passage of time on its function.

2. Methods

This case series study was approved by the Research Ethics Committee of the Faculty of Medicine at Cairo University, Cairo, Egypt. It was conducted at Cairo University Hospital and included 40 patients with simple multinodular goiters who were indicated for total thyroidectomy because of compression manifestations, and where nodularity extended to both lobes. Children, unwilling patients, and those who had any clinical or ultrasound suspicion of malignancy were excluded. Similarly, those with a family history of thyroid cancer and history of neck irradiation were excluded because they constitute a high risk of developing thyroid cancer. The study included 36 women and four men. Written informed consent was obtained from all patients, stressing the importance of regular follow up. Preoperative evaluation followed the same standard protocol and included a thorough history, examination, thyroid function tests, neck ultrasound, and fine-needle aspiration cytology of a dominant or suspicious nodule.

Total thyroidectomies were performed under general anesthesia. During postexcision hemostasis and closure a member of the operating team performed the autotransplantation preparation at a side table. The healthiest-looking part of the thyroid was chosen. The slightest gross suspicion of malignancy led to termination of the implantation procedure. Intraoperatively, two patients were excluded from the study on gross picture suspicion of malignancy. Neither showed cancer on histological examination of postoperative paraffin sections.

The initial 12 patients received 5-g implants, while the remaining 28 received 10-g implants. The tissues to be transplanted were very finely divided using a pair of scissors and made into an emulsion by adding them to saline in a 20-mL syringe. This was attached to a 2.4 mm-caliber needle. A 3-mm incision was made in the anterolateral aspect of the middle third of the thigh. Through this incision the thyroid tissue emulsion was injected in 8–10 sites in the thigh muscles by changing the direction and depth of needle introduction. Figure 1 shows the steps of this technique.

Postoperatively, L-thyroxine replacement was given at a dose of 50 µg/d, pending the take of implanted tissues. Thyroid function tests—free T3 (FT3), free T4 (FT4), thyroid stimulating hormone (TSH), and isotope scan were done at 2 months, 6 months, and 12 months after the operation. Replacement therapy was withheld 3 weeks prior to each occasion in order to strictly assess function of the implanted tissues. Scans were done by intravenous injection of 5–10 mCi of radioactive technetium (^{99m}Tc). Imaging was done 20 minutes later and the uptake ratio by the implant was obtained.

Data showed parametric distribution; therefore Student *t* test was used for comparisons between the 5- and 10-g groups for isotope uptake by the implant, TSH, FT3, and FT4. Analysis of the significance of the time passage on isotope uptake, TSH, FT3, and FT4 was done using analysis of variance test, as well as a comparison of the different means using paired *t* test. The significance level was set at $p \leq 0.05$.

3. Results

Apart from minor complications, postoperative courses were uneventful. Temporary recurrent laryngeal nerve occurred in one patient and resolved spontaneously in 4 weeks. Temporary hypoparathyroidism occurred in 11 patients and was controlled by oral calcium and vitamin D. The condition resolved within 3–7 weeks. There were no complications related to the autotransplantation site. None of the excised thyroids showed histological evidence of malignancy.

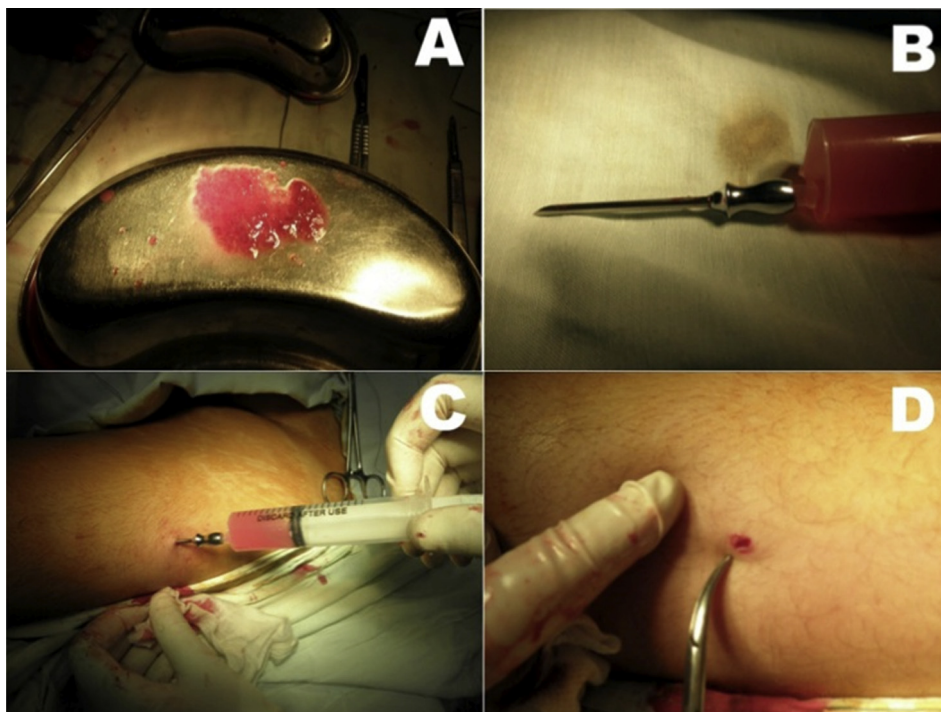


Figure 1 (A) Finely-minced thyroid tissue. (B) Emulsified thyroid tissue in saline, ready for injection. (C) Injection of the emulsion in the thigh. (D) The 3-mm incision after injection.

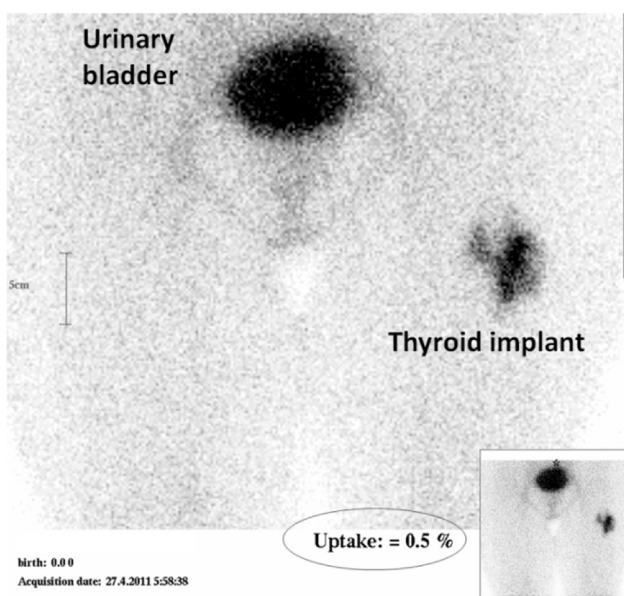


Figure 2 Normal isotope uptake (0.5%) by the implanted thyroid tissue in the left thigh.

The 5- and 10-g implant patients were statistically matched for age with a mean \pm standard deviation of 42.7 ± 12.9 and 37.8 ± 8.8 , respectively. In all patients the autotransplanted thyroid tissue showed uptake of ^{99m}Tc . The degree of uptake, however, was variable. **Figure 2** demonstrates normal isotope uptake of the heterotopically implanted thyroid tissue. Faint isotope uptake in the

neck was observed in 18 patients. In all, its mean value was $0.06 \pm 0.08\%$. **Table 1** shows ^{99m}Tc uptake by the thigh implant. Isotope uptake was significantly higher for the 10-g implants than the 5-g implants at 6 months ($p = 0.001$) and at 12 months ($p = 0.001$). Even though uptake tended to increase with passage of time, this did not reach statistical significance.

Table 2 shows TSH levels. There were no statistically significant differences between those with 5- and 10-g implants at 2 months, 6 months, and 12 months. By contrast, TSH levels significantly decreased with time passage for both the 5-g ($p = 0.001$) and the 10-g implants ($p = 0.001$).

Table 3 shows FT3 levels. These levels tended to be higher with the 10-g implants than the 5-g implants, although the difference was statistically significant only at 12 months ($p = 0.04$). FT3 levels significantly increased by passage of time for the 5-g implants ($p = 0.02$) and for the 10-g implants ($p = 0.01$).

Table 4 shows FT4 levels. These levels tended to be higher with the 10-g implants than the 5-g implants, although the differences did not reach statistical significance at any time after the procedure. There were, however, significant elevations of FT4 levels with the passage of time for the 5-g implants ($p = 0.02$) and for the 10-g implants ($p = 0.02$).

At 12 months, those patients who achieved normal TSH or near normal levels (up to 8 UI/mL, particularly in the elderly) discontinued eltroxine replacement therapy, but were still kept under regular follow-up every 3 months. These were three patients in the 5-g group and five patients in the 10-g group.

Table 1 ^{99m}Tc Uptake by the implant ($n = 0.5\text{--}2\%$).

	5-g implants (12 patients)		10-g implants (28 patients)	
	Mean \pm SD	% Patients achieving normal values	Mean \pm SD	% Patients achieving normal values
2 mo	0.28 \pm 0.16	8.3	0.44 \pm 0.35	37
6 mo	0.28 \pm 0.15	16.6	0.59 \pm 0.27	73
12 mo	0.44 \pm 0.16	41.6	0.71 \pm 0.20	88

SD = standard deviation.

Table 2 Thyroid stimulating hormone levels ($n = 0.4\text{--}4$ UI/mL).

	5-g implants (12 patients)		10-g implants (28 patients)	
	Mean \pm SD	% Patients achieving normal values	Mean \pm SD	% Patients achieving normal values
Preop	2.26 \pm 1.15		2.89 \pm 1.22	
2 mo	49.56 \pm 32	0	46.0 \pm 26.2	0
6 mo	37.14 \pm 29.6	0	37.04 \pm 26.4	0
12 mo	27.74 \pm 30.4	16.6	22.78 \pm 19.7	3

SD = standard deviation.

Table 3 Free T3 levels ($n = 1.3\text{--}5$ pg/mL).

	5-g implants (12 patients)		10-g implants (28 patients)	
	Mean \pm SD	% Patients achieving normal values	Mean \pm SD	% Patients achieving normal values
Preop	2.99 \pm 0.94		3.31 \pm 0.8	
2 mo	1.85 \pm 1.0	58.3	2.13 \pm 0.6	89.2
6 mo	2.25 \pm 0.9	83.3	2.61 \pm 0.6	92.8
12 mo	3.07 \pm 1.10	91.6	3.92 \pm 1.2	100

SD = standard deviation.

Table 4 Free T4 levels ($n = 0.8\text{--}2$ ng/dL).

	5-g implants (12 patients)		10-g implants (28 patients)	
	Mean \pm SD	% Patients achieving normal values	Mean \pm SD	% Patients achieving normal values
Preop	1.31 \pm 0.37		1.08 \pm 0.35	
2 mo	0.61 \pm 0.3	33.3	0.68 \pm 0.2	35.7
6 mo	0.78 \pm 0.3	66.6	0.81 \pm 0.3	67.8
12 mo	1.01 \pm 0.3	83.3%	1.05 \pm 0.3	85.7%

SD = standard deviation.

4. Discussion

The purpose of heterotopic thyroid autotransplantation is to leave thyroid tissue in the body that might be able to avoid or reduce severity of post-thyroidectomy hypothyroidism in noncompliant patients. In the meantime, if recurrence occurs it would not be in the neck, thus avoiding compression on the trachea and avoiding dangerous reoperation in the neck. Reports on its clinical application are very scarce in the literature, with few patients in each study. Furthermore, none of these studies focused on simple multinodular goiters; the majority were directed to Graves' disease. The only well-documented study that addressed this issue with a few

multinodular cases was that of Roy et al¹² who included eight multinodular goiters among their studied 15 patients.

Even though all animal and human studies documented the survival and function of thyroid tissue that was implanted in muscle, the technique seldom achieved a euthyroid status and suffered heterogeneity of tissue preparation (some used frozen, while others used fresh tissue), implant timing, and variability of implant weight. This work was set to study the survival and function of implanted tissues of multinodular goiters, on a larger patient population. It was also a trial at standardizing the amount to be transplanted and to test the applicability of an easy technique for its implementation.

In the best documented technical description, that of Shimizu et al,¹¹ the workers implanted 2.5–3.5 g per patient with Graves' disease. For the current work, the implanted tissue was expected to be less active and hence at the start of the study 5-g implants were implanted for the first 12 patients. As functional results of these patients were found to be suboptimal, the weight of implanted tissue was raised to 10 g. The problem with implanting such sizable amount of tissue was that many muscle pockets were made; they would be over-packed with the implanted thyroid tissue, a factor that may hinder the graft take. The procedure would also take an unacceptably long time. In 2000, Gauger et al¹³ described the technique of injecting parathyroid emulsion in the sternomastoid. Their technique was adopted in this work for thyroid tissue implantation using a 20-mL syringe with saline. This technique simplifies the implantation of sizable tissues, in a short time (~15 minutes), and leaves a small, barely visible scar. With this technique all implants survived and functioned.

To avoid the development of hypothyroidism, pending the take of the graft, all patients were given 50 µg levothyroxine daily. Such a relatively low replacement dose was chosen because it was felt that keeping a high TSH would enhance implant survival and function. Replacement therapy was discontinued 3 weeks before assessment of its function. This was judged enough time for the replacement therapy to practically disappear from the circulation, the half-life of T4 being 1 week, and that of T3 1 day. Thus, 3 weeks after discontinuation of replacement therapy, the patient is totally dependent on the implanted thyroid tissue. Although in a number of patients, isotope scans detected residual thyroid tissue in the neck, such cervical uptake was too small to interfere with interpretation of the implant function. The overall implant function was satisfactory but not ideal. At 1 year, the majority of patients showed normal isotope uptake by the implant, normal FT3 and FT4. Actually, all patients with 10-g implants showed normal T3 levels. Meanwhile, the majority maintained a high TSH levels. This means that the majority of patients achieved a euthyroid status but at the expense of hyperactivity of the anterior pituitary gland.

In the literature there is no previous mention of the effect of time passage on the function of thyroid autotransplant. In the current work, however, this point was investigated. Analysis of variance showed that the levels of FT3 and FT4 increased with time, and likewise TSH showed significant move towards normalization, i.e., reduction of its levels. Even though isotope uptake showed also a tendency towards elevation, it did not reach statistical significance.

Since the volume of a normal thyroid gland varies from one country to another,^{14–18} its weight is also variable from 15 g to 25 g. As far as the effect of tissue weight was concerned, 10-g implants showed significantly higher isotope uptake and higher FT3 than the 5-g implants. It thus looks reasonable to advise that the minimum weight of thyroid autotransplantation for a simple multinodular goiter should be 10 g. Future studies may achieve better function with heavier implants. This sounds logical when the weight of a normal gland is considered. A piece of the excised multinodular goiter, even though it looks grossly

normal, is very likely to contain micronodules, and thus may have a lower functional capacity.

The possibility of implanting undetected thyroid cancer in muscle is a concern. In a recent study 23.1% of cervical multinodular goiters that had a benign preoperative fine-needle aspiration were found to have thyroid cancer on final pathology.¹⁹ Precautions that have been taken included preoperative and operative measures. Before surgery those with a family history of thyroid cancer or neck irradiation were excluded. Thorough clinical assessment, neck ultrasound, and fine-needle aspiration cytology for any suspicious nodule were done. The slightest suspicion of malignancy disqualified the patient for autotransplantation. At operation the healthiest-looking piece of excised thyroid was chosen for implantation. Cutting of the chosen tissue was too fine to allow for missing any gross change in appearance or texture. Still, the possibility of implanting an occult thyroid cancer is a point to be considered. The possible survival of cancer cells in somatic muscles has to be investigated. However, under the previously mentioned precautions it is a very remote possibility that should not interfere with the clinical application of thyroid autotransplantation. To cite an example, the theoretical possibility of a microscopic carcinoma in a donor organ does not interfere with the transplantation process.

Hypothetically, function depends on the status of the graft (cell density and potential regeneration power), survival of cells in the transplant bed, its size, and the duration of long-term stimulation. Longer follow-up is undoubtedly needed. The principle of the technique relies on the thyroid autotransplant as a robust, life-long substitute for replacement therapy. Such an assumption waits time testing. Another concern is possible goiter recurrence in the thigh muscles. Theoretically a goiter in the thigh is less likely to be visible or to compress important structures. Surgery for such a swelling would certainly be less serious than a second operation in the neck.

References

1. Moalem J, Suh I, Duh Q. Treatment and prevention of recurrence of multinodular goiter: an evidence-based review of the literature. *World J Surg.* 2008;32:1301–1312.
2. Agarwal G, Aggarwal V. Is total thyroidectomy the surgical procedure of choice for benign multinodular goiter? An evidence-based review. *World J Surg.* 2008;32:1313–1324.
3. Lips DJ, van Reisen MT, Voigt V, Venekamp W. Diagnosis and treatment of levothyroxine pseudomalabsorption. *Neth J Med.* 2004;62:114–118.
4. Sethi MJ, Parr M, Bhatia V. Management strategies for hypothyroidism in noncompliant patients: a case report and review of literature. *S. D Med.* 2008;61:368–369.
5. Shimizu K, Nagahama M, Kitamura Y, Igarashi T, Aida N, Tanaka S. Improvement of thyroid function after autotransplantation of cryopreserved thyroid tissue in rats: clinical application of the procedure to patients with persistent hypothyroid Graves' disease after thyroidectomy. *Thyroidol Clin Exp.* 1996;8:55–62.
6. Papaziogas B, Antoniadis A, Lazaridis C, et al. Functional capacity of the thyroid autograft: an experimental study. *J Surg Res.* 2002;103:223–227.

- 1 7. Gál I, Mikó I, Furka I, Nagy D. Autotransplantation of cryo- 24
2 opreserved thyroid tissue in dogs. *Magy Seb.* 2005;58:93–99 25
3 [in Hungarian]. 26
- 4 8. Dobrinja C, Trevisan R, Trevisan G, Liguori G. Auto- 27
5 transplantation of thyroid tissue in rats. An experimental 28
6 study. *Ann Ital Chir.* 2008;79:389–395. 29
- 7 9. Pushkar' NS, Makedonskaia VA, Utevskaia AM, Chuiko VA, 30
8 Karpenko LG. Autoimplantation of cryopreserved (–196 de- 31
9 grees C) thyroid gland parenchyma as a treatment method in 32
10 postoperative hypothyroidism. *Probl Endokrinol (Mosk).* 1984; 33
11 30:42–46 [in Russian]. 34
- 12 10. Okamoto T, Fujimoto Y, Obara T, Ito Y, Kodama T, Kusakabe K. 35
13 Trial of thyroid autotransplantation in patients with Graves' 36
14 disease whose remnant thyroid has unintentionally been made 37
15 too small at subtotal thyroidectomy. *Endocrinol Jpn.* 1990;37: 38
16 95–101. 39
- 17 11. Shimizu K, Kumita S, Kitamura Y, et al. Trial of auto- 40
18 transplantation of cryopreserved thyroid tissue for post- 41
19 operative hypothyroidism in patients with Graves' disease. 42
20 *J Am Coll Surg.* 2002;194:14–22. 43
- 21 12. Roy PG, Saund MS, Thusoo TK, Roy D, Sankar R. Fate of human 44
22 thyroid tissue autotransplants. *Surg Today.* 2003;33:571–576. 45
23 46
13. Gauger PG, Reeve TS, Wilkinson M, Delbridge LW. Routine 24
14 parathyroid autotransplantation during total thyroidectomy: 25
15 the influence of technique. *Eur J Surg.* 2000;166:605–609. 26
- 16 14. Yousef M, Sulieman A, Ahmed B, Abdella A, Eltom K. Local 27
17 reference ranges of thyroid volume in Sudanese normal sub- 28
18 jects using ultrasound. *J Thyroid Res.* 2011;2011:935141. 29
- 19 15. Ivanac G, Rozman B, Skreb F, Brkljacic B, Pavić L. Ultrasono- 30
20 graphic measurement of the thyroid volume. *Coll Antropol.* 31
21 2004;28:287–291. 32
- 22 16. Ahidjo A, Tahir A, Tukur MA. Ultrasound determination of 33
23 thyroid gland volume among adult Nigerians. *Internet J Radiol;* 34
24 2006;4. Available at: <https://ispub.com/IJRA/4/2/8932>. 35
- 25 17. Chanoine JP, Toppet V, Lagasse R, Spehl M, Delange F. Deter- 36
26 mination of thyroid volume by ultrasound from the neonatal 37
27 period to late adolescence. *Eur J Pediatr.* 1991;150:395–399. 38
- 28 18. Adibi A, Sirous M, Aminorroaya A, et al. Normal values of thy- 39
29 roid gland in Isfahan, an iodine replete area. *J Res Med Sci.* 40
30 2008;13:55–60. 41
- 31 19. Campbell MJ, Seib CD, Candell L, et al. The underestimated 42
32 risk of cancer in patients with multinodular goiters after a 43
33 benign fine needle aspiration. *World J Surg.* 2015;39: 44
34 695–700. 45
35 46