

Multifocal Visual Evoked Potential in Idiopathic Intracranial Hypertension

Hala R. El Habashy¹, Amira M. El Gohary¹, Radwa M. Azmy¹,
Mohamed I. Hegazy², Zeinab S. Elsanabary³, Aliaa A. Tawfeek¹

Departments of Clinical Neurophysiology¹, Neurology², Ophthalmology³, Cairo University; Egypt

ABSTRACT

Background: The multifocal visual evoked potential (mfVEP) has been developed to examine conduction in the parts of the visual field that the conventional visual evoked potential (cVEP) does not, thus mfVEP better reflects the true state of the optic nerve by including information from fibers subserving more peripheral part of the visual field. **Objective:** To assess mfVEP changes in idiopathic intracranial hypertension (IIH) patients and to compare role of cVEP and mfVEP methods in detecting optic pathway affection in IIH patients. **Methods:** mfVEP and cVEP were recorded during the same session in 30 eyes of IIH patients with an active electrode at Oz to Fz (Oz-Fz) for the cVEP and the active electrodes of the mfVEP at theinion in the form of cross electrode fixed around the inion and the ground at Fz. **Results:** 19 eyes (63.3%) of the examined 30 eyes had abnormal cVEP; while 11 eyes (36.7%) had normal responses. 28 eyes (93.3 %) of the examined 30 eyes had abnormal mfVEP responses, while only 2 eyes (6.7%) had normal responses. **Conclusion:** mfVEP is superior to the cVEP in detecting local damage to the optic nerve in idiopathic intracranial hypertension patients. [Egypt J Neurol Psychiat Neurosurg. 2014; 51(4): 477- 482]

Key Words: Idiopathic intracranial hypertension; conventional visual evoked potentials; multifocal visual evoked potentials

INTRODUCTION

Idiopathic intracranial hypertension (IIH) is a condition characterized by raised intracranial pressure, normal cerebrospinal fluid (CSF) contents, and normal brain with normal or small ventricles on imaging studies^{1, 2}. IIH presents with various clinical manifestations, including headache, vomiting, visual disturbances, papilledema, cranial-nerve palsies, or a combination of these signs³.

It is primarily a disease of obese women in the childbearing age, but it can affect patients of any weight, sex, and age⁴. Clinical features often cannot reliably distinguish IIH without papilledema from other chronic daily headaches⁵. IIH patients can have delayed worsening or relapses and about tenth of patients can have permanent visual loss early or late in the course of the disease. All patients with IIH need to be kept under long-term monitoring, with regular follow-up of visual functions⁶. If not treated, chronic ensuing papilledema may lead to irreversible optic neuropathy⁷. Kesler and his colleagues⁸ measured visual evoked potential in an attempt to evaluate quantitatively the optic nerve damage in patients with chronic IIH.

Correspondence to Hala R. El Habashy. Clinical Neurophysiology Unit, Cairo University, Egypt.
Email: hala.elhabashy@kasralainy.edu.eg

The conventional visual evoked potential (cVEP) sums responses from a wide region of the field. Thus, local delays may be lost in the process⁹. Unlike cVEP, multifocal visual evoked potential (mfVEP) samples regions of the central 48° (diameter) of the field¹⁰. Furthermore, in light of the fact that the lower field can contribute more to the cVEP than the upper field¹¹, the cVEP is less likely to detect upper field defects. It is therefore reasonable to assume that although the cVEP may detect wide spread areas of demyelination, it may fail to detect localized changes¹².

The mfVEP may better reflect the true state of the optic nerve by including information from fibers subserving more peripheral part of the visual field. Simultaneous recording from plurality of visual field locations also results in higher spatial resolution of the mfVEP technique, allowing independent assessment of multiple regions¹⁰.

The mfVEP has been developed to examine conduction in the parts of the visual field that the cVEP does not. The mfVEP uses a paradigm of sectorial stimulation with pseudo-stimulation at other sites, using the fellow eye and normal controls for comparison at each point¹³.

The aim of this work is to assess mfVEP changes in idiopathic intracranial hypertension (IIH) patients and to compare role of cVEP and mfVEP methods in detecting optic pathway affection in IIH patients.

METHODS

Subjects

This study included thirty eyes of 15 IIH female patients referred from neurology outpatient clinic and neurology department in the Cairo university teaching hospital. Their ages ranged from 27 to 55 years with mean age of 35.6 ± 8.3 years with matching age and sex control group. The patients were fulfilling the modified Dandy criteria¹⁴ excluding patients with ocular diseases, hormonal disturbance, and diabetic and hypertensive patients. The control group consisted of 27 females; their ages ranged from 26 to 54 years with mean age of 38.2 ± 6.3 years.

Thorough neuro-ophthalmological examination was performed for all patients including Snellen visual acuity, ophthalmoscopic examination and fundus photography. Lumbar punctures were performed in the lateral decubitus position to measure the intracranial pressure. All patients underwent brain-computed tomography (CT) with contrast and magnetic resonance imaging of the brain and cerebral veins (MRI and MRV).

cVEP RECORDING AND ANALYSIS

cVEP and mfVEP examination were performed at the same session with the same machine (RETI scan 21, version 07/01, Roland Consult Electrophysiological Diagnostic Systems, Brandenburg, Germany). The active electrode was placed at Oz with the reference electrode at Fz. A separate electrode was attached at vertex Cz and connected to the ground, in a manner adhering to the international society for clinical electrophysiology of vision (ISCEV) guidelines¹⁵. The patient sat on a comfortable chair at a distance of about 60-70 cm from a black and white checkerboard 20-inch monochrome screen after correction of vision. Gold disc electrodes were used for recording pattern-reversal visual evoked potential (PRVEP). The electrode impedances were kept below 5 k Ω . The mean luminance of the checkerboard was 50 cd/m² and contrast between black and white squares was 100%, at a frequency of 1.0 Hz. The PRVEP waveform consists of N75, P100, and N135 peaks. The P100 latency that equals to/or above 117 msec and amplitude below than 3 μ v was considered abnormal¹⁶.

mfVEP RECORDING AND ANALYSIS

Electrodes used for mfVEP recording were cross connection and bridge electrode connection attached to the head by a rubber band. The skin is prepared with cleaning using gel (Nuprep). Electrodes are fixed in position as follows: Channel A: 2cm above the

inion, Channel C: 1 cm below it, Channel B and D: 1cm above and 4cm lateral to the inion. VEP cross is designed to fit every channel in the right position just by adjusting channel A position by the examiner. Ground electrode was placed over the forehead using the rubber band. Electrode impedance is kept below 5 k Ω . A 20-inch monochrome monitor displayed the stimulus, which consisted of 62 segments, each one with 16 checks; eight white and eight black. The black and white checks change phase abruptly and repeatedly. The visual angle was 31° with correction of vision. An artifact level of 10% of the trials was accepted for a reliable examination. Each eye was examined separately starting with the right one. Average of 4 cycles was taken for each eye; each cycle consisted of 1000 responses and consumed 2.14 minutes.

The mfVEP response was considered abnormal when there was 3 contiguous segments in the same hemifield had a P value less than 0.05 with at least one segment had a P value less than 0.02^{17, 18}. The segments with statistically significant P value (0.05) of latency and/or amplitude were considered abnormal. Z values were calculated for both latency and amplitudes for each segment then converted to P value.

All statistical calculations were done using Microsoft Excel 2010 (Microsoft Corporation, NY, USA) and SSPS version 16. Correlations were done using the Pearson correlation method between any two quantitative data.

RESULTS

Nineteen eyes (63.3%) of the patient group had abnormal cVEP responses, while 11 eyes (36.7%) had normal VEP responses.

Twenty-eight eyes (93.3 %) of the examined 30 eyes had an abnormal mfVEP response, while only two eyes (6.7%) had normal mfVEP responses. Most of the abnormalities were due to prolongation in latencies of the mfVEP responses rather than amplitude reduction.

The mean and standard deviation for each segment of the 30 examined eyes were calculated for the patient group for the latency and amplitude and compared with that of the control group. We found out that segments number 6,9,26,33,44 and 45 showed a statistically significant P value (≤ 0.05) for the latency while all other segments showed non-significant P value as shown in Figure (1).

Regarding the amplitude, no segment showed a statistically significant P value.

There was a highly, statistically significant linear relationship between cVEP latency and intra-cranial pressure (ICP) ($P=0.0003$) (Table 1).

We correlated number of segments affected in mfVEP with cVEP latency using Pearson correlation; it showed a statistically significant linear relationship ($P=0.026$). In addition, number of segments affected of the mfVEP and the ICP showed a highly significant linear relationship ($P=0.009$).

Out of the 11 eyes that had normal cVEP responses, nine eyes (30% of sample size) had an abnormal mfVEP response, while only two eyes (6.7% of sample size) of them had a normal cVEP and

mfVEP responses. Comparing the cVEP and mfVEP as regards the ability to identify the abnormality of the optic pathway in IIH patients, the kappa (κ) statistic was used to determine the strength of agreement between the two tests. A statistically significant agreement was found between both ($P=0.038$). This means that although a difference exists between the number of eyes identified by each test an agreement between both results was found to be statistically significant (Table 2).

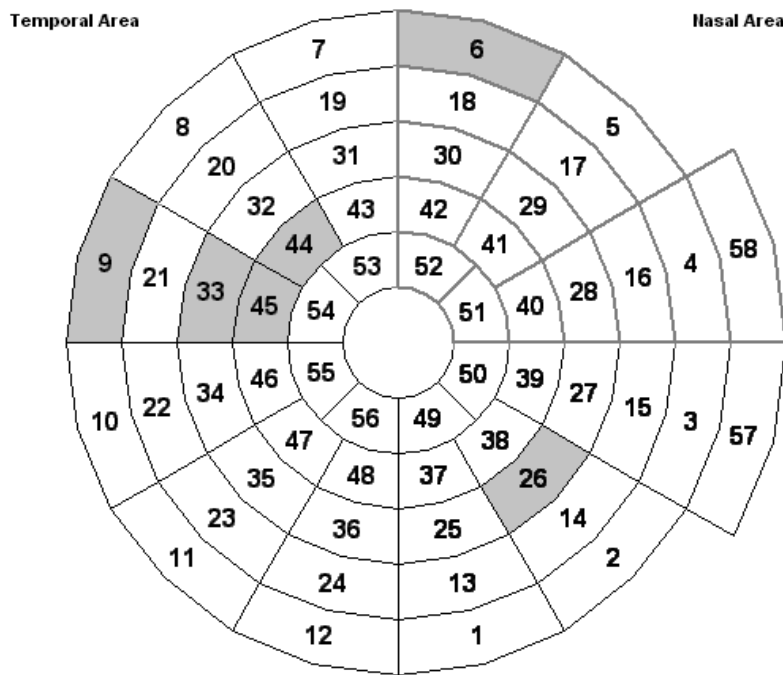


Figure 1. A result scheme for all 58 fields that shows the segments with significant P value for the latency.

Table 1. Shows the relation between the cVEP latency and ICP.

| | ICP |
|------------------------------------|---------|
| cVEP latency - Pearson Correlation | 0.761 |
| - Sig. (2-tailed) | 0.0003* |
| - Number of eyes | 30 |

*Correlation is significant at the 0.01 level (2-tailed)

cVEP conventional visual evoked potential, ICP intracranial pressure, sig. significance

Table 2. Shows the measure of agreement using kappa test between the cVEP and mfVEP.

| Measure of Agreement | Value | Asymp. Std. error | Approx. T | Approx. sig. |
|----------------------|-------|-------------------|-----------|--------------|
| Kappa | 0.25 | 0.15 | 2.07 | 0.038* |
| No. of valid cases | 30 | | | |

Approx approximate, asymp asymptomatic, std. standard

*significant at $p < 0.05$

DISCUSSION

Idiopathic intracranial hypertension is a syndrome of raised intracranial pressure in the absence of clinical, laboratory, or radiological evidence of possible etiology¹⁴. Studies of American-based populations have estimated that the incidence of IIH ranges from 0.9 to 1.0 per 100,000 in the general population. This figure increases to 1.6-3.5 per 100,000 in women reaching 7.9-20 per 100,000 in overweight women¹⁹.

The visual system is particularly sensitive to elevated intracranial pressure and chronic pressure elevation may lead to more significant visual deterioration²⁰. The ophthalmic hallmark of raised intracranial pressure is papilledema¹². In this study, 30 eyes (100%) of examined eyes in our patients had blurring of vision and papilledema on fundus examination. In a study of Arab IIH patients in Saudi Arabia, papilledema was found in 99% of patients²¹.

A percentage of 36.7% of the examined eyes had normal cVEP responses while 63.3% had abnormal cVEP responses. Demyelination of the nerves may be a more likely mechanism, similar to compression neuropathy in the peripheral nerves²². Our patients showed prolonged P100 responses' latencies on cVEP, while P100 responses' amplitudes were within normal ranges. Axonal damage was a late complication of the disease according to Guttman et al.²³ and Hickman et al.²⁴, while in glaucoma and in acute ischemic optic neuropathy, low amplitude of the VEP is the characteristic finding²⁵.

Falsini et al.²⁶ using more elaborated techniques, reported prolonged responses in 55% of their IIH patients. Kesler et al.⁸ determined a frequency of 55% prolonged cVEP responses in patients with IIH which represents a closer frequency to our patients (63.3%). The finding of prolonged VEP is not specific for IIH, but was described also in increased intracranial hypertension due to other causes as craniosynostosis²⁷ and head trauma²⁸; thus the assumption that the abnormalities are due to a direct influence of the increased intracranial pressure on the optic nerve is reinforced⁸.

In our study, there was a statistically significant linear relationship between cVEP latency and ICP, which agrees with Sorensen et al.²⁹ who found a linear relation between mean latency of P100 from both eyes and the intracranial pressure in their pseudotumor cerebri patients. As regarding mfVEP, 28 eyes (93.3 %) had abnormal responses, while only two eyes (6.7%) had normal responses. Most of the abnormalities were in the form of prolongation in latencies of the mfVEP responses rather than amplitude reduction.

The delay in latency of the mfVEP responses suggested that demyelination of the optic nerve may be the more likely mechanism²², and similar to that seen in multiple sclerosis^{23, 24}.

On comparing the patient group with the control group as regards the latency and amplitude of the 58 segments of the mfVEP responses, segments number 6,9,26,33,44 and 45 showed a statistically significant P value (≤ 0.05) for the latency compared to the control group while all other segments showed non-significant P value. Regarding the amplitude, no segments showed a statistically significant P value. Segments 9, 33, 44 and 45 are present in the upper temporal field, segment 6 in the upper nasal field and segment 26 in the lower nasal field. Segments 33, 44 and 45 are adjacent to each other in the upper temporal field and they are the frequently affected segments in our patients. Enlargement of the blind spot is commonly seen in IIH patients³⁰, Wall and George³¹, found that less common defects may be central, paracentral and cecocentral scotomata, with temporal losses.

Comparing the cVEP and mfVEP in identifying abnormalities of the optic pathway in IIH patients, we found that 63.3% of the examined eyes had abnormal cVEP responses while 93.3% had abnormal mfVEP responses. The kappa (κ) statistic was used to determine the strength of agreement between the two tests; a statistically significant agreement was found between both ($P=0.038$). A previous study compared the cVEP and mfVEP in assessing patients with multiple sclerosis and confirmed concordance between both techniques in 87.5% of cases. There was no superiority of either technique from the perspective of diagnostic sensitivity³².

A percentage of 81.8% of the examined eyes that had normal cVEP values were found to have an abnormal mfVEP response indicating an additive value of mfVEP in IIH patients, while 6.7% of the whole sample size had a normal cVEP and mfVEP responses. It was found that eight out of the nine eyes that had normal cVEP and abnormal mfVEP (26.6% of whole sample size) had peripheral field abnormalities with normal central vision according to their mfVEP responses, which could explain their normal cVEP, which is generated from the central 20° to 25° radius of the visual field³³.

In our study, a statistically significant linear relationship was found between number of segments affected of the mfVEP responses and cVEP latency ($P=0.026$) and ICP ($P=0.009$). No previous studies addressed assessment of IIH patients with mfVEP.

Thus, we conclude that, mfVEP is more sensitive than the cVEP in reflecting the damage to the optic nerve in IIH patients, and it remains to be seen with more studies whether follow up with mfVEP parameters can be clinically helpful to assess visual function of IIH patients.

[Disclosure: Authors report no conflict of interest]

REFERENCES

1. Spennato P, Ruggiero C, Parlato RS, Buonocore MC, Varone A, Cianciulli E, et al. Pseudotumor cerebri. *Childs Nerv Syst.* 2011 Feb;27(2):215–35.
2. Johnston I, Owlser B PJ. *The Pseudotumor Cerebri Syndrome.* Cambridge: Cambridge University Press; 2007.
3. Rangwala LM, Liu GT. Pediatric idiopathic intracranial hypertension. *Surv Ophthalmol.* 52(6):597–617.
4. Bruce BB, Biousse V, Newman NJ. Update on idiopathic intracranial hypertension. *Am J Ophthalmol.* 2011 Aug;152(2):163–9.
5. Wraige E, Chandler C, Pohl KRE. Idiopathic intracranial hypertension: is papilloedema inevitable? *Arch Dis Child.* 2002 Sep;87(3):223–4.
6. Baheti NN, Nair M, Thomas S V. Long-term visual outcome in idiopathic intracranial hypertension. *Ann Indian Acad Neurol.* 2011 Jan;14(1):19–22.
7. Daniels AB, Liu GT, Volpe NJ, Galetta SL, Moster ML, Newman NJ, et al. Profiles of obesity, weight gain, and quality of life in idiopathic intracranial hypertension (pseudotumor cerebri). *Am J Ophthalmol.* 2007 Apr;143(4):635–41.
8. Kesler A, Vakhapova V, Korczyn AD, Drory VE. Visual evoked potentials in idiopathic intracranial hypertension. *Clin Neurol Neurosurg.* 2009 Jun;111(5):433–6.
9. Hood DC, Thienprasiddhi P, Greenstein VC, Winn BJ, Ohri N, Liebmann JM, et al. Detecting early to mild glaucomatous damage: a comparison of the multifocal VEP and automated perimetry. *Invest Ophthalmol Vis Sci.* 2004 Feb;45(2):492–8.
10. Hood DC, Odel JG, Winn BJ. The multifocal visual evoked potential. *J Neuroophthalmol.* 2003 Dec;23(4):279–89.
11. Fortune B, Hood DC. Conventional pattern-reversal VEPs are not equivalent to summed multifocal VEPs. *Invest Ophthalmol Vis Sci.* 2003 Mar;44(3):1364–75.
12. Acheson JF. Idiopathic intracranial hypertension and visual function. *Br Med Bull.* 2006 Jan;79-80:233–44.
13. Hood DC, Zhang X, Winn BJ. Detecting glaucomatous damage with multifocal visual evoked potentials: how can a monocular test work? *J Glaucoma.* 2003 Feb;12(1):3–15.
14. Friedman DI, Jacobson DM. Diagnostic criteria for idiopathic intracranial hypertension. *Neurology.* 2002 Nov 26;59(10):1492–5.
15. Odom JV, Bach M, Brigell M, Holder GE, McCulloch DL, Tormene AP, et al. ISCEV standard for clinical visual evoked potentials (2009 update). *Doc Ophthalmol.* 2010 Feb;120(1):111–9.
16. Chiappa KH. *Evoked Potentials in Clinical Medicine.* Second Ed. New York: Raven Press; 1990.
17. Fraser C. The use of multifocal visual evoked potential objective perimetry for diagnosing optic neuritis primarily associated with Multiple Sclerosis. the University of Sydney; 2006.
18. De Moraes CG, Liebmann JM, Ritch R, Hood DC. Clinical use of multifocal visual-evoked potentials in a glaucoma practice: a prospective study. *Doc Ophthalmol.* 2012 Aug;125(1):1–9.
19. Wall M. Idiopathic intracranial hypertension (pseudotumor cerebri). *Curr Neurol Neurosci Rep.* 2008 Mar;8(2):87–93.
20. Wall M. Idiopathic intracranial hypertension: mechanisms of visual loss and disease management. *Semin Neurol.* 2000 Jan;20(1):89–95.
21. Alkali NH, Daif A, Dorasanamma M, Almoallem MA. Prognosis of idiopathic intracranial hypertension in Saudi Arabia. *Ann Afr Med.* 10(4):314–5.
22. Keir PJ, Rempel DM. Pathomechanics of peripheral nerve loading. Evidence in carpal tunnel syndrome. *J Hand Ther.* 18(2):259–69.
23. Weinstock-Guttman B, Baier M, Stockton R, Weinstock A, Justinger T, Munschauer F, et al. Pattern reversal visual evoked potentials as a measure of visual pathway pathology in multiple sclerosis. *Mult Scler.* 2003 Oct;9(5):529–34.
24. Hickman SJ, Toosy AT, Miszkiel KA, Jones SJ, Altmann DR, MacManus DG, et al. Visual recovery following acute optic neuritis—a clinical, electrophysiological and magnetic resonance imaging study. *J Neurol.* 2004 Aug;251(8):996–1005.
25. Parisi V, Miglior S, Manni G, Centofanti M, Bucci MG. Clinical ability of pattern electroretinograms and visual evoked potentials in detecting visual dysfunction in ocular hypertension and glaucoma. *Ophthalmology.* 2006 Feb;113(2):216–28.
26. Falsini B, Tamburrelli C, Porciatti V, Anile C, Porrello G, Mangiola N. Pattern electroretinograms and visual evoked potentials in idiopathic intracranial hypertension. *Ophthalmologica.* 1992 Jan;205(4):194–203.
27. Liasis A, Nischal KK, Walters B, Thompson D, Hardy S, Towell A, et al. Monitoring visual function in children with syndromic craniosynostosis: a comparison of 3 methods. *Arch Ophthalmol.* 2006 Aug;124(8):1119–26.
28. York DH, Pulliam MW, Rosenfeld JG, Watts C. Relationship between visual evoked potentials and intracranial pressure. *J Neurosurg.* 1981 Dec;55(6):909–16.
29. Sørensen PS, Trojaborg W, Gjerris F, Krogsaa B. Visual evoked potentials in pseudotumor cerebri. *Arch Neurol.* 1985 Feb;42(2):150–3.
30. Galvin JA, Van Stavern GP. Clinical characterization of idiopathic intracranial hypertension at the Detroit Medical Center. *J Neurol Sci.* 2004 Aug 30;223(2):157–60.

31. Wall M, George D. Idiopathic intracranial hypertension. A prospective study of 50 patients. Brain. 1991 Feb;114 (Pt 1):155-80.
32. Morris K, Klistorner A YC. Comparison of multifocal and conventional visual-evoked potentials in assessing patients with multiple sclerosis. 28th congress of the European committee for treatment and research of multiple sclerosis. Lyon; 2012.
33. Baseler HA, Sutter EE, Klein SA, Carney T. The topography of visual evoked response properties across the visual field. Electroencephalogr Clin Neurophysiol. 1994 Jan;90(1):65-81.

الملخص العربي

الجهد المثار البصري متعدد البؤر في ارتفاع الضغط غير المسبب

ارتفاع الضغط غير المسبب داخل الجمجمة هو مرض له مظاهر سريرية متعددة، أكثرها شيوعا الصداع، الاضطرابات البصرية وبعد فقدان البصر هو من المضاعفات الخطيرة لهذا المرض. ارتفاع الضغط غير المسبب داخل الجمجمة يصيب النساء البدينات في سن الإنجاب، لكنه يمكن أن يصيب المرضى بأي وزن، أو جنس، أو سن. يعد الجهد المثار البصري مؤشر حساس لوظيفة العصب البصري وقد تمكن الجهد المثار البصري متعدد البؤر من تسجيل الاستجابات البؤرية من مناطق متعددة من المجال البصري في نفس الوقت مما ساعد على إنشاء خريطة بصرية تمثل المجال بأكمله.

وقد كان الهدف من هذا العمل هو تقييم التغيرات في الجهد المثار البصري متعدد البؤر في مرضى ارتفاع الضغط غير المسبب داخل الجمجمة ومقارنة الجهد المثار البصري التقليدي والجهد المثار البصري متعدد البؤر في الكشف عن إصابة المسار البصري في مرضى ارتفاع الضغط غير المسبب داخل الجمجمة.

أجريت هذه الدراسة على مجموعتين؛ المجموعة الضابطة تألفت من 27 أنثى، وتراوحت أعمارهن بين 26-54 سنة ومجموعة المرضى التي تألفت من 15 أنثى تراوحت أعمارهن بين 27-55 سنة مع أعراض وعلامات متسقة مع معايير داندو المعدلة لتشخيص ارتفاع الضغط غير المسبب داخل الجمجمة وتم اختيارهن من المرضى المقيمين بقسم الأمراض العصبية والعيادات الخارجية بمستشفى جامعة القاهرة. تم أخذ التاريخ المرضي الكامل وعمل الفحص السريري الشامل لجميع المرضى.

وقد كانت نتائج الجهد المثار البصري التقليدي غير طبيعية في (63,3%) من المرضى في حين أن نتائج الجهد المثار البصري متعدد البؤر كانت غير طبيعية في (93,3%).

وتعد إزالة مادة الميالين من العصب البصري الآلية الأكثر احتمالا في مرضى ارتفاع الضغط غير المسبب داخل الجمجمة، الأمر الذي يتسبب في ضعف البصر ثم ضمور العصب البصري الذي قد يحدث في وقت متأخر.

وقد استنتجنا مما سبق أن الجهد المثار البصري متعدد البؤر له أفضلية على الجهد المثار البصري التقليدي في الكشف عن الأضرار البؤرية في مرضى ارتفاع الضغط غير المسبب داخل الجمجمة.